

## PDF hosted at the Radboud Repository of the Radboud University Nijmegen

The following full text is a publisher's version.

For additional information about this publication click this link.

<http://hdl.handle.net/2066/185552>

Please be advised that this information was generated on 2019-06-02 and may be subject to change.

A RECESSIVE FORM OF THE EHLERS–DANLOS SYNDROME  
CAUSED BY TENASCIN-X DEFICIENCY

JOOST SCHALKWIJK, PH.D., MANON C. ZWEERS, PH.D., PETER M. STEIJLEN, M.D., WILLOW B. DEAN, B.A.,  
GLEN TAYLOR, B.A., IVONNE M. VAN VLIJMEN, M.Sc., BRIGITTE VAN HAREN, M.D., WALTER L. MILLER, M.D.,  
AND JAMES BRISTOW, M.D.

**ABSTRACT**

**Background** The Ehlers–Danlos syndrome is a heritable connective-tissue disorder caused by defects in fibrillar-collagen metabolism. Mutations in the type V collagen genes account for up to 50 percent of cases of classic Ehlers–Danlos syndrome, but many other cases are unexplained. We investigated whether the deficiency of the tenascins, extracellular-matrix proteins that are highly expressed in connective tissues, was associated with the Ehlers–Danlos syndrome.

**Methods** We screened serum samples from 151 patients with the classic, hypermobility, or vascular types of the Ehlers–Danlos syndrome; 75 patients with psoriasis; 93 patients with rheumatoid arthritis; and 21 healthy persons for the presence of tenascin-X and tenascin-C by enzyme-linked immunosorbent assay. We examined the expression of tenascins and type V collagen in skin by immunohistochemical methods and sequenced the tenascin-X gene.

**Results** Tenascin-X was present in serum from all normal subjects, all patients with psoriasis, all patients with rheumatoid arthritis, and 146 of 151 patients with the Ehlers–Danlos syndrome. Tenascin-X was absent from the serum of the five remaining patients with Ehlers–Danlos syndrome, who were unrelated. Tenascin-X deficiency was confirmed in these patients by analysis of skin fibroblasts and by immunostaining of skin. The expression of tenascin-C and type V collagen was normal in these patients. All five of these patients had hypermobile joints, hyperelastic skin, and easy bruising, without atrophic scarring. Tenascin-X mutations were identified in all tenascin-X-deficient patients; one patient had a homozygous tenascin-X gene deletion, one was heterozygous for the deletion, and three others had homozygous truncating point mutations, confirming a causative role for tenascin-X and a recessive pattern of inheritance.

**Conclusions** Tenascin-X deficiency causes a clinically distinct, recessive form of the Ehlers–Danlos syndrome. This finding indicates that factors other than the collagens or collagen-processing enzymes can cause the syndrome and suggests a central role for tenascin-X in maintaining the integrity of collagenous matrix. (N Engl J Med 2001;345:1167-75.)

Copyright © 2001 Massachusetts Medical Society.

**T**HE Ehlers–Danlos syndrome is a genetically heterogeneous group of heritable connective-tissue disorders characterized by hyperextensible skin, hypermobile joints, and tissue fragility.<sup>1,2</sup> Ultrastructural studies of the skin in the Ehlers–Danlos syndrome frequently reveal abnormal heterotypic collagen fibrils containing collagen types I, III, and V, indicating that the syndrome is a disorder of the collagen fibril.<sup>3</sup> This concept is supported by the identification of mutations in genes encoding the fibrillar collagens or collagen-modifying enzymes in patients with the Ehlers–Danlos syndrome.<sup>4-12</sup> Thirty to 50 percent of patients with classic Ehlers–Danlos syndrome have haploinsufficiency of the gene encoding type V collagen (*COL5A1*).<sup>13,14</sup> Thus, although type V collagen mutations are an important cause of classic Ehlers–Danlos syndrome, other genes are probably involved in its pathogenesis.

The tenascins are a family of at least three structurally similar extracellular-matrix proteins.<sup>15</sup> Two of them, tenascin-C and tenascin-X, are expressed in the tissues affected in the Ehlers–Danlos syndrome, including skin, tendons, muscle, and blood vessels.<sup>16-20</sup> This pattern suggests a potential role in the Ehlers–Danlos syndrome.

Tenascin-X is a large extracellular-matrix protein that was originally identified because the gene encoding it overlaps *CYP21*, the gene that encodes steroid 21-hydroxylase.<sup>21,22</sup> We previously described a patient with a contiguous-gene syndrome consisting of congenital adrenal hyperplasia (due to 21-hydroxylase deficiency) and classic Ehlers–Danlos syndrome (apparently due to deficiency of tenascin-X).<sup>23</sup> In that index patient, tenascin-X protein and messenger RNA were absent from skin and cultured skin fibroblasts, and a large deletion encompassing all of *CYP21* and part of the tenascin-X gene was found on one allele. Although the findings in this patient suggested an essential function for one of the tenascins *in vivo*,<sup>24,25</sup> it remained unclear whether Ehlers–Danlos syndrome due to tenascin-X deficiency is dominant or recessive.

From the Department of Dermatology, University Medical Center Nijmegen, the Netherlands (J.S., M.C.Z., P.M.S., I.M.V., B.H.); and the Department of Pediatrics, University of California at San Francisco, San Francisco (W.B.D., G.T., W.L.M., J.B.). Address reprint requests to Dr. Bristow at the University of California at San Francisco, Laurel Heights Campus, 3333 California St., Box 1245, San Francisco, CA 94118, or at jbristow@pedcard.ucsf.edu, or to Dr. Schalkwijk at the Department of Dermatology, UMCN, P.O. Box 9101, 6500 HB Nijmegen, the Netherlands, or at j.schalkwijk@derma.azn.nl

sive. Furthermore, it was not known whether isolated deficiency of tenascin-X without congenital adrenal hyperplasia occurs, and if so, whether it causes the Ehlers–Danlos syndrome. Because tenascin-X is a secreted protein, we identified tenascin-X in normal serum and then developed protein-based assays to measure tenascin-X and tenascin-C in serum samples collected from patients with the Ehlers–Danlos syndrome.

## METHODS

### Study Population

The human-research committees of both participating institutions approved the study protocol, and all patients gave written informed consent. Serum was obtained from 151 patients with the Ehlers–Danlos syndrome, who were identified through the Dutch Ehlers–Danlos syndrome organization. The referring diagnosis was classic Ehlers–Danlos syndrome in 35 patients, isolated joint hypermobility in 87, and vascular-type Ehlers–Danlos syndrome in 1; 28 patients were unclassified. Serum was also collected from 21 normal persons, 75 patients with psoriasis, and 93 patients with rheumatoid arthritis. The samples were stored at  $-20^{\circ}\text{C}$  until used.

Five tenascin-X–deficient persons and their available relatives were examined by one of us according to the criteria of Beighton et al. for Ehlers–Danlos syndrome subtypes.<sup>2</sup> We used the nine-point Beighton scale to score joint hypermobility. Patients received a score of 1 for each fifth finger dorsiflexed more than 90 degrees, 1 for each thumb apposed to the wrist, 1 for each elbow hyperextended more than 10 degrees, 1 for each knee hyperextended more than 10 degrees, and 1 if the palms could be placed on the floor with the knees locked; the maximal score was 9 points. A score of 5 or more defines hypermobility. Skin hyperelasticity was scored on a three-point scale (0, 1, or 2); higher scores indicate greater elasticity. Two 4-mm punch-biopsy specimens of the skin were obtained from the upper thigh of each tenascin-X–deficient person for culture of dermal fibroblasts and immunohistochemical studies.

### Enzyme-Linked Immunosorbent Assay, Immunohistochemical Analysis, and Western Blotting

Tenascin-X was detected with a rabbit polyclonal antiserum<sup>23,26</sup> and a new guinea pig antiserum, both raised against a 100-kD carboxy-terminal fragment of human tenascin-X expressed in *Escherichia coli*. Tenascin-C was detected with mouse monoclonal antibody T2H5<sup>27</sup> and A107 rabbit polyclonal antiserum (Telios, La Jolla, Calif.). No cross-reactivity between tenascin-X and tenascin-C was found. Tenascin-C in serum was measured by enzyme-linked immunosorbent assay (ELISA) according to the method described by Latijnhouwers et al.,<sup>28</sup> with a lower limit of detection of 5 ng per milliliter. Tenascin-X was measured with use of a sandwich ELISA with affinity-purified rabbit anti–tenascin-X for antigen capture. Detection of tenascin-X was performed with use of guinea pig anti–tenascin-X, followed sequentially by biotinylated goat anti–guinea pig immunoglobulin and peroxidase-conjugated avidin–biotin complex (Vector Laboratories, Burlingame, Calif.). The lower limit of detection of the ELISA for tenascin-X was 100 pg per milliliter.

A semiquantitative ELISA was first used to screen patients with the Ehlers–Danlos syndrome, normal subjects, and patients with psoriasis or rheumatoid arthritis in a single (1:50) dilution of serum. For the quantitative determination of tenascin-X (Table 1), we tested serial dilutions of serum. Patients with Ehlers–Danlos syndrome and control populations were compared by analysis of variance with post hoc testing by Duncan's multiple-range test.

We immunostained cryosections of skin-biopsy specimens for tenascin-X and tenascin-C using the antisera described above. Paraffin sections were stained with hematoxylin and eosin or an antiserum to collagen V (Dako, Carpinteria, Calif.). Secondary antisera (biotinylated antirabbit or anti–guinea pig immunoglobulin)

TABLE 1. SERUM LEVELS OF TENASCIN-X AND TENASCIN-C.\*

SUBJECTS	TENASCIN-X		TENASCIN-C	
	NO. TESTED	ng/ml	NO. TESTED	μg/ml
Normal subjects	21	476±117	7	1.1±0.4
Patients with psoriasis	20	470±95	34	1.3±0.8
Patients with classic Ehlers–Danlos syndrome	31	448±217	31	1.2±0.5
Patient 1		<0.1		2.1
Patient 2		<0.1		1.1
Patient 3		<0.1		1.8
Patient 4		<0.1		1.1
Patient 5		<0.1		2.0
Obligate heterozygotes	12	217±57†		Not determined

\*Serum levels of tenascin-X and tenascin-C were determined by enzyme-linked immunosorbent assay. Tenascin-C levels in normal subjects and patients with psoriasis are from Latijnhouwers et al.<sup>28</sup> Tenascin-X and tenascin-C levels were read from standard curves by using recombinant C-terminal tenascin-X and purified tenascin-C. The indicated tenascin-X concentrations should be interpreted as equivalent to recombinant tenascin-X, because neither the serum form nor full-length native tenascin-X is available for use as a standard. Plus–minus values are means ±SD.

† $P<0.001$  for the comparison with the normal subjects.

lin) were followed by peroxidase-conjugated avidin–biotin complex and aminoethylcarbazol as the chromogenic substrate (Vector Laboratories). Western blotting of serum and fibroblast-culture supernatant was performed as described previously.<sup>23</sup>

### Cell Culture

First to third passages of human skin fibroblasts were used. Cells were grown in Dulbecco's modified Eagle H21 medium (GIBCO BRL, Rockville, Md.), supplemented with 10 percent fetal-calf serum, L-ascorbic acid (20 μg per milliliter), penicillin, and streptomycin. Conditioned medium was harvested from confluent cultures for assay of tenascin-X by ELISA and Western blotting.

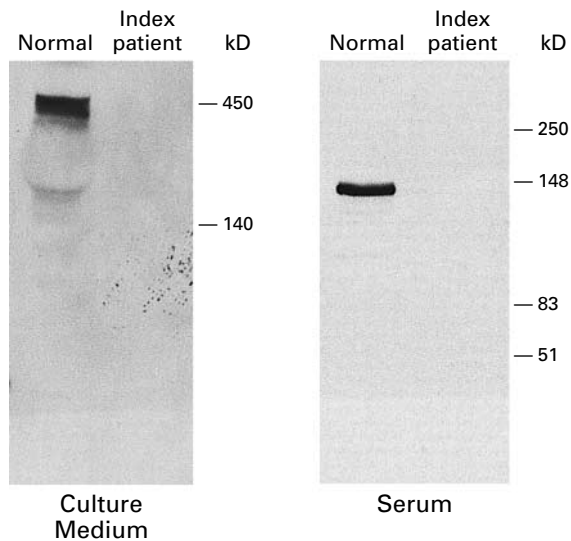
### Mutation Detection

Genomic DNA was prepared from peripheral blood or fibroblasts, and polymerase-chain-reaction (PCR) detection of the 30-kb tenascin-X deletion was carried out as previously described.<sup>23</sup> The coding sequence of tenascin-X was PCR-amplified with 23 primer pairs, with annealing at  $62^{\circ}\text{C}$  and extension for 2.5 minutes at  $72^{\circ}\text{C}$  for 35 cycles. The 12.5-kb region coding for tenascin-X was sequenced directly from PCR products with use of 42 primers. The sequences of primers used for PCR and DNA sequencing and the sizes of amplified products are available as Supplementary Appendix 1 with the full text of this article at <http://www.nejm.org>.

## RESULTS

### Absence of Tenascin-X in Serum from Patients with the Ehlers–Danlos Syndrome

Tenascin-X is normally secreted by skin fibroblasts as a 450-kD protein that can be detected with antibodies directed against its carboxy terminal (Fig. 1). Because tenascin-C is found in serum, we tested nor-



**Figure 1.** Detection of Tenascin-X in Culture Medium and Serum. The figure shows a Western blot of fibroblast-conditioned medium and serum from a normal subject and from the tenascin-X-deficient index patient. In medium conditioned by normal fibroblasts, the 450-kD tenascin-X monomer was detected, whereas in serum only a 140-kD species was present. No immunoreactive material was identified in fibroblast medium or serum from the tenascin-X-deficient patient.

mal human serum for the presence of tenascin-X. Tenascin-X is also readily detected in normal serum, but the serum form of tenascin-X is a 140-kD protein probably resulting from proteolytic cleavage or alternative splicing of tenascin-X (Fig. 1). To confirm that the immunoreactive species in serum is derived from the tenascin-X gene, we verified that the serum of the tenascin-X-deficient index patient<sup>23</sup> also lacked tenascin-X (Fig. 1).

Tenascin-X was readily detected by ELISA in serum from 21 healthy subjects and from 146 of 151 patients with the Ehlers–Danlos syndrome. However, five unrelated patients with the Ehlers–Danlos syndrome (designated Patients 1, 2, 3, 4, and 5) lacked tenascin-X. We also tested serum from 75 patients with psoriasis and 93 patients with rheumatoid arthritis to determine whether tenascin-X deficiency was a nonspecific result of skin or joint disease. Tenascin-X was present in the specimens from all these patients.

We repeated the ELISA at multiple dilutions of serum, using samples from the five tenascin-X-deficient patients, normal subjects, patients with classic Ehlers–Danlos syndrome who were not deficient in tenascin-X in the initial screening, and patients with psoriasis (Table 1). The control groups had similar serum concentrations of tenascin-X, but tenascin-X

was again undetectable in serum samples from the five tenascin-X-deficient patients. Although tenascin-C is coexpressed with tenascin-X in tissues affected by the Ehlers–Danlos syndrome, all the patients had normal serum tenascin-C levels (Table 1).

#### Tenascin-X Deficiency in Skin and Fibroblasts of Patients with the Ehlers–Danlos Syndrome

Tenascin-X was readily detected in conditioned medium from cultures of normal skin fibroblasts by Western blotting (Fig. 1) and ELISA, although the mean ( $\pm$ SD) amount of tenascin-X found in conditioned medium ( $0.54 \pm 0.06$  ng per milliliter in 48-hour supernatants of confluent cells) was substantially less than in serum. As expected, Western blotting and ELISA did not detect tenascin-X in medium conditioned by fibroblasts of the five patients who lacked tenascin-X in their serum, a result that confirmed that these patients had tenascin-X deficiency.

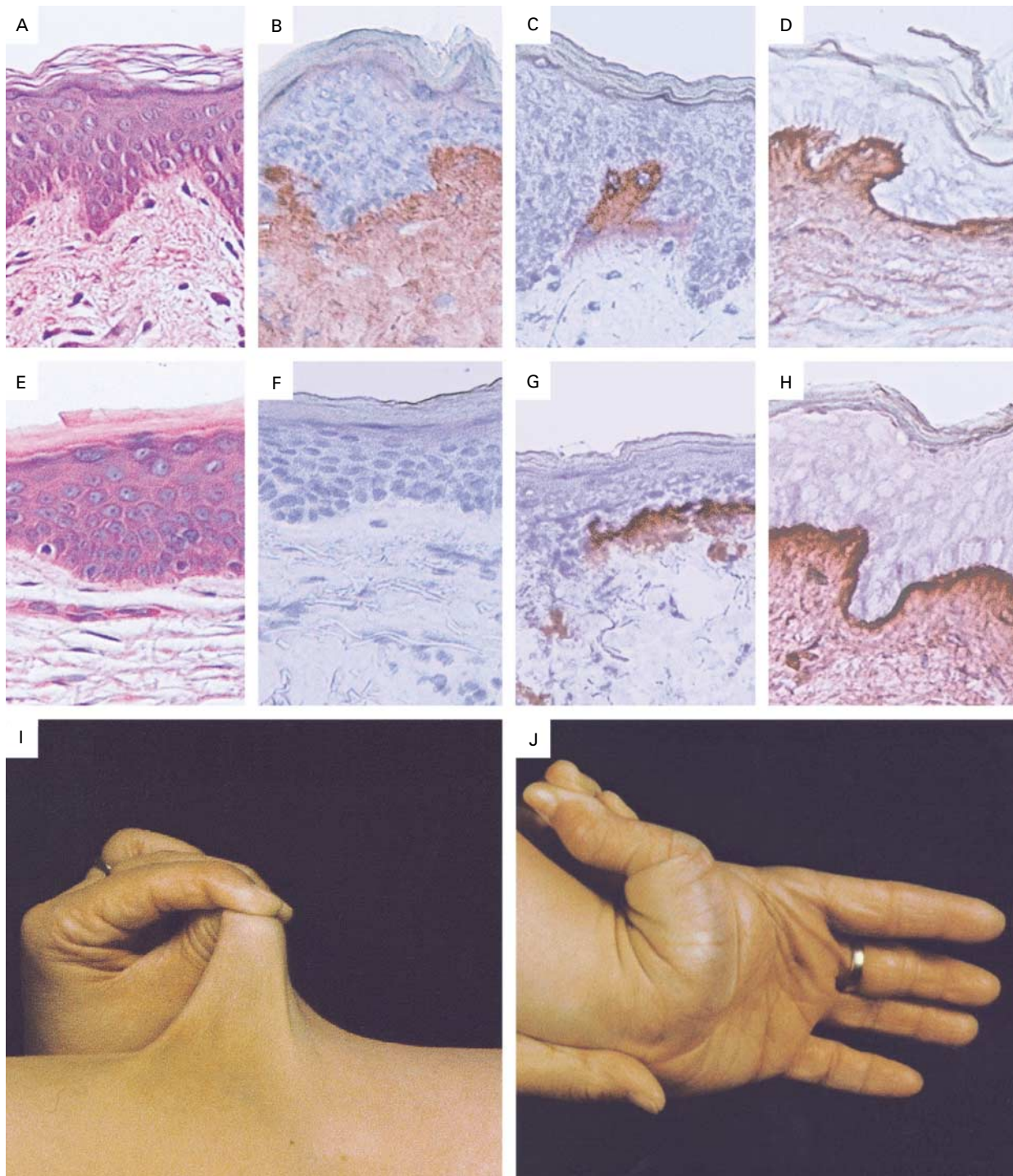
Histologic examination of skin-biopsy specimens from tenascin-X-deficient patients revealed no gross morphologic abnormalities, although the collagen network in the papillary dermis appeared less dense (Fig. 2E) than in specimens of normal skin (Fig. 2A). Immunostaining showed abundant expression of tenascin-X throughout the dermis of normal skin (Fig. 2B), whereas tenascin-X was completely absent in skin from patients who lacked tenascin-X in their serum (Fig. 2F). Tenascin-C and type V collagen were expressed normally in dermis of tenascin-X-deficient persons (Fig. 2C, 2D, 2G, and 2H).

#### Clinical Findings in Tenascin-X Deficiency

All five tenascin-X-deficient patients and three clinically affected tenascin-X-deficient siblings had hyperelastic skin and hypermobile joints (Table 2 and Fig. 2I and 2J), fulfilling major diagnostic criteria for classic Ehlers–Danlos syndrome. Minor diagnostic criteria supporting the diagnosis of classic Ehlers–Danlos syndrome in the tenascin-X-deficient patients and their siblings included easy bruising in all, velvety skin in seven, joint pain in two, and multiple subluxations in three. No delayed wound healing or atrophic scars were noted. For this reason and because of the absence of evidence of dominant inheritance, four of the five patients were unclassified at the time of referral. Of the eight tenascin-X-deficient patients, only Patient 3 had coexisting congenital adrenal hyperplasia.

None of the parents of the five patients with tenascin-X deficiency were related, and none of the four parents available for study (from the families of Patients 1, 2, and 3) had clinical signs of the Ehlers–Danlos syndrome. The father of Patient 1 had mitral insufficiency, and the father of Patient 2 had atrial arrhythmias and had had a cerebrovascular accident.

These tenascin-X-deficient patients also had a range of additional clinical findings not frequently associat-



**Figure 2.** Histopathological Findings in Skin in Patients with Tenascin-X Deficiency.

Panels A, B, C, and D show normal control skin, and Panels E through J show the skin and joints of a patient with the Ehlers–Danlos syndrome and tenascin-X deficiency. Hematoxylin and eosin staining revealed less dense eosinophilic staining in tenascin-X–deficient skin (Panel E) than in normal skin (Panel A) of the papillary dermis. Immunostaining with antiserum against recombinant tenascin-X showed strong staining of the papillary dermis and moderate staining of the deeper dermal layers in normal skin (Panel B), but no staining for tenascin-X was seen in the extracellular matrix of tenascin-X–deficient skin (Panel F). Staining for tenascin-C (Panels C and G) and type V collagen (Panels F and H) was similar in control and tenascin-X–deficient skin. (Magnification in Panels A through H,  $\times 250$ .) Panels I and J show the skin hyperextensibility and joint hypermobility typical of tenascin-X–deficient patients with the Ehlers–Danlos syndrome.

**TABLE 2.** CLINICAL CHARACTERISTICS OF FIVE TENASCIN-X–DEFICIENT PATIENTS AND THREE AFFECTED SIBLINGS.

PATIENT	SEX AND AGE (YR)	HYPER-EXTENSIBILITY SCORE*	HYPER-MOBILITY SCORE†	EASY BRUISING	ATROPHIC SCARS	VELVETY SKIN	OTHER SYMPTOMS
Patient 1	F/43	1	5	+	–	+	Joint pain, striae
Sister of Patient 1	F/53	2	4	+	–	+	Goiter
Patient 2	F/39	1	7	+	–	+	Multiple subluxations, IgA deficiency, spina bifida occulta
Sister of Patient 2	F/44	2	8	+	–	+	Multiple subluxations, chronic obstructive pulmonary disease
Brother of Patient 2	M/43	1	7	+	–	+	Hypertension
Patient 3	F/32	2	9	+	–	+	Congenital adrenal hyperplasia, Sudeck's atrophy of the left arm
Patient 4	M/44	1	4	+	–	+	Mitral-valve insufficiency, multiple subluxations, stroke, gastrointestinal bleeding
Patient 5	F/48	2	ND	+	–	–	Arrhythmia, cardiomyopathy, arteriosclerosis, amputation of the left leg

\*Skin hyperextensibility was scored on a three-point scale: 0 absent, 1 present, and 2 severe.

†Joint hypermobility was assessed by the Beighton scale<sup>22</sup>; ND denotes not determined. A score of 5 or more indicates hypermobility.

ed with the Ehlers–Danlos syndrome (Table 2). These included congenital adrenal hyperplasia, spina bifida occulta, mitral-valve prolapse, stroke, gastrointestinal bleeding, and premature arteriosclerosis. Although these conditions contributed substantially to the disability of this cohort of tenascin-X–deficient patients, it is not yet clear whether these additional disorders were related to tenascin-X deficiency or were unrelated coexisting conditions.

**Genetics of Tenascin-X Deficiency**

The complete absence of tenascin-X messenger RNA and protein in our index patient suggested that tenascin-X deficiency is recessive.<sup>23</sup> The index patient's phenotypically normal parents and siblings each shared one tenascin-X allele with him, providing further evidence of a recessive pattern of inheritance. However, only the index patient's paternal tenascin-X allele carried a gene deletion, and complete sequencing of the tenascin-X gene failed to identify a second mutation.

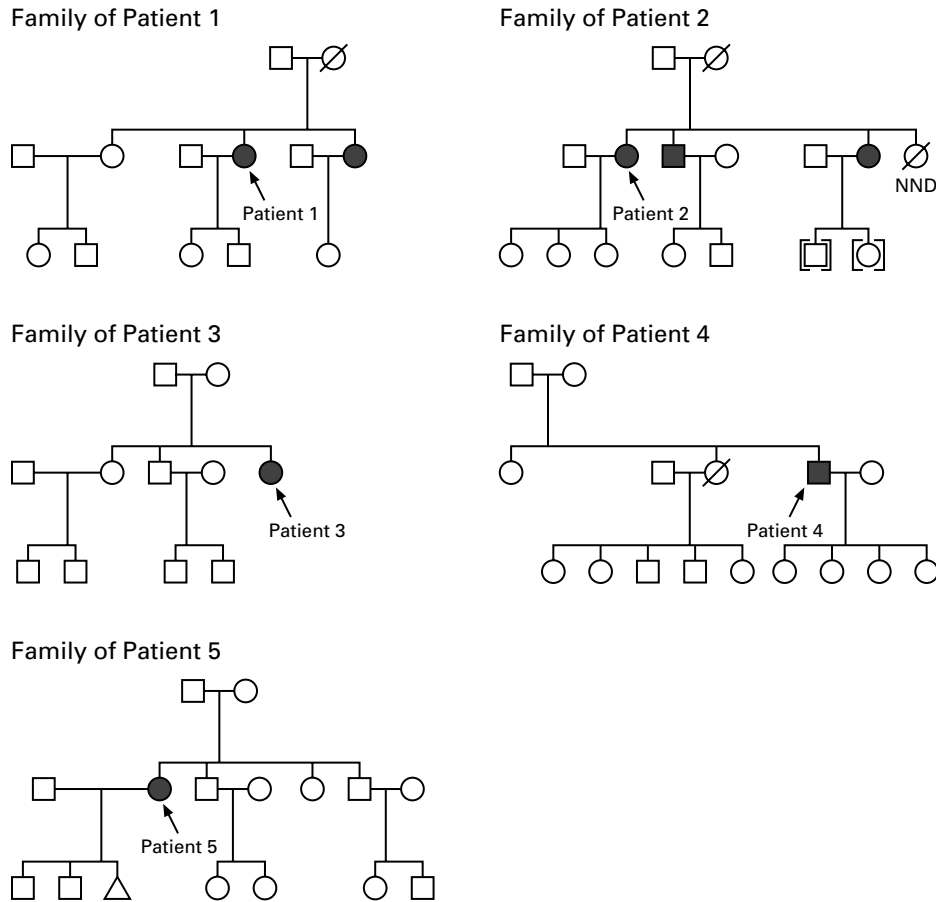
The present study allowed us to reexamine whether isolated tenascin-X deficiency is dominant or recessive (Fig. 3). In three of the families we studied (those of Patients 3, 4, and 5), the patient was the only affected member and both parents were phenotypically normal, a situation consistent with recessive inheritance or with the presence of new dominant mutations in each patient. In the other two families (those of Patients 1 and 2), there were three clinically affected siblings of patients, all of whom were tenascin-X–deficient. The presence of two or more affected siblings makes new mutation an unlikely mechanism of

disease in these families. Furthermore, clinical Ehlers–Danlos syndrome and tenascin-X deficiency were confined to members of one generation in all five families, also evidence of recessive inheritance. Finally, we measured serum tenascin-X levels in 12 parents and children of tenascin-X–deficient patients, who would be obligatory heterozygotes if tenascin-X deficiency were recessive. The mean serum tenascin-X concentration in these persons was approximately half that in controls (Table 1), a result consistent with haploinsufficiency and strongly supporting the hypothesis of recessive inheritance.

**Mutation Detection**

We tested the tenascin-X–deficient patients for the 30-kb deletion described in the index patient.<sup>23</sup> This deletion creates a fusion gene of tenascin-X and XA, a partial duplicate of tenascin-X. The XA gene has an internal deletion that truncates its open reading frame, rendering XA and the fusion gene nonfunctional. The fusion gene can be amplified independently of the normal tenascin-X gene by allele-specific PCR (Fig. 4A). Patient 3 had the same contiguous-gene syndrome as the index patient, but unlike the index patient, she was homozygous for the deletion, which explains both the presence of Ehlers–Danlos syndrome and that of congenital adrenal hyperplasia (Fig. 4B). Both her parents and two siblings were heterozygous for the deletion and were clinically normal, providing evidence of recessive inheritance in this family.

We next sequenced the tenascin-X gene in the re-

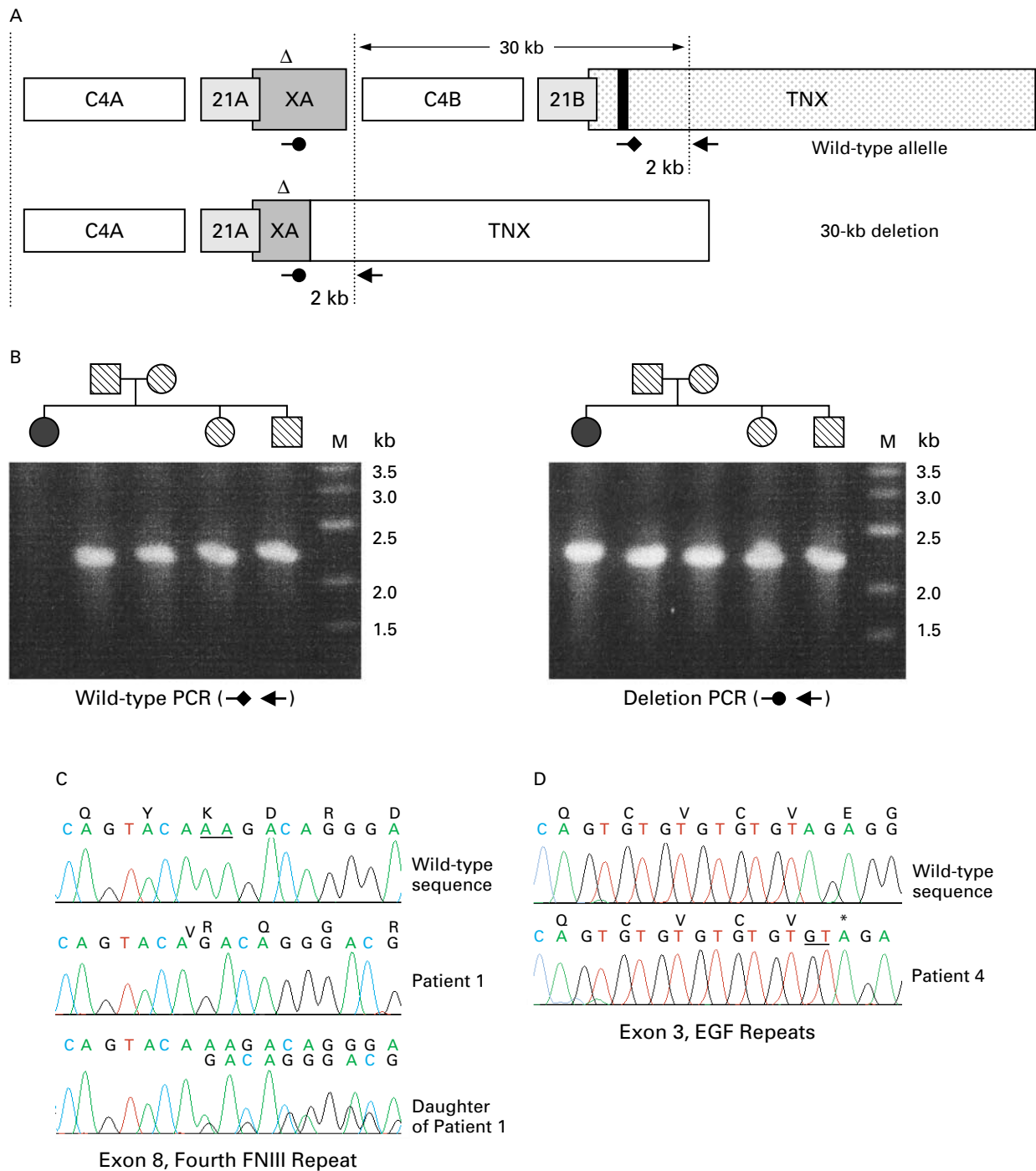


**Figure 3.** Pedigrees of the Five Tenascin-X-Deficient Patients.

Patients identified in the initial screening are indicated by arrows. Solid symbols indicate persons with complete tenascin-X deficiency. Circles indicate female family members, squares male family members, and symbols with a slash mark deceased members. Three additional affected family members were identified in the families of Patients 1 and 2. Brackets indicate adopted children in the family of Patient 2, and the triangle in the family of Patient 5 represents a stillborn female child. NND denotes neonatal death.

**Figure 4 (facing page).** Mutation Analysis of the Tenascin-X Gene.

The upper figure in Panel A shows a genetic map of the tenascin-X locus. The locus is duplicated into A and B loci at the positions shown by the vertical dotted line. C4A and C4B encode isoforms of the fourth component of serum complement; 21A is a pseudogene, and 21B is the functional 21-hydroxylase gene; XA is a partial duplicate of tenascin-X (TNX).<sup>29</sup> Unique polymerase-chain-reaction (PCR) primers were designed that are specific for XA (→) and tenascin-X (←→). These primers were paired with a tenascin-X sense primer (←). The 30-kb deletion removes 21B and creates a nonfunctional tenascin-X-XA fusion gene (lower figure in Panel A).<sup>23</sup> XA is a partial duplicate of tenascin-X and has an internal deletion (Δ). Panel B shows PCR products from the normal and deleted alleles for Patient 3 and her family. M indicates molecular-size markers. The wild-type allele was present in all family members except the patient (left), whereas the deleted allele was amplified from all family members (right). The patient was homozygous for the deletion (solid symbols), which produces combined Ehlers-Danlos syndrome and congenital adrenal hyperplasia, whereas unaffected parents and siblings were heterozygous for the deletion (hatched symbols). Panel C shows mutation analysis of Patient 1 and her daughter. The nucleotide and predicted amino-acid sequences at the 3' end of exon 8 are shown above the top two electropherograms of Panels C and D. The bottom electropherogram of Panel C shows the DNA sequence of both alleles. A two-nucleotide deletion (underlined) was found in codon 1184. Patient 1 was homozygous for this mutation, and her unaffected father and daughter were heterozygous. FNIII denotes fibronectin type III. In Panel D, sequence analysis of exon 3, encoding the epidermal growth factor (EGF) repeat domain, demonstrates a homozygous insertion of guanosine and thymine in Patient 4, which changes a glutamic acid residue to a stop codon (asterisk).



maining patients to identify point mutations or small insertions or deletions. In Patient 1, we found a homozygous 2-bp deletion in exon 8 that encoded the fourth fibronectin type III repeat (Fig. 4C). This deletion alters the open reading frame, affecting amino acids 1184 through 1230, after which a premature

stop codon is encountered (not shown). The clinically normal father of this patient was heterozygous for the deletion (Fig. 4C). We could not examine the mother because she had died (Fig. 3), but we found that one of her sisters carried the deletion. It is therefore likely that the mother of Patient 1 also car-



ried this mutation, which would be consistent with recessive inheritance. Patient 5 was also homozygous for this mutation, but her parents were unavailable for study.

Patient 4 carried a homozygous 2-bp insertion in exon 3, encoding the epidermal growth factor–like repeats of tenascin-X (Fig. 4D). The insertion of guanosine and thymine replaced the glutamic acid residue at position 707 with a stop codon. Additional family members were not available for study.

Patient 2 was heterozygous for the 30-kb deletion and did not have congenital adrenal hyperplasia. We were unable to identify a second tenascin-X mutation in this patient, although we sequenced the entire tenascin-X gene. This patient, like our index patient, may have had a mutation in factors, not yet defined, that regulate tenascin-X gene expression.

Finally, we wondered whether missense mutations in tenascin-X could also cause classic Ehlers–Danlos syndrome. To answer this question, we sequenced the entire tenascin-X gene in 10 patients who had classic Ehlers–Danlos syndrome and normal serum levels of tenascin-X. In these patients, we identified 26 DNA polymorphisms, 8 of which change an amino acid (data not shown). However, all 8 polymorphisms were identified in a cohort of 48 normal persons, demonstrating that these polymorphisms do not by themselves cause disease.

## DISCUSSION

This study defines a form of the Ehlers–Danlos syndrome that is both clinically and genetically distinct from previously described types.<sup>2</sup> All tenascin-X–deficient patients fulfilled three criteria for the Ehlers–Danlos syndrome: they had hyperelastic skin, hypermobile joints, and fragile tissue, manifested as easy bruising. Although the clinical findings of tenascin-X deficiency are similar to those of the classic type of Ehlers–Danlos syndrome, the tenascin-X–deficient patients we studied lacked atrophic scars, a major diagnostic criterion for the classic type. Delayed wound healing is also found frequently in patients with classic Ehlers–Danlos syndrome. Delayed wound healing was found in our index patient but was not a prominent feature of the present cohort. Whether delayed wound healing is a rare finding in tenascin-X deficiency or is a consequence of the treatment of congenital adrenal hyperplasia with glucocorticoids is not clear.

Tenascin-X deficiency is also distinguished from classic Ehlers–Danlos syndrome by its mode of inheritance. Classic Ehlers–Danlos syndrome is an autosomal dominant disorder. Tenascin-X deficiency is recessive, as shown by the occurrence of Ehlers–Danlos syndrome in only one generation in each family; the complete absence of tenascin-X protein from the serum, skin, and fibroblast-conditioned medium of affected persons; the lack of a clinical phenotype in

parents and offspring with tenascin-X haploinsufficiency; and the identification of homozygous tenascin-X mutations in four of the five tenascin-X–deficient patients.

Although more study is needed to determine whether other conditions are associated with tenascin-X deficiency, the list of coexisting diseases in this cohort with isolated tenascin-X deficiency is striking (Table 2) and suggests that tenascin-X deficiency may be a particularly debilitating form of the Ehlers–Danlos syndrome. The diagnosis should be considered in patients with the Ehlers–Danlos syndrome who do not have atrophic scars and in those without affected family members, or when the disease is confined to one generation. The availability of a simple serum-based test for tenascin-X deficiency should make accurate diagnosis of this deficiency possible in populations with the Ehlers–Danlos syndrome and should lead to more widespread recognition of this variant.

Despite a decade of intensive investigation, very little is known about the functions of the tenascins.<sup>15,25,30</sup> Patients with isolated tenascin-X deficiency provide evidence of an *in vivo* function of the tenascins, though it is not yet clear how tenascin-X deficiency leads to the Ehlers–Danlos syndrome. Several mechanisms of action of tenascin-X are possible. Tenascin-X may be an important structural component of the affected connective tissues. The fibronectin type III repeats of titin and tenascin-C may be capable of reversible unfolding and refolding and may thus act as serial elastic elements.<sup>31</sup> Tenascin-X appears to be associated with collagen fibrils,<sup>32,33</sup> so tenascin-X may act as an elastic element linking adjacent collagen fibrils and limiting the deformability of collagenous matrix.

Tenascin-X may also affect fibrillar collagen synthesis or fibrillogenesis. Type V collagen expression appears to be normal in tenascin-X–deficient patients, but the synthesis of other fibrillar collagens has not been examined.

Finally, it is possible that tenascin-X regulates collagen deposition. Although the structure of fibrils is normal in tenascin-X–deficient patients, the density of the collagenous matrix in the skin appears to be reduced (Fig. 2). During development, tenascin-X expression is maximal when the connective-tissue scaffolding for muscle, tendon, and ligament is being laid down,<sup>18</sup> suggesting that tenascin-X may influence the tissue-specific forms that fibrillar collagens assume.<sup>34</sup> The search for additional causes of the Ehlers–Danlos syndrome should now extend beyond the collagens.

Supported by grants from the National Institutes of Health (HL02695, to Dr. Bristow, and DK37922 and DK42154, to Dr. Miller), the March of Dimes Birth Defects Foundation (to Dr. Bristow), and the University Medical Center Nijmegen (to Dr. Schalkwijk).

*We are indebted to Dr. B. Hamel (Department of Human Genetics), Dr. B. van Engelen (Department of Neurology), Mrs. M. Koo-*

*ijmans-Otero (Department of Dermatology), and Dr. M. Latijnhouwers (Department of Dermatology) — all of the University Medical Center Nijmegen, Nijmegen, the Netherlands — for their advice and technical assistance.*

REFERENCES

1. Beighton P, de Paepe A, Danks D, et al. International Nosology of Heritable Disorders of Connective Tissue, Berlin, 1986. *Am J Med Genet* 1988;29:581-94.

2. Beighton P, De Paepe A, Steinmann B, Tsipouras P, Wenstrup RJ. Ehlers-Danlos syndromes: revised nosology, Villefranche, 1997. *Am J Med Genet* 1998;77:31-7.

3. Vogel A, Holbrook KA, Steinmann B, Gitzelmann R, Byers PH. Abnormal collagen fibril structure in the gravis form (type I) of Ehlers-Danlos syndrome. *Lab Invest* 1979;40:201-6.

4. Hyland J, Ala-Kokko L, Royce P, Steinmann B, Kivirikko KI, Myllylä R. A homozygous stop codon in the lysyl hydroxylase gene in two siblings with Ehlers-Danlos syndrome type VI. *Nat Genet* 1992;2:228-31.

5. Smith LT, Wertelecki W, Milstone LM, et al. Human dermatosparaxis: a form of Ehlers-Danlos syndrome that results from failure to remove the amino-terminal propeptide of type I procollagen. *Am J Hum Genet* 1992;51:235-44.

6. Byers PH. Ehlers-Danlos syndrome: recent advances and current understanding of the clinical and genetic heterogeneity. *J Invest Dermatol* 1994;103:Suppl:47S-52S.

7. Toriello HV, Glover TW, Takahara K, et al. A translocation interrupts the COL5A1 gene in a patient with Ehlers-Danlos syndrome and hypomelanosis of Ito. *Nat Genet* 1996;13:361-5.

8. Giunta C, Steinmann B. Compound heterozygosity for a disease-causing G1489D and disease-modifying G530S substitution in COL5A1 of a patient with the classical type of Ehlers-Danlos syndrome: an explanation of intrafamilial variability? *Am J Med Genet* 2000;90:72-9.

9. De Paepe A, Nuytinck L, Hausser I, Anton-Lamprecht I, Naeyaert JM. Mutations in the COL5A1 gene are causal in the Ehlers-Danlos syndromes I and II. *Am J Hum Genet* 1997;60:547-54.

10. Smith LT, Schwarze U, Goldstein J, Byers PH. Mutations in the COL3A1 gene result in the Ehlers-Danlos syndrome type IV and alterations in the size and distribution of the major collagen fibrils of the dermis. *J Invest Dermatol* 1997;108:241-7.

11. Burrows NP, Nicholls AC, Richards AJ, et al. A point mutation in an intronic branch site results in aberrant splicing of COL5A1 and in Ehlers-Danlos syndrome type II in two British families. *Am J Hum Genet* 1998;63:390-8.

12. Wenstrup RJ, Langland GT, Willing MC, D'Souza VN, Cole WG. A splice-junction mutation in the region of COL5A1 that codes for the carboxyl propeptide of pro alpha 1(V) chains results in the gravis form of the Ehlers-Danlos syndrome (type I). *Hum Mol Genet* 1996;5:1733-6.

13. Schwarze U, Atkinson M, Hoffman GG, Greenspan DS, Byers PH. Null alleles of the COL5A1 gene of type V collagen are a cause of the classical forms of Ehlers-Danlos syndrome (types I and II). *Am J Hum Genet* 2000;66:1757-65.

14. Wenstrup RJ, Florer JB, Willing MC, et al. COL5A1 halpainsufficient-

cy is a common molecular mechanism underlying the classical form of EDS. *Am J Hum Genet* 2000;66:1766-76.

15. Erickson HP. Tenascin-C, tenascin-R and tenascin-X: a family of talented proteins in search of functions. *Curr Opin Cell Biol* 1993;5:869-76.

16. Schalkwijk J, Steijlen PM, Vlijmen-Willems IM, Oosterling B, Mackie EJ, Verstraeten AA. Tenascin expression in human dermis is related to epidermal proliferation. *Am J Pathol* 1991;139:1143-50.

17. Matsumoto K, Saga Y, Ikemura T, Sakakura T, Chiquet-Ehrismann R. The distribution of tenascin-X is distinct and often reciprocal to that of tenascin-C. *J Cell Biol* 1994;125:483-93.

18. Burch GH, Bedolli MA, McDonough S, Rosenthal SM, Bristow J. Embryonic expression of tenascin-X suggests a role in limb, muscle, and heart development. *Dev Dyn* 1995;203:491-504.

19. Geffrotin C, Garrido JJ, Tremet L, Vaiman M. Distinct tissue distribution in pigs of tenascin-X and tenascin-C transcripts. *Eur J Biochem* 1995;231:83-92.

20. Mackie EJ, Ramsey S. Expression of tenascin in joint-associated tissues during development and postnatal growth. *J Anat* 1996;188:157-65.

21. Morel Y, Bristow J, Gitelman SE, Miller WL. Transcript encoded on the opposite strand of the human steroid 21-hydroxylase/complement component C4 gene locus. *Proc Natl Acad Sci U S A* 1989;86:6582-6.

22. Bristow J, Tee MK, Gitelman SE, Mellon SH, Miller WL. Tenascin-X: a novel extracellular matrix protein encoded by the human XB gene overlapping P450c21B. *J Cell Biol* 1993;122:265-78.

23. Burch GH, Gong Y, Liu W, et al. Tenascin-X deficiency is associated with Ehlers-Danlos syndrome. *Nat Genet* 1997;17:104-8.

24. Erickson HP. Gene knockouts of c-src, transforming growth factor beta 1, and tenascin suggest superfluous, nonfunctional expression of proteins. *J Cell Biol* 1993;120:1079-81.

25. *Idem*. A tenascin knockout with a phenotype. *Nat Genet* 1997;17:5-7.

26. Tee MK, Thomson AA, Bristow J, Miller WL. Sequences promoting the transcription of the human XA gene overlapping P450c21A correctly predict the presence of a novel, adrenal-specific, truncated form of tenascin-X. *Genomics* 1995;28:171-8.

27. Verstraeten AA, Mackie EJ, Hageman PC, et al. Tenascin expression in basal cell carcinoma. *Br J Dermatol* 1992;127:571-4.

28. Latijnhouwers MA, Bergers M, Kuijpers AL, et al. Tenascin-C is not a useful marker for disease activity in psoriasis. *Acta Derm Venereol* 1998;78:331-4.

29. Gitelman SE, Bristow J, Miller WL. Mechanism and consequences of the duplication of the human C4/P450c21/gene X locus. *Mol Cell Biol* 1992;12:2124-34. [Erratum, *Mol Cell Biol* 1992;12:3313-4.]

30. Mackie EJ, Tucker RP. The tenascin-C knockout revisited. *J Cell Sci* 1999;112:3847-53.

31. Oberhauser AF, Marszalek PE, Erickson HP, Fernandez JM. The molecular elasticity of the extracellular matrix protein tenascin. *Nature* 1998;393:181-5.

32. Eleftheriou F, Exposito JY, Garrone R, Lethias C. Characterization of the bovine tenascin-X. *J Biol Chem* 1997;272:22866-74.

33. Lethias C, Descollonges Y, Boutillon MM, Garrone R. Flexilin: a new extracellular matrix glycoprotein localized on collagen fibrils. *Matrix Biol* 1996;15:11-9.

34. Mao JR, Bristow J. The Ehlers-Danlos syndrome: on beyond collagens. *J Clin Invest* 2001;107:1063-9.

Copyright © 2001 Massachusetts Medical Society.