

**UNIVERSITY OF ZAGREB
SCHOOL OF MEDICINE**

Jure Murgić

**MRI guidance in high-dose-rate
brachytherapy for prostate cancer**

DISSERTATION



Zagreb, 2017.

**UNIVERSITY OF ZAGREB
SCHOOL OF MEDICINE**

Jure Murgić

**MRI guidance in high-dose-rate
brachytherapy for prostate cancer**

DISSERTATION

Zagreb, 2017.

This dissertation was made in the Radiation Medicine Program at Princess Margaret Cancer Centre University Health Network and Department of Radiation Oncology, University of Toronto, Canada.

Mentor 1: Prof. Zvonko Kusić, MD, PhD

Mentor 2: Prof. Cynthia Ménard, MD, FRCPC

First of all, I would like to express the most sincere gratitude to my mentor, Dr. Cynthia Ménard, who made this dissertation possible. Cythia is passionate brachytherapist, far-sighted innovator, distinguished scientist, dedicated clinician, great mentor and I really do feel privileged and honoured I was able to work closely with her and to learn from her vast knowledge and experience.

I also need to acknowledge Dr. Rob Bristow, mentor from my prostate cancer genomics project who allowed me to continue brachytherapy research while working in his clinical service and in the lab.

I would also like to thank to my Croatian mentor, professor Kusić, who provided me with the opportunity to specialize oncology and later on pushed me in the field of prostate cancer. Moreover, he wholeheartedly supported my overseas research endeavours and taught me the life wisdom.

Thanks mom for your love, support and for believing in my potential. Dear dad, aunt, granny and sister, thanks to all of you for providing me with strong family foundations that are pillars of my whole life.

I also express my gratitude to my loving wife Lucija who supported me from the beginning of my career and made my stay in US and Canada enduring and enjoyable. Words cannot express my appreciation for you.

Finally, my warmest gratitude goes to our lovely children Dominik, Marija, Marko and Jakov, who tolerated daddy's often absence from home. Hopefully this will pay off one day. Thank you from the bottom of my heart!

CONTENTS:

1. INTRODUCTION AND BACKGROUND FOR THE PROPOSED RESEARCH.....	1
1.1. Epidemiology of prostate cancer.....	1
1.2. Risk stratification and management options in localized prostate cancer.....	2
1.3. Evolving role of radiotherapy technique and delivery for prostate cancer treatment.....	5
1.4. Radiotherapy dose considerations.....	6
1.5. Interaction of radiotherapy dose escalation and androgen deprivation therapy.....	9
1.6. Addition of androgen deprivation therapy to improve radiotherapy outcomes.....	10
1.7. General radiobiology considerations.....	14
1.8. Biological effects of radiation and radiobiology of brachytherapy.....	17
1.9. Brachytherapy treatment options (LDR vs HDR).....	18
1.10. Rationale for combining HDR brachytherapy and EBRT.....	21
1.11. Image guidance modalities for HDR brachytherapy.....	25
1.12. Role of MRI in the prostate cancer management and HDR brachytherapy image guidance.....	27
1.13. Rationale for proposed research.....	29
2. HYPOTHESIS	31
3. AIMS AND PURPOSE OF THE RESEARCH.....	31
3.1. General aim.....	31
3.2. Specific aims.....	31
4. MATERIALS AND METHODOLOGY.....	32
4.1. Patient population.....	32
4.2. Inclusion and exclusion criteria for the study.....	33
4.3. Interventional MRI procedure and imaging details.....	33
4.4. HDR brachytherapy planning and treatment details.....	39
4.5. EBRT treatment details.....	40
4.6. Patient follow-up.....	40

4.7.	Statistical considerations.....	40
5.	RESULTS	41
5.1.	Patient and tumor characteristics.....	41
5.2.	Overview of the implant procedures.....	43
5.3.	MR imaging observations.....	43
5.4.	Work flow efficiencies.....	47
5.5.	Dosimetric outcomes.....	48
5.6.	PSA and clinical outcomes.....	51
5.7.	Toxicity and health-related quality of life.....	52
6.	DISCUSSION	54
7.	CONCLUSION	60
8.	FUTURE DIRECTIONS.....	61
9.	ABSTRACT IN CROATIAN.....	63
10.	ABSTRACT IN ENGLISH.....	64
11.	REFERENCES.....	66
12.	CURRICULUM VITAE.....	84

List of abbreviations

125-I	125-Iodine
192-Ir	192-Iridium
3D	3-dimensional
ADT	Androgen deprivation therapy
BED	Biologically equivalent dose
CNS	Central nervous system
CT	Computerised tomography
CTV	Clinical target volume
DCE	Dynamic contrast enhanced
DNA	Deoxyribonucleic acid
DWI	Diffusion-weighted imaging
EBRT	External beam radiotherapy
EORTC	European Organisation for Research and Treatment of Cancer
EPIC	Expanded Prostate Cancer Index Composite
GS	Gleason score
GTV	Gross tumor volume
HDR	High-dose-rate
IMRT	Intensity-modulated radiotherapy
IPSS	International Prostate Symptom Score
IRB	Institutional Review Board
IT	Information technology
LDR	Low-dose-rate
LQ	Linear-quadratic
MDR	Medium-dose-rate
mpMRI	Multiparametric Magnetic Resonance Imaging
MRC	Medical Research Council
MRI	Magnetic Resonance Imaging
MRSI	Magnetic Resonance Spectroscopic Imaging
MSKCC	Memorial Sloan Kettering Cancer Centre
NCCN	National Cancer Comprehensive Network
OAR	Organs-at-risk
PDR	Pulse-dose-rate
PIRADS	Prostate Imaging Reporting and Data System

PSA	Prostate-Specific Antigen
PTV	Planning target volume
RTOG	Radiation Therapy Oncology Group
TCD50	Tumor control dose 50%
TRUS	Transrectal ultrasound
TURP	Trans-urethral resection of the prostate
VMAT	Volumetric modulated arc therapy

1. INTRODUCTION AND BACKGROUND FOR THE PROPOSED RESEARCH

1.1. Epidemiology of prostate cancer

Prostate cancer (PCa) is the most common cancer among male population in Western world. Annually, there are more than 180.000 new cases of PCa in the United States, with more than 26.000 deaths from PCa (1). In Canada, although incidence and mortality rates are declining, PCa is the most common male malignancy, and third leading cause of cancer-related death, only after lung and colorectal cancer. In 2015, 24.000 Canadian men were diagnosed with PCa, and more than 4.000 died from the disease. Moreover, one in eight Canadian men will be diagnosed with PCa in their lifetime (2). In Croatia, epidemiological situation is similar. According to last available National Cancer Registry data for 2014, PCa is the second most common cancer in Croatian men, with more than 1.700 new cases recorded in 2014. In the same year, 750 men died from this malignancy, making PCa the third largest cause of cancer-related mortality in Croatia, after lung and colorectal cancer. PCa incidence in last few years is stable in Croatia, but the mortality is slowly increasing (3).

The wide-spread adoption of prostate-specific antigen (PSA) screening in US occurred in the 1990s resulted in increasing incidence and decreasing mortality rates from PCa (4). However, the dispute over role of PSA screening has been ongoing since two PSA-screening trials reported conflicting results: European Trial (5) revealed survival benefit associated with PSA-screening while US trial (6) found no survival difference between PSA screened and not screened men leading to US Preventive Services Task Force (USPSTF) recommendation discouraging PSA screening for asymptomatic men (7). This recommendation caused approximately 5-10% decline in PSA screening rates among US man older than 50 years, however, still large proportion of men continues to be screened, especially in age group of older than 75, despite having high-risk other-cause mortality where no PSA screening benefit was seen even in European trial (8).

Despite numerous limitation of PSA screening, such as high false-positivity rates and lack of specificity, PSA remains the cornerstone for early detection of PCa. Consequentially, over 80% of new PCa cases in US are diagnosed in early stage where the tumor is confined to the prostate, resulting in 5-year PCa-specific survival approaching 100% (9). However, the natural history of PCa is very variable, covering the entire spectrum from slowly progressing disease to aggressive, treatment-resistant disease, with rapid onset of metastasis and PCa-related death

underlying our inability to distinguish between indolent and aggressive disease based only on PSA measurement (10).

1.2. Risk stratification and management options in localized PCa

Localised PCa is stratified into low, intermediate and high risk categories based on classical factors, such as clinical T-stage, biopsy Gleason score and initial serum PSA, as these parameters predict for PSA-relapse, metastasis and prostate-cancer-specific mortality (11,12). Clinical Tumor-Node-Metastasis (TNM) staging system for prostate cancer according to American Joint Committee on Cancer (AJCC) is presented in **Table 1** (13).

These clinical factors are the most widely used and form the basis of National Comprehensive Cancer Network (NCCN) risk classification, the landmark staging system for PCa (14). NCCN criteria recently adopted new risk categories: very low risk and very high risk, acknowledging these clinical entities have distinctly different prognosis (15).

The utility of NCCN risk group classification has been externally validated by D'Amico et al. who demonstrated this risk classification system predicted time to PCa-specific mortality after primary surgery or radiotherapy (16). Contemporary NCCN risk classification for prostate cancer is presented in **Table 2**.

Table 1. Clinical TNM classification for prostate cancer (American Joint Committee on cancer, version 7)

Primary tumor (T)	
Tx	Primary tumor cannot be assessed
T0	No evidence of primary tumor
T1	Clinically inapparent tumor neither palpable nor visible by imaging
T1a	Tumor incidental histologic finding in 5% or less of tissue resected
T1b	Tumor incidental histologic finding in more than 5% of tissue resected
T1c	Tumor identified by needle biopsy (e.g. because of elevated PSA)
T2	Tumor confined within the prostate*

T2a	Tumor involves one-half of 1 lobe or less
T2b	Tumor involves more than one-half of 1 lobe but not both lobes
T2c	Tumor involves both lobes
T3	Tumor extends through prostatic capsule**
T3a	Extracapsular extension (unilateral or bilateral)
T3b	Tumor invading seminal vesicle(s)
T4	Tumor fixed or invades adjacent structures other than seminal vesicles (eg, bladder, levator muscles, and/or pelvic wall)
Regional lymph nodes (N)	
NX	Regional lymph nodes were not assessed
N0	No regional lymph node metastasis
N1	Metastasis in regional lymph node(s)
Distant metastasis (M)*	
M0	No distant metastasis
M1	Distant metastasis
M1a	Nonregional lymph nodes(s)
M1b	Bone(s)
M1c	Other site(s) with or without bone disease

*Tumor found in one of both lobes by the needle biopsy, but is not palpable or reliably visible by imaging, is classified as T1c.

**Invasion into the prostatic apex or into (but not beyond) the prostatic capsule, is not classified as T3, but as T2.

***When more than one site of metastasis is present, the most advanced category is used.

Table 2. NCCN risk classification (NCCN=National Comprehensive Cancer Network), modified from ref (14).

Very-low risk	Low risk	Intermediate risk	High risk	Very high-risk
T1c and GS \leq 6 and PSA <10 and fewer than 3 biopsy cores positive and \leq 50% cancer in each core	T1-T2a and GS 2–6 and PSA \leq 10 not very low-risk	T2b or T2c and/or GS 7 and/or PSA >10–20 not low-risk	T3a or PSA >20 or GS 8–10 not very high risk	T3b-4

In a current practice, majority of men with PSA-detected PCa ultimately undergo definitive management with local therapy – either radical prostatectomy or radiotherapy with or without androgen deprivation therapy. More precisely, surgical approach as primary treatment modality is increasingly utilised across patients in intermediate and high risk groups, while active surveillance as approach is rapidly gaining more acceptance and becoming standard in low risk group (17). This is especially true for patients with low risk prostate cancer with T1c disease, \leq 3 positive biopsy cores, PSA <10 ng/ml and Gleason score 6, who are considered as best candidates for active surveillance program according to recent guidelines (18). Patients with intermediate-risk, high-risk or aggressive, locally advanced prostate cancer have a number of options for primary local treatment, including radical prostatectomy with pelvic lymphadenectomy, dose escalated image guided radiotherapy and brachytherapy (either using low- or high-dose rate modality), with differential outcomes (19).

However, the optimal management of PCa remains controversial as a result of long natural history of disease, the diversity of available treatments and lack of high quality data guiding the treatment choice.

External beam radiotherapy (EBRT), along with surgery, constitutes cornerstone of the primary treatment modality for patients with localized PCa. EBRT implies use of ionizing radiation to

kill cancer. Specifically, high energy megavoltage X-rays generated in linear accelerator are being used to treat PCa. EBRT is more often used in patients with high(er) risk features and in those with locally advanced disease where is combined with androgen deprivation therapy.

1.3. Evolving role of radiotherapy technique and delivery for prostate cancer treatment

Numerous advances have occurred in the field of radiotherapy for prostate cancer in last 30 years. Adoption of information technology and engineering solutions in this field allowed fast development. New planning software, introduction of planning based on CT and MRI imaging gave rise to advent of 3D conformal radiotherapy, which made possible to escalate the dose to the prostate and simultaneously minimize the dose to the organs-at-risk (20).

Conventional radiotherapy fractionation for radical treatment of PCa before the era of dose escalation ranged between 66 Gy and 70 Gy, given in 2 Gy fractions. Treatment volumes were treated using four rectangular fields with margins around prostate of 1.5 cm (21,22). Technical abilities at that time precluded conformal shaping of the treatment beams. However, in late 1980s, technological advances in radiotherapy planning software and linac hardware allowed major breakthrough: 3D conformal radiotherapy where the beams were shaped according to individual patient anatomy and target volume. This treatment technique usually involves the utilization of 5-6 field arrangements with maximal shielding and allows dose escalation to the prostate beyond 70 Gy, with margins of 1 cm around prostate. With increased number of beams used, reduced margins as the consequence of improved precision and maximized shielding, the rectal and bladder dose were significantly reduced which gave rise to safe dose escalation to the prostate (23).

Next step in development of radiotherapy technique is advent of Intensity Modulated Radiotherapy (IMRT) in early 1990s which since then has been rapidly assimilated into regular clinical practice.

Briefly, IMRT is advanced form of conformal radiotherapy for delivering EBRT to highly conformed treatment volumes. In IMRT process each beam is being segmented into multiple beamlets, where each beamlet has individually controlled radiation intensity. This enables the high dose volume to be more appropriately shaped around the target volume further reducing the dose to normal tissue. Moreover, IMRT involves inverse planning, where dose constraints for critical organs and target doses along with hierarchy of organs-at-risk sparing are predefined

and the plan is produced and optimized to best match all input criteria. IMRT was made possible by the use of a multileaf collimator and advanced treatment planning calculation algorithms that optimize its position (20). Nowadays, majority of North American radiotherapy centers treating PCa use IMRT technique. This technique is currently recommended over 3D conformal radiotherapy for the radical treatment of localized PCa in which an escalated radiation dose (>70 Gy) is required (24). However, the hypothesis that IMRT technique would lead to better patient-reported outcomes (and better quality of life) as opposed to 3D conformal technique has never been tested in a randomized trial. On further note, analysis of dose-escalated arm of RTOG 0126 trial showed no difference in relevant patient-reported outcomes (bowel, bladder, sexual) between patients treated with IMRT when compared to those treated with 3D conformal technique (25).

Further work was done in the field of image-guidance technologies for precise delivery of daily radiation treatments. For this purpose intraprostatic fiducial markers use and on-board imaging using cone-beam CT or MRI allowed to monitor and correct for daily prostate motion and enhanced precision in modern radiotherapy that improved cure rates in prostate cancer while minimizing toxicity (26,27).

1.4. Radiotherapy dose considerations

First evidence of a dose-response above 60 Gy in localized PCa was obtained by Zelefsky who ascertained benefits of increasing radiotherapy dose in terms of PSA nadir and biochemical control. He prospectively increased the dose to the prostate from 64.8 Gy to 81 Gy and the patients with intermediate- and high risk PCa benefited the most from this dose escalation (28). Moving forward, in the same institution (MSKCC), with accruing more patients on dose escalated protocols, authors have observed improvement in local control, distant metastasis, and prostate cancer specific mortality (29).

Although optimal EBRT dose for treating PCa has not yet been defined, six large randomised trials of dose escalation in PCa have consistently showed that increase in the radiotherapy dose resulted in improved biochemical control, and in one trial metastasis-free survival and PCa-related survival. Simultaneously, there was also an increase in late toxicities observed. Summary of details and findings from dose escalation trials are presented in **Table 3**.

In a trial by Pollack *et al.* patients were randomized to 78 Gy or 70 Gy and better biochemical control and a diminished rate of distant metastasis and CaP deaths were found in higher dose arm. At detailed look, patients younger than 70 years with PSA of more than 10 ng/ml have benefited the most from dose escalation (30–33). Improvement in biochemical relapse-free survival ranging from 10%-25% was the common finding across all trials (34–39).

In the most recent report of RTOG 0126, the largest study addressing the benefit of dose escalation, where 1,500 patients with intermediate-risk CaP were randomised to 79.2 vs. 70.2 Gy, 7-year OS was similar between both cohorts (HR 0.98, 95%CI[0.79-1.21]) although in dose escalated arm were less metastatic events observed (40). In the dose escalated arm, only 3% of prostate cancer-specific mortality was observed underlying relevance of competing causes of death in dose escalation trials where the overall survival is expected endpoint. Careful patient selection is needed for dose escalation. Probably younger patients with high-risk disease are those most likely to experience benefits of treatment with higher radiation doses (33).

Table 3. Overview of radiotherapy dose-escalation trials for localized prostate cancer

Trial	N	Patients	RT dose levels	ADT	Median follow-up	Main finding (control group vs dose escalated group)	Toxicity (control group vs dose escalated group)	Reference
MRC RT01 (UK)	843	IR: 37% HR: 43%	64 Gy in 32 fractions vs 74 Gy in 37 fractions	All pts received neo-adjuvant ADT for 3-6 months	10 years	10-year BPFS 43% vs 55%, p=0.0003 10-year OS 71% for both groups (p=0.96)	5-year grade ≥2 late GU 8% vs 11% (p=0.056) grade ≥2 late GI 24% vs 33% (p=0.055)	Dearnaley 2007 (41) Dearnaley 2014 (38)
MDACC 93-002	301	IR: 46% HR: 34%	70 Gy in 35 fractions vs 78 Gy in 39 fractions	No	8.7 years	8-year FFBF 59% vs 78% (p=0.004) 8-year FFDM 95% vs 99%, p=0.059 8-year OS 78% vs 79%, p=0.315	Late GI grade ≥2 13% vs 26%, p=0.013 Late GU grade ≥2 8% vs 13%, p=NS	Pollack 2002 (31) Kuban 2008 (32)

PROG 95-09	393	LR:58% IR: 37% HR: 5%	70.2 GyE in 39 fractions vs 79.2 GyE in 44 fractions (proton boost)	No	8.9 years	HR 0.57 for local failure in dose-escalation group 10-year BFR 32.0% vs 17.4% (p=0.0001) 10-year OS 78.4% vs 83.4% (p=0.41)	Late grade ≥ 3 GU 2% Late grade ≥ 3 GI 1 % (both groups, p=NS)	Zietman 2010 (36)
Dutch trial (CKTO 6910)	664	IR: 27% HR: 55%	68 Gy in 34 fractions vs 78 Gy in 39 fractions	Yes, 22% of pts	9.2 years	BCFR 46% vs 52% (p=0.025) CFR 34% vs 37% (p=0.4) PCD 13% vs 13% (p=0.8) OS 31% vs 30% (p=0.9)	7-year late grade ≥ 2 GU 40% vs 41% (p=0.6) Late grade ≥ 2 GI 25 % vs 35% (p=0.04)	Heemsbergen 2014 (35) Al-Mamgani 2008 (34)
RTOG 0126	1532	70% had PSA < 10 ng/ml, 84% with GS 7, 57% had T1 disease	70.2 Gy in 39 fractions vs 79.2 Gy in 44 fraction	No	7 years	10-year OS 66% vs 67% (p=0.87) BFR 43% vs 26% (p<0.0001) LPR 8% vs 4% (p=0.0059) DMR 8% vs 5% (p=0.026) STR 21% vs 13.5% (p=0.0002)	Late grade ≥ 2 GU/GI 37% vs 45% (p=0.0012) Time to late grade ≥ 3 GI was higher for the 79.2Gy arm (p=0.035) but time to late grade ≥ 3 GU toxicity was not (p=0.14)	Michalski 2015 (40)
GETUG 06	306	HR: 29%	70 Gy in 35 fractions vs 80 Gy in 40 fractions	No	5 years	BRR 39% vs 28% (p=0.036)	Late grade ≥ 2 GU 10% vs 17.5% (p=0.046) Late grade ≥ 2 GI 14 % vs 19.5% (p=0.22)	Beckendorf 2011 (37)

ADT=androgen deprivation therapy, MRC=Medical Research Council, IR=intermediate-risk, HR=high-risk, BPFS=biochemical progression-free survival, OS=overall survival, GU=genitourinary, GI=gastrointestinal, MDACC=MD Anderson Cancer Centre, FFBF=freedom from biochemical failure, FFDM=freedom from distant metastasis, NS=not

significant, GyE=Grey Equivalent, HR=Hazard ratio, BFR=biochemical failure rate, BCFR=biochemical failure rate, CFR=clinical failure rate, PCD=prostate cancer death, PSA=Prostate-specific antigen, GS=Gleason score, LPR=local progression rate, DMR=distant metastasis rate, STR= salvage therapy rate, BRR=biochemical relapse rate

Meta-analysis of above referenced six dose-escalation trials that included more than 2800 patients revealed that each 1-Gy increase in radiotherapy dose reduce the risk of biochemical failure by 1.8%, where the theoretical dose of 90 Gy would theoretically yield almost 100% rate of biochemical control (42).

Similarly, Zaorsky et al. performed meta-analysis of 12 randomized controlled trials with 6884 patients that evaluated dose escalation or hypofractionation, using calculated biologically equivalent doses (BED) for each schedule ($\alpha/\beta=1.5$). He found that BED escalation resulted in improved biochemical control at up to 10 years, but no improvement in overall survival, distant metastasis and cancer-specific mortality was observed (43).

1.5. Interaction of radiotherapy dose escalation and androgen deprivation therapy

Androgen deprivation therapy (ADT) is often given in conjuncture with radiotherapy as this approach improves outcomes for intermediate and high risk PCa. ADT and radiotherapy have the synergistic effect meaning that this combination mimics dose-escalation effect. This practically translates into notion that lower dose radiotherapy treatment combined with ADT produces the similar outcomes as the high dose radiotherapy alone. This observation is confirmed with the results from several randomised trials of combination of ADT and radiotherapy which established level one evidence supporting this combination in high-risk prostate cancer (44–49). Having said, the optimal radiotherapy dose in the setting of combined modality treatment is still unknown. To illustrate this, in MRC RT01 trial which compared 64 Gy with 74 Gy both in combination with 6 months of ADT, patients with high-risk PCa had better biochemical control if treated on higher dose arm, although no effect on overall survival was observed (38). In EORTC 22991 study and the Quebec study both questions were addressed (radiotherapy dose and addition of ADT). EORTC 22991 study tested the effect of addition of 6 months of ADT to three different dose levels (70 Gy vs. 74 Gy vs. 78 Gy as per centre discretion), while Quebec study similarly tested 70 Gy vs 76 Gy \pm 6 months of ADT (50,51). Results of these important studies were similar: biochemical control was indeed

improved in ADT arm compared to radiotherapy alone arm, regardless of radiotherapy dose received.

Nowadays, it has become a contemporary standard in Europe to treat prostate with doses of at least 74 Gy (as per dose-escalated arm of MRC RT01 trial) when 2-Gy fractionation is used. However, in many US centres prescribed doses are even higher, ranging from 75.6 Gy (University of Michigan) to ultra-high doses of 86.4 Gy (Memorial Sloan Kettering Cancer Centre), both in 1.8-Gy fraction schedule. In Canada, most common standard EBRT fractionation is 78 Gy given in 39 fractions. Furthermore, overwhelming majority of high-risk patients and considerable portion of intermediate risk patients also receive additional ADT. However, late genitourinary and gastrointestinal side-effects limit our ability to safely escalate the dose as we have probably reached the limit of dose escalation in the range of >80 Gy. As current evidence points out, it is less likely to observe benefit of dose escalation beyond 74 Gy in the presence of ADT (50). Anyhow, contemporary series using doses above 74 Gy report long-term biochemical control rates in range 65%-90% depending on patient population.

1.6. Addition of androgen deprivation therapy to improve radiotherapy outcomes

Number of randomized studies investigated combination of androgen deprivation therapy and radiotherapy in PCa to improve patient clinical outcomes. Rationale for this combination came from seminal observation of Huggins and Hodges that prostate cancer cell heavily depend on the androgens (52). Biological basis of added efficacy of combination of ADT and radiation although not yet fully understood, implies several important aspects: a) tumor can be controlled with diminished radiotherapy dose in the presence of ADT (53); b) neoadjuvant ADT increased overall tumor cell kill in animal models and caused retardation in residual tumor growth (54); c) ADT has suppressive impact on tumor vascularisation (55). By normalizing tumor vascularisation, androgen deprivation is decreasing hypoxia (56), the common feature in prostate cancer associated with radiation resistance, aggressive phenotype and development of metastasis (57). On clinical level, neoadjuvant androgen deprivation sensitizes tumor to radiation, thereby improving radiotherapy local control and reduces the second wave of metastasis (58).

On systemic level, androgen deprivation therapy, by means of inhibition of DNA synthesis and cell proliferation, promoting apoptosis of cancer cells, may prevent the spread of micrometastatic disease (59).

Mainstay of combination of androgen deprivation therapy and radiotherapy is in the intermediate-, and high-risk disease. Using either neoadjuvant or adjuvant ADT, randomized phase III clinical trials have consistently shown that the combined-modality treatment with ADT and radiotherapy improves biochemical relapse-free, metastasis-free, and overall survival in high-risk and locally advanced disease compared with the use of either ADT or radiotherapy alone. Currently, the common standard is to give 6 months of androgen deprivation therapy in unfavourable-intermediate patients, and 2-3 years in high-risk disease. Even in the presence of EBRT dose escalation, ADT is necessary to optimize outcomes for unfavourable prostate cancer patients. In the study done by Zapatero et al., which included 355 patients with intermediate-risk and high-risk prostate cancer, who all received dose-escalated radiotherapy with a mean dose of 78 Gy, and were randomized to receive short-term (4 month duration) or long-term (28 month duration) ADT. With a median follow-up time of 63 months, patients treated with the long-term regimen demonstrated significantly higher 5-year biochemical progression-free survival (89.8% versus 81.3%, $p = 0.019$), higher rates of 5-year metastasis-free survival (93.6% versus 83.4%, $p = 0.009$) and overall survival (94.8% versus 86.1%, $p = 0.01$). The results of this trial underlay importance of ADT in patients receiving high-dose radiotherapy, which alone is not sufficient to prevent metastasis and increase the survival, as it fails to address the risk of primary occult or post-treatment secondary metastases.

Overview of clinical trials addressing combination of androgen deprivation therapy and radiotherapy are presented in **Table 4**.

Table 4. Overview of studies investigating combination EBRT and ADT to improve outcomes in localized prostate cancer.

Trial	Comparison	Results
RT±ADT		
RTOG 8610	65-70 Gy RT±	Improved local control
Pilepich et al. (60)	2 months neoadjuvant ADT	Reduction in disease progression and disease-specific mortality for patients

		treated with neoadjuvant ADT
EORTC 22863 Bolla et al. (61)	50 Gy RT to pelvis + 20 Gy RT to prostate and seminal vesicles ± adjuvant ADT for 3 years	Improved 10-year OS in combined treatment (58.1% vs 39.8%, HR 0.60, p = 0.0004) 10-year PCSM 30.4% and 10.3%, respectively (HR 0.38, p <0.0001)
DFCI 95096 D'Amico et al. (62)	70 Gy RT ± 6 months ADT	13% OS benefit at 7.6 years with combined modality compared with RT alone
RTOG 8531 Lawton et al. (63)	65–70 Gy RT ± adjuvant indefinitely ADT	Improved absolute survival rate with adjuvant ADT compared with RT alone (49% versus 39%, p = 0.002)
TROG 9601 Denham et al. (64)	66 Gy RT + 0, 3 or 6 months ADT	Improved disease-free survival with 3 months ADT (HR = 0.65, p = 0.0001), and with 6 months ADT (HR = 0.56, p <0.0001)
RTOG 9408 Jones et al. (49)	66.6 Gy RT ± 4 months ADT	Improved OS with combined modality treatment compared with RT alone (62% versus 57%, HR 1.17, p = 0.03)
EORTC 22991 Bolla et al. (50)	70/74/78 Gy RT ± 6 months ADT	Improved 7-year biochemical and clinical disease-free survival with

ADT relative to without
ADT

ADT+RT

MRC RT01	6 months of ADT + 64 Gy or 74 Gy	Improved 10-year biochemical progression-free survival in the dose-escalation group (53%) compared with the standard-dose group (43%) (HR 0.69, p=0.0003)
Dearnaley et al. (65)	RT	
EORTC 22961	70 Gy RT + 6 months ADT vs 70 Gy RT + 3 years ADT	Inferior 5-year survival with 6 months of ADT compared to 3 years of ADT (81% vs 85%)
Bolla et al. (66)		
RTOG 9202	65–70 Gy RT with 4 months of neoadjuvant and concurrent ADT ± additional 6 months ADT	Improved disease-free and distant metastasis-free survival in the long-term ADT group. For men with GS 8–10, long-term ADT had significantly better OS than short-term ADT.
Horwitz et al. (48)		
DART 01/05 GICOR	76 Gy RT with 4 months ADT or 76 Gy RT with 24 months ADT	All 5-year endpoints improved in longer ADT duration compared to shorter ADT duration (biochemical control 90% vs 81%; metastasis-free survival 94%
Zapatero et al. (67)		

		vs 83%; overall survival 95% vs 86%)
RTOG 9910 Pisansky et al. (68)	2 months vs 7 months of neoadjuvant ADT followed by 70.2 Gy to the prostate with 2 months of adjuvant ADT	10-year incidence of locoregional progression (6% vs 4%, p=0.07), distant metastasis (6% vs 6%, p=0.8), and PSA recurrence (27% vs 27%, p=0.77)

RT=radiotherapy, ADT=androgen deprivation therapy, RTOG=Radiation Therapy Oncology Group, EORTC=European Organisation for Research and Treatment of Cancer, HR=hazard ratio, PCSM=prostate cancer-specific mortality, DFCI=Dana Farber Cancer Institute, OS=overall survival, TROG= Trans Tasman Radiation Oncology Group, MRC=Medical Research Council, GICOR=Grupo de Investigación Clínica en Oncología Radioterápica.

1.7. General radiobiology consideration

Traditionally, EBRT is given in equal daily increments or fractions, five days a week to allow normal tissue to repair radiation injury and to allow tumours to re-oxygenate between the treatments. Re-oxygenation is known to be crucial for the efficacy of radiation-induced cancer cell kill as the hypoxic tumours are resistant to radiotherapy.

Radiation prescription can be either standard (1.8 or 2 Gy fraction size), hypofractionated (fraction size >2 Gy and given in smaller number of daily fractions) or hyperfractionated (fraction size <2 Gy and given more than once daily). Daily fraction of 2 Gy is the standard in the radiotherapy as it is believed that this fraction size offer the best balance between desired tumour kill and unwanted normal tissue injury for most cancers.

Generally, with increasing radiotherapy dose the number of surviving cancer cell is decreasing but instantly, the toxicity to surrounding tissues is also increasing. Linear-quadratic (LQ) model is widely used tool for quantitative prediction of dose and fractionation relationship in the radiotherapy (69). In LQ model, alpha/beta ratio is the measure of radiation fraction size sensitivity. More theoretically, alpha/beta ratio is the radiotherapy dose where linear and quadratic components of the cell kill are equal, as displayed on cell survival plot.

The alpha/beta ratio is used in the calculation of the biologically equivalent dose (BED), which is the measure of true biological dose delivered by a particular combination of dose per fraction

and total dose to a particular tissue characterized by specific alpha/beta ratio. The following equation puts into relation BED and alpha/beta ratio:

$$\text{BED} = nd * [1 + d / (a / b)]$$

Where n is the number of radiation fraction, d is the fraction size and a/b is the alpha/beta ratio. Accumulating evidence over past 15 years points out that PCa is less likely to behave like other cancers as regards to its response to radiation. Most cancers, as well as all rapidly dividing normal tissues (like intestine or oral mucosa), have an alpha/beta of approximately 10 Gy. Those tissues are also called acute reacting tissues as they pronounce acute reaction to radiation injury (typical example is stomatitis, colitis or dermatitis which occurs during radiation). On other hand, slowly dividing late reacting normal tissues (i.e. fibroblasts, muscles, blood vessels, rectum, kidneys, lung, CNS) have an alpha/beta ratio between 3 and 5 Gy (70). Such late responding tissues exhibit radiation injury several months to years after irradiation.

However, a number of studies and radiobiological models based on clinical data suggest that the alpha/beta ratio for prostate cancer is 0.9-1.5 Gy, which is surprisingly low (71–73). This implies that PCa cells are more sensitive to radiotherapy doses delivered in larger fraction size. Moreover, a low alpha/beta ratio for PCa means that hypofractionated radiotherapy would be more efficient in tumor kill than standard fractionated radiotherapy, and potentially will produce equivalent tumor control with lower total dose and shorter overall treatment time.

Furthermore, alpha/beta ratio of 1.5 for PCa is lower than 3-5 Gy what is estimated alpha/beta ratio for rectum and bladder, surrounding late responding tissues and main organs-at-risk in PCa radiotherapy. This translates to the assumption that increasing the dose per fraction would increase BED for the PCa more than the BED for the rectum and bladder, thus increasing the therapeutic ratio (74).

On the premises that low alpha/beta ratio render PCa more sensitive to larger fraction size and thus theoretically makes hypofractionated radiotherapy potentially more efficient compared to conventionally fractionated radiotherapy, several randomized trials comparing these two approaches were carried out. Trials were designed to test whether hypofractionated arm is either superior or “non-inferior” to conventional treatment arm. None of the studies so far (CHHiP, NRG RTOG 0415, Fox Chase Cancer Centre Study, Italian study, MD Anderson Cancer Centre study, Dutch HYPRO trial) found neither that hypofractionated treatment is superior to conventional dose-escalated treatment or has less late toxicities (65,75–77). As a result, it is still controversial what the optimal fractionation schedule for PCa is.

Overview of studies comparing hypofractionated radiotherapy and conventional radiotherapy for localized PCa is presented in **Table 5**.

Table 5. Overview of studies testing the hypofractionation hypothesis in prostate cancer

Trial	RT schedule	BED (Gy)			Outcome	Reference
		$\alpha/\beta=1.5$ (prostate cancer)	$\alpha/\beta=3$ (normal tissue)	$\alpha/\beta=10$ (tumor)		
Australian trial	64 Gy/32fr	149	107	77	7.5-year BRFS 34% vs 53% (p<0.05) 7.5-year OS 69% vs 71% (p=NS)	Yeoh 2011 (78)
	55 Gy/20fr	156	105	70		
Ontario (Canada)	66 Gy/33fr	154	110	79	5-year BCF 52.95% vs 59.95% 5-year OS 85% vs 87% (p=NS) 2-year PBR 53% vs 51% (p=NS)	Lukka 2005 (79)
	52.5 Gy/20fr	145	98	66		
CHHiP (CRUK/06/016)	60 Gy/20fr	180	120	78	5-year FFBF 90.6% vs 85.9% (p=0.003) vs 88.3%	Dearnaley 2016 (65)
	57 Gy/19fr	171	114	74		
	74 Gy/37fr	173	123	89		
NRG Oncology RTOG 0415	73.8 Gy/41fr	162	118	87	7-year DFS 75.6% vs 81.8% (p=NS) FFBF and OS not different	Lee 2016 (77)
	70 Gy/28fr	187	128	88		
Fox Chase Cancer Center	76 Gy/38fr	177	127	91	5-year BCDFR 21.4% vs 23.3% (p=0.7) PCD and OS not different	Pollack 2013 (80)
	70.2 Gy/26fr	197	133	89		
Italian	80 Gy/40fr	187	133	96	5-year BFFS 79% vs 85% (p=0.065) 5-year FFLF 91% vs 93% (p=0.33) 5-year FFDF 86% vs 90% (p=0.29) 5-year CSS 82% vs 92% (p=0.16) 5-year OS 92% vs 98% (p=0.13)	Arcangeli 2012 (81)
	62 Gy/20fr	190	126	81		

MDACC	72 Gy/30fr	187	130	89	5-year PSAFFS 96% (p=NS)	Kuban 2008 (32)
	75.6 Gy/42fr	166	121	89	5-year PSAFFS 92% (p=NS)	

Table legend: BED=biological equivalent dose, BRFS=biochemical relapse-free survival, OS=overall survival, BCF=biochemical/clinical failure, PBR=positive biopsy rate, CRUK=Cancer Research UK, FFBF=freedom from biochemical failure, GU=genitourinary, GI=gastrointestinal, DFS=disease-free survival, PCD=prostate cancer death, OS=overall survival, NS=not significant, BCDFR= biochemical and/or clinical disease failure, BFFS=biochemical failure-free survival, FFLF=freedom from local failure, FFDF=freedom from distant failure, CSS=cancer-specific survival, MDACC=MD Anderson Cancer Center, PSAFFS=PSA Failure-free survival.

1.8. Biological effects of radiation and radiobiology of brachytherapy

Main mechanisms how radiation kills cancer cells are atom ionization and creation of free radicals which induce chemical damages in target cell structures, primarily in the DNA. Effect on DNA (single-strand or double-strand break) provides the basis of biological effects associated with radiation. Cells are trying to repair DNA breaks using special repair enzymes machinery. If this machinery fails to repair DNA breaks, the cell is destined to die, usually through apoptosis or programmed cellular death.

Biological effects of radiotherapy are strongly dependent on the rate of dose delivery. In HDR brachytherapy, where the dose-rate is high, repair (repair of sublethal DNA damage between the radiotherapy fractions), repopulation (the increase in cell division – clonogenic cell survival after the radiation is delivered), and reoxygenation (increase in oxygenized and radiosensitive cell fraction of the tumor after the radiation is delivered) are the main biological factors determining treatment outcome. In HDR brachytherapy, repair, repopulation, and reoxygenation are less likely to happen as a consequence of short treatment time (i.e. big blast of radiation given only in few minutes) (82).

The biological effects of radiotherapy build upon several important factors which primarily include delivered dose, dose distribution, treated volume, dose rate, fractionation and treatment

duration (82). In brachytherapy, treated volumes are usually small compared to EBRT volumes, and characteristically, the dose distribution is very heterogeneous. In brachytherapy, as opposed to EBRT, treatment is delivered continuously (i.e. within several minutes in HDR brachytherapy) without gaps, allowing no repair, which can occur in EBRT during treatment gaps.

Based on different dose rates, brachytherapy can be divided into several categories, as described in ICRU report 38 (83). *Low Dose Rate (LDR)* brachytherapy covers spectrum between 0.4 and 2 Gy/h, and this kind of radiation is delivered using conventional manual or automatic afterloading techniques. Permanent radioactive implants with very low dose rate (i.e. 125-I permanent seed prostate brachytherapy) which deliver very high dose (145 Gy) over the course of several months fall under this category.

Medium Dose Rate (MDR) brachytherapy is positioned between 2 Gy/h and 12 Gy/h, while high dose rate (HDR) brachytherapy has dose rate of ≥ 12 Gy/h employing high activity sources, requiring delivery by using automatic afterloading systems only.

1.9. Brachytherapy treatment options (LDR and HDR)

Brachytherapy is old radiotherapy technique where the radioactive source is introduced into vicinity of the tumor or into the tumor itself and has tradition over 100 years (84). In case of PCa, radiation is targeted directly at the prostate through radiation source that is either implanted (permanent seed brachytherapy or low-dose-rate-LDR) or temporarily placed within the prostate (high-dose-rate brachytherapy or HDR). Brachytherapy actually has preceded EBRT as latter was developed much later due to considerable technology requirements. Brachytherapy is known to be the most conformal radiotherapy technique for PCa because of rapid dose fall off outside of the prostate, by the virtue of inverse-square law. In the work done by Dr. Georg, HDR and LDR brachytherapy were dosimetrically compared with the most advanced radiotherapy techniques: volumetric modulated arc therapy (VMAT), intensity modulated proton therapy (IMPT) and scanned carbon-ion therapy (as most advanced modalities of particle therapies), in a terms of radiation doses to rectum and bladder wall. The lowest doses to the rectum and bladder wall were associated with HDR brachytherapy in this planning study (85).

Brachytherapy allows safe dose escalation (>140 Gy) as the dose to the rectum and bladder are kept minimal. Furthermore, there are no uncertainties related to prostate movement, as the implanted sources move with the prostate. Even the most contemporary EBRT techniques such as IMRT or volumetric arc therapy (VMAT) fail to match superb conformality associated with HDR brachytherapy as significant volume of the rectum still receive substantial dose in EBRT plans (**Figure 1**). As a result of tight dose conformity, in HDR brachytherapy less radiation is received by rectum and bladder, thus reducing the incidence of urinary, sexual and bowel side-effects compared to surgery or EBRT (86) and minimizing the risk of secondary malignancies (87). In terms of health economics, brachytherapy is favourable as treatment delivery time is shorter compared to EBRT and set-up and maintenance cost are considerably lower compared to contemporary EBRT delivery (88).

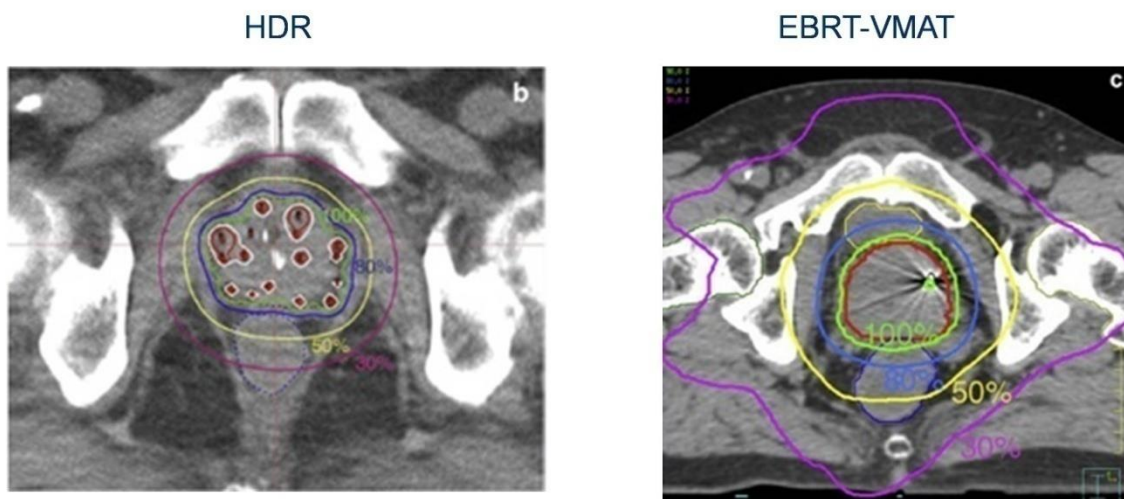


Fig. 1. Isodose distribution of high-dose-rate (HDR) (b) and external beam radiotherapy (EBRT) delivered using volumetric modulated arc therapy (VMAT) (c). HDR implant delivers much higher dose within the prostate with fewer doses to surrounding tissue. Even when the most contemporary EBRT technique (VMAT) is being used, significant high dose volumes cover surrounding tissues (so called wash-out dose). Please note 50% isodose encompassing almost all rectum. Reproduced from ref. (89), courtesy by Dr. Morton.

Both LDR and HDR represent appealing brachytherapy options with proven track record accumulated over 15 years of clinical experience. We now have two randomised trials (UK trial and Canadian British Columbia Cancer Agency trial) showing improved biochemical

relapse-free survival for patients receiving combination of brachytherapy and EBRT compared to EBRT alone (90,91). In UK trial led by Hoskin, EBRT was hypofractionated (55 Gy in 20 fractions in EBRT alone arm and 35.75 Gy in 13 fractions in the brachytherapy boost arm), and boost was given as HDR implant of 2 fractions of 8.5 Gy. Five, seven, and 10-years recurrence-free survival for the boost arm was 75%, 66%, and 46%, respectively as opposed to 61%, 48%, and 39%, respectively in EBRT alone arm. In BCCA trial EBRT dose was 78 Gy in EBRT alone arm and 46 Gy in the brachytherapy boost arm. Boost was given as 125-I LDR implant with 115 Gy of minimal peripheral dose. Five, seven, and nine-year biochemical progression-free survival for the LDR boost arm vs EBRT alone arm was 89% vs 84%, 86% vs 75%, and 83% vs 62%, respectively. It is possible that with extended follow-up an improvement in PCa-related mortality will emerge. Both of these trials set the benchmark for future studies and provide level one evidence supporting the use of brachytherapy boost for optimizing cure rates for localized prostate cancer.

There is uniform consensus nowadays that treatment with brachytherapy, alone or combined with EBRT, results in improved disease control compared to EBRT alone.

When LDR and HDR are compared, several key points need to be made. The disadvantages of LDR brachytherapy are following: possible seed migration, permanent nature of deposition of radioactive sources in the prostate, and protracted overall treatment time (it takes approximately two months to deliver full dose using 125-I seeds due to slow radioactive decay). As per basic radiobiology concept, radiation treatment is more effective if it is delivered in shorter treatment time thus avoiding repopulation of tumor cells and recovery from sublethal damage (70). HDR on contrary has the edge here. Using advanced technology now available in the routine practice, it is possible to automatically deploy and retract HDR brachytherapy source (192-Ir) along the specified catheter path. Remote after-loading system controls the source which travels along the catheter(s) and dwells in specified positions in order to deliver prescribed radiotherapy dose. Inverse dose optimisation planning is used to produce radiotherapy plan which in terms of conformality and prostate coverage regularly supersede EBRT or LDR dose distribution. Furthermore, the possibility of the seed migration is minimal as the source is located in the plastic hollow catheter that is inserted into prostate. In HDR dose optimization is done after catheter placement, therefore it allows more consistent target coverage with live dose sculpting compared to permanent seed implants. This finally leads to improved dose conformity, and lower doses to urethra and rectum typical for HDR brachytherapy (92).

Furthermore, related to HDR, there is no radiation exposure for staff and one HDR source can serve multiple patients requiring HDR brachytherapy either intracavitary or interstitial (gynaecological, prostate, head and neck, lung, etc.) leading to improved cost-effectiveness. Using HDR it is also possible to cover microscopical disease outside of prostate in case of high-risk disease while low-energy LDR cannot cover areas distant to prostate capsule, which is inherent limitation of low-energy beta decay of ¹²⁵I.

On other hand, HDR brachytherapy is not devoid of limitations. Potential for catheter displacement and consequential impaired dosimetry is significant, especially if the patient is being transferred from implantation phase to planning phase (in case of CT planning) and between planning and treatment delivery (93). If the patients are moved, consequential displacement of catheters can easily occur. Displacement within few millimetres would lead to deterioration in dosimetry emphasizing critical importance of catheter position verification. Finally, HDR dosimetry is not depended on prostate volume changes that occur over the course of time compared to LDR dosimetry where swelling of the prostate after implantation significantly affects quality of the implant (94).

HDR brachytherapy is well established treatment option in PCa, however the mainstay of HDR today is boost to EBRT where the 5-years biochemical control rates for men with low-risk, intermediate-risk, and high-risk PCa are in range >85%, 69-97%, and 63-80%, respectively (95–97). As a result of the benefits of delivering highly conformal dose-escalated radiation, HDR brachytherapy has been recognized and routinely recommended, either alone or in combination with EBRT, for the treatment of PCa by major professional bodies (American Brachytherapy Society (ABS), Groupe Européen de Curithérapie (GEC), and European Society for Radiotherapy and Oncology (ESTRO) (98,99).

1.10. Rationale for combining HDR brachytherapy and EBRT

There are several reasons behind the use of HDR brachytherapy in combination with EBRT. Firstly, external beam dose escalation above 70-76 Gy is necessary to optimize probability of cancer control. Secondly, HDR allows unparalleled target dose conformity and sparing of adjacent organs-at-risk. Thirdly, postulated low α/β ratio for prostate cancer provide radiobiological basis for delivering larger doses per fraction (by means of HDR or hypofractionation). Fourthly, abundance of mature clinical data support the use of this combination (100).

As we previously discussed, further dose escalation by EBRT is limited by increased rectal toxicity, despite advances in modern EBRT techniques (101). On other side, hypofractionated EBRT has been investigated as the alternative method of radiotherapy dose escalation by increasing BED. However, results of clinical trials so far are not conclusive and this issue is matter of current debate, underlying uncertainty of this approach (80).

As previously said, HDR brachytherapy is usually combined with either conventionally fractionated or hypofractionated course of EBRT. In the case of hypofractionated EBRT, advantages of both radiotherapy components are being exploited. As a backbone, EBRT provide basic dose escalation. It allows intraprostatic dose escalation (increasing BED) and escalation of the dose in the vicinity of the prostate to cover eventual extracapsular extension and seminal vesicle invasion, which are not within the therapeutic range of HDR brachytherapy. Furthermore, it allows entire pelvis and pelvic lymph nodes to be treated (i.e. for high-risk patients). Lastly, in the case of eventual substandard HDR implant with poor dosimetry, supplemental EBRT can compensate for that.

Body of evidence supporting the use of HDR brachytherapy boost is impressive, and include numerous single-centre studies with total of 5000 patients treated with median follow-up of up to 10 years (100). However, there is wide variation in dose and fractionation used. Average biochemical disease-free survival in these studies is steadily high: 95%, 91%, and 82%, for low-, intermediate-, and high risk patients, respectively. HDR treatment is generally well tolerated, with rare late Grade 3 rectal toxicity. Most common side-effects are genitourinary (dominantly late strictures); with late Grade 3 toxicity rates being between 1% and 14%. Overview of clinical results (biochemical recurrence-free survival and toxicity) of contemporary series of patients treated with HDR boost supplemental to EBRT is presented in **Table 6**.

Table 6. Overview of results of major modern series of HDR brachytherapy boost combined with EBRT with biochemical disease-free survival by risk grouping and late Grade 3 urinary (GU) and gastrointestinal (GI) toxicity. Modified from ref. (100), courtesy by dr. Morton.

Author (ref)	N	Median follow-up (months)	Late grade 3 bDFS by risk group (%)					Dose/fraction (EBRT+HDR) (Gy)
			toxicity (%)		bDFS (%)			
			G U	GI	Lo w	Intermedia te	Hig h	
Agoston (102)	100	62	14	2		84	82	60/30+10/1
Aluwini (103)	264	75	4	1		97		45/25+18/3
Bachand (104)	153	44				96		44/22+18/2-20/2
Cury (105)	121	63	2	2		91		50/20+10/1
Deutsch (106)	160	53			100	98	93	50.4/28+21/3
Galalae (107)	122	117	5	3	88	71	72	50/25+18-30* Gy/2
Ghadjar (108)	64	61	14	0		100	91	50/25+21/3
Kaprelian (109)	64	105	1	0		84	80	45/25+18/3
	101	43				94	82	45/25+19/2
Khor (110)	344	61	2	0		84	74	46/23+19.5/3
Kotecha (111)	229	61	5	0.4	95	90	57	50.4/28+16.5-22.5/3
Lilleby (112)	275	44				100	98.8	50/25+20/2
Marina (113)	282	96				91		46/23+19-23/2

Martinez- Monge (114)	200	44	5	2			85	54/27+19/4
Morton (115)	60	72	4	0		98		45/25+20/2
	123	45	1	0		95		37.5/15+15/1
Neviani (116)	455	48	8	1	92	88	85	45/25+16.5/3-21/3
Pellizon (117)	209	64			92	90	89	45/25+20/2
Phan (118)	309	59	4	0.3	98	90	78	36/18-50.4/28+15/3- 26/4
Pistis (119)	114	32					97	60/30+10/1
Prada (120)	313	68	2	0	100	88	79- 91	46/23+23/2
Savdie (121)	90	95					80	45/25+16.5/3
Whalley (122)	101	56	2	0		95	66	46/23+19.5/3-17/2
Zwahlen (123)	196	66	7	0		83		46/23+20/4-18/3

* 30 Gy to peripheral zone, 18 Gy to anterior prostate.

To supplement discussed clinical results, several clinical scenarios of radiotherapy treatment options for PCa are presented in **Table 7**. Please note the combination of course of EBRT and single fraction HDR boost yield the highest BED (biologically equivalent dose) while EBRT alone has the lowest BED. Owing to low α/β (1.5 Gy) for prostate cancer these BEDs are much higher than BEDs for organs-at-risk ($\alpha/\beta=3$) illustrating improved therapeutic ratio for combination therapy (EBRT+HDR).

High BED associated with combination of HDR brachytherapy and hypofractionated EBRT is key reason of excellent clinical results of this increasingly popular combination.

Table 7. Examples of BED (biologically equivalent dose) calculations for several clinical scenarios with different radiotherapy modalities and schedules with α/β of 1.5 (prostate cancer) and 3 (rectum).

Dose (Gy)/fractionation	BED/Gy ($\alpha/\beta=1.5$)	BED/Gy ($\alpha/\beta=3$)
EBRT+HDR vs HDR mono vs EBRT mono		
46/23# (EBRT) + 15/1# (HDR)	272	167
45/25# (EBRT) + 15/1# (HDR)	264	162
37.5/15# (EBRT) + 20/2# (HDR)	253	156
37.5/15# (EBRT) +15/1# (HDR)	265	158
19/1# (HDR monotherapy)	260	139
15/1# (HDR monotherapy)	165	90
84.6/47# (EBRT monotherapy)	186	135
78/39# (EBRT monotherapy)	182	130

#=fractions

1.11. Image guidance modalities for HDR brachytherapy

Transrectal ultrasound (TRUS) has been the standard imaging guidance modality for HDR brachytherapy. Since introduction of TRUS in the 1980s by Holm to guide implantation of radioactive seeds into prostate and enable planning (124), TRUS has become increasingly popular and probably most widely accepted intraoperative image guidance tool (**Fig. 2**). TRUS undoubtedly has some relative advantages compared with CT and MRI as eventual competing image guidance tools. TRUS enables fair visualization of the prostate and urethra facilitating accurate standard arrangement implantation (125,126). Probably the biggest TRUS asset is possibility to guide needle insertion in the real-time. Intraoperative TRUS-based prostate HDR brachytherapy allows for prostate implantation, imaging, planning, and treatment to be performed in a single session with the patient in the same position throughout the procedure. This minimizes the possibility of catheter migration and subsequent inaccurate treatment delivery, a serious cause of concern in every brachytherapy method (127). However, TRUS-

based HDR brachytherapy is not without difficulties and limitations. Ultrasound images are limited in their ability to objectively delineate needles paths; cannot differentiate tumor lesion within the prostate or unequivocally detect extraprostatic disease extension, and are susceptible to acoustic shadows (128). For this reason, catheters are often implanted at the prostate boundary to aid segmentation of the prostate in a degraded final TRUS image.

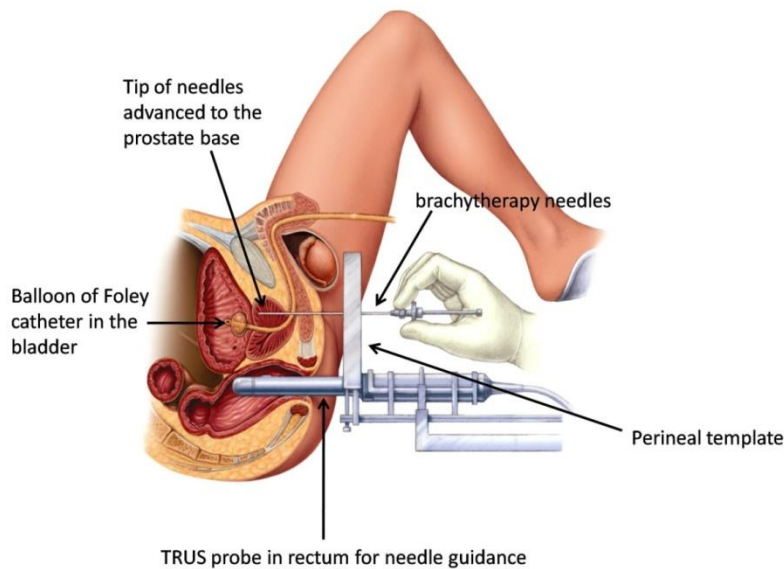


Fig. 2. Schematic illustration of transperineal insertion of brachytherapy needles using transrectal ultrasound (TRUS) guidance.

In TRUS-based procedure, live TRUS images are acquired with inserted catheters and transferred to the planning system. Prostate, urethra, bladder, and rectum are contoured, catheters identified and the treatment plan developed based on anatomy-based inverse planning. This form of planning optimize the dwell time at each position along the catheters to sculpt the dose to achieve target coverage while limiting dose to organ-at-risk (urethra, rectum) (89). The main advantage of TRUS-based planning is that the entire HDR brachytherapy procedure of catheter insertion, planning and treatment delivery can be carried out in a shielded brachytherapy suite without movement of patient. TRUS-based HDR brachytherapy is outpatient 1.5-2 hour's procedure during which the patient is under the general anaesthesia. Furthermore, TRUS-based planning is practical, convenient, and inexpensive.

Other potential image guidance modalities include computerized tomography (CT) and magnetic resonance imaging (MRI). Each of these modalities has their own advantages and limitations (**Table 8**).

Table 8. Relative advantages and disadvantages for each imaging guidance modality for prostate HDR brachytherapy

	CT	MRI	TRUS
Catheter identification	++	++	-
Catheter tip localization	++	-	-
Prostate delineation	-	++	+
Critical structure delineation	-	++	+
Patient comfort	-	--	++
Cost, efficiency and convenience	-	--	++

CT=computerised tomography, MRI=magnetic resonance imaging, TRUS=trans-rectal ultrasound

CT has the advantage of being geometrically accurate and is so far the gold-standard imaging modality for identifying the needle/catheters locations and its tip (129). However, it has poor capacity for prostate delineation and often requires the patient to be moved from the procedure room to the imaging suite and then back to the treatment vault. These multiple transfers can result in displacement of needles and significant changes in implant geometry (93,130,131). Moreover, CT is resource- intensive requiring an available CT scanner and logistic support which increase cost of the procedure.

1.12. Role of MRI in the prostate cancer management and HDR brachytherapy image guidance

Magnetic resonance imaging (MRI) is being increasingly used in genitourinary imaging because of its superior soft tissue contrast compared to CT and TRUS. MRI offers unprecedented high quality image resolution and is increasingly used in the management of PCa. MRI is the most accurate imaging to assess local extent of PCa, depict zonal prostate

anatomy and to detect seminal vesicle invasion and/or extracapsular extension (132–134). Recently updated guidelines provided frame for reporting multiparametric MRI (mpMRI) findings through standardization of imaging protocols and brought more agreement in this evolving area (135–138).

Briefly, prostate cancer has specific features on mpMRI supplemented by endorectal coil for optimal signal strength and image resolution and quality. On T2-weighted sequences, most PCa can be visualized as hypointense (darker) areas within the high-signal-intensity (gray) normal peripheral zone which is primary site of cancer in 70% of all PCa. On diffusion weighted imaging, PCa displays restricted (lower) diffusion compared with benign prostate tissue, with lower signal intensity on the ADC (apparent diffusion coefficient) map and hyperintense signal on high b-values compared to surrounding prostate tissue. On dynamic contrast-enhanced imaging, PCa typically shows early enhancement associated with abnormal tumor angiogenesis (139).

MRI has been used both for EBRT and low-dose-rate brachytherapy treatment planning with the potential to allow better sparing of organs-at-risk, including erectile tissues (140,141). Moreover, MRI-delineated prostate target volumes proved to be up to 30% smaller than CT-delineated volumes, resulting in higher treatment accuracy and avoidance of unnecessary radiation exposure of surrounding organs. In several studies that included patients treated either with EBRT or with combined EBRT and brachytherapy, MRI features proved to be predictive for biochemical relapse outcomes (142,143). There is also a notion to use MRI as a tool for adaptive external beam radiotherapy with the goal to develop and clinically employ MR-Linac as the next generation of image-guided radiotherapy (144).

Multiparametric MRI has the added benefit as it combines anatomical information provided by T2-weighted MR images with functional imaging sequences, such as diffusion-weighted imaging (DWI), dynamic contrast-enhanced imaging (DCE), and magnetic resonance spectroscopic imaging (MRSI). These sequences combined provide extensive information on status of active disease within the prostate and beyond the gland (145,146).

As previously elaborated, in HDR brachytherapy, where image guidance is an indispensable for accurate catheter placement, MRI additionally offers excellent soft tissue resolution, ideal brachytherapy catheter visualization, and better image quality compared to (TRUS). This asset of MRI may lead to better brachytherapy plan optimization, target coverage, intraprostatic tumor dose escalation, and sparing of organs-at-risk (rectum and urethra) that could potentially turn in the long run in better long-term cancer control and less treatment-related side-effects.

Moreover, it allows HDR treatment planning and delivery to be based on 3D MRI images, and allows precise identification of brachytherapy catheters relative to the target volumes and adjacent normal tissues.

However, the main limitations of MRI in the context of HDR brachytherapy remain the high cost and scarce availability as it presents many logistical and resource issues.

Comparison of prostate imaging modalities, TRUS, CT and MRI is presented in **Fig. 3**. Please note superior soft tissue contrast in MR image, resulting in clear visibility of the prostate, intraprostatic tumor lesion and surrounding anatomy as compared to TRUS and CT.

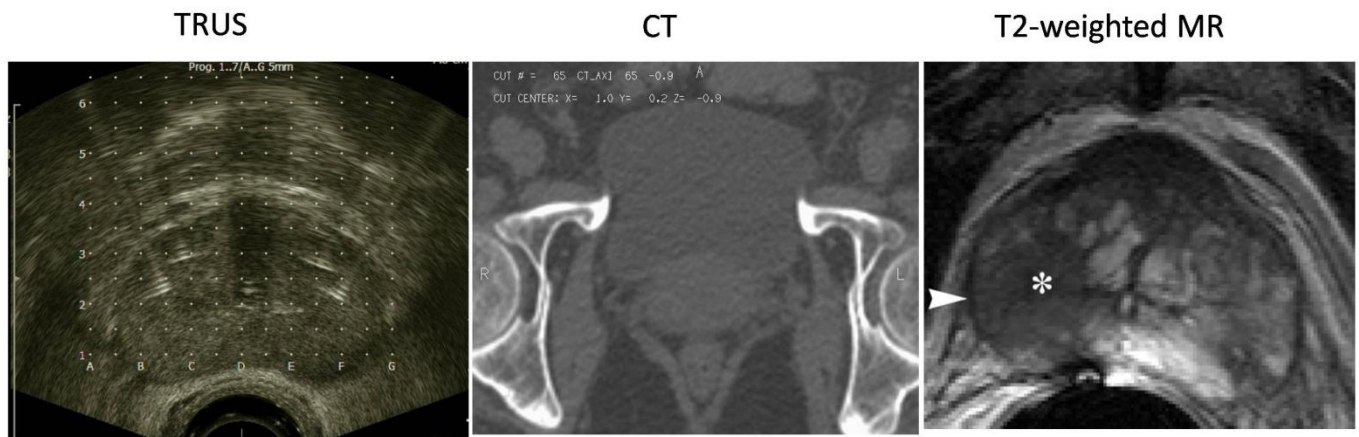


Fig. 3. Comparison of the TRUS, CT, and MRI in prostate imaging. On the far right panel, depicting MRI, asterisk indicates cancerous lesion in the prostate and arrowhead indicates clearly distinguishable and defined prostate capsule (from ref. (147)).

1.13. Rationale for proposed research

First experience with MRI-guided brachytherapy was gained by Dr. Cynthia Ménard at National Institutes of Health (Bethesda, MD) in early 2000s using standard, 1.5T “closed-bore” scanner (**Fig. 4**). This was pilot study on 5 patients which were treated with EBRT and received HDR boost before and after the course of EBRT. T2-weighted MRI images were used and achieved dosimetry was very favorable. This early study showed that HDR brachytherapy in a standard 1.5T MRI scanner is feasible (148).

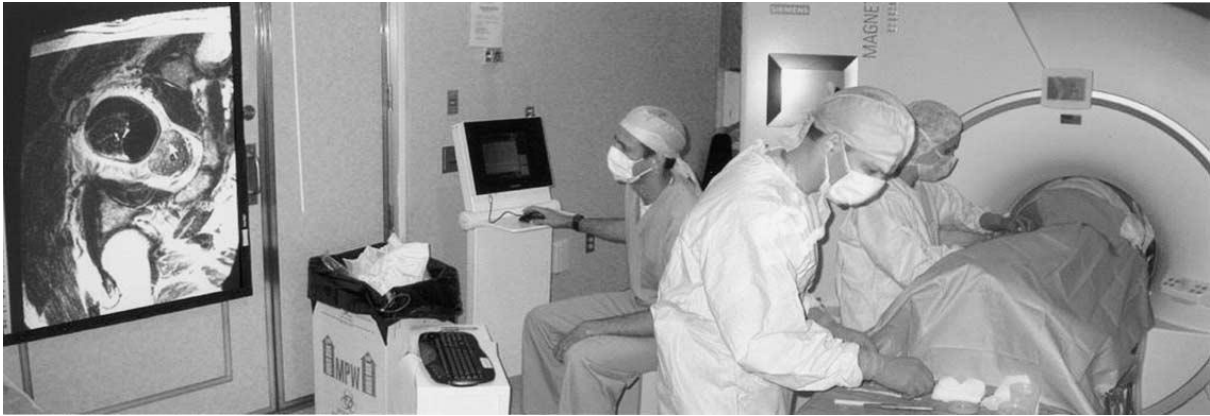

Fig. 4. Magnetic resonance imaging (MRI) scanner room setup with patient in decubitus position during the first MRI-guided HDR brachytherapy for prostate cancer, reproduced from ref. (148), courtesy of dr. Ménard.

Later on, the interests of group led by Dr. Ménard switched to MRI-guided, tumor targeted HDR brachytherapy as salvage treatment for locally recurrent prostate cancer. In this program, multi-parametric MRI integrated with guided biopsies proved to be crucial tool to achieve geometric precision and effective salvage treatment (149).

In this study a modified transperineal stereotactic template-based biopsy technique was used in the online MR imaging environment with endorectal coil in place (150).

Based on this encouraging experience, Dr. Ménard as principal investigator (PI) in MRI-guided HDR brachytherapy program at Princess Margaret Cancer Centre, decided to prospectively include patients planned for standard-care HDR brachytherapy whole gland boost to EBRT on MRI-guided program. Furthermore, the eventual benefit of MRI guidance has never been clinically proven in this setting.

Phase II prospective trial was designed with objective to assess feasibility, safety, and value of a technique using interventional MRI for online guidance of catheter insertion and treatment planning in patients receiving HDR brachytherapy boost for intermediate- and high-risk localized prostate cancer. The novelty of this concept lays in the exclusive use of MRI both for brachytherapy catheter image guidance and treatment planning. This study builds on early work on this method using MRI scanner prototype and procedure workflow developed by Dr. Ménard, as previously described (150). Furthermore, this work continues on our pilot study which enrolled patients receiving HDR whole gland boost where we observed this unique technique based on interventional MRI provide additional data that allow more accurate target

coverage, organ-at-risk sparing and plan optimization (151). Encouraged by these initial results, in this study we enrolled total of 40 patients in Princess Margaret Cancer Centre in Toronto that were treated together by study P.I. (Dr. Ménard) and PhD candidate (Dr. Murgic). This study has been IRB approved (University Health Network Research Ethics Board No 09-0026-C). Aim of this study was to assess feasibility, safety and value of MRI image guidance in the context of whole gland HDR boost.

2. HYPOTHESIS

Interventional MRI-guidance as novel technique for high-dose-rate (HDR) brachytherapy for prostate cancer is feasible and safe.

3. AIMS AND PURPOSE OF THE RESEARCH

3.1. GENERAL AIM:

To assess feasibility, safety, and value of a technique which utilize interventional MRI for online guidance of catheter insertion and treatment planning in patients receiving HDR brachytherapy boost for intermediate- and high-risk localized prostate cancer.

3.2. SPECIFIC AIMS:

To determine:

1. the frequency, nature, and clinical impact of gross tumor visualization through the course of the HDR brachytherapy procedure-related workflow efficiencies (primarily refers to procedure time)
2. dose metrics of implant quality:
 - a) PTV V100 (planning target volume receiving 100% of prescribed dose)
 - b) PTV D90 (dose received by the 90% of planning target volume)
 - c) urethra V105 (volume of urethra receiving 105% of the prescribed dose)
 - d) rectum V75 (volume of the rectum receiving 75% of the prescribed dose)
 - e) bladder V75 (volume of the bladder receiving 75% of the prescribed dose))

4. acute and late toxicity and health related quality of life
5. patient's clinical oncologic outcomes
(biochemical disease-free survival, metastasis-free survival)

4. MATERIALS AND METHODOLOGY

The research was done at the Radiation Medicine Program in Princess Margaret Cancer Centre of the University Health Network and University of Toronto Department of Radiation Oncology, Toronto, Canada, under mentorship of professor Cynthia Ménard, MD, FRCPC as part of the project “MRI-Guided HDR Brachytherapy for Prostate Cancer” (REB#09-0026-C). Study was funded by Ontario Consortium for Adaptive Interventions in Radiation Oncology, Ontario Research Fund (project number RE-04-026) matched to an industry grant provided by Hologic Inc.

4.1. Patient population

Total of forty (40) patients were enrolled on prospective, single cohort, non-randomized, open-labeled, interventional, IRB-approved, single-center trial (NCT registration number 00913939) recruiting patients to receive whole gland prostate HDR brachytherapy boost under MRI guidance, combined with supplemental EBRT. This trial was based in Princess Margaret Cancer Centre, University Health Network Department of Radiation Oncology University of Toronto, Canada, where all the patients were treated. This study enrolled patients with prostate cancer who were receiving HDR brachytherapy boost in conjunction to EBRT. Study intervention consisted in the use of MRI for image guidance for brachytherapy procedure, and this is basic concept of this protocol. PI of the trial was Dr. Cynthia Ménard, the pioneer in use of MRI imaging in HDR brachytherapy for prostate cancer and the PhD candidate Dr. Jure Murgic, who worked closely with Dr. Ménard as brachytherapy fellow in Princess Margaret Cancer Centre, analyzed patient and treatment-related data acquired throughout this trial.

4.2. Inclusion and exclusion criteria for the study

Eligible patients for this trial were those with intermediate- or high-risk prostate cancer according to NCCN criteria (stage T2/3 or PSA>10 or Gleason score>6), with no evidence of nodal or distant metastasis. Trial intervention is basically associated only with regards to MRI guidance for HDR brachytherapy boost. Other elements of patient care, such as doze of HDR boost, fractionation of EBRT, use of hormonal therapy, etc. were delivered as per standard of care. Hormone therapy was allowed and prescribed at the discretion of treating oncologist. Exclusion criteria for trial were: contraindications to MRI (patients weighing more than 136 kg, or having pacemakers, cerebral aneurysm clips, shrapnel injury or implantable electronic devices not compatible with MRI), bleeding diathesis, contraindications to endorectal coil or to anesthesia, International Prostate Symptom Score (IPSS)>18, large post-transurethral resection of the prostate (TURP) defect, TURP within the past 6 months, prostate gland volume >80 cubic centimeters, and history of bowel inflammatory disease. Patients had to be staged clinically, primarily using digital rectal examination and TRUS. Bone scan and CT scan of abdomen and pelvis were performed in high-risk patients to exclude the presence of distant metastasis.

4.3. Interventional MRI procedure and MR imaging details

Patients were immobilized in a frog-leg position on an interventional MRI tabletop (Sentinel Endocoil Array System by Invivo), **Figure 5**.

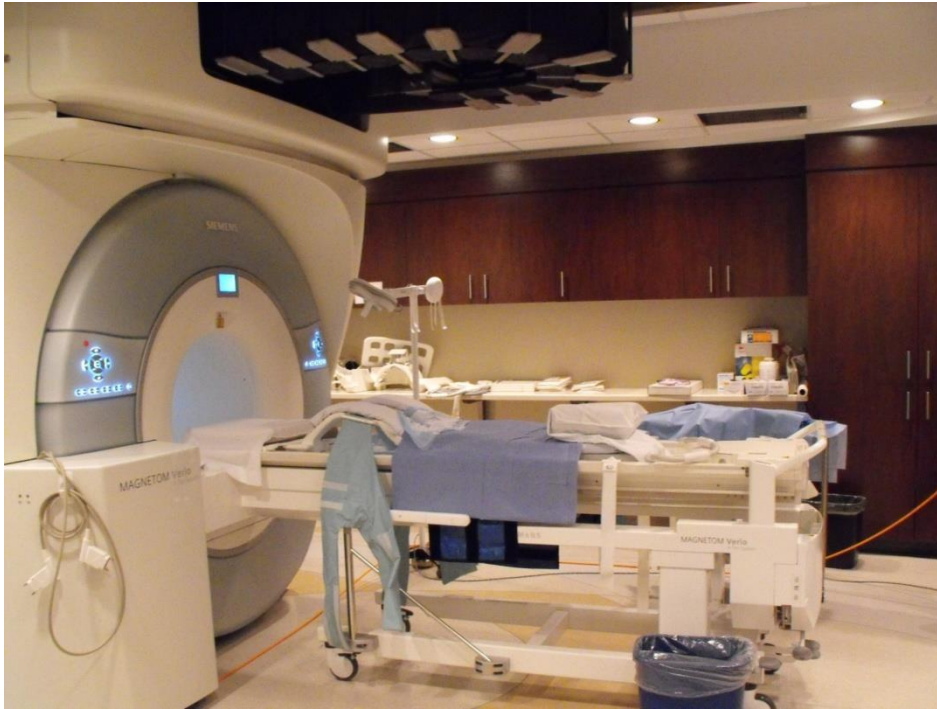

Figure 5. 3T-MRI scanner, interventional MRI tabletop with movable MRI table which can be undocked for patient transportation purposes.

The procedure was performed under intravenous anesthesia with propofol (Diprivan, Astra Zeneca, London, UK) and laryngeal mask airway. A Foley catheter was inserted in the bladder for the duration of the procedure, and the Foley balloon inflated with diluted X-ray contrast. A sterile MRI-compatible perineal template was affixed perpendicular to the endorectal coil and positioned and immobilized against the perineum (**Fig. 6**). Whole team working in the procedure is depicted on **Fig. 7**.

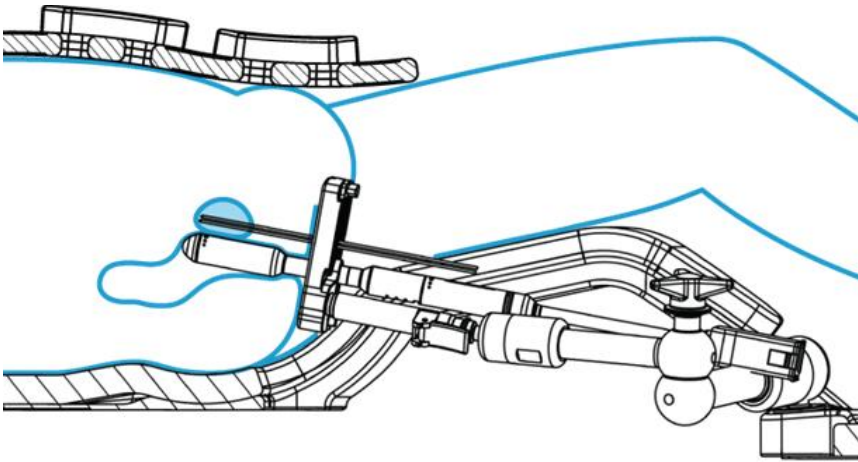
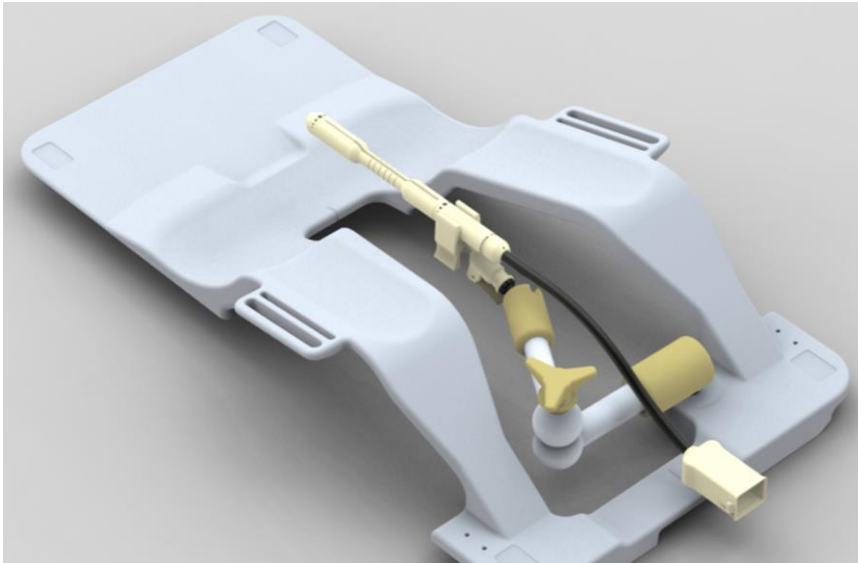


Figure 6. MRI setup system consisting of body coil, four-channel phased-array pelvic surface coil, and endorectal coil which is affixed with the perineal template.

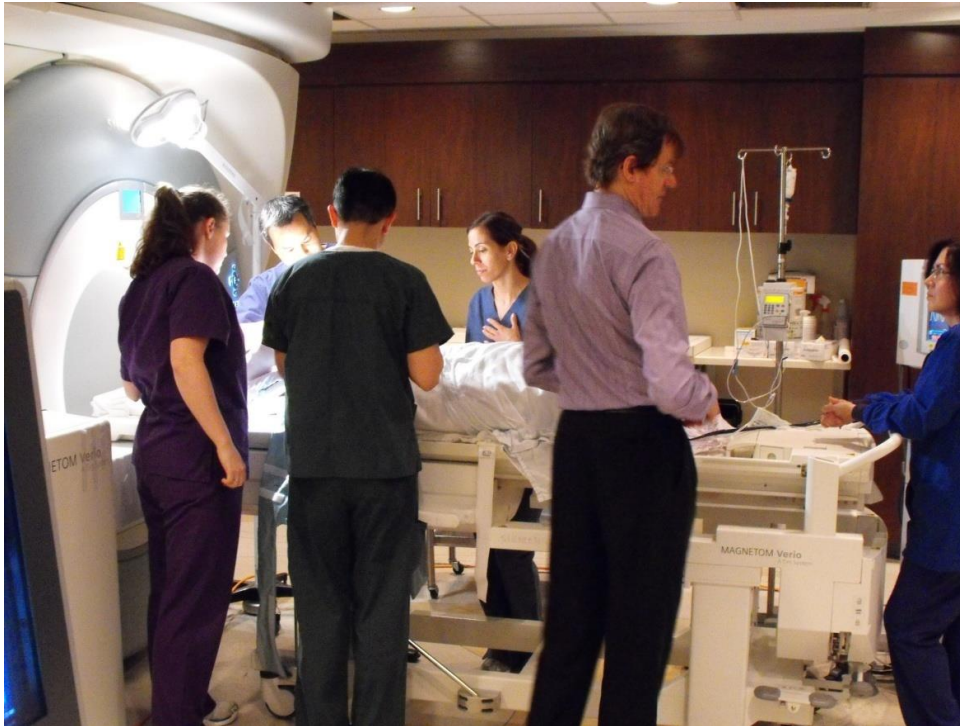

Fig. 7. Team required for smooth running of the procedure (radiation oncologist with brachytherapy expertise, brachytherapy technician, MRI technician, anesthetist, and anesthetist technician). Note the patient position – frog leg, with legs first to the scanner. MRI table is undockable and transferable. All equipment is MRI safe.

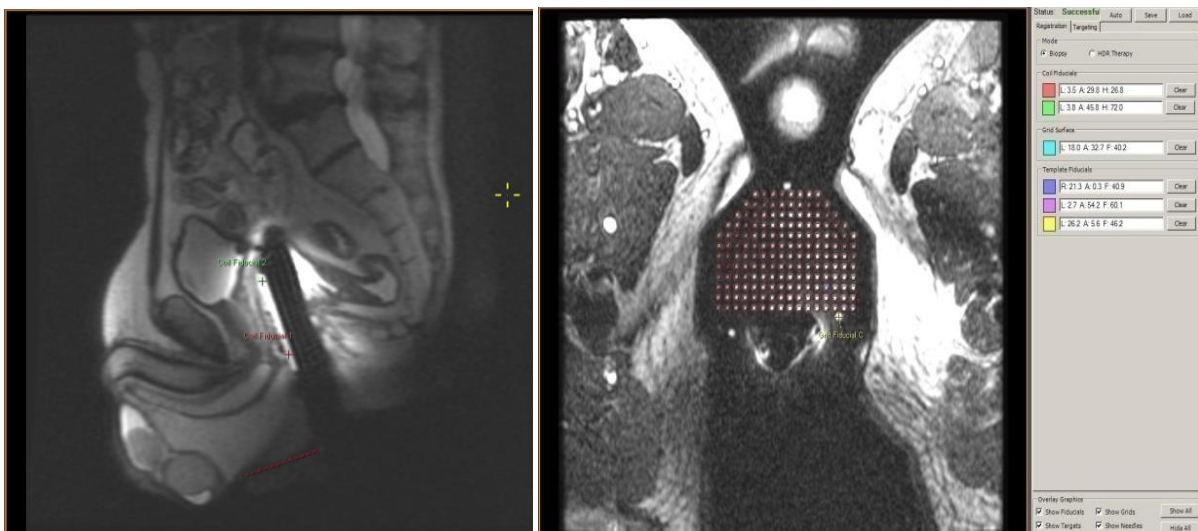


Fig. 8. MRI scout images for the purpose of endorectal coil and perineal template registration allowing stereotactic navigation of the needles. Each hole in the template has unique coordinates, allowing needle tracking.

MR images were acquired for device registration (**Fig. 8**) (steady-state free precession imaging of the template system) and depiction of anatomic details facilitated with body coil used for excitation and a four-channel phased-array surface coil placed anterior to the pelvis combined with the endorectal coil for signal reception. Procedures were initially performed using a 1.5 T MRI scanner (Signa; GE Medical Systems, Milwaukee, WI) but subsequently migrated to using a 3T MRI scanner (IMRIS, Minnetonka, MN), **Figure 5**. T2-weighted Turbo Spin Echo (TSE) axial images (Field-of-view (FOV) 140 mm, TR (Repetition Time) 2500 ms, TE (Echo Time) 100 ms, matrix 320 x 320, voxel resolution 0.4 x 0.4 x 2.0 mm) and diffusion-weighted imaging-DWI (FOV 180 mm, TR 6000 ms, TE 83 ms, matrix 128 x 128, voxel resolution 1.4 x 1.4 x 3.0 mm, b (value) = 0; 100; 600; 1000) were acquired immediately before catheter insertion.

Dynamic contrast-enhanced MRI (DCE-MRI) was not used as only PIRADS 4-5 lesions were considered (137,138). PIRADS 4 and 5 lesions represent high and very high probability of clinically significant prostate cancer being present in the prostate, based on the combinational analysis of the findings from T2w, DWI, and DCE-MRI sequences (152).

Catheter placement was guided using template-based stereotactic navigation software (Aegis, Hologic, MA) which was supported by passive fiducial registration.

This process was aided by MRI technician using displayed MR images in the procedure room, allowing the operator real-time feedback of the catheter position (**Fig. 9**).

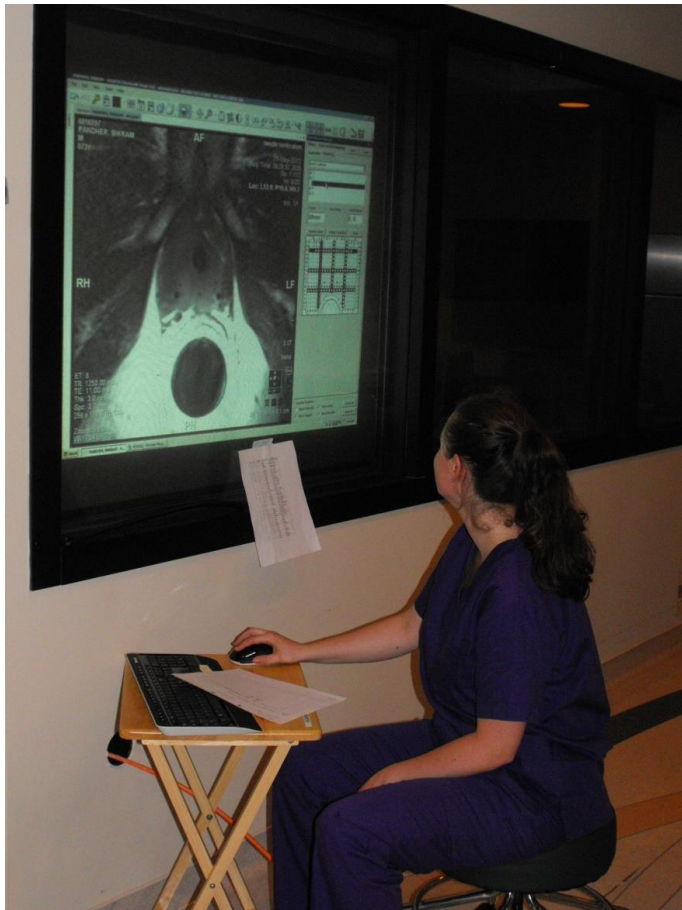


Fig. 9. Catheter navigation using navigation software with in-room control of MRI using remote commands.

The prostate was implanted via a peripheral loading technique with additional effort to insert catheters directly into any visualized tumor and within the prostate boundary.

Technically, catheters were placed by withdrawing the scanner table, inserting a coaxial MR-compatible needle (In Vivo, Germany), aided by stereotactic navigation software, to the depth at the level of prostate base. Afterwards, the MRI table was advanced back to the isocentre and fast-spin-echo images were acquired to verify needle positions. Upon achieving satisfactory needle position with the tip at the prostate base, a brachytherapy catheter (ProGuide, Nucletron) was inserted through the coaxial needle which was then removed. Several needles were inserted between each image verification sequence.

Once catheters (ProGuide, Elekta, Stockholm, Sweden) were satisfactorily positioned, they were locked into position using template screws. Following this, high-resolution two-

dimensional T2-weighted images (FOV 140 mm, TR 4000 ms, TE 100 ms, matrix 320 x 320, voxel resolution 0.4 x 0.4 x 2.0 mm, three averages) were acquired for the treatment planning. These images were exported to the treatment planning software (Oncentra Masterplan, Elekta, Crawley, United Kingdom).

After the acquisition of the treatment planning images, the obturators were replaced inside the brachytherapy catheters, and the patient was transferred into HDR treatment vault by undocking the MR table from the scanner without the need to move the patient.

Clinical target volume included the prostate and a 2-mm margin beyond gross visible disease (GTV) on MRI, excluding urethra, rectum, and bladder. Planning target volume (PTV) included the clinical target volume plus 1 mm superior/inferior to account for the uncertainties introduced with slice thickness volume averaging. Urethra, bladder, and rectum were delineated as solid organs-at-risk (OARs).

4.4. HDR brachytherapy planning and treatment details

HDR brachytherapy dose prescription migrated from a standard-care approach of two fractions (10 Gy each) in two separated implants, to a single fraction implant (15 Gy) during the course of the study. This change was reflection of adoption of Canadian regimen of hypofractionated EBRT (37.5 Gy in 15 fractions with 2.5 Gy dose per fraction) combined with single HDR implant of 15 Gy once this approach was shown to be effective and has favorable quality-of-life profile (115,153,154).

A brachytherapy plan was generated using inverse planning to meet dose objectives based on Radiation Therapy Oncology Group (RTOG) and Toronto (Odette Cancer Centre at Sunnybrook Health Sciences Centre) experience (98)(Dr. Morton Personal Communication: $V_{100} \geq 95\%$ of prostate volume $V_{90} \geq 98\%$ of prostate volume, Urethral $D_{10} \leq 117\%$ (17.5 Gy), Rectal $V_{80} < 0.5$ cc).

Our dose objectives included PTV $V_{100} > 95\%$, PTV $V_{150} < 50\%$, rectal $V_{75} < 1$ cc and $V_{80} < 0.5$ cc, urethral $V_{125} < 0.5$ cc, bladder $V_{75} < 1$ cc. Additional effort was made to encompass GTV (gross tumor volume) by prescription dose (priority objective).

Lateral C-arm X-rays were acquired immediately before delivery of treatment, and off-set correction was applied if catheter displacement greater than 3 mm was identified. Treatment was delivered using multichannel MicroSelectron afterloader (Elekta). Patients were discharged home the same day after successful voiding.

4.5. EBRT treatment details

One week following HDR brachytherapy implant, patients started EBRT portion of the treatment. EBRT dose for intermediate risk patients was 37.5 Gy delivered in 15 fractions to the prostate alone and 1 cm of proximal seminal vesicles and 46 Gy in 23 fractions to the pelvis for high-risk patients. EBRT was delivered using a 4-field conformal technique or IMRT. The PTV (Planning Target Volume) was a uniform 1 cm expansion beyond the CTV (Clinical Target Volume). PTV received $\geq 95\%$ of the prescription dose, prescribed at the isocentre.

4.6. Patient follow-up

Patients were followed prospectively at 1, 3, and 6 months and 1, 2, 3, and 5 years after brachytherapy.

Toxicity was evaluated using the Common Terminology Criteria for Adverse Events version 4.0 (155). Early toxicity was defined if occurred within 3 months after the procedure, whereas late toxicity was defined if occurred more than 3 months after the procedure. Health-related quality of life was assessed by the Expanded Prostate Cancer Index Composite (EPIC) questionnaire, with urinary symptoms level assessed by International Prostate Symptom Score (IPSS). Both EPIC and IPSS questionnaires are recognized, validated and widely acknowledged instruments for assessing symptom burden and quality-of-life of patients with PCa receiving curative treatment (156,157).

4.7. Statistical considerations

This was an exploratory feasibility study which aimed to provide estimates of variance in the data. Numerical indices and values were presented either with average and standard deviation or median and range. Kolmogorov-Smirnov test was used to assess normality of the data distribution. Change in overall procedure duration over course of time was assessed by linear regression.

Prostate-specific antigen (PSA) relapse-free survival is measured from the date of the brachytherapy implant to the date of confirmed biochemical failure, which is assessed using Phoenix definition (nadir+2) (158). Patients without biochemical failure were censored at the date of last follow up. PSA relapse-free survival and metastasis-free survival were assessed using Kaplan-Meier method. Change in IPSS and EPIC summary scores were assessed in

comparison with baseline scores using Wilcoxon-signed rank test with Bonferroni correction for multiple testing.

Statistical analysis was performed using MedCalc for Windows, version 13.0.6.0 (licensed MedCalc Software, Ostend, Belgium), with *p*-value less than 0.05 considered statistically significant.

5. RESULTS

5.1. Patient and tumor characteristics

Patient's and tumor characteristics are presented in **Table 9**.

Table 9. Patient's and tumor characteristics

N of patients	40
Median age (range)	68 (49-78)
Median PSA (range)	13.1 (3.1-117.0)
Gleason score, N (%)	
7	25 (62.5)
8	6 (15.0)
9	9 (22.5)
Clinical stage*, N (%)	
cT1c	8 (20.0)
cT2a	8 (20.0)
cT2b	3 (7.5)
cT2c	7 (17.5)
cT3a	9 (22.5)
cT3b	5 (12.5)
Risk category, N (%)	
Intermediate-risk	11 (27.5)

High-risk	29 (72.5)
Androgen deprivation therapy, N (%)	25 (62.5)
Median IPSS (range)	4 (0-18)
Median prostate volume in cc (range)	34 (17-81)
Median MRI max. tumor diameter in cm (range)	1.2 (0.5-3.8)
Tumor findings on MRI, N (%)	
No tumor	8 (20.0)
One tumor	23 (57.5)
Two tumors	7 (17.5)
Three tumors	1 (2.5)
Four tumors	1 (2.5)
Dominant tumor location (%)	
Anterior zone	9 (28.1)
Posterior zone	23 (71.9)

PSA=prostate-specific antigen, IPSS=International Prostate Symptom Score

*staging included imaging data both from staging MRI (when available) and interventional MRI

Between January 2010 and March 2015, 40 patients were enrolled to receive whole gland prostate HDR brachytherapy combined with EBRT under MRI guidance on a prospective clinical trial approved by institutional research ethics board (<https://clinicaltrials.gov/ct2/show/NCT00913939>). Median patient's age was 68, and median PSA was 13.1. Majority of patients had Gleason 7 PCa and had initial T1-T2 stage. Majority of patients had high-risk disease and 25 patients (62.5%) received androgen deprivation therapy. Median IPSS was low (4), indicating low lower urinary tract symptom burden among the included patients. Median prostate volume was of average size (34 cc). Median of patient's follow-up of was 30 months (range, 6-61 months).

5.2. Overview of the implant procedures

In total, 62 implants were performed. The first 22 patients had two separate HDR implants of 10 Gy each, and the subsequent 17 patients had a single 15 Gy implant. One patient received a single 10 Gy implant. He developed acute urinary retention immediately afterwards and was not eligible for the second implant. One patient received a first implant with a dose of 10 Gy, and the second implant with 11.5 Gy for gross seminal vesicle involvement found on interventional MRI. This case was very illustrative, has a teaching point on relevance of interventional MRI scans, and is presented on **Figure 10**.

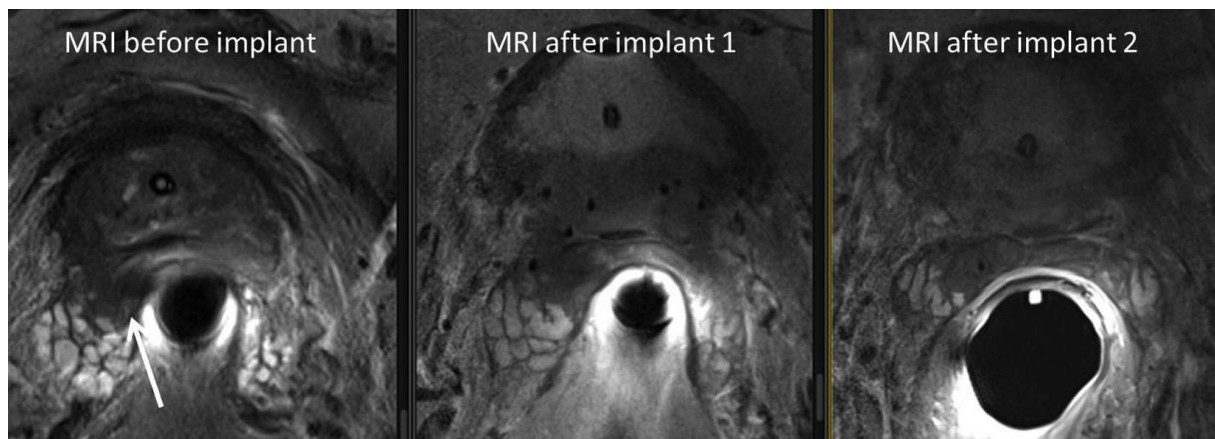

Figure 10. Example of the case with seminal vesicle invasion (up-staged to T3b disease based on interventional MRI scans). Patient presented with intermediate-risk prostate cancer (clinical T2a, Gleason score 3+4, iPSA 12). Right seminal vesicle involvement was revealed at the time of HDR brachytherapy. On left panel is T2-weighted pre-implant MRI with arrow indicating gross seminal vesicle involvement; middle panel is showing catheters implanted anteriorly to the tumor. Right panel indicate successful implantation of the catheter (black signal void) in the center of the tumor.

5.3. MR imaging observation

At the moment of the HDR brachytherapy, interventional MRI scans upstaged 14 patients (35%) who were found to have a higher stage of disease than initially perceived on clinical

staging (based on digitorectal examination and TRUS) – **Table 10.** Six patients from this group required insertion of brachytherapy catheters outside of the prostate boundary to address gross extracapsular disease extension (N=2) or seminal vesicle invasion (N=4). Case example illustrating implantation of locally advanced disease with extracapsular extension is depicted on **Figure 11.**

Table 10. Change in patient’s clinical stage based on MRI scans at the time of brachytherapy. Note 14 patients were restaged and found to have a higher stage of disease. In 6 patients, this change in stage impacted management (change in brachytherapy volumes and/or addition of hormonal therapy based on the migration to high-risk group).

		Staging based on interventional MRI						Total
		cT1c	cT2a	cT2b	cT2c	cT3a	cT3b	
Staging based on DRE and/or TRUS*	cT1c	8	4	/	3	/	3	18
	cT2a	/	3	/	/	2	/	5
	cT2b	/	/	2	1	/	/	3
	cT2c	/	/	/	/	/	1	1
	cT3a	/	/	/	/	1	/	1
	cT3b	/	/	/	/	/	1	1
	Total	8	7	2	4	3	5	29

DRE=digitorectal examination; TRUS=transrectal ultrasound.

*11 patients who had baseline MRI staging scans were excluded from this analysis.

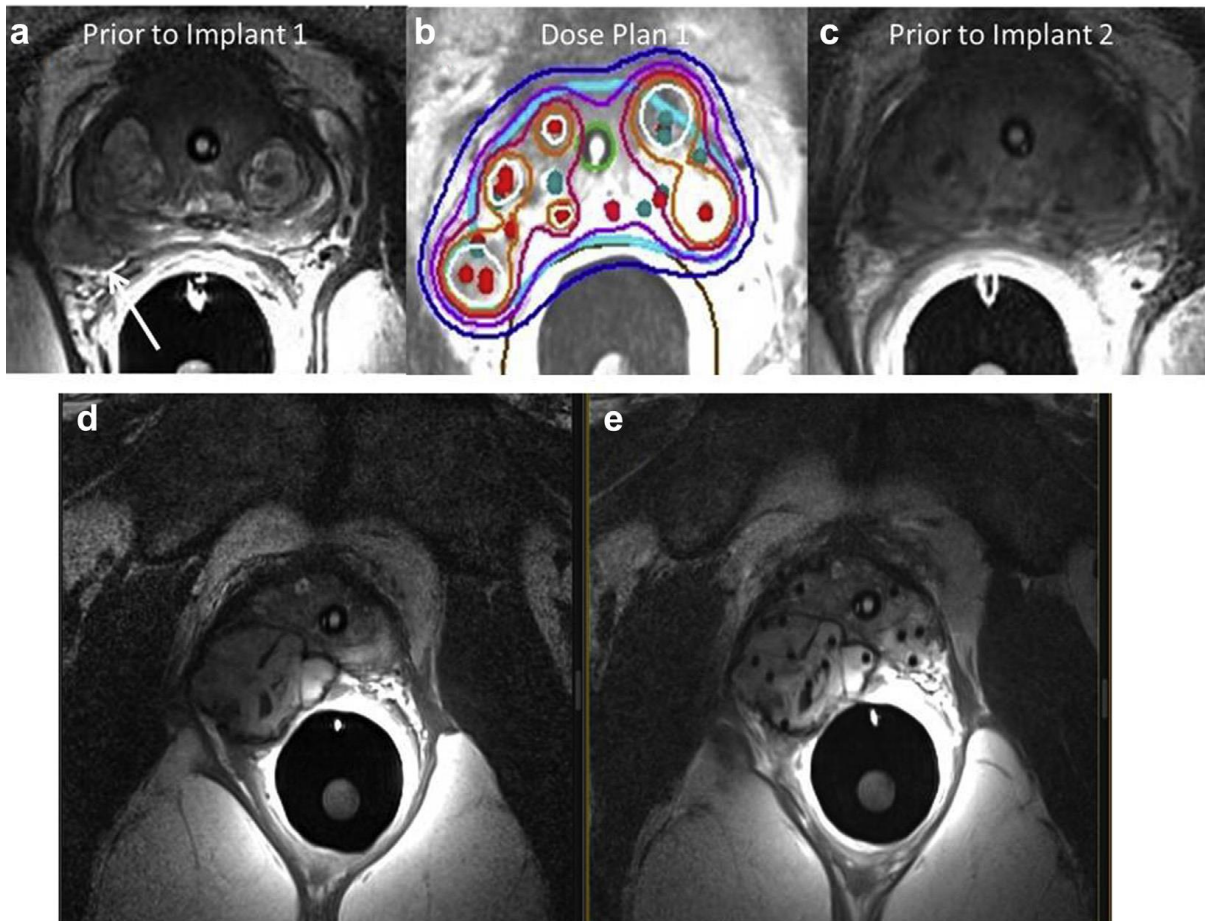


Figure 11. Example of extracapsular extension (MRI T3a). Patient initially presented with high-risk prostate cancer with known T3a disease before the brachytherapy. Left panel (a): T2-w MRI before first implant showing gross extracapsular extension (arrow). Middle (b): implant with isodose plan (blue line=75% isodose, pink line=100% isodose). Note complete coverage of extraprostatic disease with 100% isodose). Right (c): MRI before the second implant. Note significant reduction in extraprostatic disease in response to treatment. This enabled reduced rectal dose exposure. Second row (d): Example of large locally advanced prostate cancer. (e): MRI guidance allowed implantation of the large right-sided extraprostatic tumor abutting the rectum.

Most patients (N=32, 80%) were found to have at least one tumor (scored using PIRADS version 2.0 as 4 or 5) (138). Median maximum tumor diameter was 1.2 cm (range 0.5-2.9 cm). Nine patients had gross multifocal disease with more than one tumor identified. Tumors were located anteriorly in 11 patients (28%).

MRI before catheter insertion was essential for tumor staging and GTV delineation. It also assisted in segmentation of the prostate apex for treatment planning, whereas MRI acquired after catheter insertion provided highly resolved anatomic boundaries and clear catheter signatures for accurate treatment planning. See example in **Fig. 12**.

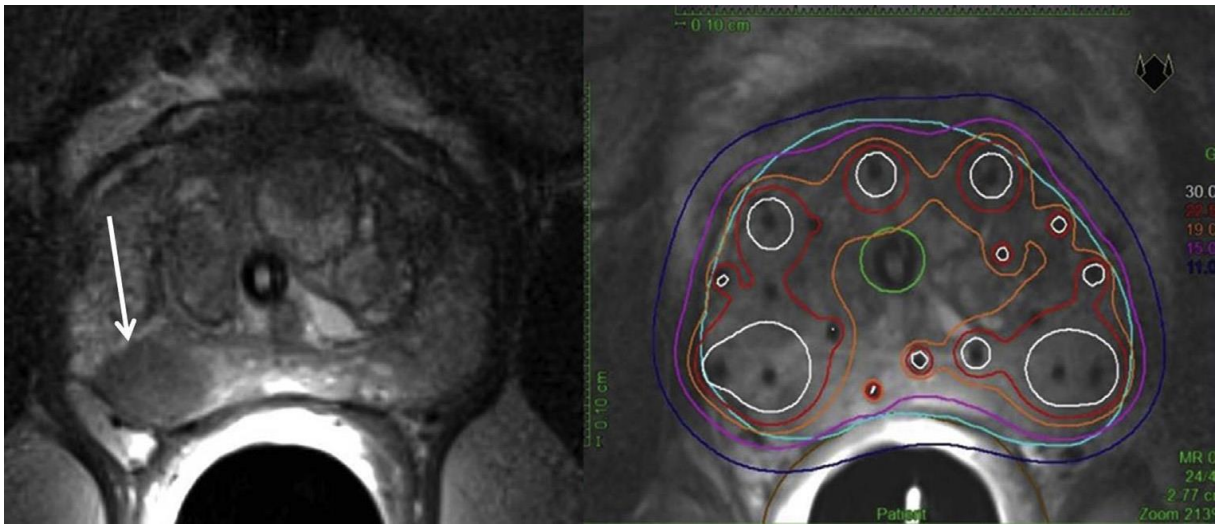


Fig. 12. Provided is typical example of posterior tumor. On the left: tumor in right peripheral zone (arrow) abutting the rectum. Right: subsequent HDR brachytherapy dose plan. Prescription isodose-100% (pink) covers tumor whereas prostate gland coverage is compromised contralaterally in non-tumor bearing regions to reduce rectal dose. This is illustration of dose painting and sculpting enabled by the MRI-targeted HDR brachytherapy. Note that tumor is not clearly visualized after catheter placement due to bleeding and edema.

Blurring of the prostate apex boundary after catheter insertion which was related to pelvic hematoma caused by needle trauma, was observed in all cases and is illustrated in **Fig. 13**.

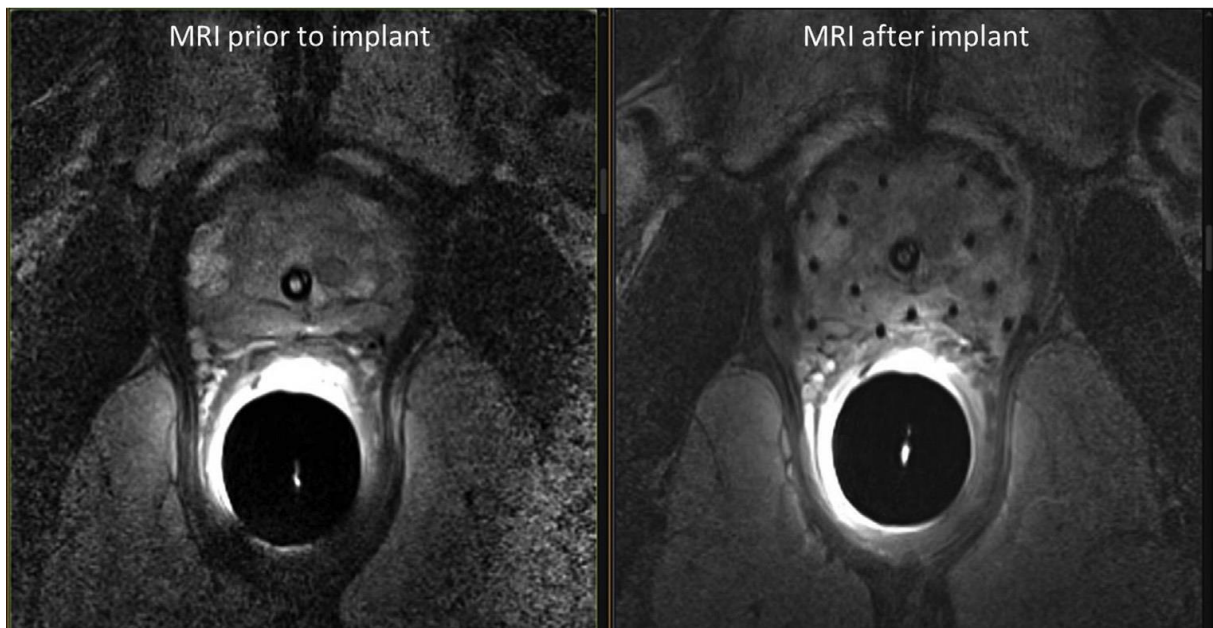


Fig. 13. Illustration indicate typical example of the blurring of the apical prostate boundary after the insertion of catheters secondary to oedema and bleeding. Note brighter T2-w signal in levator ani muscle as a result of trauma.

5.4. Workflow efficiencies

Median time for patient setup was 25 minutes (range, 14-78 minutes). This included induction into intravenous anesthesia, patient positioning on interventional MRI tabletop, insertion of endorectal coil and perineal template, positioning of body coils, and MRI scout imaging for registration of devices. Median duration of the interventional procedure (catheter insertion plus all imaging time) was 100 minutes (range, 51-357 minutes). Median overall anaesthesia time was 4.0 hours (range, 2.1-6.9 hours). A learning curve was evident with trends for improved efficiency over time (**Fig. 14**). Median number of catheter used was 15 (range, 9-18).

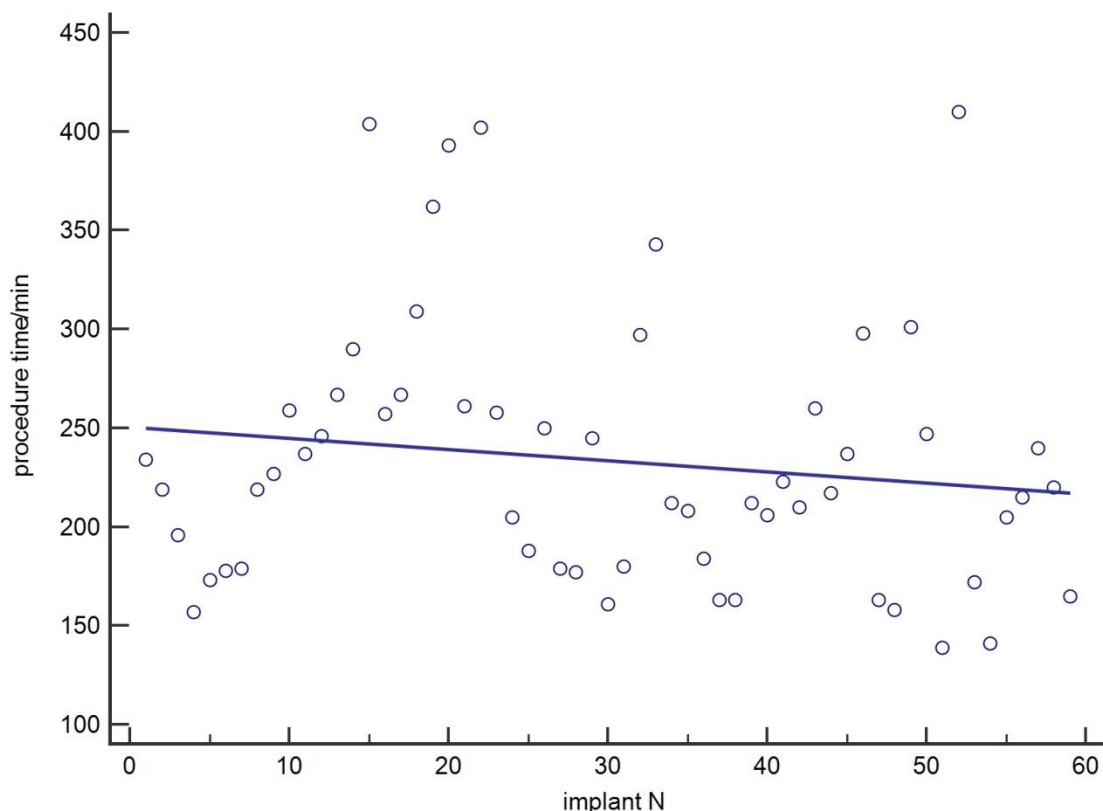


Fig. 14. Regression analysis of overall implant procedure time over the course of the study showing trend towards improved efficiency with shortened overall procedure time (p for slope <0.0001).

5.5. Dosimetric outcomes

Dosimetry data are presented in **Table 10**. Median PTV volume was 34.8 cc (range, 16.8-84.7 cc). Median PTV V100 was 95.8% (range, 81.5-99.4%), whereby PTV V100 was $\geq 95\%$ in 47 procedures (76%) and PTV V100 $>90\%$ in 60 procedures (97%) (**Fig. 15**). Prostate D90 between 105% and 115% of prescribed dose was achieved in 82% of procedures. PTV coverage was typically compromised in non-tumor-bearing regions to improve rectal dose exposures (see example in **Fig. 11**). Rectal doses ranged widely, and dose planning objectives were not met in 48 of 62 implants (77%), mainly due to the proximity of the anterior rectal wall at the mid-gland and apical levels against the posterior prostate boundary (see example in **Fig. 12**). Rectal V75 <1 cc was achieved in only 21% of procedures (**Fig. 16**). Urethral doses were low

and in only one implant exceeded our dose-planning objectives, whereas bladder dose objectives were met in all 62 implants. Prostate $V_{150} \leq 40\%$ was achieved in 42% of procedures and $\leq 50\%$ in 98% of procedures (**Fig. 17**). This large high-dose volume was attributed to a catheter implantation approach that favored catheters to be placed a few millimeters medial to the prostate capsule, rather than immediately at the capsule, to improve catheter visualization, intensify prostate dose, and improve dose conformity.

Table 10. HDR dosimetry data

Parameter	Median value (range)
<i>PTV dose metrics</i>	
PTV volume	34.8 (16.8-84.7) cc
V100	95.8 (81.5-99.4) %
V150	40.7 (25.0-59.7) %
V200	16.9 (11.2-30.1) %
D90	108.6 (94.4-118.0) %
<i>Urethral dose metrics</i>	
V125	6.9 (0-65.0) %
V115	46.7 (1.2-73.0) %
V105	68.7 (19.0-99.0) %
D0.5cc	115.3 (97.4-136.4) %
D10	123.6 (109.8-145.3) %
Maximum point dose	144.0 (126.0-262.0) %
<i>Rectal dose metrics</i>	
V75	3.0 (0-11.8) %
V75 (cc)	1.6 (0-6.1) cc
V80	1.9 (0.1-8.3) %
V80 (cc)	1.0 (0.1-4.2) cc
D0.5cc	85.2 (58.8-95.2) %
Maximum point dose	103.8 (73.6-228.4) %
<i>Bladder dose metrics</i>	
V75	5.0 (0.2-24.1) %
D0.5 cc	90.2 (63.4-116.4) %
Maximum point dose	151.8 (86.8-312.6) %

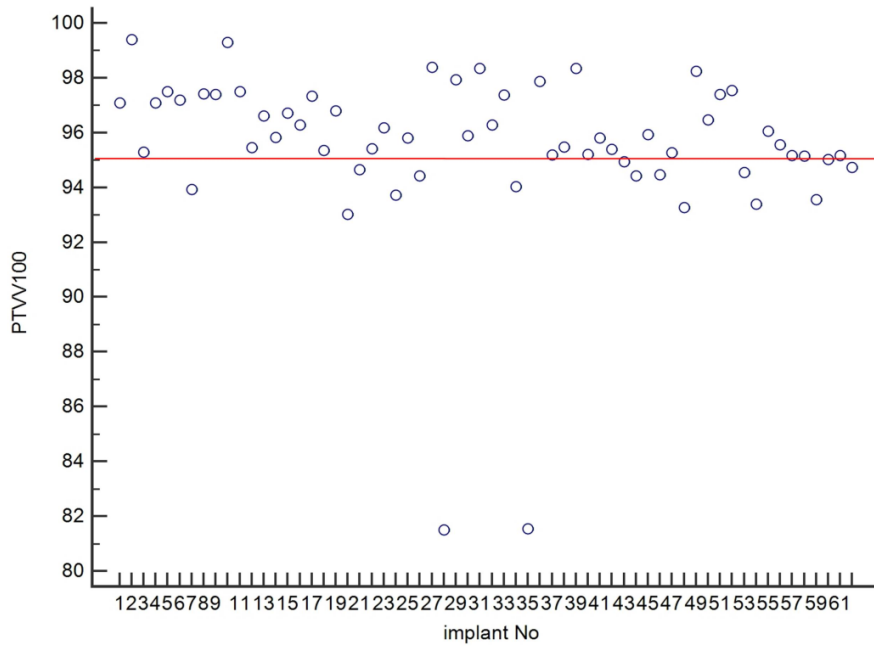


Figure 15. Achieved V100 for PTV (PTV volume covered by 100% of prescribed dose) for each HDR implant plotted against the number of HDR implants performed. Red line represents our planning aim of >95%.

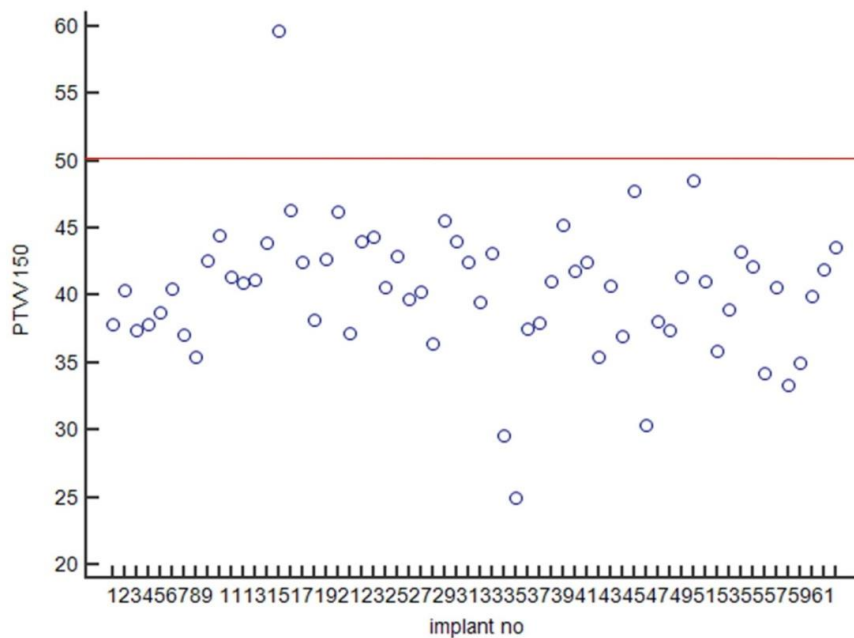


Fig. 16. Achieved V150 for PTV (PTV volume covered by 150% of prescribed dose) for each HDR implant plotted against the number of HDR implants performed. Red line represents our planning aim of <50%.

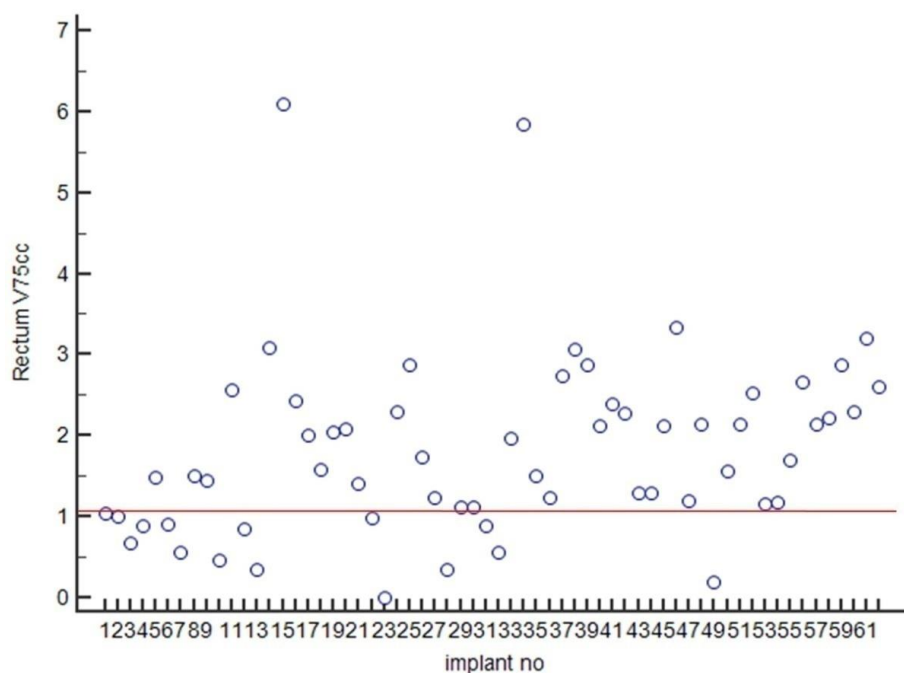


Fig. 17. Achieved Rectal V75(cc) (rectal volume in cc covered by 75% of prescribed dose) for each HDR implant plotted against the number of HDR implants performed. Red line represents our planning aim of <1 cc. Note that in many implants this planning aim was not met.

5.6. PSA and clinical outcomes

At median follow-up of 30 months, 3 patients (7.5%) experienced biochemical failure 16, 30, and 39 months after completion of treatment, respectively. Two of these patients also developed widespread bone metastases shortly after experiencing biochemical failure; 1 patient later developed castrate-resistant disease and is currently receiving docetaxel chemotherapy, whereas the second patient continues to have hormone-sensitive disease. Three patients who failed treatment had unfavourable pre-treatment characteristics, including seminal vesicle invasion, extraprostatic tumor extension of Gleason score (GS) 4+5 disease, seminal vesicle involvement of bulky GS 3+4 tumor, and bilateral GS 3+4 tumor with initial PSA 10.6, respectively. On the review of the implant dosimetry in those patients, no impaired target coverage was identified.

Biochemical relapse-free probability at 3 years was 91.7% (95% confidence interval: 85.0-97.4%). One patient died from stroke 18 months after the procedure, which was not related to either treatment or prostate cancer recurrence.

5.7. Toxicity and health-related quality of life

Two patients (5%) experienced Grade 3 toxicity. One patient experienced Grade 3 acute urinary retention and hematuria that required hospitalization following the HDR brachytherapy implant of 10 Gy. His intra-procedural MRI scans were later reviewed, and on the needle insertion images, urethral trauma was revealed. Other patient developed Grade 3 urethral stricture in the proximal bulbar urethra 4 months after the procedure. Again, careful review of treatment planning images identified urethral trauma at the level inferior to the prostate. This stricture was successfully corrected with urethral dilatation and the patient remained in good urinary function thereafter.

Eight patients (20%) developed Grade 2 acute urinary toxicity, whereas there was no acute Grade 2 gastrointestinal toxicity. Six patients (15.0%) experienced late Grade 2 urinary toxicity. Three patients (7.5%) experienced late Grade 2 gastrointestinal toxicity attributed to the EBRT component.

Changes in IPSS from baseline to follow-up levels are presented in **Fig. 18**. Statistically significant increase in IPSS was observed at the 1-month, 3-month, 6-month, and 1-year follow-up (Bonferroni corrected $p < 0.001$, $p = 0.014$, $p = 0.021$, and $p = 0.021$, respectively), whereas at 2-year and 3-year follow-up this difference was not significant ($p = 0.37$, $p = 1.0$, respectively).

Changes in EPIC summary scores from baseline to follow-up levels are presented in **Fig. 19**. Statistically and clinically significant decrease was observed in EPIC urinary and bowel summary scores during the first year after the treatment. Change in urinary summary scores, bowel summary scores, and sexual summary scores as compared with baseline scores were not statistically different at 1-, 2-, and 3-year follow-up, respectively. Low sexual summary scores were reflective of high use of androgen deprivation therapy (62.5% of patients).

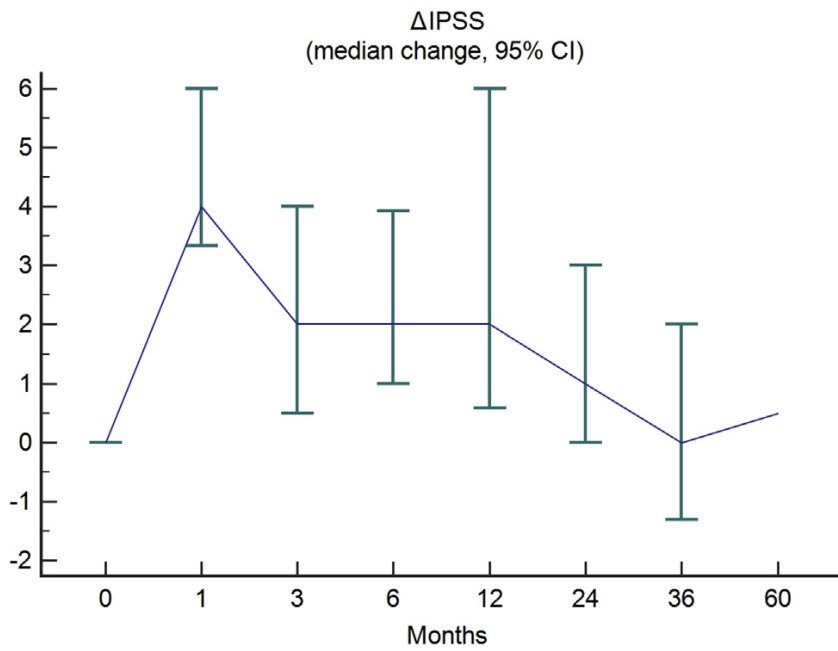


Fig. 18. Change in IPSS from baseline over time
(IPSS=International Prostate Symptom Score, CI=confidence interval)

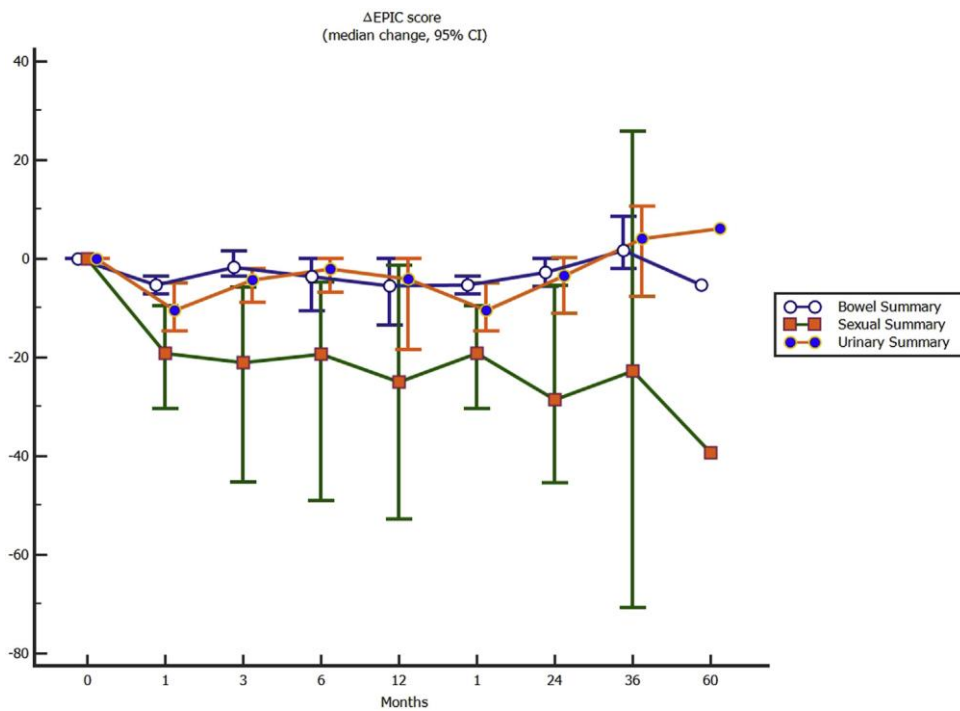


Fig. 19. Changes in EPIC summary scores from baseline over time
(EPIC=Expanded Prostate Cancer Index Composite, CI=confidence interval)

6. DISCUSSION

Main finding from this prospective study is that MRI-guidance of HDR brachytherapy boost for PCa is feasible and safe. This conclusion was established on sufficient number of patients showing added benefit of having MRI both for on-line guidance of brachytherapy catheter insertion and for treatment planning. However, the steep learning curve was evident but with more experience work-flow efficiency was significantly improved and the procedure was subsequently completed within 3-4 hours.

Several important advancements were implemented into our technique of MRI-guided HDR brachytherapy which was initially reported in 2004 as first use of MRI as image guidance tool for prostate HDR brachytherapy (148). Technique has evolved from lateral decubitus to a frog-leg position, from ventilated to non-ventilated anesthesia, from 1.5T to 3T systems, and from prototype to commercialized device (**Fig. 6.**). Interventional MRI is highly resource-intensive program, occupying MRI brachytherapy suite almost for a whole shift and colliding with other increasing demands for MRI scanner in busy radiotherapy department. Therefore, our program initially focused on a tumor-targeted approach in the salvage setting for failure after previous radiotherapy. Subsequently, our program expanded to include patients receiving standard-care HDR brachytherapy prostate boost to EBRT.

In this study, we used an MRI-only work flow, implicating that MRI was used both for catheter navigation, insertion and for treatment planning. Patient stayed on movable table top during all procedure, without changing position, but was transported from MRI suite to brachytherapy suite for treatment delivery.

With this prospective phase II study, we continue to show that MRI guidance is a feasible and safe approach for delivering HDR brachytherapy whole gland boost for prostate cancer. No major toxicity was observed and patient's quality of life although initially decreased, in further follow-up normalized back to the baseline levels. Incidence of late Grade 3 genitourinary toxicity is very low at 2.5%, what is on lower end of observed toxicities in other reports with similar risk-group patient population. Furthermore, early oncologic outcomes are very encouraging. Biochemical recurrence-free survival of 92.5% is in keeping with other reports for similar intermediate- and high-risk population (**Table 6.**). However, these results should be interpreted with caution because of short follow-up (median 30 months), differential use of androgen deprivation therapy compared to other studies and relatively small patient sample size.

The main limitations to broader acceptance of this pure-MRI approach are intensive workflow-related burden and limited access to MRI in general and particularly to interventional MRI in majority of radiotherapy centres.

We demonstrated with the use of interventional MRI that significant proportion of patients had disease extending beyond the prostate boundary, something that was unnoticed at the initial presentation using routine clinical staging such as digitorectal examination and TRUS. Those patients required a more targeted catheter implantation and dose-planning strategy to prevent marginal miss. It is clear that TRUS-guided approach in this setting would result in unappreciated and underestimated disease that would be left untreated leading to major target miss and potential treatment failure.

Our experience is comparable to that reported in EBRT literature where additional imaging information obtained from MRI scans changed treatment coverage in up to 20% of patients (159).

We defined our dose-planning objectives based on TRUS- or CT-based HDR brachytherapy data using published literature (160,161) and found that those dose criteria did not readily translate when using our MRI-based approach.

Basically, we were not able to meet rectal dose-planning objectives in many cases. There might be some potential explanations for that. First, MRI very clearly depicts the rectal wall and posterior prostate boundary, whereby there is little if any uncertainty in delineation compared with TRUS and CT. In our experience, the rectal wall was consistently closely abutted to the prostate gland from the apex to the midgland. It might be possible that the rectal wall is under contoured (or underestimated) on CT and TRUS in the absence of clear visualization. Alternatively, it is also possible that the endorectal imaging coil is positioned in such manner that applies anterior displacement of the rectal wall compared with the conventional TRUS probe setup. Second, in our anesthesia approach, we used intravenous propofol anesthesia without muscle relaxants what might have led to increased tone of pelvic floor musculature that possibly brings closer prostate and the rectum. Furthermore, in TRUS-guided procedure legs are in the lithotomy position sustained by leg supporters, while in MRI-guided procedure legs are on the table, in the frog-leg position. This could also have impact on pelvis floor muscles and rectal-prostate boundary.

It is reassuring, though, that we have not observed any rectal toxicity to date despite more adverse dosimetric indices. Challenges with rectal dose exposures resulted in lower PTV coverage outside tumor-bearing regions of the prostate. It is premature to determine whether PSA or local control outcomes were consequently compromised, but our present results are

encouraging. Finally, we generally observed larger high-dose volumes stemming from a deliberate strategy of implanting all catheters well within the periphery of the gland, with no evident clinical implications to date.

Two cases of transient Grade 3 genitourinary side-effects were observed, both related to incurred urethral trauma at the time of implantation, as confirmed on interventional MR images. One patient had acute urinary retention caused by blood coagulum in the bladder, while the other developed stricture in bulbar urethra. First patient required short hospitalization, bladder catheterization and irrigation and soon was discharged home with spontaneous voiding. Second patient underwent ambulatory urethral dilatation which was successful and the patient remained well with no obstructive urinary issues.

Incidence of acute urinary retention varies between different HDR brachytherapy boost series and heavily depends on fractionation protocol used. In Canadian prospective trial by Morton et al. from Sunnybrook which enrolled 123 patients who were receiving EBRT of 37.5 Gy in 15 fractions combined with single HDR boost dose of 15 Gy, only 2 patients (1.6%) experienced acute urinary retention requiring catheterization. On other hand, in the two HDR fractions protocol, which accrued 60 patients, 12 patients (20%) experienced acute Grade 3 urinary retention (115).

However, comforting is that the majority of acute retention episodes are transient events which completely resolve after patients having catheter inserted for couple of days.

Urethral strictures are the most important and the most common serious late genitourinary side-effects associated with HDR brachytherapy. Incidence of Grade ≥ 2 strictures reported in HDR brachytherapy literature range from less than 1% to alarming 30% (109,162–164). However, realistic rate of urinary strictures in contemporary series is probably below 10% and is associated with fraction size and unintended high-radiation exposure of the external sphincter and bulbo-membranous urethra while delivering full dose to the prostate apex (165). In the work by Hindson et al. on 345 patients treated with EBRT and 3 different HDR brachytherapy boost fractionations (20 Gy/4x, 18 Gy/3x, and 19 Gy/2x) during three sequential time periods with CT-based planning, overall stricture rate was 12.7%, and overall risk of stricture formation at 2 years was 8.2%. The highest stricture risk (31.6%) was in the group of patients that received HDR boost of 19 Gy in 2 fractions. Majority of strictures were located in the bulbomembranous urethra (50%) or external sphincter region (33%). On multivariable analysis the only significant predictor for increased stricture formation was dose schedule used (164). The largest analysis of strictures issue following HDR brachytherapy boost to EBRT is the work by Sullivan et al. on 474 patients using multiple HDR fraction schedules. Thirty-eight patients (8%) were

diagnosed with a urethral stricture leading to 6-year actuarial risk of 12%. The overall actuarial rate of Grade \geq 2 urethral strictures was estimated to be at 10.8%, with the median time to diagnosis of 22 months. Dominant stricture location was bulbo-membranous urethra (92.1%). Most common initial management included dilatation or optical urethotomy, however second and third line salvage therapy was required in 49%, and 9% of cases, respectively. On multivariate analysis, predictive factors for stricture formation were prior TURP and, as in the previous study, HDR dose per fraction (163).

In our experience, needle trauma was presumable causative factor for development of serious genitourinary side-effects. This comes as no surprise, as needle trauma is factor known to be associated with development of urinary toxicity following HDR brachytherapy. In a study by Boyea et al. from William Beaumont Group on 37 patients receiving HDR monotherapy, investigators found that increased number of attempts to satisfactorily position the needles was associated with development of urinary toxicity (166). Possible explanation of this toxicity is probably related to increased prostate oedema caused by repetitive needle insertion and manipulation.

In this study, several features unique to an MRI-only workflow were observed. First, we found that $\frac{3}{4}$ of all patients had either one of two prostatic tumor(s) within the gland. Prostate cancer is often multifocal disease, as data from historical prostatectomy series indicate (167). Contemporary use of MRI enables visualisation of tumor lesions and evaluation of their clinical significance. Furthermore, MRI allowed new avenues of treatment enabling boosting the dominant intraprostatic lesion, which is often the site of local recurrence after EBRT (168). There is growing interest to boost imaging-identified intraprostatic disease and several ongoing trials are trying to address feasibility and utility of this concept (169). However, there is no consensus on GTV definition and boost dose. Boost dose could be delivered either with HDR brachytherapy (10 Gy) or IMRT/VMAT technique (95 Gy in 38 fractions to GTV) as in TARGET study led by Dr. Ménard (study number NCT01802242). Regularly during HDR implant procedure it is possible to place catheters in the core of the tumor (**Fig. 10**) so the lesion can be encompassed by area of very high dose (usually within 200% isodose). HDR brachytherapy whole gland boost routinely employs the principle of boosting the dominant intraprostatic nodule as per regular workflow.

In a recent report by Spanish brachytherapy group aiming to demonstrate feasibility, safety and effectiveness of intraprostatic dose escalation using HDR brachytherapy, 15 patients with intermediate or high risk PCa with MRI detected dominant intra-prostatic nodule (DIL) were

treated with HDR boost using combined MRI-TRUS fusion for image guidance (170). They showed that dose escalation to DIL was feasible in 14 patients, where the dose of 18.75 Gy (125% of the prescribed dose) was successfully delivered to at least 98% of the DIL volume ($D_{98\%} \geq 18.75$ Gy). Authors showed encouraging results for technique where TRUS images were registered with diagnostic MRI for purpose of needle insertion and planning, allowing fair partial prostate dose escalation. Using our pure MRI technique, which brings unprecedented accuracy and precision compared to TRUS-MRI fusion, we were able to escalate dose to the intraprostatic tumor even further. In our experience, DIL would be often encompassed by 200% isodose curve, as the needles were deliberately positioned in the core of the DIL allowing safe extreme dose escalation to the tumor. This was not possible only in a case when the DIL was in the vicinity of the rectum.

In our study, we identified tumors in the anterior aspect of the gland in almost a third of patients. As previously discussed, MRI is capable to discern zonal anatomy of the prostate, which is based on the seminal work by McNeal, who described prostate regional architecture (171). According to that concept, prostate is made up of anterior fibromuscular stroma, and three distinct glandular zones: peripheral zone (located posteriorly and inferiorly), the central zone (located anteriorly), and the transitional zone (located centrally and medially) (**Fig. 20**).

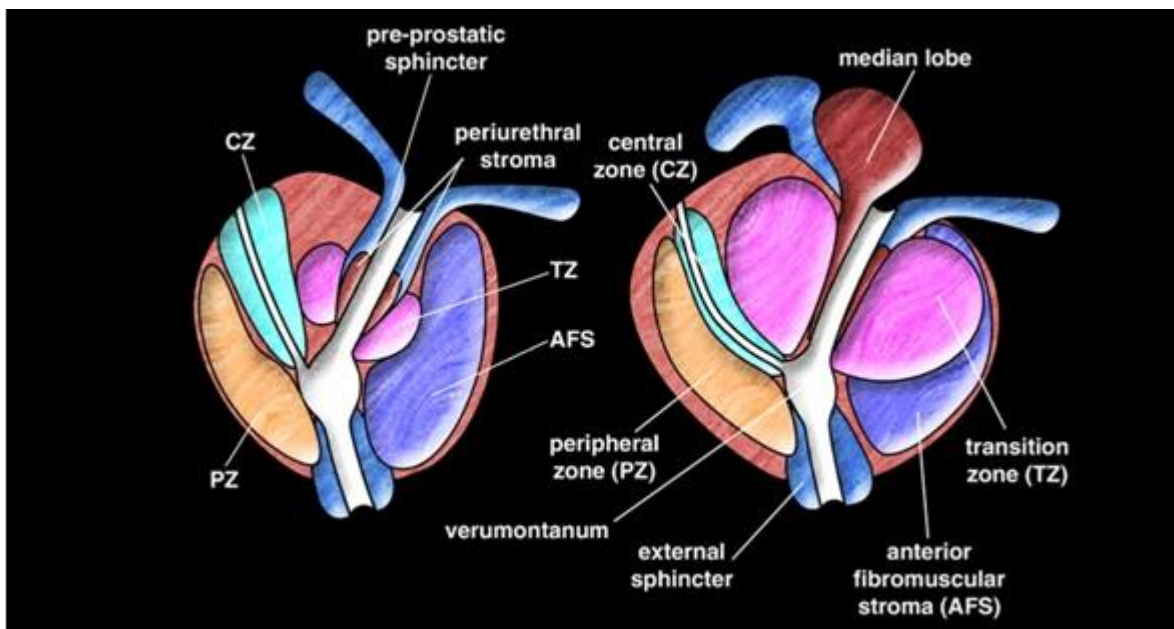


Fig. 20. Zonal anatomy of the prostate (reproduced with permission from Prostadoodle.com, courtesy by Dr. Patrick W. McLaughlin).

Although cancers of the anterior prostate (part of the prostate anterior to the urethra) account for approximately 20% of all prostate cancers, they are often undetected using classical TRUS-guided biopsy as anterior prostate biopsies are excluded from standard sextant biopsy templates (172). Most of the data on anterior prostate cancer comes from the surgical series with whole mount pathology. Those data suggest that anterior prostate cancers have lower Gleason score and lower rates of extraprostatic extension, however they come with higher overall tumor volume and higher rates of positive surgical margins (173). Their clinical behaviour is not well understood although reports indicate that despite adverse pathological features associated with anterior cancers, those cancer have similar clinical outcomes compared to more prevalent posterior cancers (174).

Radiotherapy dose is frequently compromised in the anterior prostate region under presumption that cancer cell are predominantly located in the peripheral zone. However, awareness of the tumor location in anterior prostate, as revealed using interventional MRI, augments the dose distribution and planning aiming to cover all visible disease, avoiding marginal miss.

We also noted blurring of apical prostatic boundary after insertion of catheters and brightening of T2 signal in levator ani muscles resulting from needle trauma (**Fig. 12**).

This observation highlights the importance of having access to MR images acquired before catheter insertion to aid accurate delineation of the prostatic apex. The most important image acquired throughout the procedure is the image acquired before catheter insertion. An alternative strategy would be to obtain a diagnostic MRI scan before the brachytherapy procedure and to either cognitively (175) or computationally register that image to interventional TRUS images (using deformable registration software). However, it is challenging to achieve high registration accuracy in the context of highly deformable target and minimal common imaging structure, especially after catheter insertion which alters anatomical relations. Although some commercial solutions have been developed for three-dimensional fusion of diagnostic MR and TRUS, at present they are far from optimal (176)(177).

This can be particularly relevant in the context of steep dose gradients inherent to HDR brachytherapy, as opposed to TRUS-guided diagnostic biopsies for which these solutions have been mainly developed and tested (178).

Acquiring MR images both before and after a TRUS guided implant may mitigate these issues but introduces other potential workflow inefficiencies to the process. An MRI-only workflow, improved through better computation strategies and the integration of robotics (179,180), remains an appealing strategy.

In this study described MRI-only workflow bring unprecedented precision and customization in the process of image guidance and dose planning of prostate HDR boost. However, it does come with significant associated costs and high resource utilization. This technique requires dedicated MRI access and the crew of highly trained staff who operate scanner and assist in needle navigation and insertion. Although we observed trend of improved procedure efficiency over time, in majority of cases procedure duration is still more than 3 hours. Similarly, steep learning curve and recent trends for shortened procedure time was observed in TRUS/MRI combined prostate HDR program by Aarhus group (Denmark), where average procedure duration time from starting average 7.6 came down to 5.3 hours in more recent procedures (181).

In addition, an anaesthesia team was always present throughout the duration of the procedure. Furthermore, all equipment in the room must be MRI safe, including needles, anaesthesia equipment, stretchers, carts, cameras, monitors, etc. which brings additional significant costs.

Our study has certain limitations that should be acknowledged. Our short patient follow-up (median 30 months) and modest sample size limit our observation regarding clinical outcomes (biochemical control and metastasis-free survival) and prevent drawing conclusion on long-term efficacy and toxicity profile of our treatment protocol. In addition, migration of standard dose prescription practices (both for EBRT and HDR components of the treatment) through the course of the study resulted in a heterogeneous radiation treatment across the cohort. Optimally, dose-summation analysis using deformable image registration in a larger cohort of patients may better identify relationship between dose metrics and patient outcomes.

7. CONCLUSION

In this study we found that an MRI-only workflow for prostate HDR brachytherapy revealed the influence of images acquired throughout the course of the procedure toward improving tumor coverage and overall implant quality. An MRI-only workflow is feasible and safe and justified in patients with large tumor burden but must be streamlined for broader acceptance given its high resource utilization. One way to improve efficiency of the procedure would potentially be dual imaging modality use: TRUS for needle insertion guidance and MRI for treatment planning. In this scenario, MRI could be acquired following TRUS-guided needle

implantation to facilitate improve dose optimization for HDR brachytherapy. However, it remains to be seen whether this concept is clinically feasible.

8. FUTURE DIRECTIONS

MRI-guided brachytherapy remains attractive concept in both in LDR and HDR brachytherapy for prostate cancer. However, it is hard to predict how the role of MRI will entails in HDR brachytherapy given very high level of complexity and intense resource utilisation associated with interventional MRI. Added benefit of MRI in whole gland boost might be less critical compared with role of MRI guidance in focal treatment (either for salvage after previous EBRT or targeted dose escalation to dominant intraprostatic lesion or upfront partial gland treatment). Recent study from Princess Margaret Cancer Centre prostate brachytherapy group presented dosimetric feasibility of focal dose-escalated HDR monotherapy. In this dosimetric study it was found feasible to escalate the dose both to intraprostatic PTV (33-36 Gy) and GTV (40 Gy) in two fractions respecting predefined OAR constraints. Additionally, in almost half of the investigated cases it was possible to achieve single-dose treatment of 24 Gy to PTV (182). Although focal therapy concept definitively needs to be assessed in rigorously conducted prospective trial, these preliminary dosimetric results remain encouraging. Potential candidates for focal approach would probably be patients with unifocal gross disease (MRI-defined lesion) in lower risk group.

Advent of new technologies can further augment precision of MRI-guided brachytherapy and streamline its flow. Introduction of robotics in this field has already been tested (180,183) with encouraging results. Given accessibility problem in interventional MRI scanner in regards to needle insertion, this part of procedure could be performed by the MRI-compatible robot. Current strategy is being tested in Nijmegen, Netherlands.

Other avenues of research which could impact MRI-targeted brachytherapy are integration of TRUS with MRI in order to simplify implant procedure. Such dual-imaging modality offers potential for improving efficiency of the implant procedure and overcoming of shortcomings of each single imaging modality. As previously discussed, one potential explication of inefficiencies of intraoperative MRI guidance could be integration of TRUS for intraoperative catheter guidance and subsequent MRI-TRUS fusion. However, caution should be exerted here, as there is always potential for significant error given imperfect image fusion. To overcome this issue, different deformable registration software solutions have been developed including our in-house program (Morfeus). This is a biomechanical-model based deformable

registration algorithm which takes into account elastic registration of prostate MR based on estimation of deformation states between two imaging points (i.e. fusion of diagnostic MRI or simulation MRI with planning MRI with implanted prostate) (184).

More work remains to be done in area of MRI sequence optimization and imaging efficiency with aim of acquiring highest quality images in shortest time frame to reduce procedure length, improve clinical workflow and decrease treatment-related burden while optimizing cure rates and maintaining high quality of life.

9. SAŽETAK - ABSTRACT IN CROATIAN

UVOD: Brahiterapija velikom brzinom doze je metoda izbora u visokodoznom zračenju raka prostate. Magnetska rezonanca (MR) pruža visoku slikovnu rezoluciju mekih tkiva i teoretski može poslužiti kao odlično sredstvo slikovnog navođenja brahiterapije velikom brzinom doze.

BOLESNICI I METODE: Četrdeset (40) bolesnika s rakom prostate srednjeg ili visokog rizika uključeno je u prospektivnu kliničku studiju koju je odobrilo etičko povjerenstvo ustanove Princess Margaret Hospital. Multiparametrijska MR sa stereotaksijskom navigacijom je korištena u svrhu navođenja brahiterapijskih katetera, nakon čega je uslijedilo planiranje zračenja na osnovi MR.

REZULTATI: U okviru studije provedena su 62 brahiterapijska implanta. Medijan vremena potrebnog za inserciju katetera i oslikavanje bio je 100 minuta, dok je cjelokupno vrijeme trajanja anestezije bilo oko 4.0 sati (raspon 2.1-6.9 sati). MR korištena za vrijeme brahiterapije otkrila je da je u 14 (35%) bolesnika viši stadij bolesti nego što se prethodno smatralo. U 6 bolesnika ovo saznanje je koristilo u ciljanom navođenju brahiterapijskih katetera izvan granica prostate: slučaj ekstrakapsularnog širenja u 2 bolesnika te širenje bolesti u sjemene mjehuriće u 4 bolesnika. Većina bolesnika (80%) je imalo vidljiv tumor uočljiv na MR, koji je utjecao na raspored razmještanja katetera i planiranja zračenja. MR je opisao anatomske granice jasno nakon provedene implantacije, osim u slučaju apeksa prostate koji je bio zamagljen prisutnom krvlju nakon insercije katetera. Konvencionalna ograničenja doze za pokrivanje PTV (PTV V100>98%) i za rektum (V75<1.0 cc) bilo je teško zadovoljiti, no toksičnost metode je bila mala (akutna genitourinarna toksičnost većeg ili jednakog stupnja od 2 bila je 20%, kasna genitourinarna toksičnost većeg ili jednakog stupnja od 2 bila je 15%, kasna gastrointestinalna toksičnost većeg ili jednakog stupnja od 2 iznosila je 7%). Mehaničko oštećenje uretre viđeno na MR dovelo je do dvije ozbiljne nuspojave gradusa 3, koje su bile prolazne prirode.

ZAKLJUČAK: Unatoč standardnom brahiterapijskom pristupu, MR snimanje i slikovno vođenje tijekom brahiterapijske procedure promjenilo je raspored insercije katetera i strategiju planiranja zračenja. Klinički rad u brahiterapiji velikom brzinom doze u liječenju raka prostate upotrebom isključivo MR kao metode slikovnog navođenja je izvediv i siguran, no da bi bio opće prihvaćen potrebno ga je pojednostavniti.

10. ABSTRACT IN ENGLISH

PhD thesis: MRI guidance in high-dose-rate brachytherapy for prostate cancer

PhD candidate: Jure Murgic, MD

Year: 2017

INTRODUCTION: MRI has been widely accepted as the best imaging modality for prostate cancer. However, there is lack of knowledge how MRI perform when applied in MRI-only workflow for catheter insertion and treatment planning in patients receiving standard-care high-dose-rate (HDR) brachytherapy prior to external beam radiotherapy for prostate cancer.

PATIENTS AND METHODS: Forty patients with intermediate or high-risk prostate cancer were enrolled on a prospective clinical trial approved by institution's research ethics board. Multiparametric MR imaging with stereotactic navigation was used to guide insertion of brachytherapy catheters, followed by MRI-based treatment planning.

RESULTS: Sixty-two implants were performed. Median catheter insertion + imaging time was 100 min, and overall anaesthesia time was 4.0 hours (range 2.1-6.9 hours). MRI at the time of brachytherapy re-staged 14 patients (35%) who were found to have a higher stage of disease. In 6 patients this translated in directed insertion of brachytherapy catheters outside of the prostate boundary (extracapsular disease (n=2) or seminal vesicle invasion (n=4)). Most patients (80%) had gross tumor visible on MRI, which influenced catheter insertion and treatment planning. MRI depicted post-implant anatomic boundaries clearly, with the exception of the apical prostate which was blurred by blood after catheter insertion. Conventional dose planning objectives for PTV coverage (PTV V100>98%) and for the rectum (rectal V75<1.0 cc) were difficult to achieve, but toxicities were low (acute grade \geq 2 genitourinary = 20%, late grade \geq 2 genitourinary = 15%, late grade \geq 2 gastrointestinal = 7%). Urethral trauma visualized on MRI led to 2 transient grade 3 events.

CONCLUSION: Despite a standard-care treatment, MRI acquired throughout the procedure altered catheter insertion and dose-planning strategies. An MRI-only workflow is feasible and safe, but must be streamlined for broader acceptance.

Portions of this dissertation were previously published in the following manuscript: Murgic J, Chung P, Berlin A, Bayley A, Warde P, Catton C, et al. Lessons learned using an MRI-only workflow during HDR brachytherapy for prostate cancer. *Brachytherapy*. 2016; 15(2): 147-55.

11. REFERENCES

1. Siegel RL, Miller KD JA. Cancer statistics, 2016. *CA Cancer J Clin*. 2016;66(1):7–30.
2. Canadian Cancer Society’s Advisory Committee on Cancer Statistics. Canadian Cancer Statistics 2016. [Internet]. 2016 [cited 2016 Nov 1]. Available from: cancer.ca/Canadian-Cancer-Statistics-2016-EN.pdf
3. Cancer incidence in Croatia [Internet]. Croatian Institute of Public Health and Croatian National Cancer Registry. 2014. Available from: http://www.hzjz.hr/wp-content/uploads/2013/11/Bilten-2014_final.pdf
4. Cooperberg MR, Broering JM, Carroll PR. Time trends and local variation in primary treatment of localized prostate cancer. *J Clin Oncol*. 2010;28(7):1117–23.
5. Schröder FH, Hugosson J, Roobol MJ, Tammela TLJ, Ciatto S, Nelen V, et al. Screening and prostate-cancer mortality in a randomized European study. *N Engl J Med*. 2009;360(13):1320–8.
6. Andriole GL, Crawford ED, Grubb RL, Buys SS, Chia D, Church TR et al. Mortality results from a randomized prostate-cancer screening trial. *N Engl J Med*. 2009;360(13):1310–9.
7. Moyer VA. Screening for prostate cancer: U.S. preventive services task force recommendation statement. Vol. 157, *Annals of Internal Medicine*. 2012. p. 120–34.
8. Drazer MW, Huo D, Eggener SE. National prostate cancer screening rates after the 2012 US Preventive Services Task Force recommendation discouraging prostate-specific antigen-Based screening. *J Clin Oncol*. 2015;33(22):2416–23.
9. (U.S.) NCI. Surveillance, Epidemiology, and End Results (SEER) Program Stat Fact Sheets [Internet]. Prostate Cancer. 2015. Available from: <http://seer.cancer.gov/statfacts/html/prost.html>
10. Augustin H, Hammerer PG, Graefen M, Palisaar J, Daghofer F, Huland H, et al. Characterisation of biomolecular profiles in primary high-grade prostate cancer treated by radical prostatectomy. *J Cancer Res Clin Oncol*. 2003;129(11):662–8.
11. Hernandez DJ, Nielsen ME, Han M, Partin AW. Contemporary Evaluation of the D’Amico Risk Classification of Prostate Cancer. *Urology*. 2007;70(5):931–5.
12. D’Amico A V, Whittington R, Malkowicz SB, Schultz D, Blank K, Broderick G a, et al. Biochemical outcome after radical prostatectomy, external beam radiation therapy, or interstitial radiation therapy for clinically localized prostate cancer. *JAMA*. 1998;280(11):969–74.

13. Edge SB, Compton CC. The American Joint Committee on Cancer: the 7th edition of the AJCC cancer staging manual and the future of TNM. *Ann Surg Oncol.* 2010;17(6):1471–4.
14. Mohler L, Armstrong J, Bahnson R, D’Amico Victor A, Davis J, Eastham A, et al. Prostate Cancer, Version 1.2016. *J Natl Compr Canc Netw.* 2016;14(1):19.
15. Sundi D, Wang V, Pierorazio P, Han M, Bivalacqua T, Ball M, et al. Very-high-risk localized prostate cancer: definition and outcomes. *Prostate Cancer Prostatic Dis.* 2013;17(10):57–63.
16. D’Amico A V., Moul J, Carroll PR, Sun L, Lubeck D, Chen MH. Cancer-specific mortality after surgery or radiation for patients with clinically localized prostate cancer managed during the prostate-specific antigen era. *J Clin Oncol.* 2003;21(11):2163–72.
17. Cooperberg MR, Carroll P. Trends in management for patients with localized prostate cancer, 1990-2013. *JAMA.* 2015;314(1):80–2.
18. Chen RC, Bryan Rumble R, Andrew Loblaw D, Finelli A, Ehdaie B, Cooperberg MR, et al. Active surveillance for the management of localized prostate cancer (Cancer Care Ontario guideline): American society of clinical oncology clinical practice guideline endorsement. *J Clin Oncol.* 2016;34(18):2182–90.
19. Grimm P, Billiet I, Bostwick D, Dicker AP, Frank S, Immerzeel J, et al. Comparative analysis of prostate-specific antigen free survival outcomes for patients with low, int. & high risk prostate cancer treatment by radical therapy. *BJU Int.* 2012;109 Suppl:22–9.
20. Zaorsky NG, Harrison AS, Trabulsi EJ, Gomella LG, Showalter TN, Hurwitz MD, et al. Evolution of advanced technologies in prostate cancer radiotherapy. *Nat Rev Urol.* 2013;10(10):565–79.
21. Shipley WU, Thames HD, Sandler HM, Hanks GE, Zietman AL, Perez CA, et al. Radiation therapy for clinically localized prostate cancer: a multi-institutional pooled analysis. *JAMA.* 1999;281(17):1598–604.
22. Pollack a, Smith LG, von Eschenbach a C. External beam radiotherapy dose response characteristics of 1127 men with prostate cancer treated in the PSA era. *Int J Radiat Oncol Biol Phys.* 2000;48(2):507–12.
23. Symon Z, Griffith KA, McLaughlin PW, Sullivan M, Sandler HM. Dose escalation for localized prostate cancer: Substantial benefit observed with 3D conformal therapy. *Int J Radiat Oncol Biol Phys.* 2003;57(2):384–90.
24. Bauman G, Rumble RB, Chen J, Loblaw A, Warde P. Intensity-modulated Radiotherapy in the Treatment of Prostate Cancer. *Clin Oncol.* 2012;24(7):461–73.

25. Bruner DW, Hunt D, Michalski JM, Bosch WR, Galvin JM, Amin M, et al. Preliminary patient-reported outcomes analysis of 3-dimensional radiation therapy versus intensity-modulated radiation therapy on the high-dose arm of the Radiation Therapy Oncology Group (RTOG) 0126 prostate cancer trial. *Cancer*. 2015;121:2422–30.
26. Jaffray DA. Image-guided radiotherapy: from current concept to future perspectives. *Nat Rev Clin Oncol*. 2012;9(12):688–99.
27. Bujold A, Craig T, Jaffray D, Dawson LA. Image-Guided Radiotherapy: Has It Influenced Patient Outcomes? Vol. 22, *Seminars in Radiation Oncology*. 2012. p. 50–61.
28. Zelefsky MJ, Leibel SA, Gaudin PB, Kutcher GJ, Fleshner NE, Venkatramen ES, et al. Dose escalation with three-dimensional conformal radiation therapy affects the outcome in prostate cancer. *Int J Radiat Oncol Biol Phys*. 1998;41(3):491–500.
29. Zelefsky MJ, Pei X, Chou JF, Schechter M, Kollmeier M, Cox B, et al. Dose escalation for prostate cancer radiotherapy: Predictors of long-term biochemical tumor control and distant metastases-free survival outcomes. *Eur Urol*. 2011;60(6):1133–9.
30. Pollack A, Zagars GK, Smith LG, Lee JJ, Von Eschenbach AC, Antolak JA, et al. Preliminary results of a randomized radiotherapy dose-escalation study comparing 70 Gy with 78 Gy for prostate cancer. *J Clin Oncol*. 2000;18(23):3904–11.
31. Pollack A, Zagars GK, Starkschall G, Antolak JA, Lee JJ, Huang E, et al. Prostate cancer radiation dose response: Results of the M. D. Anderson phase III randomized trial. *Int J Radiat Oncol Biol Phys*. 2002;53(5):1097–105.
32. Kuban DA, Tucker SL, Dong L, Starkschall G, Huang EH, Cheung MR, et al. Long-Term Results of the M. D. Anderson Randomized Dose-Escalation Trial for Prostate Cancer. *Int J Radiat Oncol Biol Phys*. 2008;70(1):67–74.
33. Kuban DA, Levy LB, Cheung MR, Lee AK, Choi S, Frank S, et al. Long-term failure patterns and survival in a randomized dose-escalation trial for prostate cancer. Who dies of disease? *Int J Radiat Oncol Biol Phys*. 2011;79(5):1310–7.
34. Al-Mamgani A, van Putten WLJ, Heemsbergen WD, van Leenders GJLH, Slot A, Dielwart MFH, et al. Update of Dutch Multicenter Dose-Escalation Trial of Radiotherapy for Localized Prostate Cancer. *Int J Radiat Oncol Biol Phys*. 2008;72(4):980–8.
35. Heemsbergen WD, Al-Mamgani A, Slot A, Dielwart MFH, Lebesque J V. Long-term results of the Dutch randomized prostate cancer trial: Impact of dose-escalation on local, biochemical, clinical failure, and survival. *Radiother Oncol*. 2014;110(1):104–9.

36. Zietman AL, Bae K, Slater JD, Shipley WU, Efstathiou JA, Coen JJ, et al. Randomized trial comparing conventional-dose with high-dose conformal radiation therapy in early-stage adenocarcinoma of the prostate: Long-term results from Proton Radiation Oncology Group/American College Of Radiology 95-09. *J Clin Oncol.* 2010;28(7):1106–11.
37. Beckendorf V, Guerif S, Le Prisé E, Cosset JM, Bougnoux A, Chauvet B, et al. 70 Gy versus 80 Gy in localized prostate cancer: 5-year results of GETUG 06 randomized trial. *Int J Radiat Oncol Biol Phys.* 2011;80(4):1056–63.
38. Dearnaley DP, Jovic G, Syndikus I, Khoo V, Cowan RA, Graham JD, et al. Escalated-dose versus control-dose conformal radiotherapy for prostate cancer: Long-term results from the MRC RT01 randomised controlled trial. *Lancet Oncol.* 2014;15(4):464–73.
39. Michalski JM et al. Initial Results of a Phase 3 Randomized Study of High Dose 3DCRT/IMRT versus Standard Dose 3D-CRT/IMRT in Patients Treated for Localized Prostate Cancer (RTOG 0126). *Int J Radiat Oncol Biol Phys.* 2014;90(suppl.):1263.
40. Michalski JM, Moughan J, Purdy J, Bosch W, Bahary JP LH. A randomized trial of 79.2Gy versus 70.2Gy radiation therapy (RT) for localized prostate cancer. *J Clin Oncol.* 2015;33(suppl 7):abstract 4.
41. Dearnaley DP, Sydes MR, Graham JD, Aird EG, Bottomley D, Cowan RA, et al. Escalated-dose versus standard-dose conformal radiotherapy in prostate cancer: first results from the MRC RT01 randomised controlled trial. *Lancet Oncol.* 2007;8(6):475–87.
42. Viani GA, Stefano EJ, Afonso SL. Higher-Than-Conventional Radiation Doses in Localized Prostate Cancer Treatment: A Meta-analysis of Randomized, Controlled Trials. *Int J Radiat Oncol Biol Phys.* 2009;74(5):1405–18.
43. Zaorsky NG, Keith SW, Shaikh T, Nguyen PL, Horwitz EM, Dicker AP, et al. Impact of Radiation Therapy Dose Escalation on Prostate Cancer Outcomes and Toxicities. *Am J Clin Oncol.* 2016;
44. Bolla M, Collette L, Blank L, Warde P, Dubois JB, Mirimanoff R-O, et al. Long-term results with immediate androgen suppression and external irradiation in patients with locally advanced prostate cancer (an EORTC study): a phase III randomized trial. *Lancet.* 2002;360(9327):103–6.
45. D’Amico A V, Manola J, Loffredo M, Renshaw A a, DellaCroce A, Kantoff PW. 6-Month Androgen Suppression Plus Radiation Therapy Vs Radiation Therapy Alone for Patients With Clinically Localized Prostate Cancer: a Randomized Controlled Trial.

- JAMA. 2004;292(7):821–7.
46. Denham JW, Steigler A, Lamb DS, Joseph D, Mameghan H, Turner S, et al. Short-term androgen deprivation and radiotherapy for locally advanced prostate cancer: Results from the Trans-Tasman Radiation Oncology Group 96.01 randomised controlled trial. *Lancet Oncol.* 2005;6(11):841–50.
 47. Lawton CA, DeSilvio M, Roach M 3rd, Uhl V, Kirsch R, Seider M, Rotman M, Jones C, Asbell S, Valicenti R, Hahn S TCJ. An update of the phase III trial comparing whole pelvic to prostate only radiotherapy and neoadjuvant to adjuvant total androgen suppression: updated analysis of RTOG 94-13, with emphasis on unexpected hormone/radiation interactions. *Int J Radiat Oncol Biol Phys.* 2007;69(3):646–55.
 48. Horwitz EM, Bae K, Hanks GE, Porter A, Grignon DJ, Brereton HD, et al. Ten-year follow-up of radiation therapy oncology group protocol 92-02: a phase III trial of the duration of elective androgen deprivation in locally advanced prostate cancer. *J Clin Oncol.* 2008;26(15):2497–504.
 49. Jones CU, Hunt D, McGowan DG, Amin MB, Chetner MP, Bruner DW, et al. Radiotherapy and short-term androgen deprivation for localized prostate cancer. *N Engl J Med.* 2011;365(2):107–18.
 50. Bolla M, Maingon P, Carrie C, Villa S, Kitsios P, Poortmans PMP, et al. Short Androgen Suppression and Radiation Dose Escalation for Intermediate- and High-Risk Localized Prostate Cancer: Results of EORTC Trial 22991. *J Clin Oncol.* 2016;34(15):JCO.2015.64.8055-.
 51. Nabid A, Carrier N, Vigneault E, Souhami L, Lemaire C BM. Place of short-term androgen deprivation therapy in intermediate-risk prostate cancer treated with radiotherapy: A phase III trial. *J Clin Oncol.* 2015;33(suppl.):abstract 5019.
 52. Huggins C HC. Studies on prostatic cancer: i. The effect of castration, of estrogen and of androgen injection on serum phosphatases in metastatic carcinoma of the prostate. *J Urol.* 1941;168:9–12.
 53. Zietman AL, Prince EA, Nakfoor BM, Park JJ. Androgen deprivation and radiation therapy: Sequencing studies using the shionogi in vivo tumor system. *Int J Radiat Oncol Biol Phys.* 1997;38(5):1067–70.
 54. Kaminski JML, Hanlon AL, Joon DL, Meistrich M, Hachem P, Pollack A. Effect of sequencing of androgen deprivation and radiotherapy on prostate cancer growth. *Int J Radiat Oncol Biol Phys.* 2003;57(1):24–8.
 55. Godoy A, Montecinos VP, Gray DR, Sotomayor P, Yau JM, Vethanayagam RR, et al.

- Androgen deprivation induces rapid involution and recovery of human prostate vasculature. *Am J Physiol Endocrinol Metab.* 2011;300(2):E263-75.
56. Joseph IBJK, Nelson JB, Denmeade SR, Isaacs JT. Androgens regulate vascular endothelial growth factor content in normal and malignant prostatic tissue. *Clin Cancer Res.* 1997;3(12 D):2507–11.
 57. Milosevic M, Warde P, Ménard C, Chung P, Toi A, Ishkanian A, et al. Tumor hypoxia predicts biochemical failure following radiotherapy for clinically localized prostate cancer. *Clin Cancer Res.* 2012;18(7):2108–14.
 58. Wo JY, Zietman AL. Why does androgen deprivation enhance the results of radiation therapy? Vol. 26, *Urologic Oncology: Seminars and Original Investigations.* 2008. p. 522–9.
 59. Harris WP, Mostaghel EA, Nelson PS, Montgomery B. Androgen deprivation therapy: progress in understanding mechanisms of resistance and optimizing androgen depletion. *Nat Clin Pract Urol.* 2009;6(2):76–85.
 60. Pilepich M V, Winter K, John MJ, Mesic JB, Sause W, Rubin P, et al. Phase III radiation therapy oncology group (RTOG) trial 86-10 of androgen deprivation adjuvant to definitive radiotherapy in locally advanced carcinoma of the prostate. *Int J Radiat Oncol Biol Phys.* 2001;50(5):1243–52.
 61. Bolla M, Van Tienhoven G, Warde P, Dubois JB, Mirimanoff RO, Storme G, et al. External irradiation with or without long-term androgen suppression for prostate cancer with high metastatic risk: 10-year results of an EORTC randomised study. *Lancet Oncol.* 2010;11(11):1066–73.
 62. D’Amico A V., Chen MH, Crook J, Armstrong JG, Malone S, Steigler A, et al. Duration of short-course androgen suppression therapy and the risk of death as a result of prostate cancer. *J Clin Oncol.* 2011;29(35):4682–7.
 63. Lawton CA, Winter K, Murray K, Machtay M, Mesic JB, Hanks GE, Coughlin CT PM. Updated results of the phase III Radiation Therapy Oncology Group (RTOG) trial 85-31 evaluating the potential benefit of androgen suppression following standard radiation therapy for unfavorable prognosis carcinoma of the prostate. *Int J Radiat Oncol Biol Phys.* 2001;49(4):937–46.
 64. Denham JW, Steigler A, Lamb DS, Joseph D, Turner S, Matthews J, et al. Short-term neoadjuvant androgen deprivation and radiotherapy for locally advanced prostate cancer: 10-year data from the TROG 96.01 randomised trial. *Lancet Oncol.* 2011;12(5):451–9.

65. Dearnaley D, Syndikus I, Mossop H, Khoo V, Birtle A, Bloomfield D, et al. Conventional versus hypofractionated high-dose intensity-modulated radiotherapy for prostate cancer: 5-year outcomes of the randomised, non-inferiority, phase 3 CHHiP trial. *Lancet Oncol.* 2016;17(8):1047–60.
66. Bolla M, de Reijke TM, Van Tienhoven G, Van den Bergh ACM, Oddens J, Poortmans PMP, et al. Duration of androgen suppression in the treatment of prostate cancer. *N Engl J Med.* 2009;360(24):2516–27.
67. Zapatero A, Araceli Guerrero, Xavier Maldonado, Ana Alvarez, Carmen Gonzalez San Segundo, Maria Angeles Cabeza Rodríguez, Victor Macias, Agustí Pedro Olive, Francesc Casas, Ana Boladeras, Carmen Martín de Vidales, Maria Luisa Vazquez de la Torre, S FAC. High-dose radiotherapy with short-term or long-term androgen deprivation in localised prostate cancer (DART01/05 GICOR): a randomised, controlled, phase 3 trial. *Lancet Oncol.* 2015;16(3):320–7.
68. Pisansky TM, Hunt D, Gomella LG, Amin MB, Balogh AG, Chinn DM, et al. Duration of androgen suppression before radiotherapy for localized prostate cancer: Radiation therapy oncology group randomized clinical trial 9910. In: *Journal of Clinical Oncology.* 2015. p. 332–9.
69. Fowler JF. The linear-quadratic formula and progress in fractionated radiotherapy. Vol. 62, *British Journal of Radiology.* 1989. p. 679–94.
70. Joiner M. *Basic Clinical Radiobiology.* Boca Raton, FL: CRC Press; 2009.
71. Brenner DJ, Hall EJ. Fractionation and protraction for radiotherapy of prostate carcinoma. *Int J Radiat Oncol Biol Phys.* 1999;43(5):1095–101.
72. Miralbell R, Roberts SA, Zubizarreta E, Hendry JH. Dose-fractionation sensitivity of prostate cancer deduced from radiotherapy outcomes of 5,969 patients in seven international institutional datasets: $a/b = 1.4 (0.9-2.2)$ Gy. *Int J Radiat Oncol Biol Phys.* 2012;82(1).
73. Vogelius IR, Bentzen SM. Meta-analysis of the alpha/beta ratio for prostate cancer in the presence of an overall time factor: Bad news, good news, or no news? *Int J Radiat Oncol Biol Phys.* 2013;85(1):89–94.
74. Brenner DJ, Martinez AA, Edmundson GK, Mitchell C, Thames HD, Armour EP. Direct evidence that prostate tumors show high sensitivity to fractionation (low α/β ratio), similar to late-responding normal tissue. *Int J Radiat Oncol Biol Phys.* 2002;52(1):6–13.
75. Arcangeli G, Saracino B, Gomellini S, Petrongari MG, Arcangeli S, Sentinelli S, et al. A Prospective phase III randomized trial of hypofractionation versus conventional

- fractionation in patients with high-risk prostate cancer. *Int J Radiat Oncol Biol Phys.* 2010;78(1):11–8.
76. Incrocci L, Wortel RC, Alemayehu WG, Aluwini S, Schimmel E, Krol S, et al. Hypofractionated versus conventionally fractionated radiotherapy for patients with localised prostate cancer (HYPRO): final efficacy results from a randomised, multicentre, open-label, phase 3 trial. *Lancet Oncol.* 2016;17(8):1061–9.
 77. Lee WR, Dignam JJ, Amin MB, Bruner DW, Low D, Swanson GP, et al. Randomized phase III noninferiority study comparing two radiotherapy fractionation schedules in patients with low-risk prostate cancer. *J Clin Oncol.* 2016;34(20):2325–32.
 78. Yeoh EE, Botten RJ, Butters J, Di Matteo AC, Holloway RH, Fowler J. Hypofractionated versus conventionally fractionated radiotherapy for prostate carcinoma: Final results of phase III randomized trial. *Int J Radiat Oncol Biol Phys.* 2011;81(5):1271–8.
 79. Lukka H, Hayter C, Julian J a, Warde P, Morris WJ, Gospodarowicz M, et al. Randomized trial comparing two fractionation schedules for patients with localized prostate cancer. *J Clin Oncol.* 2005;23(25):6132–8.
 80. Pollack A, Walker G, Horwitz EM, Price R, Feigenberg S, Konski AA, et al. Randomized trial of hypofractionated external-beam radiotherapy for prostate cancer. *J Clin Oncol.* 2013;31(31):3860–8.
 81. Arcangeli S, Strigari L, Gomellini S, Saracino B, Petrongari MG, Pinnarò P, et al. Updated results and patterns of failure in a randomized hypofractionation trial for high-risk prostate cancer. *Int J Radiat Oncol Biol Phys.* 2012;84(5):1172–8.
 82. Mazon JJ, Scalliet P, Van Limbergen E LE. Radiobiology of Brachytherapy and the Dose-Rate Effect. *Handb Brachytherapy.* 2005;96–121.
 83. International Commission on Radiation Units and Measurements. Dose and volume specification for reporting intracavitary therapy in gynecology. Report 38. Bethesda, MD; 1985.
 84. Gupta VK. Brachytherapy - Past, Present And Future. *J Med Phys.* 1995;20(2):31–8.
 85. Georg D, Hopfgartner J, Góra J, Kuess P, Kragl G, Berger D, et al. Dosimetric considerations to determine the optimal technique for localized prostate cancer among external photon, proton, or carbon-ion therapy and high-dose-rate or low-dose-rate brachytherapy. *Int J Radiat Oncol Biol Phys.* 2014;88(3):715–22.
 86. Zelefsky MJ, Poon BY, Eastham J, Vickers A, Pei X, Scardino PT. Longitudinal assessment of quality of life after surgery, conformal brachytherapy, and intensity-

- modulated radiation therapy for prostate cancer. *Radiother Oncol.* 2016;118(1):85–91.
87. Hinnen KA, Schaapveld M, van Vulpen M, Battermann JJ, van der Poel H, van Oort IM, et al. Prostate brachytherapy and second primary cancer risk: a competitive risk analysis. *J Clin Oncol.* 2011;29(34):4510–5.
 88. Shah C, Lanni TB, Ghilezan MI, Gustafson GS, Marvin KS, Ye H, et al. Brachytherapy provides comparable outcomes and improved cost-effectiveness in the treatment of low/intermediate prostate cancer. *Brachytherapy.* 2012;11(6):441–5.
 89. Morton GC, Hoskin PJ. Brachytherapy: current status and future strategies -- Can high dose rate replace low dose rate and external beam radiotherapy? *Clin Oncol.* 2013;25(8):474–82.
 90. Hoskin PJ, Rojas AM, Bownes PJ, Lowe GJ, Ostler PJ, Bryant L. Randomised trial of external beam radiotherapy alone or combined with high-dose-rate brachytherapy boost for localised prostate cancer. *Radiother Oncol.* 2012;103(2):217–22.
 91. Morris WJ, Tyldesley S, Pai H, Halperin R, McKenzie M, Duncan G, et al. A multicenter, randomized trial of dose-escalated external beam radiation therapy (EBRT-B) versus low-dose-rate brachytherapy (LDR-B) for men with unfavorable-risk localized prostate cancer. *J Clin Oncol.* 2015;33(suppl7):abstr 3.
 92. Wang Y, Sankrecha R, Al-Hebshi A, Loblaw A, Morton G. Comparative study of dosimetry between high-dose-rate and permanent prostate implant brachytherapies in patients with prostate adenocarcinoma. *Brachytherapy.* 2006;5(4):251–5.
 93. Holly R, Morton GC, Sankrecha R, Law N, Cisecki T, Loblaw DA, et al. Use of cone-beam imaging to correct for catheter displacement in high dose-rate prostate brachytherapy. *Brachytherapy.* 2011;10(4):299–305.
 94. Lee WR. Permanent prostate brachytherapy: the significance of postimplant dosimetry. *Rev Urol.* 2004;6 Suppl 4:S49–56.
 95. Thrasher JB. Conformal high dose rate brachytherapy improves biochemical control and cause specific survival in patients with prostate cancer and poor prognostic factors: Editorial comment. Vol. 169, *Journal of Urology.* 2003. p. 979–80.
 96. Demanes DJ, Martinez AA, Ghilezan M, Hill DR, Schour L, Brandt D, et al. High-dose-rate monotherapy: Safe and effective brachytherapy for patients with localized prostate cancer. *Int J Radiat Oncol Biol Phys.* 2011;81(5):1286–92.
 97. Galalae RM, Martinez A, Nuernberg N, Edmundson G, Gustafson G, Gonzalez J, et al. Hypofractionated conformal HDR brachytherapy in hormone naïve men with localized prostate cancer: Is Escalation to very high biologically equivalent dose beneficial in all

- prognostic risk groups? *Strahlentherapie und Onkol.* 2006;182(3):135–41.
98. Yamada Y, Rogers L, Demanes DJ, Morton G, Prestidge BR, Pouliot J, et al. American Brachytherapy Society consensus guidelines for high-dose-rate prostate brachytherapy. *Brachytherapy.* 2012;11(1):20–32.
 99. Hoskin PJ, Colombo A, Henry A, Niehoff P, Paulsen Hellebust T, Siebert FA, et al. GEC/ESTRO recommendations on high dose rate afterloading brachytherapy for localised prostate cancer: An update. *Radiother Oncol.* 2013;107(3):325–32.
 100. Morton GC. High-dose-rate brachytherapy boost for prostate cancer: rationale and technique. *J Contemp Brachytherapy.* 2014;6(3):323–30.
 101. Michalski JM, Yan Y, Watkins-Bruner D, Bosch WR, Winter K, Galvin JM, et al. Preliminary toxicity analysis of 3-dimensional conformal radiation therapy versus intensity modulated radiation therapy on the high-dose arm of the Radiation Therapy Oncology Group 0126 prostate cancer trial. *Int J Radiat Oncol Biol Phys.* 2013;87(5):932–8.
 102. Ágoston P, Major T, Fröhlich G, Szabó Z, Lövey J, Fodor J, et al. Moderate dose escalation with single-fraction high-dose-rate brachytherapy boost for clinically localized intermediate- and high-risk prostate cancer: 5-year outcome of the first 100 consecutively treated patients. *Brachytherapy.* 2011;10(5):376–84.
 103. Aluwini S, Van Rooij PH, Kirkels WJ, Jansen PP, Praag JO, Bangma CH, et al. High-dose-rate brachytherapy and external-beam radiotherapy for hormone-naïve low- and intermediate-risk prostate cancer: A 7-year experience. *Int J Radiat Oncol Biol Phys.* 2012;83(5):1480–5.
 104. Bachand F, Martin AG, Beaulieu L, Harel F, Vigneault É. An Eight-Year Experience of HDR Brachytherapy Boost for Localized Prostate Cancer: Biopsy and PSA Outcome. *Int J Radiat Oncol Biol Phys.* 2009;73(3):679–84.
 105. Cury FL, Duclos M, Aprikian A, Patrocinio H, Kassouf W, Shenouda G, et al. Single-fraction high-dose-rate brachytherapy and hypofractionated external beam radiation therapy in the treatment of intermediate-risk prostate cancer - Long term results. *Int J Radiat Oncol Biol Phys.* 2012;82(4):1417–23.
 106. Deutsch I, Zelefsky MJ, Zhang Z, Mo Q, Zaider M, Cohen G, et al. Comparison of PSA relapse-free survival in patients treated with ultra-high-dose IMRT versus combination HDR brachytherapy and IMRT. *Brachytherapy.* 2010;9(4):313–8.
 107. Galalae RM, Zakikhany NH, Geiger F, Siebert FA, Bockelmann G, Schultze J, et al. The 15-year outcomes of high-dose-rate brachytherapy for radical dose escalation in

- patients with prostate cancer-A benchmark for high-tech external beam radiotherapy alone? *Brachytherapy*. 2014;13(2):117–22.
108. Ghadjar P, Rentsch CA, Isaak B, Behrensmeier F, Thalmann GN, Aebbersold DM. Urethral toxicity vs. cancer control-Lessons to be learned from high-dose rate brachytherapy combined with intensity-modulated radiation therapy in intermediate- and high-risk prostate cancer. *Brachytherapy*. 2011;10(4):286–94.
 109. Kaprealian T, Weinberg V, Speight JL, Gottschalk AR, Roach M, Shinohara K, et al. High-dose-rate brachytherapy boost for prostate cancer: Comparison of two different fractionation schemes. *Int J Radiat Oncol Biol Phys*. 2012;82(1):222–7.
 110. Khor R, Duchesne G, Tai KH, Foroudi F, Chander S, Van Dyk S, et al. Direct 2-arm comparison shows benefit of high-dose-rate brachytherapy boost vs external beam radiation therapy alone for prostate cancer. Vol. 85, *International Journal of Radiation Oncology Biology Physics*. 2013. p. 679–85.
 111. Kotecha R, Yamada Y, Pei X, Kollmeier MA, Cox B, Cohen GN, et al. Clinical outcomes of high-dose-rate brachytherapy and external beam radiotherapy in the management of clinically localized prostate cancer. *Brachytherapy*. 2013;12(1):44–9.
 112. Lilleby W, Tafjord G, Raabe NK. Implementation of high-dose-rate brachytherapy and androgen deprivation in patients with prostate cancer. *Int J Radiat Oncol Biol Phys*. 2012;83(3):933–9.
 113. Marina O, Gustafson GS, Kestin LL, Brabbins DS, Chen PY, Ye H, et al. Comparison of dose-escalated, image-guided radiotherapy vs. dose-escalated, high-dose-rate brachytherapy boost in a modern cohort of intermediate-risk prostate cancer patients. *Brachytherapy*. 2014;13(1):59–67.
 114. Martinez-Monge R, Moreno M, Ciervide R, Cambeiro M, Perez-Gracia JL, Gil-Bazo I, et al. External-beam radiation therapy and high-dose rate brachytherapy combined with long-term androgen deprivation therapy in high and very high prostate cancer: preliminary data on clinical outcome. *Int J Radiat Oncol Biol Phys*. 2012;82(3):e469-76.
 115. Morton G, Loblaw A, Cheung P, Szumacher E, Chahal M, Danjoux C, et al. Is single fraction 15 Gy the preferred high dose-rate brachytherapy boost dose for prostate cancer? *Radiother Oncol*. 2011;100(3):463–7.
 116. Neviani CB, Miziara MA, De Andrade Carvalho H. Results of high dose-rate brachytherapy boost before 2D or 3D external beam irradiation for prostate cancer. *Radiother Oncol*. 2011;98(2):169–74.

117. Pellizzon AC, Salvajoli J, Novaes P, Maia M, Fogaroli R. Updated results of high-dose rate brachytherapy and external beam radiotherapy for locally and locally advanced prostate cancer using the RTOG-ASTRO Phoenix definition. *Int Braz J Urol.* 2008;34(3):293–301.
118. Phan TP, Syed AM, Puthawala A, Sharma A, Khan F. High dose rate brachytherapy as a boost for the treatment of localized prostate cancer. *J Urol.* 2007;177(1):123–7; discussion 127.
119. Pistis F, Guedea F, Pera J, Gutierrez C, Ventura M, Polo A, et al. External beam radiotherapy plus high-dose-rate brachytherapy for treatment of locally advanced prostate cancer: The initial experience of the Catalan Institute of Oncology. *Brachytherapy.* 2010;9(1):15–22.
120. Prada PJ, González H, Fernández J, Jiménez I, Iglesias A, Romo I. Biochemical outcome after high-dose-rate intensity modulated brachytherapy with external beam radiotherapy: 12 years of experience. *BJU Int.* 2012;109(12):1787–93.
121. Savdie R, Symons J, Spornat D, Yuen C, Pe Benito R a, Haynes A-M, et al. High-dose rate brachytherapy compared with open radical prostatectomy for the treatment of high-risk prostate cancer: 10 year biochemical freedom from relapse. *BJU Int.* 2012;110:71–6.
122. Whalley D, Patanjali N, Jackson M, Lovett A, Chatfield M, Hruby G. HDR brachytherapy combined with external beam radiation for localised prostate cancer: Early experience from the Sydney Cancer Centre. *J Med Imaging Radiat Oncol.* 2012;56(2):220–6.
123. Zwahlen DR, Andrianopoulos N, Matheson B, Duchesne GM, Millar JL. High-dose-rate brachytherapy in combination with conformal external beam radiotherapy in the treatment of prostate cancer. *Brachytherapy.* 2010;9(1):27–35.
124. Holm HH GJ. Ultrasonically guided precise needle placement in the prostate and the seminal vesicles. *J Urol.* 1981;125:385–7.
125. Batchelar D, Gaztañaga M, Schmid M, Araujo C, Bachand F, Crook J. Validation study of ultrasound-based high-dose-rate prostate brachytherapy planning compared with CT-based planning. *Brachytherapy.* 2014;13(1):75–9.
126. Batchelar DL, Chung HT, Loblaw A, Law N, Cisecki T, Morton GC. Intraoperative ultrasound-based planning can effectively replace postoperative CT-based planning for high-dose-rate brachytherapy for prostate cancer. *Brachytherapy.* 2016;15(4):399–405.
127. Damore SJ, Syed AM, Puthawala AA, Sharma A. Needle displacement during HDR

- brachytherapy in the treatment of prostate cancer. *Int J Radiat Oncol Biol Phys.* 2000;46(5):1205–11.
128. Bowes D, Crook JM, Araujo C, Batchelar D. Ultrasound-CT fusion compared with MR-CT fusion for postimplant dosimetry in permanent prostate brachytherapy. *Brachytherapy.* 2013;12(1):38–43.
 129. Schmid M, Crook JM, Batchelar D, Araujo C, Petrik D, Kim D HR. A phantom study to assess accuracy of needle identification in real-time planning of ultrasound-guided high-dose-rate prostate implants. *Brachytherapy.* 2013;12(1):56–64.
 130. Kim Y, Hsu ICJ, Pouliot J. Measurement of craniocaudal catheter displacement between fractions in computed tomography-based high dose rate brachytherapy of prostate cancer. *J Appl Clin Med Phys.* 2007;8(4):2415.
 131. Tiong A, Bydder S, Ebert M, Caswell N, Waterhouse D, Spry N, et al. A small tolerance for catheter displacement in high-dose rate prostate brachytherapy is necessary and feasible. *Int J Radiat Oncol Biol Phys.* 2010 Mar 15;76(4):1066–72.
 132. Akin O, Hricak H. *Imaging of Prostate Cancer.* Vol. 45, *Radiologic Clinics of North America.* 2007. p. 207–22.
 133. de Rooij M, Hamoen EHJ, Witjes JA, Barentsz JO, Rovers MM. Accuracy of Magnetic Resonance Imaging for Local Staging of Prostate Cancer: A Diagnostic Meta-analysis. *Eur Urol.* 2016;70(2):233–45.
 134. Want L, Hricak H, Kattan MW, Chen H, Scardino PT, Kuroiwa K. Prediction of Organ-confined Prostate Cancer : Incremental Value of MR Imaging and MR Spectroscopic Imaging to Staging Nomograms 1. *Radiology.* 2006;238(2):597–603.
 135. Hamoen EHJ, de Rooij M, Witjes JA, Barentsz JO, Rovers MM. Use of the Prostate Imaging Reporting and Data System (PI-RADS) for Prostate Cancer Detection with Multiparametric Magnetic Resonance Imaging: A Diagnostic Meta-analysis. *Eur Urol.* 2014;67(6):1112–21.
 136. Barentsz JO, Richenberg J, Clements R, Choyke P, Verma S, Villeirs G, et al. ESUR prostate MR guidelines 2012. *Eur Radiol.* 2012;22(4):746–57.
 137. Barentsz JO, Weinreb JC, Verma S, Thoeny HC, Tempany CM, Shtern F, et al. Synopsis of the PI-RADS v2 Guidelines for Multiparametric Prostate Magnetic Resonance Imaging and Recommendations for Use. Vol. 69, *European Urology.* 2016. p. 41–9.
 138. Weinreb JC, Barentsz JO, Choyke PL, Cornud F, Haider MA, Macura KJ, et al. PI-RADS Prostate Imaging - Reporting and Data System: 2015, Version 2. *Eur Urol.* 2016;69(1):16–40.

139. Hegde J V., Mulkern R V., Panych LP, Fennessy FM, Fedorov A, Maier SE, et al. Multiparametric MRI of prostate cancer: An update on state-of-the-art techniques and their performance in detecting and localizing prostate cancer. Vol. 37, *Journal of Magnetic Resonance Imaging*. 2013. p. 1035–54.
140. McLaughlin PW, Evans C, Feng M, Narayana V. Radiographic and Anatomic Basis for Prostate Contouring Errors and Methods to Improve Prostate Contouring Accuracy. *Int J Radiat Oncol Biol Phys*. 2010;76(2):369–78.
141. McLaughlin PW, Troyer S, Berri S, Narayana V, Meirowitz A, Roberson PL, et al. Functional anatomy of the prostate: Implications for treatment planning. *Int J Radiat Oncol Biol Phys*. 2005;63(2):479–91.
142. Fuchsjäger MH, Pucar D, Zelefsky MJ, Zhang Z, Mo Q, Ben-Porat LS, et al. Predicting post-external beam radiation therapy PSA relapse of prostate cancer using pretreatment MRI. *Int J Radiat Oncol Biol Phys*. 2010;78(3):743–50.
143. Riaz N, Afaq A, Akin O, Pei X, Kollmeier MA, Cox B, et al. Pretreatment endorectal coil magnetic resonance imaging findings predict biochemical tumor control in prostate cancer patients treated with combination brachytherapy and external-beam radiotherapy. *Int J Radiat Oncol Biol Phys*. 2012;84(3):707–11.
144. McPartlin AJ, Li XA, Kershaw LE, Heide U, Kerkmeijer L, Lawton C, et al. MRI-guided prostate adaptive radiotherapy - A systematic review. *Radiotherapy and Oncology*. 2016;
145. DiBiase SJ, Hosseinzadeh K, Gullapalli RP, Jacobs SC, Naslund MJ, Sklar GN, et al. Magnetic resonance spectroscopic imaging-guided brachytherapy for localized prostate cancer. *Int J Radiat Oncol Biol Phys*. 2002;52(2):429–38.
146. Verma S, Turkbey B, Muradyan N, Rajesh A, Cornud F, Haider MA, et al. Overview of dynamic contrast-enhanced MRI in prostate cancer diagnosis and management. Vol. 198, *American Journal of Roentgenology*. 2012. p. 1277–88.
147. Bloch BN, Furman-Haran E, Helbich TH, Lenkinski RE, Degani H, Kratzik C, et al. Prostate cancer: accurate determination of extracapsular extension with high-spatial-resolution dynamic contrast-enhanced and T2-weighted MR imaging--initial results. *Radiology*. 2007;245(1):176–85.
148. Ménard C, Susil RC, Choyke P, Gustafson GS, Kammerer W, Ning H, et al. MRI-guided HDR prostate brachytherapy in standard 1.5T scanner. *Int J Radiat Oncol Biol Phys*. 2004;59(5):1414–23.
149. Ménard C, Iupati D, Publicover J, Lee J, Abed J, O’Leary G, et al. MR-guided prostate

- biopsy for planning of focal salvage after radiation therapy. *Radiology*. 2015;274(1):181–91.
150. Susil RC, Camphausen K, Choyke P, McVeigh ER, Gustafson GS, Ning H, et al. System for prostate brachytherapy and biopsy in a standard 1.5 T MRI scanner. *Magn Reson Med*. 2004;52(3):683–7.
 151. Murgic J, Chung P, Bayley A, Elantholi Parameswaran S, Warde P, Catton C, Simeonov A, Abed J, Rink A MC. MRI-guided brachytherapy boost for prostate cancer. *Radiother Oncol*. 2015;116(suppl. 1).
 152. Steiger P, Thoeny HC. Prostate MRI based on PI-RADS version 2: How we review and report. Vol. 16, *Cancer Imaging*. 2016.
 153. Morton GC, Loblaw DA, Chung H, Tsang G, Sankrecha R, Deabreu A, et al. Health-related quality of life after single-fraction high-dose-rate brachytherapy and hypofractionated external beam radiotherapy for prostate cancer. *Int J Radiat Oncol Biol Phys*. 2011;80(5):1299–305.
 154. Morton GC, Loblaw DA, Sankrecha R, Deabreu A, Zhang L, Mamedov A, Cheung P, Keller B, Danjoux C, Szumacher E TG. Single-fraction high-dose-rate brachytherapy and hypofractionated external beam radiotherapy for men with intermediate-risk prostate cancer: analysis of short- and medium-term toxicity and quality of life. *Int J Radiat Oncol Biol Phys*. 2010;77(3):811–7.
 155. U.S.Department of Health and Human Services Common Terminology Criteria for Adverse Events (CTCAE) Version 4.0. 2010; Available from: https://evs.nci.nih.gov/ftp1/CTCAE/CTCAE_4.03_2010-06-14_QuickReference_5x7.pdf
 156. Wei JT, Dunn RL, Litwin MS, Sandler HM, Sanda MG. Development and validation of the Expanded Prostate Cancer Index Composite (EPIC) for comprehensive assessment of health-related quality of life in men with prostate cancer. *Urology*. 2000;56(6):899–905.
 157. Barry MJ, Fowler FJ, O’Leary MP, Bruskewitz RC, Holtgrewe HL, Mebust WK, et al. The American Urological Association symptom index for benign prostatic hyperplasia. The Measurement Committee of the American Urological Association. *J Urol*. 1992;148(5):1549–1557; discussion 1564.
 158. Roach M, Hanks G, Thames H, Schellhammer P, Shipley WU, Sokol GH, et al. Defining biochemical failure following radiotherapy with or without hormonal therapy in men with clinically localized prostate cancer: Recommendations of the RTOG-ASTRO

- Phoenix Consensus Conference. *Int J Radiat Oncol Biol Phys*. 2006;65(4):965–74.
159. Chang JH, Lim Joon D, Nguyen BT, Hiew CY, Esler S, Angus D, et al. MRI scans significantly change target coverage decisions in radical radiotherapy for prostate cancer. *J Med Imaging Radiat Oncol*. 2014;58(2):237–43.
 160. Hsu IC, Bae K, Shinohara K, Pouliot J, Purdy J, Ibbott G, et al. Phase II trial of combined high-dose-rate brachytherapy and external beam radiotherapy for adenocarcinoma of the prostate: Preliminary results of RTOG 0321. *Int J Radiat Oncol Biol Phys*. 2010;78(3):751–8.
 161. Hsu IC, Hunt D, Straube W, Pouliot J, Cunha A, Krishnamurthy D, et al. Dosimetric analysis of radiation therapy oncology group 0321: The importance of urethral dose. *Pract Radiat Oncol*. 2014;4(1):27–34.
 162. Åström L, Pedersen D, Mercke C, Holmäng S, Johansson KA. Long-term outcome of high dose rate brachytherapy in radiotherapy of localised prostate cancer. *Radiother Oncol*. 2005;74(2):157–61.
 163. Sullivan L, Williams SG, Tai KH, Foroudi F, Cleeve L, Duchesne GM. Urethral stricture following high dose rate brachytherapy for prostate cancer. *Radiother Oncol*. 2009;91(2):232–6.
 164. Hindson BR, Millar JL, Matheson B. Urethral strictures following high-dose-rate brachytherapy for prostate cancer: Analysis of risk factors. *Brachytherapy*. 2013;12(1):50–5.
 165. McLaughlin PW N V. High-dose-rate strictures: A theory of cancer meets anatomic reality. *Brachytherapy*. 2013;12:199–201.
 166. Boyea GAJ, Wallace M, Ghilezan M et al. The role of needle trauma in the development of urinary toxicity following prostate high dose rate (HDR) brachytherapy. *Int J Radiat Oncol Biol Phys*. 2007;69(suppl.):357–8.
 167. Andreoiu M, Cheng L. Multifocal prostate cancer: biologic, prognostic, and therapeutic implications. Vol. 41, *Human Pathology*. 2010. p. 781–93.
 168. Cellini N, Morganti AG, Mattiucci GC, Valentini V, Leone M, Luzi S, et al. Analysis of intraprostatic failures in patients treated with hormonal therapy and radiotherapy: Implications for conformal therapy planning. *Int J Radiat Oncol Biol Phys*. 2002;53(3):595–9.
 169. Bauman G, Haider M, Van Der Heide UA, Ménard C. Boosting imaging defined dominant prostatic tumors: A systematic review. Vol. 107, *Radiotherapy and Oncology*. 2013. p. 274–81.

170. Gomez-Iturriaga A, Casquero F, Urresola A, Ezquerro A, Lopez JI, Espinosa JM, et al. Dose escalation to dominant intraprostatic lesions with MRI-transrectal ultrasound fusion High-Dose-Rate prostate brachytherapy. Prospective phase II trial. *Radiother Oncol.* 2016;119(1):91–6.
171. McNeal JE. The Zonal Anatomy of the Prostate. *Prostate.* 1981;2(1981):35–49.
172. Terris MK, Freiha FS, McNeal JE, Stamey TA. Efficacy of transrectal ultrasound for identification of clinically undetected prostate cancer. *J Urol.* 1991;146(1):78-83-4.
173. Koppie TM, Bianco FJ, Kuroiwa K, Reuter VE, Guillonneau B, Eastham JA, et al. The clinical features of anterior prostate cancers. Vol. 98, *BJU International.* 2006. p. 1167–71.
174. Mygatt J, Sesterhenn I, Rosner I, Chen Y, Cullen J, Morris-Gore T, et al. Anterior tumors of the prostate: clinicopathological features and outcomes. *Prostate Cancer Prostatic Dis.* 2014;17(1):75–80.
175. Da Rosa MR, Milot L, Sugar L, Vesprini D, Chung H, Loblaw A, et al. A prospective comparison of MRI-US fused targeted biopsy versus systematic ultrasound-guided biopsy for detecting clinically significant prostate cancer in patients on active surveillance. *J Magn Reson Imaging.* 2015;41(1):220–5.
176. Wang Y, Cheng JZ, Ni D, Lin M, Qin J, Luo X, et al. Towards personalized statistical deformable model and hybrid point matching for robust MR-TRUS registration. *IEEE Trans Med Imaging.* 2016;35(2):589–604.
177. Marks L, Young S, Natarajan S. MRI-ultrasound fusion for guidance of targeted prostate biopsy. *Curr Opin Urol.* 2013;23(1):43–50.
178. Baco E, Ukimura O, Rud E, Vlatkovic L, Svindland A, Aron M, et al. Magnetic resonance imaging-transectal ultrasound image-fusion biopsies accurately characterize the index tumor: Correlation with step-sectioned radical prostatectomy specimens in 135 patients. *Eur Urol.* 2015;67(4):787–94.
179. Muntener M, Patriciu A, Petrisor D, Mazilu D, Bagga H, Kavoussi L, et al. Magnetic resonance imaging compatible robotic system for fully automated brachytherapy seed placement. *Urology.* 2006;68(6):1313–7.
180. van den Bosch MR, Moman MR, van Vulpen M, Battermann JJ, Duiveman E, van Schelven LJ, et al. MRI-guided robotic system for transperineal prostate interventions: proof of principle. *Phys Med Biol.* 2010;55:N133–40.
181. Buus S, Rylander S, Hokland S, Søndergaard CS, Pedersen EM, Tanderup K, et al. Learning curve of MRI-based planning for high-dose-rate brachytherapy for prostate

- cancer. *Brachytherapy*. 2016;15(4):426–34.
182. Hosni A, Carlone M, Rink A, Menard C, Chung P BA. Dosimetric feasibility of ablative dose escalated focal monotherapy with MRI-guided high-dose-rate (HDR) brachytherapy for prostate cancer. *Radiother Oncol*. 2017;122(1):103–8.
183. Tokuda J, Fischer GS, DiMaio SP, Gobbi DG, Csoma C, Mewes PW, et al. Integrated navigation and control software system for MRI-guided robotic prostate interventions. *Comput Med Imaging Graph*. 2010;34(1):3–8.
184. Brock KK, Nichol AM, Menard C, Moseley JL, Warde PR, Catton CN J DA. Accuracy and sensitivity of finite element model-based deformable registration of the prostate. *Med Phys*. 2008;35(9):4019–25.

12. CURRICULUM VITAE

I was born in Zagreb, Croatia where I have obtained MD degree at the University of Zagreb Medical School in 2002. Currently, I am in final phase of completing PhD programme in Biomedicine and Health Sciences at the same medical school.

In 2005 I have started residency in clinical oncology and radiotherapy at the University Hospital Centre Sisters of Mercy in Zagreb. Upon graduation in 2009 I have been working as consultant clinical oncologist in the same department.

During 2011-2012 I worked at the University of Michigan Department of Radiation Oncology and Division of Nuclear Medicine, as the clinical research fellow in prostate cancer radiotherapy and in novel response assessment tools for Non-Hodgkin-Lymphoma (mentors: Dr. Daniel Hamstra and Dr. Anca Avram). During 2014 and 2015, as elected clinical fellow, I joined prostate brachytherapy, GU oncology and cancer genomics program in Princess Margaret Hospital, Department of Radiation Oncology University of Toronto, Canada, and worked under mentorship of Dr. Cynthia Ménard and Dr. Rob Bristow, world leaders in prostate cancer medicine.

I have published 10 original research papers in relevant international journals, contributed chapter for Springer-published book on controversies in radiotherapy, and got 2016 Conquer Cancer Foundation GU ASCO Merit Award for the presented research in novel prognostic factors in prostate cancer.