

Non-surgical removal of some stones from a red tailed catfish (*Phractocephalus hemioliopterus*) stomach as gastric foreign bodies

H. Ebrahimzadeh Mousavi^{1*} ; A.R. Vajhi¹ ; F. Hosseini¹ ;
I. Sharifpour² and P. Tajik¹

hmosavi@ut.ac.ir

1- Faculty of Veterinary Medicine, University of Tehran,
P.O.Box:14155-6453 Tehran, Iran

2- Iranian Fisheries Research Organization, P.O.Box:14155-6116
Tehran, Iran

Received: January 2006

Accepted: May 2006

Abstract: A red-tailed catfish (*Phractocephalus hemioliopterus*) referred to Aquatic Animal Health Department, Faculty of Veterinary Medicine, University of Tehran for showing lethargy, bottom sitting, extension of abdomen and sever abdominal injuries. Its abdomen was swollen and the bulk of the foreign bodies were easily palpated. The heaviness of foreign bodies had made swimming and buoyancy difficult for fish. Several radiographic images were taken after anaesthetizing the catfish with 10% carvacrol, 2 drops in 1 liter of water. Radiographs revealed some stones with their size, number and location. Stones were removed non-surgically through the large oral cavity using suitable forceps. Totally 16 stones and 2 shells were removed from the stomach of the fish. The catfish was then returned to the water where normal swimming and buoyancy was restored.

Keywords: catfish, stones, foreign body, radiography

* Corresponding author

Introduction

Catfish probably are the most variable group of fishes in the world. Approximately, 34 families of catfishes are recognized (Helfman *et al.*, 1997). They are found almost universally where other fishes exist, and show many adaptations (Axelord *et al.*, 1987). Different kinds of catfishes exist in Iran (in most rivers, the Caspian Sea and Persian Gulf). However, some catfish are kept as ornamental fish by hobbyist (Etemad & Mokhayer, 1990). Almost all catfishes are benthic and feed from bottom. Having large mouths, they ingest foreign matters to identify their edibility, and then spit it out (Wildgoose, 2001). Under certain circumstances such as poor nutrition in both wild and aquarium, some foreign bodies may become trapped in the digestive system and therefore require removal (Lewbart, 1998). Treatment of such problem is unusual in fish medicine. There are not so many reports indicating that foreign bodies being lodged in the stomach of fishes (Clark, 1988 ; Earl, 1988 ; Lewbart, 1998).

The present report describes the diagnosis and treatment of a catfish, with large amount of foreign bodies in the stomach.

Materials and Methods

A red-tailed catfish (*Phractocephalus hemioliopterus*) called "Red" was referred to Aquatic Animal Health Department, Faculty of Veterinary Medicine, University of Tehran on 17 July 2005, for having swallowed some foreign bodies 5 days earlier. The fish was about 30 cm long, weighed 420 grams (with foreign bodies) and had been kept in an indoor aquarium for five months (Figure 1). The abdomen of fish was swollen and the bulk of the foreign bodies were easily palpated. The heaviness of the foreign bodies had made swimming and buoyancy difficult for the fish and also caused severe erosion in ventral surface of abdomen because of the pressure on fish against the aquarium stony bottom during swimming (Fig. 2).

The catfish was carefully anaesthetized with 10% carvacrol (Dentol) 2 drops in 1 liter of water. Radiographs were taken to establish the size, numbers and location of the foreign bodies.



Figure 1

Figure 1: Dorsal view of red catfish showing swollen abdomen

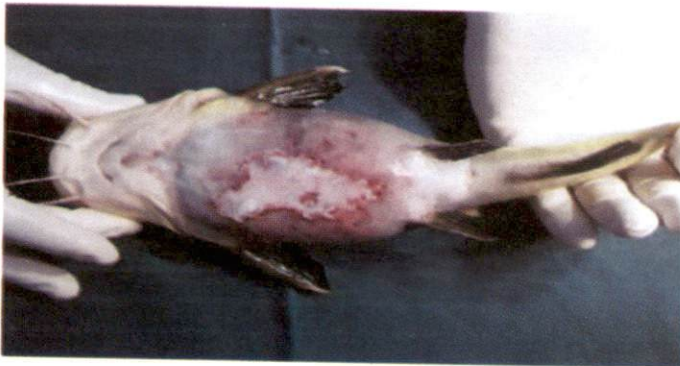

Figure 2

Figure 2: Ventral view of red catfish showing severe skin erosion

Results

Lateral and dorso-ventral views revealed some large radiopaque masses in abdomen. Large pockets of gas due to inflation of the swim bladder were also visible (Figs. 3&4). After opening the mouth, the large oral cavity of the fish made it easy to inspect the internal bulk of the foreign fragments. The pieces of foreign bodies were grasped firmly and carefully pulled out through the mouth using forceps (Figure 5). Totally 16 stones (the largest stone was 5.5 cm and the smallest

1cm length) and 2 shells were removed from stomach of the fish (Figure 6). The fish was then returned to the water where it got active and showed normal buoyancy.

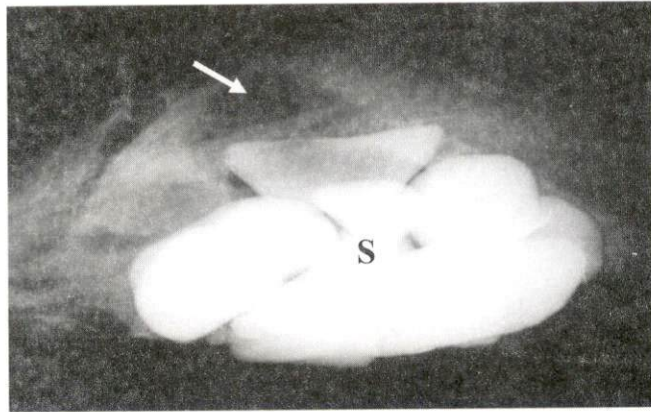


Figure 3: Lateral radiograph of catfish showing radiopaque foreign bodies (stones) in abdomen (S) and also over-inflated swim bladder (arrow)

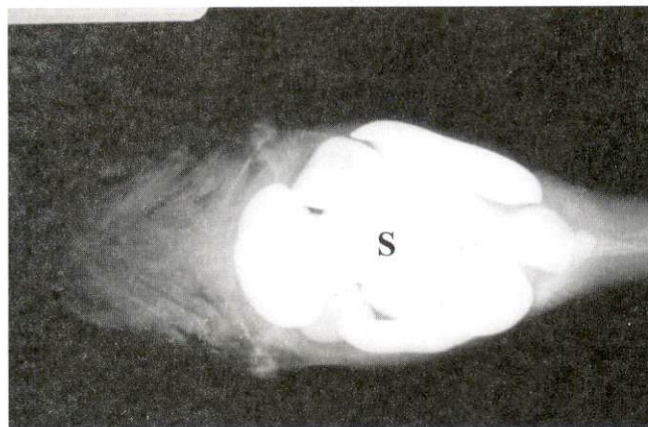


Figure 4: Dorso-ventral radiograph of catfish showing mass of stones (S)

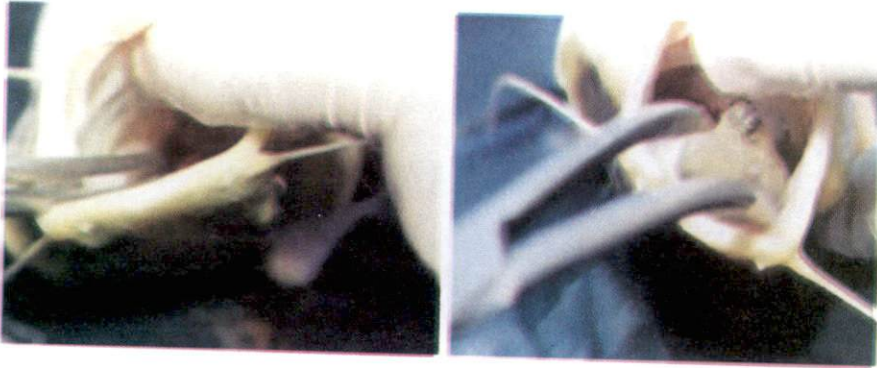


Fig. 5

Figure 5: Grasping (A) and pulling out (B) the pieces of stones through the mouth by forceps



Fig. 6

Figure 6: The red tailed catfish following successful non-surgical removal of the foreign bodies

Discussion

A few reports indicating pieces of gravel becoming lodged in the mouth of gold fish (*Carassius auratus*) have been published (Clark, 1988 ; Macholc, 1988). In all cases the fish had difficulty in swimming and required manual removal of the gravel with forceps (Earl, 1988). The authors have previously observed a goldfish

with gravel which was dislodged during transportation to the practice room. The goldfish showed no physical damage afterward.

It has been suggested that gravel should be removed from aquaria since most red-tailed catfish swallow substantial quantities of bottom fragments (Sands, 1995). The species also move objects around the tank and this is considered to be due to boredom or territorial display. A survey by the red tailed catfish club records a variety of non-food item swallowed including filter pipes, rubber suckers and even a pair of sunglasses (Scott, 1992). Most items were regurgitated within a week although the sunglasses were removed manually under anesthesia. Lewbart (1998) described gastric foreign bodies as fish hooks in bonnet-head shark. He used his hand to grasp and remove the foreign object. He suggested that when objects are deeply digested and are out of reach, the stomach lining can be pulled by fingers to bring the objects closer to be able to remove them. Catfish are physostomous and control the amount of gas in the swim bladder by the pneumatic duct which lies on the right side of esophagus near the stomach. Any interference or obstruction of this duct may result in over or under-inflation of the swim bladder and interfere with buoyancy control. It is also possible that the fish attempted to improve its buoyancy by actively over-inflating the swim bladder to compensate for the additional weight of the stones around 120 grams.

References

- Axelord, H.R. ; Burgss, W.E. ; Emmens, C.W. ; Pronek, N. ; Walls, J.G. and Hunziker, R. , 1987.** Dr. Axelord's Mini Atlas of freshwater aquarium fishes, Mini-Edition., T.F.H Publication. 480P.
- Clark, P.J. , 1988.** Oral obstruction in a goldfish. *Veterinary Record*. Vol. 122, No. 13, 311P.
- Earl, J.A. , 1988.** Oral obstruction in a goldfish. *Veterinary Record*. Vol. 122, No. 13, 400P.
- Etemad, E. and Mokhayer, B. , 1990.** Fish of the Iranian Gulf. University of Tehran Press. 422P.

- Helfman, G.S. ; Collette, B.B. and Facey D.E. , 1997.** The Diversity of Fishes. Blackwell Science Press. 285P.
- Lewbart, G.A. , 1998.** Self Assessment Color Review of Ornamental Fish. Manson Publishing. 192P.
- Machole, E.J. , 1988.** Oral obstruction in a goldfish. Veterinary Record. Vol. 122, No. 14, 340P.
- Sands, D.D. , 1995.** The handbook of the red tailed catfish. Red Tailed Catfish Club/Aquarium Advisory Service, Melton Mowbray. 134P.
- Scott, P.W. , 1992.** Making a spectacle. Veterinary Record. Vol. 130, No. 11, 232P.
- Wildgoose, W.H. , 2001.** BASVA manual of ornamental fish. BASVA Publication. 304P.