



Local infusion of *Staphylococcus aureus* into the porcine internal carotid artery as a model of sepsis-related brain abscesses - A pilot study

Astrup, Lærke B.; Iburg, Tine M.; Agerholm, Jørgen S.; Aalbæk, Bent; Nielsen, Ole L.; Leifsson, Pall S.

Published in:
Scandinavian Journal of Laboratory Animal Science

Link to article, DOI:
[10.23675/sjlas.v43i0.492](https://doi.org/10.23675/sjlas.v43i0.492)

Publication date:
2017

Document Version
Publisher's PDF, also known as Version of record

[Link back to DTU Orbit](#)

Citation (APA):
Astrup, L. B., Iburg, T. M., Agerholm, J. S., Aalbæk, B., Nielsen, O. L., & Leifsson, P. S. (2017). Local infusion of *Staphylococcus aureus* into the porcine internal carotid artery as a model of sepsis-related brain abscesses - A pilot study. *Scandinavian Journal of Laboratory Animal Science*, 43(7), [7].
<https://doi.org/10.23675/sjlas.v43i0.492>

General rights

Copyright and moral rights for the publications made accessible in the public portal are retained by the authors and/or other copyright owners and it is a condition of accessing publications that users recognise and abide by the legal requirements associated with these rights.

- Users may download and print one copy of any publication from the public portal for the purpose of private study or research.
- You may not further distribute the material or use it for any profit-making activity or commercial gain
- You may freely distribute the URL identifying the publication in the public portal

If you believe that this document breaches copyright please contact us providing details, and we will remove access to the work immediately and investigate your claim.



Original scientific article

Local infusion of *Staphylococcus aureus* into the porcine internal carotid artery as a model of sepsis-related brain abscesses – a pilot study

By Lærke B. Astrup^{1,2*}, Tine M. Iburg^{1,2}, Jørgen S. Agerholm^{1,3}, Bent Aalbæk¹, Henrik E. Jensen¹, Ole L. Nielsen¹, Pall S. Leifsson¹

¹ Department of Veterinary and Animal Sciences, Faculty of Health and Medical Sciences, University of Copenhagen, Grønnegårdsvej 15, DK-1870 Frederiksberg C, Denmark

² Section for Diagnostics and Scientific Advice, National Veterinary Institute, Technical University of Denmark, Anker Engelunds Vej, 2800 Lyngby, Denmark.

³ Department of Veterinary Clinical Sciences, Faculty of Health and Medical Sciences, University of Copenhagen, Dyrlægevej 68, DK-1870 Frederiksberg C, Denmark.

*Correspondence: Lærke B. Astrup (boyeastrup@gmail.com)

Department of Veterinary and Animal Sciences, Faculty of Health and Medical Sciences, University of Copenhagen, Grønnegårdsvej 15, DK-1870 Frederiksberg C, Denmark

Summary

Brain pathology is an important aspect of human sepsis but is difficult to study in human patients. Therefore, animal models of sepsis-related brain pathology are needed. As pigs mirror multiple aspects of sepsis-related brain pathology in humans, this makes the pig a potentially suitable model. Unfortunately, models of sepsis in pigs are difficult to manage due to the accompanying massive systemic inflammatory response. To overcome these difficulties we designed a model in pigs of brain bacteremia established by local brain infusion in order to evaluate if this approach could reduce the systemic responses but still reflect the brain pathology of sepsis in humans. As a pilot study to obtain basic knowledge, we evaluated two methods of local infusion: long term infusion (60 minutes) of *Staphylococcus aureus* suspended in saline and, short-term infusion (10 minutes) of *S. aureus* embedded in autologous microthrombi.

The study revealed: 1) bacteria suspended in saline as well as embedded in microthrombi can pass through the *rete mirabile* and thereby cause local brain bacteremia; 2) despite the high dose of *S. aureus* used for infusion, only mild clinical signs developed; and 3) despite the mild clinical signs, one pig had developed a brain microabscess by 48 h after infusion. The brain pathology present in this pig thereby reflected human cases of *S. aureus*-sepsis with microabscess formation as the predominant lesion. In addition, the abscess morphology mirrored previously observed microabscesses in experimental porcine *S. aureus* sepsis models.

Introduction

During sepsis, brain microabscesses may develop as bacteria are transported hematogenously to the brain, either as free bacteria or within emboli. The development of brain microabscesses characterizes sepsis-related brain lesions in man (Pendlebury *et al.*,

1989; Sharshar *et al.*, 2004). However, the development of sepsis-related brain pathology is difficult to study in detail in human patients thus necessitating animal models (Pendlebury *et al.*, 1989; Sharshar *et al.*, 2003). The pig is a suitable model animal as brain

microabscesses have been shown to develop in various scenarios of blood-borne spread of bacteria to the porcine brain (Bogdanski *et al.*, 2000; Astrup *et al.*, 2013; Christiansen *et al.*, 2013a), similar to that described in humans. Furthermore, the well-established association between infective valvular endocarditis and the development of brain microabscesses in humans has been observed in experimental porcine sepsis as well (Tunkel & Kaye, 1993; Azuma *et al.*, 2009; Christiansen *et al.*, 2013a). Unfortunately, models of sepsis in pigs are difficult to manage due to the development of a massive systemic inflammatory response, which causes both animal welfare concerns and technical challenges (Nemzek *et al.* 2008; Leifsson *et al.*, 2010; Soerensen *et al.*, 2012). We hypothesized that these difficulties might be reduced by a local model approach. A local model approach that applies infusion of bacteria directly into the blood supply of the brain will provide two advantages. 1) Local infusion will ensure a full-dose exposure of bacteria to the brain. 2) Local infusion will concurrently reduce the systemic exposure as the infected blood is filtered through the lungs before entering the systemic circulation, thus presenting the blood to the pulmonary intravascular macrophages, which rapidly eliminate large quantities of bacteria from the blood (Soerensen *et al.*, 2012). However, it is difficult to establish local infusion of bacteria to the porcine brain as pigs have a microarteriolar meshwork - the *rete mirabile* - at the vascular entrance to the brain (Haaland & Orderud, 1995). The *rete mirabile* hinders insertion of intra-arterial microcatheters beyond the level of the internal carotid artery (ICA) in pigs (Reinert *et al.*, 2005).

We therefore conducted a pilot study based on three pigs to investigate if it is possible to establish local brain bacteremia through infusion of *S. aureus* into the ICA without causing severe sepsis.

Methods

Animal ethics

The study was approved by the Danish Animal Experimental Inspectorate, Danish Ministry of Food, Agriculture and Fisheries (license no. 2010/561–1916). The following humane end-points were applied: reluctance to eat, drink, rise and move normally. These humane endpoints were assessed as described below in the “post-operative procedures” section.

Overall experimental design

During anesthesia, pigs were infused with *S. aureus* directly into the ICA. Two infusion methods were

tested: long-term infusion (60 minutes) of bacteria suspended in saline (Fig 1) and short-term infusion (10 minutes) of bacteria embedded in autologous microthrombi (Figs 2 and 3). The pigs were allowed to recover from anesthesia and were monitored until euthanasia after 24 h (Figs 1 and 2) or 48 h (Fig 3). Then pigs were necropsied and examined by histology, immunohistochemistry (IHC) and bacteriological culture.

Animals

Three male Göttingen minipigs (Ellegaard Göttingen Minipigs A/S, Dalmose, Denmark) at the age of 2 months and with a bodyweight (BW) of 4.5–5.5 kg were used. The pigs were housed in the Laboratory Animal Isolation Unit at the University of Copenhagen during the entire study. The stables had a 12/12 h light rhythm and the area per pig was 3.41 m². The pens were provided with abundant straw bedding and pig toys. The pigs were acclimatized for 7 days and fed the same diet as used by the pig supplier. The pigs were clinically examined 48 h before infusion and a blood sample was taken. They were fasted for 24 h before surgery, but had access to water *ad libitum* at all times. The pigs were housed together until surgery. After surgery and throughout the study period the pigs were housed in single animal units.

Inoculum

Staphylococcus aureus strain S54F9, *spa* type t1333 (Nielsen *et al.*, 2009; Hasman *et al.*, 2010) was used.

For long-term infusion, a suspension of 10⁷ colony forming units (CFU) *S. aureus*/ml was prepared. Each pig was inoculated with 10 ml/kg BW.

For short-term infusion, 9 ml autologous blood was mixed with 1 ml bovine thrombin (200 IU/ml) and 0.1 ml suspension of *S. aureus* (10⁸ CFU/ml). In this way, the total concentration of infused bacteria was 10⁸ CFU/kg BW in both infusion methods.

The blood used for microthrombi formation was drawn from the external jugular vein (EJV) catheter into a syringe. The syringe was immediately disconnected from the catheter and connected to a 150 mm polyethylene catheter (PP10; inner diameter 0.28 mm, Polysan, Værløse, Denmark). A syringe containing the thrombin and bacteria was inserted at the other end of the catheter. Blood and the thrombin-bacteria mixture were then circulated between the two syringes through the catheter several times to assure thorough mixing. Then the mixture was allowed to coagulate for 30 min. The coagulum was

transected into microthrombi by transferal through a sieve (mesh width 0.5 x 0.5 mm) into a Petri dish. Saline was added to the microthrombi until a total volume of 1.67 ml/kg BW was achieved. The microthrombi suspension was aspirated into a sterile syringe and connected to the catheter in the ICA and used for infusion.

Experimental procedures

The pigs were sedated by a mixture of 125 mg tiletamine hydrochloride (Zoletil 50 Vet, Virbac, Carros, France), 125 mg zolazepam hydrochloride (Zoletil Vet, Virbac), 125 mg xylazine hydrochloride (Rompun Vet, Bayer, Denmark), 125 mg ketamine (Ketaminol Vet., MSD Animal Health, Copenhagen, Denmark), 20 mg butorphanol tartrate (Morphasol Vet, BioVet, Fredensborg, Denmark) and 20 mg methadone hydrochloride (Comfortan Vet., Dechra Veterinary Products, Shrewsbury, UK). The sedation mixture was given at a dose of 1 ml/10 kg BW intramuscularly (IM). After sedation, pigs were anesthetized with propofol 1 mg/kg BW (Rapinovel®; Schering-Plough, Farum, Denmark) through an ear vein catheter. Then pigs were intubated. Respiration and heart rates and blood pressure were monitored automatically (Datex-Ohmeda Monitor, GE Healthcare, Brøndby, Denmark). The core temperature was maintained at 37 ± 0.5 °C during anesthesia (3M Bair Hugger, 3M Health Care, UK). When aseptically prepared for surgery, the ventral midline, the right lateral and the right dorsal surfaces of the neck were each injected with 1 ml lidocaine subcutaneously (SC) (Lidocain 10 mg/ml, SAD, Amgros I/S, Copenhagen, Denmark). A 5 cm midline incision was made in the ventral neck. Through blunt dissection, the vagal nerve, the common carotid artery and the EJV were displayed on the right side of the neck. The EJV was ligated and a catheter (0.8 PVC phthalate-free tube with X-ray line; Unomedical Inc., McAllen, USA) was guided to the cranial thoracic aperture and fixed by ligation to the vein and flushed with heparinized saline (2500 IU/ml). The free end of the catheter was tunneled SC to the right dorsal side of the neck where it was displayed via a 1 cm incision and fixed to the skin. The common carotid artery was ligated and a catheter (0.5 PVC phthalate-free tube with X-ray line; Unomedical Inc., McAllen, USA) was guided to the entrance of the ICA and fixed by ligation to the artery and flushed with heparinized saline (2500 IU/ml). The arterial catheter was then connected to an infusion pump (Alaris GH Plus Syringe Pump, CareFusion, Lyngby, Denmark). Through this pump, the

pigs received 10 ml/kg BW/h maintenance isotonic saline (Ringer-acetate; Fresenius Kabi AB, Uppsala, Sweden). The pump was also used for infusion of bacteria. The pigs were randomly assigned to the two infusion methods: Pig 1 received bacteria suspended in isotonic saline. The bacterial suspension was infused at maintenance flow rate for exactly 60 min (i.e. 10 ml suspension/kg BW/h). Pigs 2 and 3 received microthrombi suspension at maintenance flow rate for 10 min (Table 1). After infusion, all pigs received sterile saline at maintenance flow rate through a new syringe for 30 min to flush the infusion catheter. After flushing, the ICA was ligated in front of the catheter. The ICA catheter was withdrawn and the surgical incision was prepared with 1 ml bupivacaine (Bupivacain 5 mg/ml, SAD, Amgros I/S, Copenhagen, Denmark) and sutured. Pigs were treated with an IM injection of 0.3 mg buprenorphine (Temgesic, Reckitt Benckiser, Berkshire, UK) before anesthesia was ceased.

Post-operative procedures

The pigs were clinically examined every 4 h from the time of infusion and treated with 0.3 mg buprenorphine IM every 8 h until euthanasia. Clinical examinations included evaluation of appearance and general condition, appetite (feed consumed between clinical examinations), urination and defecation in the pen, skin elasticity, mucous membrane color and capillary refill time, heart rate, rectal temperature and general responsiveness. Responsiveness was measured by ear and eye movement towards sounds and by the general reaction to human contact. At each clinical examination the pigs were offered 5 ml of apple juice through a syringe. The pigs were considered to reach the humane endpoints if they displayed one or more of the following behaviors: 1) Lack of urination and/or defecation in the pen since the last clinical examination combined with reluctance to accept apple juice; 2) Lack of feed consumption since the last clinical examination combined with reluctance to accept apple juice; and 3) Reluctance or incapability to rise and approach the apple juice. Pigs that did not meet the humane endpoints were euthanized 24 h (Pigs 1 and 2) and 48 h (Pig 3) after infusion. They were deeply anesthetized by IM injection of 1 ml/kg of a solution of 125 mg tiletamine hydrochloride and 125 mg zolazepam hydrochloride suspended in 5 ml followed by 10 ml propofol applied through an ear vein catheter and finally exsanguinated.

Blood samples

Blood samples were acquired at 24 h before infusion from a venous puncture, during surgery through the EJV catheter just before infusion and, through the EJV catheter at the end of the clinical examinations at 4, 8, 12, 24 and 48 h after infusion. Each blood sample was immediately divided into three aliquots. The first aliquot was allowed to coagulate and was used for analyses of acute-phase proteins. The second aliquot was stabilized with ethylenediaminetetraacetic acid (EDTA) and used for bacteriological cultivation. The third aliquot was stabilized with EDTA and used for hematology.

Analysis of acute-phase proteins

Porcine α_1 -acid glycoprotein (PAGP) concentrations were determined by a competitive catching enzyme-linked immunosorbent assay (ELISA) (Heegaard *et al.*, 2013). All samples were run twice at 1/500 or higher dilutions with a detection limit of 50 mg/l. Haptoglobin concentrations were determined by a sandwich ELISA (Soerensen *et al.*, 2006) with a detection limit of 130 mg/l. Serum amyloid A (SAA) concentrations were determined by a commercially available sandwich ELISA (Phase SAA Assay, Tridelta Development Ltd., Kildare, Ireland) (McDonald *et al.*, 1991). Samples were tested according to the manufacturer's instructions but a low dilution of 1:20 was used to increase signal intensity. The detection limit of the assay was 31.3 mg/l (porcine SAA equivalents). Finally, C-reactive protein (CRP) concentrations were determined by a sandwich ELISA (Heegaard *et al.*, 1998). Polyclonal rabbit anti-human antibodies with cross-reactivity towards porcine CRP were employed (Heegaard *et al.*, 2009) followed by peroxidase-conjugated goat anti-rabbit antibody for detection (DAKO, Glostrup, Denmark). Pooled pig serum calibrated against a human CRP calibrator (DAKO A0073) was used as a standard. The detection limit was 0.35 mg/l (human equivalents). Development of CRP plates was done with a tetramethylbenzidine peroxide color substrate (Kem-En-Tec, Taastrup, Denmark). All samples including standards were run in duplicate. Sample values were calculated from the curve fitted to the readings of the standard (using Ascent software v. 2.6, Thermo Scientific).

Bacteriology

All blood samples and homogenized samples (10 g) of liver, lung and spleen were cultured on blood-agar plates for 24 h at 37 °C using both undiluted and ten-fold dilutions (final detection limit: 1 CFU/ml blood

and 1 CFU/g tissue). From each sample with a positive culture, the colony morphology was evaluated and one colony was selected for *S. aureus* protein A typing (*spa*-typing) with the inoculated *S. aureus* strain as the control. A multiplex polymerase chain reaction technique (Stegger *et al.*, 2012) and BioNumerics v 6.6 (Applied Maths, Sint-Martens-Latem, Belgium) were used to amplify, sequence and analyze the *spa* gene and assign the *spa* type.

Hematology

An automated complete blood cell count including neutrophil count was conducted (ADVIA 120 analyzer, Bayer Healthcare Diagnostics, Berlin, Germany), as described by Leifsson *et al.* (2010).

Necropsy, histology and immunohistochemistry

Full necropsies were conducted. Specimens of liver and lung and the entire brain were fixed by immersion in 10% neutral buffered formalin and processed by routine methods and paraffin embedded. The brain was sliced into coronal slabs of 4 mm before paraffin embedding. Sections of 4 μ m were made from each brain slab and stained with hematoxylin and eosin. Furthermore, IHC staining was performed for *in situ* detection of *S. aureus* antigen (Kvist *et al.* 2002), glial fibrillary acidic protein (GFAP) (Sikasunge *et al.*, 2009), myeloperoxidase for detection of neutrophils (Christiansen *et al.*, 2013a), and for ionized calcium binding adapter molecule 1 (IBA-1) to detect microglial cells and monocytes (Grossi *et al.*, 2015).

Results

Throughout the study, pigs showed only mild clinical signs although they preferred to lie down during the first hours after surgery. Their rectal temperature increased to a maximum of 40.5 °C (acclimatizing temperature 48 h before infusion: 38.1 – 39.5 °C).

Serum levels of acute phase proteins showed that both SAA and haptoglobin increased with a steep rise in concentration within the first 24 h after infusion. The level of CRP also increased after infusion. The level of PAGP was only raised in Pig 2 at 24 h and remained normal or decreased in the other two pigs (Fig 1). Two blood samples from Pig 3 yielded too little serum to enable analysis of all four acute-phase proteins. The missing analyzes for Pig 3 were: all acute phase proteins at 8 h after infusion and CRP and PAGP at 48 h after infusion.

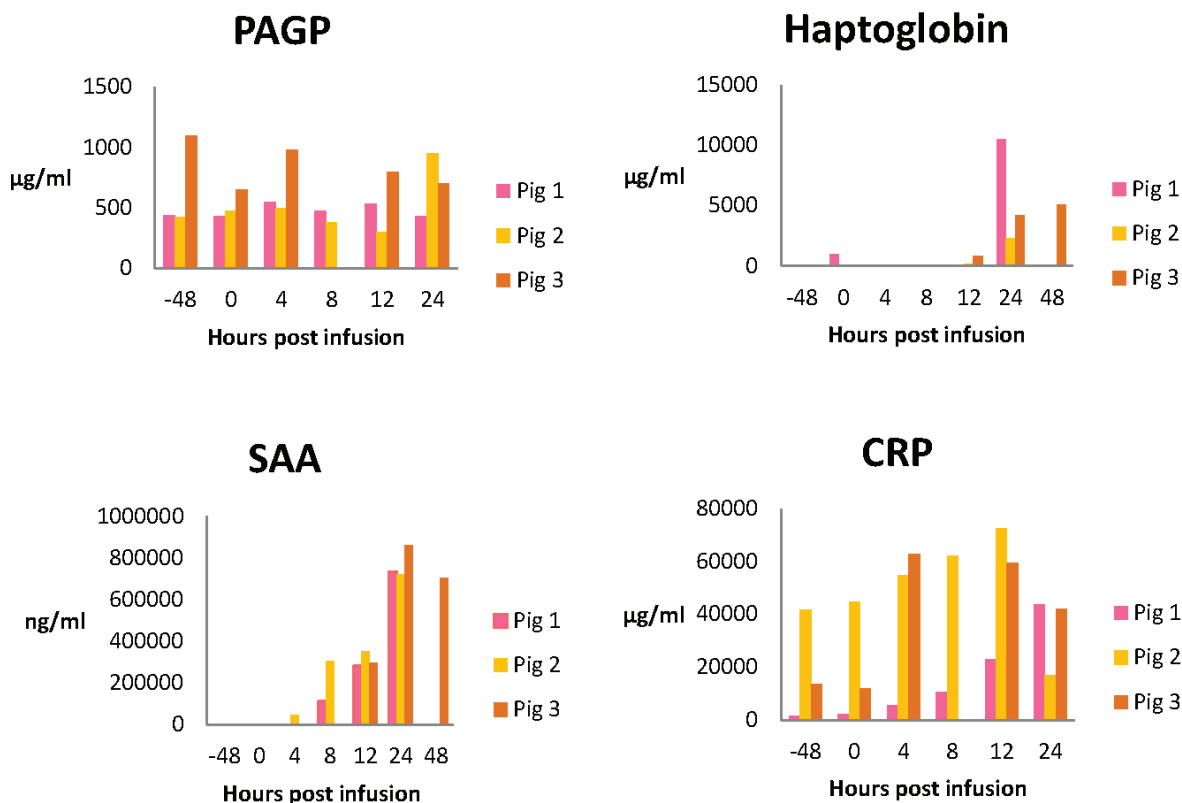


Figure 1. Serum levels of acute phase proteins.

Levels of porcine α_1 -acid glycoprotein (PAGP), haptoglobin, serum amyloid A (SAA), and C-reactive protein (CRP) during the experimental period.

No bacteria were cultured from blood or tissues from Pig 3, whereas *S. aureus* (same spa-type as infused strain) were isolated from spleen and lung, and in the blood until 12 h after infusion, in Pig 2, and in the spleen, lung and liver of Pig 1 (Table 1).

Hematology showed that all pigs developed neutrophilia within 8 h (Fig 2). Some blood samples yielded too little blood to enable analysis. The missing analyzes were: Pig 1 at 8 and 12 h post infusion; Pig 2 at 8 h post infusion; Pig 3 at 48 h before infusion and 48 h after infusion.

Histology showed that the only brain lesion present in pigs euthanized at 24 h (Pigs 1 and 2) was

slight edema. Pig 3 that was euthanized after 48 h had a single gray matter microabscess located peripheral to the right lateral ventricle near the hippocampus (Fig 3). The abscess consisted of densely organized round cells of which most stained positive for myeloperoxidase. The myeloperoxidase-negative cells stained positive for IBA-1. The microabscess comprised mainly of neutrophils with a rounded morphology but also of monocytes. GFAP IHC indicated peripheral hypertrophy and proliferation of astrocytes. Due to the limited size of the abscess only the periphery of the abscess was included in the slide used for *S. aureus* antigen detection. The periphery of

Table 1: Design and results from infusion of *Staphylococcus aureus* to the brain through the internal carotid artery.

All pigs received 10^8 CFU/kg body weight. Liver, lung, spleen and blood were examined bacteriologically. Blood samples were taken at -48, 0, 4, 8, 12, 24 and 48 h after infusion. Detection limit of bacterial cultures: 1 CFU/ml blood and 1 CFU/g tissue.

Pig	Type of infusion	Duration of infusion	Survival time	Brain lesions	Bacteriology
1	Bacteria suspended in saline	60 min	24 h	Mild edema	Spleen (1 CFU/g), lung (9 CFU/g) and liver (5 CFU/g)
2	Bacteria embedded in microthrombi	10 min	24 h	Mild edema	Blood until 12 h after infusion, spleen (3 CFU/g), lung (1CFU/g)
3	Bacteria embedded in microthrombi	10 min	48 h	Microabscess	All samples were negative

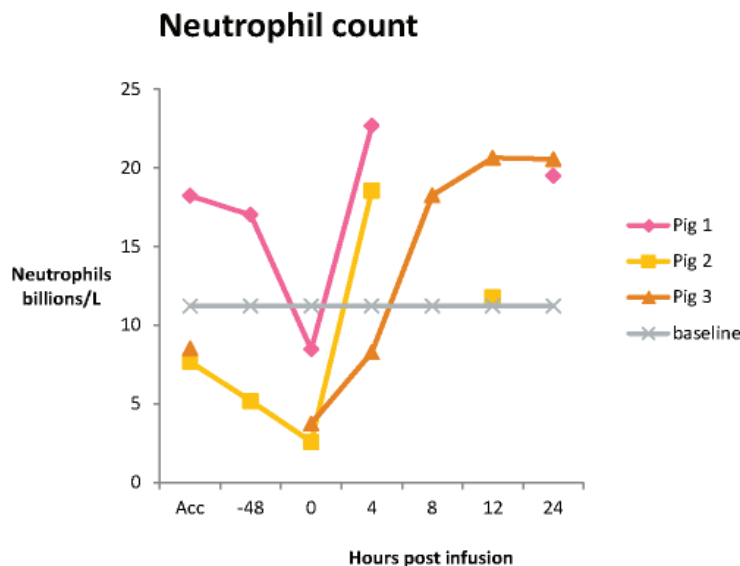
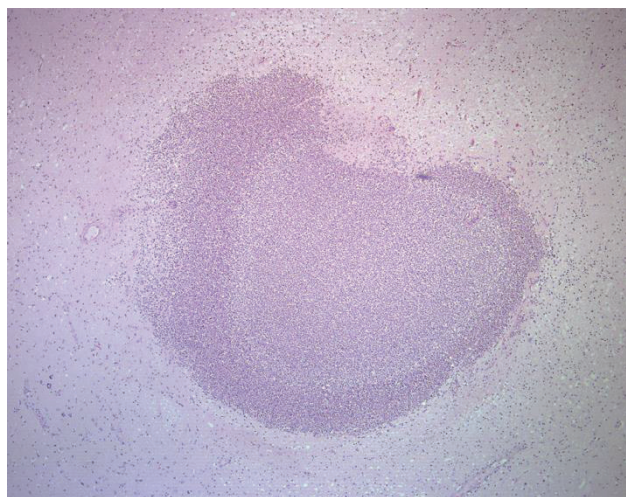


Figure 2. Change in numbers of neutrophils. All the pigs developed neutrophilia within the first 8 h after infusion. Some samples were excluded due to failed tests caused by insufficient blood volume. The baseline denotes the upper limit of the standard interval of neutrophils in porcine blood (11.22 billion/l). Acc = acclimatization (48 h before infusion).

the abscess did not stain positive for *S. aureus*. As the abscess had already been entirely cut into the existing slides it was not possible to increase the number of slides used for *S. aureus* antigen detection. No lesions were found in the lung and liver in any of the pigs.

Discussion

We here report the results for local infusion of bacteria to the porcine brain as a model of sepsis-related brain microabscesses. Our results show that bacteria suspended in saline or embedded in microthrombi can pass through the *rete mirabile* in pigs. Passage through the *rete mirabile* was confirmed by isolating bacteria from the systemic circulation following both infusion methods. Accordingly, both infusion methods resulted in local brain bacteremia and systemic bacteremia.



Furthermore, brain bacteremia created by infusion of *S. aureus* embedded in microthrombi resulted in microabscess formation and thereby resembled human cases of *S. aureus* sepsis (Pendlebury *et al.*, 1989; Sharshar *et al.*, 2004). The abscess morphology was characterized by rounded neutrophils. The presence of rounded neutrophils is a rare finding but has previously been reported in combined experimental porcine *S. aureus* sepsis and endocarditis (Astrup *et al.* 2013; Christiansen *et al.*, 2013a). Despite the limited number of pigs in our study, the finding of this particular brain abscess morphology therefore seems unlikely to be a coincidence. In addition, former studies have shown that only the center of a microabscess stains positive for *S. aureus* (Christiansen *et al.*, 2013a). This seems a likely scenario in our study as well because we could not detect the bacteria outside the center of the abscess. Our results indicate that a survival time above 24 h is needed for the development of significant brain pathology when bacteria are infused locally to the brain. This is in contrast to sepsis models that apply systemic bacterial infusion which results in brain microabscesses developing earlier and in higher numbers (Astrup *et al.*, 2013).

Concerning the clinical course, our results indicate that models of local brain infusion of bacteria are much more beneficial in terms of decreased animal suffering and management challenges compared with ordinary sepsis models (Nemzek *et al.* 2008; Leifsson

Figure 3. Brain microabscess in Pig 3. Hematoxylin and eosin. 4 x objective.

et al., 2010; Soerensen et al., 2012; Christiansen et al., 2013b).

Collectively, fever, neutrophilia, activated acute-phase response and bacteremia show that all pigs developed sepsis as defined by the criteria for the systemic inflammatory response syndrome (Levy et al., 2003). However, former models that have applied the same bacterial strain and dose systemically have resulted in severe sepsis with a mortality rate of 60% within 48 h of infection (Soerensen et al., 2013). Contrary to this, our pigs did not develop severe sepsis and the mortality rate was 0. It may therefore be speculated that the sepsis-reaction *per se* affects the development of brain microabscesses. Such sepsis influence on the brain may include cytokine-induced permeability of the blood-brain-barrier and anoxic damage to neurons (Sharshar et al., 2003, Sharshar et al., 2005). As such, sepsis-effects on the brain might ease the spread of bacteria from the blood to the brain parenchyma and thus affect the number and development time of brain microabscesses. Therefore, the sparse clinical effects with our infusion models may hypothetically also account for the decreased brain pathology despite the direct brain infusion design.

In conclusion, this study shows that brain bacteremia in pigs can be created by using either of our local infusion methods despite the presence of a *rete mirabile* in pigs. Also both infusion methods apparently avoid the development of severe clinical signs as observed in sepsis-models that apply systemic bacterial infusion. Furthermore, local brain infusion with *S. aureus* embedded in autologous microthrombi resulted in sepsis-related brain pathology with a microabscess as the most characteristic lesion. We therefore recommend the microthrombi-infusion method to be further developed as it has the potential to meet the strong demand for both reduction and refinement of existing sepsis models.

Competing interests

The authors declare that they have no competing interests.

Acknowledgments

The authors would like to thank Andreas Vegge for his contributing advice in the surgical design. The work was financed by grant no. 271-07-0417 from the Danish Medical Research Council, and by Aase og Ejnar Danielsens Fond.

References

- Astrup LB, MV Nielsen, TM Iburg, PS Leifsson, HE Jensen, OL Nielsen & JS Agerholm: Brain microabscesses in a porcine model of *Staphylococcus aureus* sepsis. *Acta Vet. Scand.* 2013, 55, 76.
- Azuma A, K Toyoda & T O'uchi: Brain magnetic resonance findings in infective endocarditis with neurological complications. *Jpn. J. Radiol.* 2009, 27, 123-130.
- Bogdanski R, M Blobner, I Becker, F Hänel, H Fink & E Kochs: Cerebral histopathology following portal venous infusion of bacteria in a chronic porcine model. *Anesthesiology.* 2000, 93, 793-804.
- Christiansen JG, M Oscarson, HE Jensen, LK Jensen, J Koch, B Aalbæk, OL Nielsen, TM Iburg & PS Leifsson: Embolic encephalitis in a porcine model of endocarditis. *In Vivo.* 2013a, 27, 591-597.
- Christiansen JG, HE Jensen, LK Johansen, J Koch, J Koch, B Aalbæk, OL Nielsen & PS Leifsson: Porcine models of non-bacterial thrombotic endocarditis (NBTE) and infective endocarditis (IE) caused by *Staphylococcus aureus*: A preliminary study. *J. Heart. Valve. Dis.* 2013b, 22, 368-376.
- Grossi AB, P Hyttel, HE Jensen & PS Leifsson: Porcine melanotic cutaneous lesions and lymph nodes: immunohistochemical differentiation of melanocytes and melanophages. *Vet. Pathol.* 2015, 52, 83-91.
- Haaland K & WJ Orderud: The piglet as a model for cerebral circulation: an angiographic study. *Biol. Neonate.* 1995, 68, 75-80.
- Hasman H, A Moodley, L Guardabassi, M Ategger, RL Skov & FM Aarestrup: Spa type distribution in *Staphylococcus aureus* originating from pigs, cattle and poultry. *Vet. Microbiol.* 2010, 141, 326-331.
- Heegaard PMH, J Klausen, JP Nielsen, N Gonzáles-Ramón, M Piñeiro, F Lampreave & MA Alava: The porcine acute phase response to infection with *Actinobacillus pleuropneumoniae*. Haptoglobin, C-reactive protein, major acute phase protein and serum amyloid A protein are sensitive indicators of inflammation. *Comp. Biochem. Physiol.* 1998, 119B, 365-373.
- Heegaard PMH, HG Pedersen, AL Jensen & U Boas: A robust quantitative solid phase immunoassay for the acute phase protein C-reactive protein (CRP) based on cytidine 5'-diphosphocholine coupled dendrimers. *J. Immunol. Meth.* 2009, 343, 112-118.
- Heegaard PMH, I Miller, NS Sorensen, KE Soerensen & K Skovgaard: Pig α 1-acid glycoprotein: Characterization and first description in any species as a negative acute phase protein. *PLOS ONE.* 2013, doi:10.1371.
- Kvist PH, ES Jensen, B Aalbæk & HE Jensen: Evaluation of the pathology, pathogenesis and aetiology of auricular elephantiasis in slaughter pigs. *J. Vet. Med.* 2002, 49, 517-522.

- Leifsson PS, TM Iburg, HE Jensen, JS Agerholm, M Kjeldgaard-Hansen, B Wiinberg, PMH Heegaard, LB Astrup, AE Olsson, MG Skov, B Aalbaek & OL Nielsen: Intravenous inoculation of *Staphylococcus aureus* in pigs induces severe sepsis as indicated by increased hypercoagulability and hepatic dysfunction. *FEMS*. 2010, 309, 208-216.
- Levy MM, MP Fink, JC Marshall, E Abraham, D Angus, D Cook, J Cohen, SM Opal, JL Vincent & G Ramsay: 2001 SCCM/ESICM/ACCP/ATS/SIS international sepsis definitions conference. *Crit. Care Med*. 2003, 31, 1250-1256.
- McDonald TL, A Weber & JW Smith: A monoclonal antibody sandwich immunoassay for serum amyloid A (SAA) protein. *J. Immunol. Meth*. 1991, 144, 149-155.
- Nemzek JA, KMS Hugunin & MR Opp: Modeling Sepsis in the Laboratory: Merging Sound Science with Animal Well-Being. *Comp. Med*. 2008, 58, 120-128.
- Nielsen OL, T Iburg, B Aalbaek, PS Leifsson, JS Agerholm, P Heegaard, M Boye, S Simon, KB Jensen, S Christensen, K Melsen, AK Bak, ER Backman, MH Jørgensen, DK Groegler, AL Jensen, M Kjeldgaard-Hansen & HE Jensen: A pig model of acute *Staphylococcus aureus* induced pyemia. *Acta Vet. Scand*. 2009, 51, 14.
- Pendlebury WW, DP Perl & DG Munoz: Multiple microabscesses in the central nervous system: a clinicopathologic study. *J. Neuropathol. Exp. Neurol*. 1989, 48, 290-300.
- Reinert M, C Brekenfeld, P Taussky, R Andres & RW Seiler: Cerebral revascularization model in a swine. *Acta Neurochir*. 2005, Suppl 94, 153-157.
- Sharshar T, F Gray, G Lorin de la Grandmaison, NS Hopkinson, E Ross, A Dorandeu, D Orlikowski, JC Raphael, P Gajdos & D Annane: Apoptosis of neurons in cardiovascular autonomic centres triggered by inducible nitric oxide synthase after death from septic shock. *Lancet*. 2003, 362, 1799-1805.
- Sharshar T, D Annane, G Lorin de la Grandmaison, JP Brouland, NS Hopkinson & F Gray: The neuropathology of septic shock. *Brain Pathol*. 2004, 14, 21-33.
- Sharshar T, NS Hopkinson, D Orlikowski & D Annane: *Science review: The brain in sepsis – culprit and victim*. *Crit. Care*. 2005, 9, 37-44.
- Sikasunge CS, MV Johansen, IK Phiri, AL Willingham & PS Leifsson: The immune response in *Taenia solium* neurocysticercosis in pigs is associated with astrogliosis, axonal degeneration and altered blood–brain barrier permeability. *Vet. Parasitol*. 2009, 160, 242-250.
- Sorensen NS, C Tegtmeier, LO Andresen, M Piñeiro, MJ Toussaint, FM Campbell, F Lampreave & PMH Heegaard: The porcine acute phase protein response to acute clinical and subclinical experimental infection with *Streptococcus suis*. *Vet. Immunol. Immunopathol*. 2006, 113, 157-168.
- Soerensen KE, OL Nielsen, MM Birck, DB Soerensen, PS Leifsson, HE Jensen, B Aalbaek, AT Kristensen, B Wiinberg, M Kjeldgaard-Hansen, PMH Heegaard & TM Iburg: The use of sequential organ failure assessment parameters in an awake porcine model of severe *Staphylococcus aureus* sepsis. *APMIS*. 2012, 120, 909-921.
- Stegger M, PS Andersen, A Kearns, B Pichon, MA Holmes, G Edwards, F Laurent, C Teale, R Skov & AR Larsen: Rapid detection, differentiation and typing of methicillin-resistant *Staphylococcus aureus* harbouring either mecA or the new mecA homologue mecA(LGA251). *Clin. Microbiol. Infect*. 2012, 18, 395-400.
- Tunkel AR & D Kaye: Neurologic complications of infective endocarditis. *Neurol. Clin*. 1993, 11, 419-440.