




Società Italiana
di Endodonzia

Available online at www.sciencedirect.com

ScienceDirect

journal homepage: www.elsevier.com/locate/gie



ORIGINAL ARTICLE/ARTICOLO ORIGINALE

A two-year report of a comparative randomized controlled trial on the treatment of upper central incisors with periapical lesions



Risultati a due anni di un trial clinico controllato randomizzato comparativo sul trattamento di incisivi centrali superiori con lesione periapicale

Daniele Angerame^{a,*}, Matteo De Biasi^a, Vittorio Franco^b,
Lorenzo Bevilacqua^a, Attilio Castaldo^a

^a Dental Clinic, University Clinic Department of Medical, Surgical and Health Sciences, University of Trieste, Trieste, Italy

^b Private Practice, Rome, Italy

Received 28 October 2016; accepted 23 December 2016

Available online 15 February 2017

KEYWORDS

Periapical lesion;
Integrated endodontic
techniques;
Carrier based systems;
Healing.

Abstract

Aim: To evaluate the two-year success rate of primary root canal treatment performed with two integrated shaping and filling systems on upper central incisors with chronic periapical pathosis. **Methodology:** The trial enrolled 60 patients with an untreated maxillary central incisor presenting a chronic periapical lesion smaller than 5 mm in diameter, who were randomly assigned to two treatment groups: G1 ($n = 30$), Revo-S/One Step Obturator; G2 ($n = 30$) GTX/GTX Obturator. The patients underwent single-session root canal treatments by an experienced endodontist and were followed up for two years. The clinical evaluation entailed percussion and palpation tests. Two independent examiners rated the radiographic healing on the basis of a previously described scale. Comparability between groups in terms of baseline clinical parameters was tested with a

* Corresponding author at: University of Trieste, Dental Clinic, University Clinical Department of Medical, Surgical and Health Sciences, Piazza Ospedale 1, I-34125 Trieste, Italy.

E-mail: d.angerame@fmc.units.it (D. Angerame).

Peer review under responsibility of Società Italiana di Endodonzia.



Production and hosting by Elsevier

<http://dx.doi.org/10.1016/j.gien.2017.01.001>

1121-4171/© 2017 Società Italiana di Endodonzia. Production and hosting by Elsevier B.V. This is an open access article under the CC BY-NC-ND license (<http://creativecommons.org/licenses/by-nc-nd/4.0/>).

PAROLE CHIAVE

Lesione periapicale;
Tecniche endodontiche integrate;
Sistemi carrier-based;
Guarigione.

Mann-Whitney test (age, apical gauging) and χ^2 test (tenderness to percussion and palpation). The comparison of clinical data and radiographic healing scores between the groups and among time points was carried out with non-parametric statistical methods ($p < 0.05$).

Results: The two groups were comparable in terms of baseline clinical parameters. All patients were available for the re-evaluation after two years. Only one patient per group was positive to the clinical tests at the final recall. An improvement of radiographic healing scores along the follow-up period was observed. After two years, the lesions were scored as totally healed, partially healed and not healed in 93.3%, 3.3% and 3.3% of cases in G1 and in 93.3%, 0% and 6.7% of cases in G2, without pointing out statistically significant differences between groups.

Conclusions: Both the two tested integrated shaping and filling systems proved to be effective for the treatment of upper central incisors with periapical pathosis. When monitoring the healing of periapical lesions, follow-up times longer than one year may be required to observe complete healing.

© 2017 Società Italiana di Endodonzia. Production and hosting by Elsevier B.V. This is an open access article under the CC BY-NC-ND license (<http://creativecommons.org/licenses/by-nc-nd/4.0/>).

Riassunto

Obiettivi: Valutare il tasso di successo a due anni del trattamento endodontico di incisivi centrali superiori affetti da lesione periapicale eseguito con due sistemi integrati di strumentazione e otturazione.

Materiali e metodi: Lo studio ha coinvolto 60 pazienti con un incisivo mascellare centrale non trattato con lesione periapicale (diametro ≤ 5 mm), i quali sono stati attribuiti casualmente a due gruppi di trattamento: G1 (n = 30), Revo-S/One Step Obturator; G2 (n = 30) GTX/GTX Obturator. I pazienti sono stati sottoposti a trattamenti endodontici in singola seduta a opera di un endodontista e seguiti nel tempo per due anni. La valutazione clinica è consistita nel testare la dolorabilità alla palpazione e alla percussione. Due esaminatori indipendenti hanno valutato la guarigione radiografica facendo riferimento a una scala descritta in precedenza. La comparabilità tra i gruppi in termini di parametri clinici iniziali è stata verificata con test Mann-Whitney (età, gauging apicale) e χ^2 (sensibilità a palpazione e percussione). Il confronto dei dati clinici e dei punteggi radiografici tra i due gruppi e tra i tempi sperimentali è stato condotto con test non parametrici ($p < 0,05$).

Risultati: I due gruppi sono risultati paragonabili in termini di parametri clinici al baseline. Tutti i pazienti si sono ripresentati alla rivalutazione a 2 anni. Un solo paziente per gruppo ha riportato dolorabilità ai test clinici al controllo finale. È stato osservato un miglioramento dei punteggi radiografici durante il follow-up. Dopo due anni le lesioni periapicali sono state classificate come guarite, ridotte in dimensioni e non guarite rispettivamente nel 93,3%, 3,3% e 3,3% dei casi in G1 e nel 93,3%, 0% e 6,7% dei casi in G2, senza rilevare differenze statisticamente significative tra i gruppi.

Conclusioni: Entrambi i sistemi integrati di strumentazione e otturazione testati sono risultati efficaci nel trattamento della patologia periapicale di incisivi centrali superiori. Il monitoraggio delle lesioni periapicali può richiedere un follow-up maggiore di un anno per osservare la guarigione completa.

© 2017 Società Italiana di Endodonzia. Production and hosting by Elsevier B.V. Cet article est publié en Open Access sous licence CC BY-NC-ND (<http://creativecommons.org/licenses/by-nc-nd/4.0/>)

Introduction

In the management of the periapical pathosis of endodontic origin, the purpose of the root canal treatment is to remove the necrotic tissue, as well as microorganisms from the endodontic system, thereby promoting the healing of periapical tissues.¹ To contribute to the success of root canal treatment, both an effective chemo-mechanical cleaning and a tight three-dimensional seal of the root canal filling should be achieved.

Shaping and filling techniques have recently undergone a process of simplification. An example of such trend is the decrease of the number of instruments that modern rotary systems are composed of.² Further, filling techniques involving

carrier-based systems provide the clinician with the possibility to fill the whole root canal with thermoplasticised gutta-percha in a single step. Filling techniques performed in fewer steps may be advantageous – especially for neophytes and non-specialists – as simplified systems seem to be less prone to cause errors in the operative procedure. This is supported by the findings of a microtomographic study, which showed how root fillings performed by novices with the continuous wave of condensation technique contained higher amount of voids and took longer times.³ In addition, manufacturers and dealers offer integrated endodontics systems, in which the size of the filling instruments matches that of shaping files. Both Revo-S (Micro-Mega, Besançon, France) and GTX rotary files (Dentsply Tulsa Dental Specialties, Tulsa, OK, USA) can be

used in combination with dedicated carrier-based obturators, the One-Step Obturator (CMS Dental ApS, Copenhagen, Denmark) and GTX Obturator (Dentsply Tulsa Dental Specialties), respectively. The sealing ability⁴ and the preliminary clinical performance on different tooth types² of these integrated systems has already been a matter of study, attesting the plausibility of considering these systems a valid alternative to traditional more complex techniques.

The present paper is the updated report of the findings of a previously published trial,⁵ which assessed the early success rate of the root canal treatment of upper central incisors with chronic periapical pathosis making use of the two aforementioned systems. The choice of focusing exclusively on such tooth type is intended to assess the clinical performance of these simplified systems on teeth that are generally characterised by a wide, straight canal. Even if extremely rare aberrations from the most common root canal configuration have been described,^{6,7} the thorough cleaning and sealing of the wide apical region of maxillary central incisors is the only true challenge that the clinician faces when treating these teeth. The present study poses the question whether the tested systems can be effective in teeth with non-vital pulp, periapical lesion and such anatomy of the apical third, despite their intrinsic simplicity.

Materials and methodology

The study setup and the methodological aspects of the present trial have already been described in detail formerly.⁵

The present randomised controlled trial designed with two parallel groups was conducted and reported according to the recommendations of the CONSORT statement guidelines⁸ and the principles of the last update of the Helsinki Declaration. After being informed on the objective and the design of the study, all the patients assessed for eligibility gave their consent for the involvement in the study by signing a dedicated form.

Eligibility criteria

The study enrolled male and female adult subjects at the Dental Clinic of the University of Trieste between August 2014 and February 2015, who needed the root canal treatment of an upper central incisor diagnosed with chronic periapical lesion with a diameter ≤ 5 mm on the periapical radiograph. The exclusion criteria were: patients with physical or psychological disabilities, inability to understand instructions, severe systemic disorders (i.e. non-controlled diabetes, immunologic diseases, malignant neoplastic processes). From a total of 70 subjects assessed for eligibility, 60 patients were enrolled in the trial.⁵ An independent operator, blind to the characteristics of the trial other than its design, generated the random sequence by stratified blocked randomization using a free simulation software.⁹ The patients were unaware of the experimental group of assignment. Blinding the operator performing the single-session root canal treatments was not feasible.

Interventions

A single experienced endodontist treated all enrolled patients. Field isolation was achieved by means of rubber

dam. A composite resin build-up restoration was made in case of suboptimal seal of the rubber dam. A manual size 10 K file (Dentsply Maillefer, Ballaigues, Switzerland) was used to scout the root canal and check the coronal and apical patency, then it was connected to an electronic apex locator (Root ZX, Morita Co., Tokyo, Japan) to determine the electronic working length. In the two groups, all the operative procedures excluding the shaping and filling protocols were kept standardised. The irrigation protocol consisted of 2.5 ml rinses after each shaping instrument with 5.25% sodium hypochlorite (NiClor 5, Ognà, Muggiò, Italy).

The rotary files were mounted on an endodontic hand-piece connected to a dedicated motor (Tecnika Vision S, ATR, Pistoia, Italy), which was set in accordance with the indications suggested by the manufacturers. The canal shaping/filling protocols were the following:

- Group 1 (G1, $n = 30$): the root canal was shaped with the standard sequence of rotary Revo-S instruments (Micro-Mega): SC 1 (25/.06), SC 2 (25/.04), and SU (25/.06). Afterwards, the apex was gauged with manual Ni-Ti files (Mity Turbo, JS Dental, Ridgefield, CT, USA) and accordingly enlarged with finishing files AS 30 (30/.06), AS 35 (35/.06) or AS 40 (40/.06). Manual refinement was performed if necessary. The root canal was dried with paper points and the canal walls were smeared with eugenol-free endodontic sealer (Sicura-Seal, Dentalica, Milan, Italy) using a sterile paper point. Making use of dedicated forceps, an obturator of the One-Step Obturator system (CMS Dental ApS, Copenhagen, Denmark) matching the apical preparation size was inserted into the One-Step Obturator Oven (CMS Dental ApS) to reach adequate gutta-percha thermo-plasticisation and then introduced into the root canal 1 mm shorter of the working length. After ten seconds, the handle of the obturator was bent and cut at the orifice level with a bur mounted on a high speed handpiece.
- Group 2 (G2, $n = 30$): the root canal was shaped with GT Series X rotary files (Dentsply Tulsa Dental Specialties) in the order: 20/.04, 20/.06, 30/.04, 30/.06. The apical gauging was performed as described in G1 and the apex was finished with .06 or 0.8 tapered GT Series X files. Once dried, the canal walls were smeared with Sicura-Seal sealer. The filling procedure followed the same principles described above and was carried out with GT Series X Obturators and a Thermaprep oven (Dentsply Tulsa Dental Specialties).

Clinical evaluation

A single operator who was not the one performing the root canal treatments gathered all anamnestic data concerning the general and oral health by interviewing the patients and performed the clinical evaluation wearing 4 \times magnifying loupes. The presence of baseline clinical signs was noted as a binary datum in a dedicated electronic spreadsheet, after testing the tenderness to percussion or palpation of the buccal sulcus in the apical area of the designated tooth. The clinical recall visits were scheduled after 6, 12, 18 and 24 months.

Radiographic centering and examination

Customised Rinn XCP devices (Rinn Corp., Elgin, IL, USA) and a digital X-ray system (Vistascan Dental Perio, Dürr Dental AG, Bietigheim, Germany) were used throughout the study

with a paralleling technique. The X-ray source was kept constant during the whole duration of the trial, using the same device (2200 Intraoral X Ray System, Kodak Dental Systems, Rochester, NY, USA) set at 70 kVp, 10 mA, and 0.20 s exposure time. All the images were registered in “Endo” mode to enhance readability.¹⁰ The images taken into examination in the radiographic healing assessment were the postoperative control radiograph, which served as baseline, and the radiographs taken at the recall visits after 6, 12, 18 and 24 months.

Two blind examiners with 19 and 23 years of clinical experience in Endodontics unaware of the study design and purpose were calibrated according to a previously described scale developed to score the healing of periapical lesions.¹¹ In a blind fashion, they were then asked to score the follow-up radiographs according to such scale, by attributing each of them to one of the following categories:

1. healing: normal trabecular bone and physiological periodontal ligament width;
2. improvement: decrease of the lesion size;
3. failure: increase of lesion size or absence of changes from the initial status;
4. unreadable radiograph.

The evaluation took place in multiple sessions immediately after the collection of the radiological images and after at least 1 month.¹² In case of disagreement between the judgement of the evaluators, the worst of the two scores was assumed.

Statistical analysis

Both the sensitivity to the clinical tests and the radiographic score were regarded main outcome measures of the present trial. All collected data were managed with the Statistical Package for Social Sciences v. 15 (SPSS Inc., Chicago, IL, USA). The comparability of baseline parameters of the two groups was tested by means of a Mann–Whitney test (age, apical diameter) and a χ^2 test (sensitivity to percussion and palpation). Radiographic healing scores and clinical examination parameters (percussion and palpation) were compared between groups with the Mann–Whitney test and χ^2 test, respectively. Within groups, changes over time in terms of positivity to clinical tests were assessed with a Cochran’s Q test, and in terms of radiographic healing with a Friedman test and a Wilcoxon test with Bonferroni correction for pairwise comparisons. The level of significance was set at 5%.

The level of intra- and inter-observer agreement of the rating of radiographic healing had been previously evaluated with kappa statistics with quadratic weighting and reported to be excellent.⁵ The imputed relative distances between the ordinal categories served as a basis for weighting: healing-improvement, 1; improvement-failure, 2.

Results

Table 1 reports a comparison between groups with regard to anamnestic variables, operative data and clinical parameters. The two groups were comparable at baseline, as no statistically significant differences in terms of age, apical diameter, and tenderness to percussion or palpation tests

Table 1 Anamnestic variables, operative data and clinical parameters registered at baseline and at recalls: comparison between groups.

	Age (y)	Apical diameter (mm)	Baseline		6-month recall		12-month recall		18-month recall		24-month recall		Cochran’s Q test	
			Percussion test (%)	Palpation test (%)	Percussion test (%)	Palpation test (%)	Percussion test (%)	Palpation test (%)	Percussion test (%)	Palpation test (%)	Percussion test (%)	Palpation test (%)	Percussion test	Palpation test
G1	46.3 ± 19.4	0.38 ± 0.06	+ 6.7	+ 6.7	+ 6.7	+ 10.0	+ 3.3	+ 3.3	+ 3.3	+ 3.3	+ 3.3	+ 3.3	+ 3.3	p = 0.637
n = 30			- 93.3	- 93.3	- 93.3	- 90.0	- 96.7	- 96.7	- 96.7	- 96.7	- 96.7	- 96.7	- 96.7	
G2	50.8 ± 19.6	0.39 ± 0.05	+ 3.3	+ 10.0	+ 3.3	+ 6.7	+ 6.7	+ 6.7	+ 0	+ 6.7	+ 0	+ 6.7	+ 3.3	p = 0.406
n = 30			- 96.7	- 90.0	- 96.7	- 93.3	- 93.3	- 93.3	- 100	- 93.3	- 100	- 93.3	- 96.7	
Mann Whitney	p = 0.340	p = 0.313	p = 0.554		p = 0.554		p = 0.640		p = 0.313		p = 0.554		p = 1.000	
			χ^2											

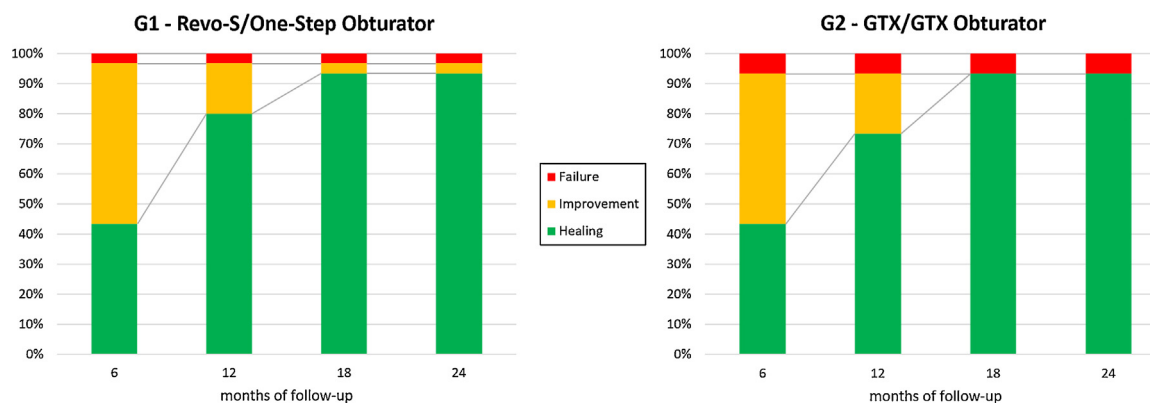


Figure 1 Frequencies of radiographic healing scores in the experimental groups at the different follow-up time points.

were observed. No patient drop-outs or voluntary withdrawals were registered, and all the recruited patients were available for re-evaluation during the follow-up period.

Throughout the whole trial, patients reporting symptoms before and after the treatment were a minority, ranging from 3.3% to 10%. At the end of the observation period, only one patient per group was positive to the clinical tests, while all the other subjects were symptom-free. On average, the prevalence of tenderness to percussion and palpation symptoms did not change over time and was similar in the two groups ($p > 0.05$).

Despite minor differences in the output of the statistical analysis, in the two groups the radiographic healing scores followed a similar trend of constant improvement during the 24 months of observation, as portrayed in Fig. 1. A substantial portion of subjects ($\approx 43\%$) presented complete radiographic healing already at the six-month recall. After one year, this subset underwent almost a two-fold increase ($p < 0.01$), because of the further reduction of partially healed lesions, with more patients being classified as totally healed. Differently, the improvement between the scores attributed after 12 and 18 months was statistically significant only in G2 ($p < 0.05$). Between 18 and 24 months, the frequencies of the scores remained constant ($p > 0.05$), evidencing two-year success rates above 90% irrespective of the integrated system. In the comparison between the radiographic healing observed in the two experimental groups, the statistical analysis did not reveal any significant difference.

Discussion

The present study demonstrated that adopting a simplified approach with integrated techniques for the treatment of upper maxillary incisors with periapical pathosis can lead to high success rates. Indeed, 93% of patients were classified as healed at the end of the follow-up period. This datum may be considered somehow unforeseen because, even though the root canal treatment can be successful in a percentage of cases that ranges between 75% and 97% according to primary and secondary studies,^{13–15} the success rate usually drops in presence of periapical lesion. Further, the clinical effectiveness of carrier-based filling techniques in presence of periapical lesion has been questioned, as the success rate of endodontic treatments carried out with Ni-Ti rotary files and Thermafil obturation may be one-half that obtainable in

teeth with vital pulps.¹⁶ The relatively low success rates reported by Gagliani and co-workers¹⁶ (48.2%) are reasonably ascribable to the characteristics of the sample, which included all types of teeth, even molar teeth, whose treatment entails more challenging tasks than upper anterior teeth. Further, the choice of first-generation Ni-Ti shaping instruments, namely the Profile system, might have influenced the effectiveness of the treatment since its instruments have negative rake angles that could possibly worsen the performance of the rotary file in case of infected canals. More generally, a recent prospective study¹³ demonstrated that the success rate of the root canal treatment of a tooth with periapical radiolucency is reduced as much as 8–13%, compared to the case in which the lesion is absent. The findings of the present study may suggest that when dealing with teeth that pose no peculiar hindrance to a standardised and simplified treatment because of their regular anatomy and good accessibility, highly satisfactory results may be obtained with relatively scarce effort and with techniques within the range of general dentists or inexperienced operators.

Surprisingly, it appears that the topic of the speed and pattern of periapical healing has been taken into consideration by literature only marginally, with only few studies following up endodontically treated teeth with periapical pathosis to monitor the initial stages of the radiographic healing.^{17,18} Instead, the early assessment of the periapical healing process is probably one of the most relevant issues from a clinical point of view, since both the clinician and the patient are interested in obtaining reliable information about the prognosis of the tooth, in order to conclude the restorative treatment as soon as possible. Based on a random-effects meta-analysis, the weighted-pooled six-month success rate of healing has been reported to be 29.6%.¹⁹ Moreover, a follow-up period lasting at least one year has been advocated to visualize substantial healing.^{20,21} The trend of periapical healing evidenced in the present study attests that a greater portion of patients can be considered totally healed after half a year (43%) and that 12 months may be insufficient to detect all the cases that are going to achieve complete resolution, as a total of 10 improved lesions (17% of the whole sample) disappeared after 18 months. Despite the improvement of the radiographic scores between the 12-month and 18-month time points was statistically significant only in G2, the global trend of radiographic healing was comparable in the two groups and the difference was

determined by only one subject still classified as partially healed in G1 after 18 months. More interestingly, the absence of differences between the healing scores attributed to the radiographs at the 18- and 24-month recalls may suggest to assume one year and a half as landmark to safely end the follow-up period. Another noteworthy finding is the fact that – with the only exception of one subject in G1 (3% of the partially healed patients) – all the patients classified as partially healed reached the status of complete periapical resolution, thus confirming the preliminary hypothesis postulated in the six-month report of the present trial on the prognostic relevance of the detection of an early sign of ongoing healing.⁵ Given the complete healing of almost the totality (97%) of the lesions already classified as reduced in size after 6 months, it might be speculated that it would be possible to proceed with the early rehabilitation of maxillary incisors with reduced lesion after 6 months in the cases when this is needed, all the more so considering that the only lesion not completely healed remained stationary after 2 years. A potential endodontic failure will be treated with an orthograde or retrograde retreatment. For future researches, it will be challenging to investigate at which extent the lesion reduction after 6 months can be safely considered a guarantee of complete/partially complete future healing in all types of teeth.

As to the evaluation of symptoms over time, no significant changes of the prevalence of patients positive to the clinical tests were observed. Strictly considering the criteria of success adopted, a total of 2 patients (3% of the whole sample) were reporting tenderness to percussion and palpation and, since they were not showing any radiographic signs of lesion reduction, should be considered treatment failures. However, even if the possibility to be subjected to non-surgical or surgical endodontic retreatment was offered to these individuals, they declared themselves unwilling to receive such therapy given the absence of major complications or spontaneous symptoms.

The most frequently used and, maybe, the most criticised rating scale for the periapical status is the periapical index (PAI).²¹ Its application to all tooth types has never been fully validated or accepted, because PAI was developed on radiographic and histological findings of maxillary incisors,²² where the proper analysis of the radiograph is not impeded by thick cortical plates or unfavourable positions of the root tip.²² The scale by Katebzadeh et al.¹¹ adopted in the present study had its validity previously tested by means of kappa statistics with quadratic weighting.⁵ The excellent inter- and intra-observer agreement that has been reported can be explained by the simplicity of the categories of this latter scale, which differ unmistakably one to another and, unlike PAI scores, were specifically designed to monitor the healing of an existing periapical lesion. Katebzadeh's scale follows the same intuitive principles of everyday clinical activity, during which clinicians classify a lesion as disappeared or decreased/unvaried/increased in size. One methodological aspect that is essential to ensure reliability of the readings is the standardisation of the film positioning and image acquisition. While standardising the phases of image acquisition and filtering is fairly easy, a little more effort is required to customise the film holder with a putty silicone registration; this procedure, though not compulsory in the clinical practice, is essential in the research setting.

The two tested integrated shaping and filling systems are examples of the endeavour made by manufacturers to provide clinicians with predefined sequences of operative steps that aim at reducing the possibility to introduce errors and not being operator-dependent. The present study proved that these systems are capable of valuable clinical performance, which can reach that of traditional approaches, and lays the ground for future investigations on other tooth types.

Conclusions

The endodontic treatments performed on maxillary central incisors with periapical lesion with the integrated shaping and filling systems tested in the present trial allowed for 93% two-year success rate, without differences between the experimental groups. One and a half years were a sufficient follow-up time period to detect the complete healing of the vast majority of the cases scored as partially healed at the previous recall examinations. All but one the lesions that were preliminarily classified as reduced in size reached the status of the complete healing.

Conflict of interest

The authors have no conflicts of interest to declare.

References

1. Sjogren U, Hagglund B, Sundqvist G, Wing K. Factors affecting the long-term results of endodontic treatment. *J Endod* 1990;16:498–504.
2. Angerame D, De Biasi M, Sossi D, Marigo L, Castagnola R, Somma F, et al. Periapical healing after simplified endodontic treatments: a digital subtraction radiography study. *G Ital Endod* 2013;27:74–9.
3. Mirfendereski M, Roth K, Fan B, Dubrowski A, Carnahan H, Azarpazhooh A, et al. Technique acquisition in the use of two thermoplasticized root filling methods by inexperienced dental students: a microcomputed tomography analysis. *J Endod* 2009;35:1512–7.
4. Tommasin E, De Biasi M, Ervas L, Angerame D. Microinfiltrazione apicale con sistemi semplificati di strumentazione e otturazione canalare. *G Ital Endod* 2010;33:60–5.
5. Angerame D, De Biasi M, Franco V, Bevilacqua L, Castaldo A. Upper central incisors with periapical lesions treated with two integrated endodontic systems: a six-month randomized controlled trial. *G Ital Endod* 2016;30:33–40.
6. Lin WC, Yang SF, Pai SF. Nonsurgical endodontic treatment of a two-rooted maxillary central incisor. *J Endod* 2006;32:478–81.
7. Kottoor J, Murugesan R, Albuquerque DV. A maxillary lateral incisor with four root canals. *Int Endod J* 2012;45:393–7.
8. Schulz KF, Altman DG, Moher D. CONSORT 2010 statement: updated guidelines for reporting parallel group randomised trials. *BMJ* 2010;340:c332.
9. Fron Chabouis H, Chabouis F, Gillaizeau F, Durieux P, Chatellier G, Ruse ND, et al. Randomization in clinical trials: stratification or minimization? The HERMES free simulation software. *Clin Oral Investig* 2014;18:25–34.
10. Yalcinkaya S, Kunzel A, Willers R, Thoms M, Becker J. Subjective image quality of digitally filtered radiographs acquired by the Durr Vistascan system compared with conventional radiographs. *Oral Surg Oral Med Oral Pathol Oral Radiol Endod* 2006;101:643–51.

11. Katebzadeh N, Sigurdsson A, Trope M. Radiographic evaluation of periapical healing after obturation of infected root canals: an in vivo study. *Int Endod J* 2000;**33**:60–6.
12. Brunette DM. *Critical Thinking: Understanding and Evaluating Dental Research*. Hanover Park, IL; 1996.
13. Ng YL, Mann V, Gulabivala K. A prospective study of the factors affecting outcomes of nonsurgical root canal treatment: part 1: periapical health. *Int Endod J* 2011;**44**:583–609.
14. Ng YL, Mann V, Gulabivala K. A prospective study of the factors affecting outcomes of non-surgical root canal treatment: part 2: tooth survival. *Int Endod J* 2011;**44**:610–25.
15. Imura N, Pinheiro ET, Gomes BP, Zaia AA, Ferraz CC, Souza-Filho FJ. The outcome of endodontic treatment: a retrospective study of 2000 cases performed by a specialist. *J Endod* 2007;**33**: 1278–82.
16. Gagliani MA, Cerutti A, Bondesan A, Colombo M, Godio E, Giacomelli G. A 24-month survey on root canal treatment performed by NiTi engine driven files and warm gutta-percha filling associated system. *Minerva Stomatol* 2004;**53**:543–54.
17. Murphy WK, Kaugars GE, Collett WK, Dodds RN. Healing of periapical radiolucencies after nonsurgical endodontic therapy. *Oral Surg Oral Med Oral Pathol* 1991;**71**:620–4.
18. Peters LB, Wesselink PR. Periapical healing of endodontically treated teeth in one and two visits obturated in the presence or absence of detectable microorganisms. *Int Endod J* 2002;**35**: 660–7.
19. Ng YL, Mann V, Rahbaran S, Lewsey J, Gulabivala K. Outcome of primary root canal treatment: systematic review of the literature - part 1. Effects of study characteristics on probability of success. *Int Endod J* 2007;**40**:921–39.
20. Siqueira Jr JF. Aetiology of root canal treatment failure: why well-treated teeth can fail. *Int Endod J* 2001;**34**:1–10.
21. Orstavik D, Kerekes K, Eriksen HM. The periapical index: a scoring system for radiographic assessment of apical periodontitis. *Endod Dent Traumatol* 1986;**2**:20–34.
22. Wu MK, Shemesh H, Wesselink PR. Limitations of previously published systematic reviews evaluating the outcome of endodontic treatment. *Int Endod J* 2009;**42**:656–66.