



Clinical Case Study

A Case of Diaphragmatic Rupture in a Criollo Pony

Khairuddin, N. H.^{1*}, Roslim, N.¹, Affandi, S. S.¹, Lau, S. F.² and Lim, S. Y.²

¹Department of Farm and Exotic Animal Medicine and Surgery, Faculty of Veterinary Medicine, Universiti Putra Malaysia, 43400 UPM, Serdang, Selangor, Malaysia

²Department of Veterinary Clinical Studies, Faculty of Veterinary Medicine, Universiti Putra Malaysia, 43400 UPM, Serdang, Selangor, Malaysia

ABSTRACT

This report describes a case of diaphragmatic rupture with migration of small and large intestines into the thoracic cavity of an 18-year-old Criollo pony. The pony was initially presented to the University Veterinary Hospital (UVH), Universiti Putra Malaysia (UPM), with mild colic and increased respiratory effort. A diagnosis of diaphragmatic rupture was made based on thoracic auscultation, radiographic and ultrasonographic findings. Due to financial constraints, surgical management was not an option and so the pony was managed medically. The pony was diagnosed with diaphragmatic rupture and concurrent bronchopneumonia and was observed closely. Mild colic was treated with analgesics while dyspnoea was managed symptomatically with bronchodilators and antibiotics. The pony remained clinically stable for more than eight (8) weeks. However, another episode of colic lead to a deterioration in its clinical condition and subsequent death. Post-mortem findings revealed migration of loops of small intestines and part of the large colon into the thoracic cavity. There was a linear tear (estimated to be about 15cm in length) in the right dorsal segment of the diaphragm at the border of the muscular and fibrous portion, which confirmed our clinical and diagnostic imaging findings of diaphragmatic rupture that had caused the pony to suffer from colic and dyspnoea.

ARTICLE INFO

Article history:

Received: 29 April 2016

Accepted: 27 March 2017

E-mail addresses:

nurul.leman82@gmail.com

nurulhayah@upm.edu.my (Khairuddin, N. H.),

noorashimah@upm.edu.my (Roslim, N.),

syaaffandi@upm.edu.my (Affandi, S. S.),

lausengfong@upm.edu.my (Lau, S. F.),

sueyee@upm.edu.my (Lim, S. Y.)

* Corresponding author

Keywords: Diaphragmatic rupture, dyspnoea, colic, radiography, ultrasonography, pony

INTRODUCTION

Diaphragmatic rupture is uncommon in horses (Speirs & Reynolds, 1976; Santschi, et al., 1997; Dabareiner & White, 1999). In adult horses, traumatic diaphragmatic injury has been recorded following parturition or excessive strenuous activities (Bristol, 1986). Following a diaphragmatic rent, various abdominal organs may pass through the defect although migration of small intestine into the thoracic cavity is most commonly recorded (Wimberly et al., 1977). Repair of diaphragmatic hernia is possible in horses but the prognosis following surgery is generally poor (Hart & Brown, 2009; Romero & Rodgers, 2010; Efrain & Kelmer, 2015). In this report, we describe the diagnosis and conservative management of a case of diaphragmatic rupture in a Criollo pony that was presented with recurrent low-grade colic and dyspnoea. Diagnosis of rupture of the diaphragm was made based on findings from clinical, radiographic and ultrasonographic examinations.

CASE HISTORY

An 18-year old Criollo pony, gelding, with 3/5 body condition was presented to UVH, UPM, with signs of mild colic that had lasted for four hours. The pony was reported to have rolled repeatedly in the stable when the colic was first noticed. According to the caretaker, there was no history of trauma or changes in its routine. Initially, administration of flunixin meglumine (1.1 mg/kg, IV) and intravenous fluids (0.9% NaCl, replacement rate at 20 mg/kg/hour, IV) provided relief as the clinical signs

subsided, and all clinical parameters such as heart and respiratory rates returned to their normal limits. However, 12 hours after the initial episode, the horse showed signs of recurrent mild colic, and another dose of flunixin meglumine (1.1 mg/kg, IV) was administered. At this stage, the horse showed increased breathing effort and was sweating profusely.

CLINICAL FINDINGS AND DIAGNOSTICS

Physical examination revealed a heart rate of 44 beats per minute and a respiratory rate of 36 breaths per minute. The pony displayed considerable respiratory effort and obvious abdominal breathing with a notable heave line. Rectal temperature, capillary refill time and the colour and hydration of mucous membranes were all within normal limits. Internal examination by rectal palpation was unremarkable. Normal borborygmi, which included gaseous components, were detected on auscultation of the abdomen. Auscultation of the left and right thoracic regions revealed sounds typical of intestinal activity. In addition, enhanced respiratory sounds, including wheezes and crackles, were evident. A radiograph of the thoracic region was taken from the left side and tubular, gas-filled structures, highly suggestive of distended loops of bowel, were seen in the cranio-ventral, caudo-ventral and caudal dorsal regions of the thorax (Figure 1). The diaphragmatic outline at the caudo-dorsal region of the thorax was not well defined, suggesting a disruption of the diaphragm in this location.

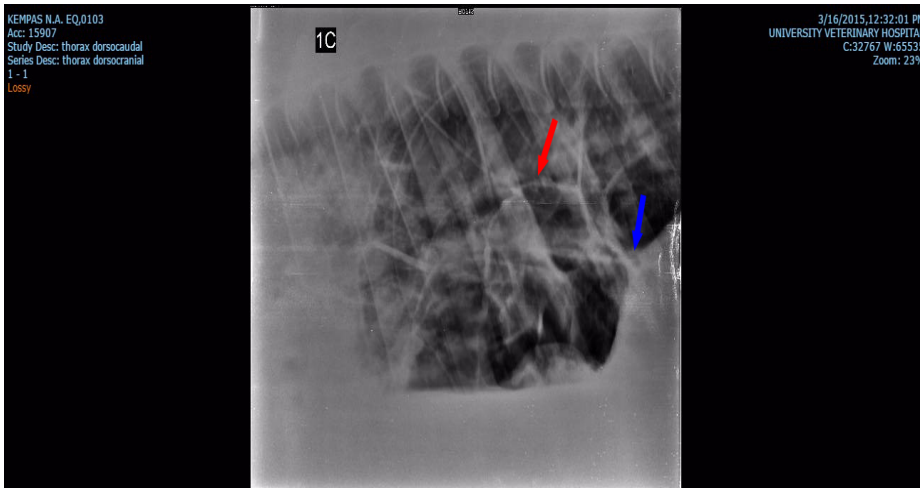


Figure 1. Left lateral thoracic radiograph revealed the presence of gas-filled organs highly suggestive of distended loops of bowel at the caudo-dorsal of the thoracic field (red arrow) and the irregularity of diaphragmatic outline at the caudo-dorsal region of thorax (blue arrow)

Transcutaneous ultrasonographic examination of the abdomen and thorax was performed using an ultrasound scanner (MyLab™ 40, Esaote) with a 3-9 MHz curvilinear probe (CA 123VET). With the horse in standing position, the ultrasound probe was placed longitudinally between two ribs and advanced sequentially cranially from the 13th intercostal space. A large amount of intra-thoracic free fluid was observed within the thoracic cavity at the level of the 11th intercostal space of the left side. Moving the probe further cranially, loops of intestines and free fluid were observed. The intestines were recognised by the reverberation artifact caused by intestinal gas. Marked pleural effusions were observed in the lung field (Figure 2). It was not possible to visualise any areas of discontinuity in the diaphragm based on ultrasonographic examination. Video of

the ultrasound examination of the thorax is available as supplementary material. Abdominal ultrasound revealed that the spleen and liver were displaced ventrally and cranially. The motility of observable intestines appeared normal.

A diagnosis of diaphragmatic rupture with passage of intestines into the pleural cavity was made based on thoracic auscultation, radiographic and ultrasonographic findings.

TREATMENT

Mild colic was treated with flunixin meglumine. Dyspnoea and tachypnea were managed with a bronchodilator (Clenbutarol, 5 g/100kg BW, BID for 10 - 14 days, PO) and a course of antibiotics (gentamicin, 6.6mg/kg BW, IV, every 24 hours and penicillin streptomycin, 22,000 IU/kg BW, IM, every 24 hours) were

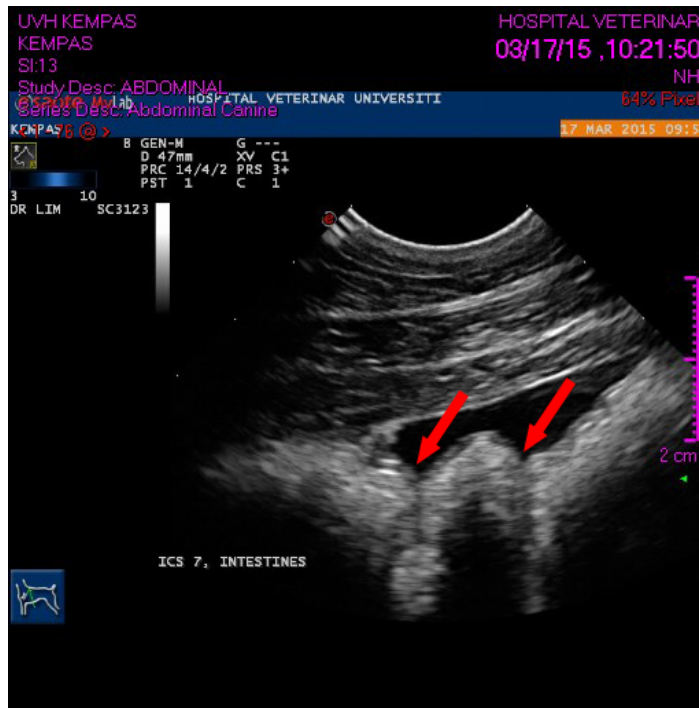


Figure 2. Transcutaneous ultrasonographic image of the thorax at the 7th intercostal space (ventral to the left, dorsal to the right, medial to the bottom). Loops of intestines (arrows) and intra-thoracic free fluid were observed. This image was obtained using a 3-9 MHz curvilinear probe

administered. Signs of colic resolved, and the pony regained its normal appetite and demeanour although it showed increased respiratory effort, with a respiratory rate of 36-40 breaths per minute.

All medications were discontinued after day five of hospitalisation at which stage the pony was discharged. It remained clinically stable for more than eight weeks. However, it then suffered another episode of colic, leading to clinical deterioration and its eventual death.

POST-MORTEM FINDINGS

Post-mortem examination revealed presence of few litres of green-coloured fluid within

the thoracic cavity and multiple loops of small intestine and part of the left large colon within the pleural space. The lungs were displaced cranially and were consolidated over more than 50% in all lobes. There was a large, linear tear (estimated to be about 15cm in length) in the right dorsal segment of the diaphragm at the border of the muscular and fibrous portions (Figure 3). The edge of the tear was smooth and was free of adhesions to any other structures. The walls of the intestine displaced in the thoracic cavity were thick and appeared congested.

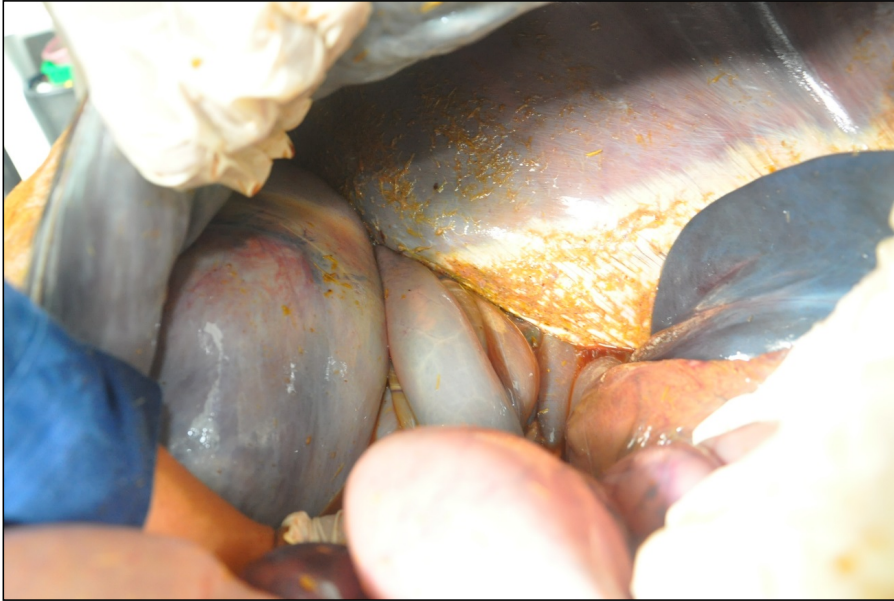

Figure 3. Post-mortem image of the thoracic cavity where small and large intestines pushing through the large linear tear at the right dorsal border of the diaphragm at the border of the muscular and fibrous portion. The edge of the tear was smooth, and no adhesion was evident. The tear was estimated to be about 15 cm in length

DISCUSSION

Diagnosis of diaphragmatic hernia in a horse can be challenging. In this case, the pony was presented with signs of acute colic, dyspnoea and detection of borborygmi that appeared to emanate from the thoracic cavity. This alerted us to the possibility of this rare condition.

In horses, the most common presenting sign of diaphragmatic rupture and passage of abdominal viscera into the pleural space is abdominal pain (Romero & Rodgers, 2010). In cases where the vascular supply to bowel is compromised, signs are acute, severe and unresponsive to medical therapy. However, where bowel is not strangulated or obstructed, colic may be low grade, chronic and recurrent in nature. Findings from rectal examination, abdominocentesis and clinical

pathology may all be within normal limits. Most commonly, horses suffering from this condition are presented with severe signs of colic that requires urgent surgical intervention. The condition is often not definitively diagnosed until the abdomen is systematically explored at celiotomy. Occasionally, the diaphragmatic rent is identified incidentally at necropsy (Bristol, 1986).

Identification of diaphragmatic rupture before induction of general anaesthesia is beneficial as it alerts the anaesthetist to the respiratory compromise that is likely to be present and will facilitate more effective surgical planning. In this case, both radiography and ultrasonography revealed evidence of gas filled loops of intestines within the thoracic cavity that proved to be

helpful in achieving an accurate diagnosis. In addition, radiography showed loss of a distinct diaphragmatic line at the level of the rupture, seen as radiopacity in the caudo-dorsal part of the chest, with the presence of gas filled within.

Rupture of the diaphragm and subsequent migration of intestine into the thoracic cavity resulted in the loss of pleural seal, leading to atelectatic lungs. Surprisingly, in this pony, despite evidence of pleural effusion on radiography and ultrasonography, and a very large tear on the diaphragm seen at post-mortem, the respiratory distress was not very severe. Indeed, the pony survived comfortably for more than two months from the time of presumed diaphragmatic rupture. The final abdominal crisis that resulted in severe deterioration in the pony's condition may be explained by the migration of portions of the gastrointestinal tract into the thoracic cavity including the large colon, which may have also caused further and more severe respiratory distress. Due to financial restraints and a poor prognosis for long-term survival, surgical repair of the diaphragmatic hernia was not an option. The pony was left with an acknowledged problem of diaphragmatic hernia. It has been reported that an unrepaired diaphragmatic rent can be partly sealed by adjacent stomach and liver (Stick, 2006). However, this may be unlikely or impossible if the tear is large and abdominal organs are displaced ventrally and cranially, as was observed in this case.

It was difficult to deduce if the diaphragmatic defect was congenital or acquired in nature. Congenital diaphragmatic hernia can be a result of failed fusion of many of the four embryonic components of the diaphragm (Malone et al., 2001). It can also be associated with diaphragmatic tear due to rib fractures in young foals (Stick, 2006). Congenital defects are reported to be small (only 2.5 cm in diameter) with smooth round edges (Schambourg, et al., 2003).

Diaphragmatic tears following trauma are more common in adults, following road traffic accidents, recent parturition (Stick, 2006) or even breeding in stallions (Riggs, personal communication, August 20, 2015). The tear is usually large and originates from the dorsal body wall as a result of increased intra-abdominal pressure. In this case, the pony survived for two months as the bowel was only mildly compromised and did not become incarcerated thus, displaying signs of low grade colic.

CONCLUSION

In conclusion, the presenting clinical sign of low-grade colic, dyspnoea, and borborygmi within the thoracic cavity, were suggestive of diaphragmatic rupture and migration of abdominal contents into the thoracic cavity. Radiographic and ultrasonographic examinations confirmed the diagnosis. Survival of a horse with unrepaired diaphragmatic hernia depends on the abdominal organs eviscerated, whether the organs have incarcerated, and also the severity of the respiratory distress.

ACKNOWLEDGEMENT

The authors acknowledge the assistance of Dr. Christopher Riggs who rigorously reviewed this paper.

REFERENCES

- Bristol, D. G. (1986). Diaphragmatic Hernias in Horse and Cattle. *Compendium on Continuing Education for the Practicing Veterinarian*, 8(8), s407-s412.
- Dabareiner, R. M., & White, N. A. (1999). Surgical Repair of a Diaphragmatic Hernia in a Racehorse. *Journal of the American Veterinary Medical Association*, 214(10), 1517-8.
- Efraim, G., & Kelmer, G. (2015). Diaphragmatic Hernia in Horses in Israel: A Case Series. *Israel Journal of Veterinary Medicine*, 70(1), 37-44.
- Hart, S. K., & Brown, J. A. (2009). Diaphragmatic Hernia in Horses: 44 Cases (1986–2006). *Journal of Veterinary Emergency and Critical Care*, 19(4), 357-362.
- Malone, E. D., Farnsworth, K., Lennox, T., Tomlinson, J., & Sage, A. M. (2001). Thoracoscopic-Assisted Diaphragmatic Hernia Repair Using a Thoracic Rib Resection. *Veterinary Surgery*, 30(2), 175-178.
- Romero, A. E., & Rodgerson, D. H. (2010). Diaphragmatic Herniation in the Horse: 31 Cases from 2001–2006. *The Canadian Veterinary Journal*, 51(11), 1247-1250.
- Santschi, E. M., Juzwiak, J. S., Moll, H. D., & Slone, D. E. (1997). Diaphragmatic Hernia Repair in Three Young Horses. *Veterinary Surgery*, 26(3), 242-245.
- Schambourg, M. A., Laverty, S., Mullim, S., Fogarty, U. M., & Halley, J. (2003). Thoracic Trauma in Foals: Post Mortem Findings. *Equine Veterinary Journal*, 35(1), 78-81.
- Speirs, V. C., & Reynolds, W. T. (1976). Successful Repair of a Diaphragmatic Hernia in a Foal. *Equine Veterinary Journal*, 8(4), 170-172.
- Stick, J. A. (2006). Abdominal hernias. In J. A. Auer & J. A. Stick (Eds.), *Equine Surgery* (pp. 496-498). United States of America, USA: Elsevier.
- Wimberly, H. C., Andrews, E. J., & Haschek, W. M. (1977). Diaphragmatic Hernias in the Horse: A Review of the Literature and an Analysis of Six Additional Cases. *Journal of the American Veterinary Medical Association*, 170(12), 1404-1407.

