

The Epidemiology and Pathogenesis of Ovine Footrot in Malaysia



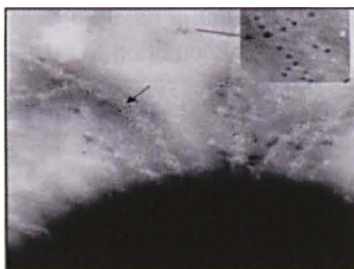
S. Jasni, K. Al-Jashamy, A. R. Mutalib, M. L. Mohd. Azmi, Z. Zakaria, S. Z. Ramanoon and A. R. Sheikh-Omar

The current study attempts to elucidate the prevalence and virulence of locally isolated strains of *D. nodosus* and the pathogenesis of the resulting disease lesion. Eight sheep farms were infected with *D. nodosus*. Five serogroups namely A, B, C, F and I as well as eight serotypes namely A1, A2, B1, B2, C1, F1, F2 and I were identified.

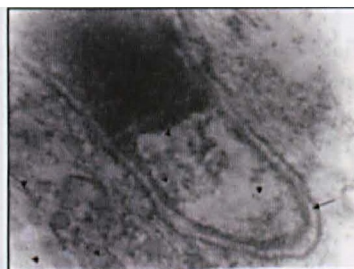
Virulent footrot observed was characterised by a grossly progressive separation of the horny tissues from the soft tissues. In severe cases, there was almost a complete separation of the wall from the under running structures.

Scanning electron microscopy showed that virulent *D. nodosus* produced a severe zone of lysis appearing as a surface depression around bacteria in the horny layer of the interdigital skin of the hoof. Transmission electron microscopy showed a degeneration of the basal cell layer and the basement membrane in both the epidermis and dermis.

Immunohistochemistry observations were found to be inadequate to validate the relationship between the lesions seen in the footrot and *D. nodosus* virulence. Specific reaction was labelled in intracellular components and the matrix of epidermis and dermis of the interdigital skin. Immunoperoxidase and immunogold staining techniques were developed to detect and localize *D. nodosus* for both light and electron microscopy. *Dichelobacter nodosus* antigen labelled with 5 nm gold particles was observed in the intracellular space of the epidermis. Immunostaining reaction of benign footrot lesions was less intense than of virulent footrot in the interdigital skin layers. We believe this is the first time that immunoperoxidase and immunogold labelling have been used in the ultrastructure study of footrot lesions.



Negative stained of virulent strain serogroup B of *D. nodosus*. Note the fimbriae are labelled with numerous 5 nm gold probes (arrows)



TEM of foot of sheep experimentally infected with virulent strain *D. nodosus* showing the gold labelling the bacterium with the gold probes 5nm in an intracellular space



Light photomicroscopy showing an intense immunoperoxidase reaction in the skin

Reader Enquiry

Faculty of Veterinary Medicine
Universiti Putra Malaysia
43400 UPM, Serdang, Selangor
Malaysia

Tel: +603 8946 8307

E-mail: jasni@vet.upm.edu.my