

## A Case of Familial Pheochromocytoma- Was It?

Siti Yazmin Zahari Sham\*,<sup>1</sup> Nor Aini Umar,<sup>2</sup> Khalidah Mazlan<sup>2</sup>

<sup>1</sup>Department of Pathology, Faculty of Medicine and Health Sciences,  
Universiti Putra Malaysia, 43400 Selangor

<sup>2</sup>Department of Pathology, Faculty of Medicine,  
Universiti Kebangsaan Malaysia, 56000, Kuala Lumpur

### ABSTRACT

With advancement in genetic studies, familial pheochromocytoma (PCC) and paraganglioma (PGL) are increasingly being recognized. Characteristically, correlations exist between genotypes and clinical and biochemical phenotypes. We report a pheochromocytoma in a young patient with intriguing family histories, raising the possibility of his being a familial case.

**Keywords:** Familial, pheochromocytoma, phenotype-genotype correlations

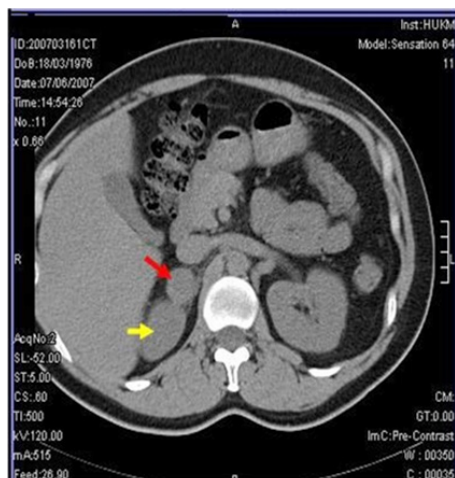
### INTRODUCTION

Pheochromocytomas (PCC) and paraganglioma (PGL) are catecholamine-producing chromaffin cell tumours of the adrenal medulla and extra-adrenal sympathetic paraganglia, respectively.<sup>1</sup> PGL usually arise in the abdomen and are functional, in contrast to those in the head and neck regions.<sup>2</sup> PCC/PGL is a rare cause of hypertension, accounting for 0.1-0.6% of cases.<sup>3</sup> Owing to its non-specific symptoms, which are shared by many other diseases, pheochromocytoma is aptly nicknamed as “the great mimic”.<sup>2</sup> This often leads to a delayed or even missed diagnosis, as reflected by a relatively higher prevalence in autopsy studies than in general population, at 0.05% and 0.015-0.04%, respectively.<sup>3</sup>

### CASE REPORT

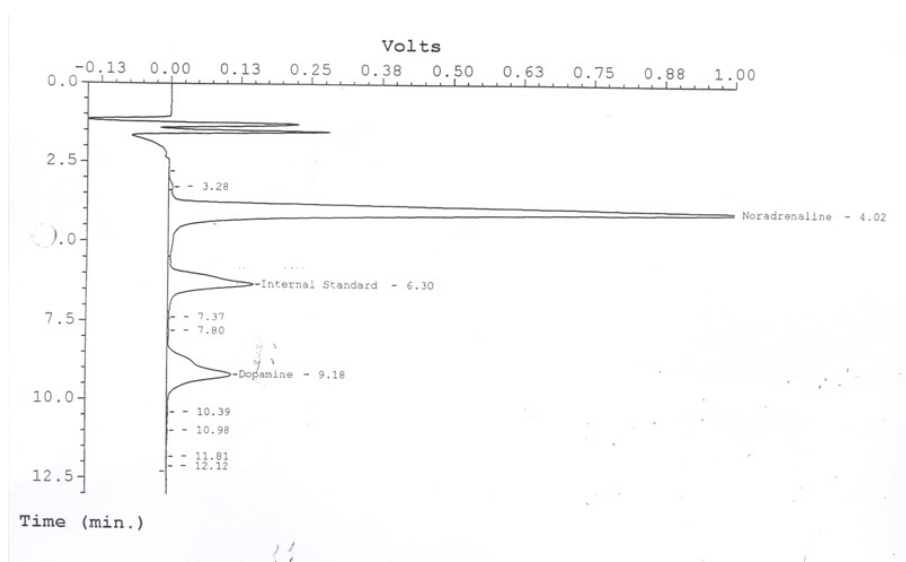
A 30 year old gentleman presented to Accident and Emergency department, feeling unwell, with headache, excessive sweating and palpitation. He recalled having them intermittently for the past five years. His father died of a heart attack whilst one of his paternal uncles had a sudden death, both in their 50s. His brother is also a hypertensive. On examination, his blood pressure was elevated at 204/140. ECG showed normal sinus rhythm with evidence of left ventricular hypertrophy, whilst his echocardiogram was normal. Renal artery stenosis was ruled out by abdominal ultrasound.

CT abdomen (Figure 1) showed a right adrenal mass, measuring 3.7 x 2.5 cm, which was suggestive of pheochromocytoma. His 24-h urinary fractionated catecholamines (Figure 2 and Table 1) showed elevated level of noradrenaline; whilst those of adrenaline and dopamine were within normal limits (Noradrenaline = 1363 µg/24h; adrenaline <3.0 µg/24h; Dopamine = 242 µg/24h).



**Figure 1:** Abdominal scan showing a right adrenal mass (→)

\*Corresponding author: Dr. Siti Yazmin Zahari Sham  
sitiyazmin@upm.edu.my



**Figure 2:** The chromatogram of 24-hour urinary fractionated catecholamines

**Table 1:** 24-hour urinary fractionated catecholamine

Noradrenaline	1362.7 (12.1-85.5 µg/24 h)
Adrenaline	<3.0 (1.7-22.4 µg/24 h)
Dopamine	242 (<498 µg/24 h)

Based on his classical clinical presentation, positive CT findings and elevated urinary catecholamines, a diagnosis of phaeochromocytoma was made. Post-operatively, the tumour was histologically confirmed and he was on a lifelong follow-up.

It was recently discovered that one of his paternal cousins had succumbed to a metastatic tumour of unknown origin. Thus this case may represent a case of familial phaeochromocytoma, given the above-mentioned family histories.

## DISCUSSION

In his case, other causes of secondary hypertension such as Cushing's syndrome, renal artery stenosis and hyperthyroidism were ruled out by normal findings of random cortisol, abdominal ultrasonography and thyroid function test, respectively. The classical symptoms of headaches, palpitations, and diaphoresis, if occur in triad in a hypertensive patient, is highly suggestive of PCC/PGL.<sup>4</sup> Clinically, the nature of his hypertension, which was sustained rather than paroxysmal, was suggestive of a noradrenaline-producing tumour.

Biochemical evidence of catecholamine overproduction is crucial for diagnosing phaeochromocytoma. Traditionally, this is achieved by urinary fractionated catecholamines (UFC). Unlike the parent catecholamine, the intra-tumoural production and secretion of the metabolite is continuous and independent.<sup>2</sup> Thus their measurement as either plasma free metanephrine (PFM) or urinary fractionated metanephrine (UFM) is more sensitive than that of the parent amine.<sup>2</sup> However, as UFM reflects the sulfate-conjugates of metanephrines, which are mainly gastrointestinal and not tumour in origin, PFM gives a higher diagnostic specificity.<sup>1,5</sup>

PFM is preferred by some authors to be used in high-risk population such as suspected familial PCC/PGL.<sup>3</sup> However, a normal PFM can be seen in strictly dopamine-secreting tumours.<sup>3</sup> Others believe that the choice of test should consider local expertise and experience as well as availability of the method of measurement.<sup>3</sup> Regardless, proper patient and sample preparation are of paramount importance for a valid interpretation of the results.

Recently, the traditional rule of 10% has been genetically challenged whereby up to 30% of cases are now shown to be hereditary, with 13 genes identified.<sup>1</sup> Syndromic familial PCC/PGLs occur in multiple endocrine neoplasia-2 (MEN-2), von Hippel-Lindau syndrome (VHL), neurofibromatosis type 1 (NF-1) and the familial paragangliomas; due to mutations of Rearranged Transfection (RET), VHL, NF-1 and the succinate dehydrogenase (SDH) subunits

(B, C, D) genes, respectively.<sup>1</sup> The latter is collectively known as SDHx.<sup>1</sup> SDHA mutation, on the other hand, is non-syndromic.<sup>1</sup> Interestingly, familial PCC/PGLs have been shown to display characteristic phenotype-genotype correlations.<sup>1,2</sup>

Genetically, familial PCC/PGL can be divided into “Cluster 1” (VHL and SDHx) or “Cluster 2” (MEN-2, NF-1), which are suggestive by their biochemical profiles and locations.<sup>1</sup> Adrenal tumours are most likely to be “Cluster 2” and are adrenergic in nature.<sup>1</sup> An exception is VHL which is usually noradrenergic despite being intra-adrenal.<sup>1</sup> In addition, solely noradrenaline-producing tumours point strongly to VHL.<sup>1</sup> In contrast, SDHx mutations are rarely adrenal and in addition to noradrenaline, they can also secrete dopamine.<sup>1</sup>

NF1 is usually diagnosed on clinical grounds, with no available genetic testing.<sup>4</sup> Being adrenaline-secreting, measurement of free metanephrines is superior in differentiating MEN-2 from “Cluster 1” tumours.<sup>5</sup> As SHDB or D may secrete dopamine, measurement of its metabolite, the free 3-methoxytyramine further distinguishes VHL from SHDx.<sup>5</sup> In addition, the marker is potentially useful in detection of metastatic diseases.<sup>1,3</sup>

Factors that suggested a familial pheochromocytoma in this patient include age<35 and suspicious family histories of sudden and tumour-related deaths, premature CVD and hypertension.<sup>4</sup> It is notable that all deaths occurred on his paternal side.

Despite being intra-adrenal, his strictly noradrenaline-secreting tumour was suggestive of VHL. However, VHL-associated features such as renal cyst were not found on imaging. Unlike MEN-2, in which the associated medullary thyroid carcinoma and primary hyperparathyroidism can be screened by serum calcitonin and calcium, respectively, biochemical screening has limited use in VHL. Such tests may include non-specific urinalysis and full blood count, looking for haematuria and polycythaemia, respectively.

A possible case of familial PCC mandates a life-long follow-up, during which a detailed family history would help us elucidate further the likelihood of and the most likely genetic mutation. Furthermore, VHL are often bilateral which may occur at different times.

In conclusion, pheochromocytomas are rare causes of hypertension with a devastating consequence in an event of a missed diagnosis. A possibility of a familial case should always be borne in mind. Although hypertension and cardiovascular disease (CVD) are common, premature CVD, sudden death and cancer-related death should raise suspicion. A definitive diagnosis of such, however, relies upon genetic testing, which is costly and unfortunately unavailable in Malaysia. Nevertheless, knowledge of the phenotype-genotype correlations should enable us to discriminate and cost-effectively utilize biochemical and genetic screening.

## REFERENCES

1. Tischler AS, Pacak K, Eisenhofer G. The adrenal medulla and extra-adrenal paraganglia: Then and now. *Endocr Pathol* 2014;25:49-58.
2. Beckel AV, Lenders JW, Timmers HJLM. Diagnosis of endocrine disease. Biochemical diagnosis of pheochromocytoma and paraganglioma. *Eur J Endocrinol* 2014; 170 (3):R109-R119.
3. Eisenhofer G, Pacak K, Maher ER, Young WF, de Krijger RR. Pheochromocytoma. *Clin Chem* 2013;59 (3):466-472.
4. Donckier JE, Michel L. Pheochromocytoma: State-of-the-art. *Acta Chir Belg* 2010; 110:140-148.
5. Davidson DF, Bradshaw N, Perry CG, Lindsay R, Freel EM. Urinary free (unconjugated) metanephrines in different hereditary forms of catecholamine-secreting pheochromocytoma/paraganglioma. *Ann Clin Biochem* 2012;49:486-490.