

COMPARISON OF TILETAMINE-ZOLAZEPAM AND TILETAMINE-ZOLAZEPAM-KETAMINE-XYLAZINE ADMINISTERED INTRAVENOUSLY IN DOGS

H.C. Chen¹, H.Y. Yeoh² and E.C. Yeoh²

¹Faculty of Veterinary Medicine, Universiti Putra Malaysia,
43400 UPM Serdang, Selangor, Malaysia

²Yeoh Veterinary Clinic and Surgery, 126, Jalan SS24/2, Taman Megah,
47300 Petaling Jaya, Selangor, Malaysia

SUMMARY

The anaesthetic effects of intravenous administration of tiletamine (2.5 mg/kg) – zolazepam (2.5 mg/kg) mixture (TZ), and tiletamine (0.5 mg/kg) – zolazepam (0.5 mg/kg) – ketamine (1.6 mg/kg) – xylazine (0.4 mg/kg) mixture (TKX) were evaluated in ten dogs. Atropine sulphate at a dose rate of 0.05 mg/kg was administered concurrently with the anaesthetic mixtures. Both mixtures produced rapid, smooth induction, and allowed intubation. The TKX mixture produced longer skin clamp analgesia and immobilisation, better jaw relaxation, with shorter and smoother recovery compared to TZ injection. The TKX mixture induced significant but transient pallor of mucous membranes (< 2 min). The TZ mixture resulted in increased heart rate and a higher respiratory rate compared to TKX mixture. Haemoglobin saturation was < 90% in some dogs following either mixture. The TKX mixture can be considered as an alternative injectable mixture to TZ for short and minimally invasive procedures in patients that have no cardiopulmonary dysfunction.

Keywords: anaesthetics, dogs, tiletamine-zolazepam, ketamine, xylazine

INTRODUCTION

Injectable anaesthetics are commonly employed to provide sedation, analgesia and immobilisation to facilitate examination and minor surgical procedures such as radiographic procedure, skin punch biopsy, superficial wound debridement and suturing, external reduction and stabilisation of fractures or luxation in small animals. The combination of tiletamine and zolazepam (TZ) at a ratio of 1:1 is available commercially, and is marketed as Zoletil® (Virbac Pty Ltd., NSW, Australia) or Telazol® (Fort Dodge Lab., IA, USA). The use of this combination, either alone, or with other anaesthetics or adjuncts has been described in cats, dogs, horses, ruminants, and exotic and wildlife species (Lin, 1996).

At the Universiti Putra Malaysia Veterinary Hospital, intravenous (IV) administration of the commercial TZ combination has routinely been used in both dogs and cats for minor procedures not lasting longer than 45-60 minutes. The typical practice involved an initial IV dose of 5 mg/kg and a top up of 1/3 to 1/2 of the initial IV dose when needed. This practice provided reliable immobilisation and appeared to be safe. However, recovery in dogs appeared to be rough. Muscle rigidity and seizure-like activity described by Short (1989) has also been observed in some dogs (Chen, unpublished observation). The relatively higher cost of the commercial TZ prompted a trial where ketamine and xylazine were added into the combination.

The use of the tiletamine, zolazepam, ketamine and xylazine mixture (TKX) has been reported in pigs (Ko *et al.*, 1993a; 1994), sheep (Lin *et al.*, 1994), cats (Ko *et al.*, 1993b; Dullard, 1994; Williams *et al.*, 2002), emus (Boyd and Day, 1995) and ferrets (Dullard, 1994). All have commented that it provides satisfactory restraint.

In Malaysia, some small animal practitioners have tried the TKX mixture in dogs and found it to be useful and reliable, with minimal morbidity (Yeoh, personal communication). The mixture is prepared by adding 4 ml of 100 mg/ml of ketamine and 1 ml of 100 mg/ml of xylazine into a vial of 250 mg freeze-dried TZ. The mixture is administered at an IV dose rate of 0.02 ml/kg with a maximum total dose of 0.5 ml per dog. A lower dose rate of 0.01 – 0.015 ml/kg is used on older dogs. To our knowledge, there are no objective studies documenting the duration of anaesthetic effects of the TKX combination in dogs. Therefore, this study was undertaken to evaluate and compare the anaesthetic effects of a pre-set dose of TKX mixture to the commercial TZ, administered intravenously in dogs.

MATERIALS AND METHODS

Animals

Ten adult local mixed-breed pound dogs, weighing 10.7 ± 1.6 (mean \pm SD) kg were used. They were judged to be normal based on physical examination and vital

signs. The dogs were adapted to individual kennels, fed on dry dog pellet and water *ad libitum*, daily leash-walk and handling for a minimum of three days before the study. Food was withheld 12 hours prior to each experiment.

Anaesthetic protocols

The two pre-set doses of anaesthetic mixtures were:

(i) TKX mixture:

0.5 mg/kg tiletamine, 0.5 mg/kg zolazepam, 1.6 mg/kg ketamine and 0.4 mg/kg xylazine.

The TKX mixture was prepared by adding 4.0 ml of 100 mg/ml ketamine (Ketavet 100® DELVET Pty Ltd, NSW, Australia) and 1.0 ml of 100 mg/ml xylazine (Xylazil 100® TROY Lab Pty Ltd, NSW, Australia) into a vial of freeze-dried 250 mg tiletamine-zolazepam (Zoletil® 50, Virbac Pty Ltd., NSW, Australia). The TKX mixture was administered at 0.02 ml/kg, similar to the dose rate used by the small animal practitioners.

(ii) TZ mixture:

2.5 mg/kg tiletamine and 2.5 mg/kg zolazepam.

The provided 5 ml diluent was used to reconstitute a vial of 250 mg freeze-dried tiletamine-zolazepam (Zoletil® 50, Virbac Pty Ltd., NSW, Australia). The TZ mixture was administered at 0.1 ml/kg.

Atropine sulphate (Atrosite, TROY Lab Pty Ltd., NSW, Australia) at a dosage of 0.05 mg/kg was mixed with the anaesthetics into the same syringe immediately prior to administration.

Experimental protocol and data collection

The dogs were assigned to the two anaesthetic mixtures in a cross-over design, with three days interval between each experiment. One observer evaluated and collected data from all the dogs. The observer was not blinded to the anaesthetic mixtures assigned.

Baseline (time at 0 minute) heart and respiratory rate were taken just before the IV induction. Once induced, and sufficient jaw relaxation was achieved, the dogs were intubated and placed on left lateral recumbency. Buccal mucous membrane colour, respiratory rate, heart rate, haemoglobin saturation, medial palpebral and pedal reflexes, and response to noxious stimulus were determined at two minutes following induction and subsequently at three minute intervals thereafter, until the dogs regained righting reflex. Respiratory rate was determined from observation of chest excursion and heart rate was based on chest auscultation using a stethoscope, both counted within 20 seconds. The haemoglobin saturation (SpO₂) was determined using pulse oximetry via the tongue probe (Vet Ox 44022® Sensor Devices Inc.,

Waukesha, USA). Medial palpebral reflex was elicited by gently touching the medial canthus. Pedal reflex was evaluated by finger-pinching the third interdigital web of the right hind limb. Superficial pain was stimulated using an Allis forcep to clamp (three ratchet) a fold of skin, incorporating the subcutaneous tissue at the last rib. A Rochester-Pean was used to clamp firmly (one ratchet) a tail segment incorporating a coccygeal vertebra to stimulate deep pain. Different skin folds and tail segments of adjacent sites were used subsequently to prevent tissue injury.

The time from injection to recumbency, first respiration, presence of response to skin clamp and tail clamp, return of medial palpebral and pedal reflex, intolerance to intubation, righting reflex, sternal recovery, standing and walking were noted. Increased respiratory rate, muscle fasciculations, vocalization, body movements or a combination of these were defined as response to noxious stimuli. The dogs were extubated when they showed swallowing reflex at least four times continuously. Return of righting reflex was taken as the time when the dog first lifted its head. Sternal recovery was taken as the time when the dog could maintain its sternal position without assistance. Standing was taken to be the time when the dog attempted to rise on all four legs. The quality of recovery was given a score of 1 to 5 as described below, with a higher score indicating better recovery:

Score 1 - Violent excitement during recovery

Score 2 - Ataxic before standing, several attempts to rise, very ataxic once standing

Score 3 - Quiet recovery, gained standing position after several attempts, ataxic when standing or walking

Score 4 - Good quiet recovery, gained standing position at first attempt, mildly ataxic when standing or walking

Score 5 - Good quiet recovery, gained standing position at first attempt, not ataxic when standing or walking

The data were analysed for anaesthetic effect using paired t-test, Wilcoxon sign rank test and ANOVA for repeated measures as appropriate. Within the anaesthetic mixtures, Dunnett's test was applied to compare for differences from baseline. A *p*-value of < 0.05 was considered significant.

RESULTS

The duration of anaesthetic effects for both combinations are summarised in Table 1. All dogs became recumbent rapidly following IV administration of either mixture, with no difference between them. The duration of apnoea (time from injection to first respiration) was significantly shorter in TKX treated dogs. All dogs induced with both the anaesthetic mixtures could be

Table 1: Duration of anesthetic effects following intravenous administration of TZ (tiletamine-zolazepam) and TKX (tiletamine-zolazepam-ketamine-xylazine).

Parameters	TZ	TKX	p-value
TI to recumbency (second)	13.3 ± 0.96	14.8 ± 0.63	0.234
TI to first respiration (second)	48.4 ± 3.15	35.00 ± 2.88	0.000*
Duration of intubation (minute)	18.8 ± 3.06	15.90 ± 1.43	0.401
TI to skin clamp positive response (minute)	8.00 ± 1.26	17.30 ± 1.92	0.010*
TI to tail clamp positive response (minute)	5.00 ± 0.00	5.90 ± 0.46	0.081
TI to presence of pedal reflex (minute)	8.90 ± 2.10	18.2 ± 2.06	0.015*
TI to righting reflex (minute)	30.8 ± 4.03	21.00 ± 2.06	0.085
TI to sternal recovery (minute)	36.20 ± 3.73	23.10 ± 2.48	0.035*
TI to standing or walking (minute)	55.6 ± 6.78	28.90 ± 2.32	0.008*

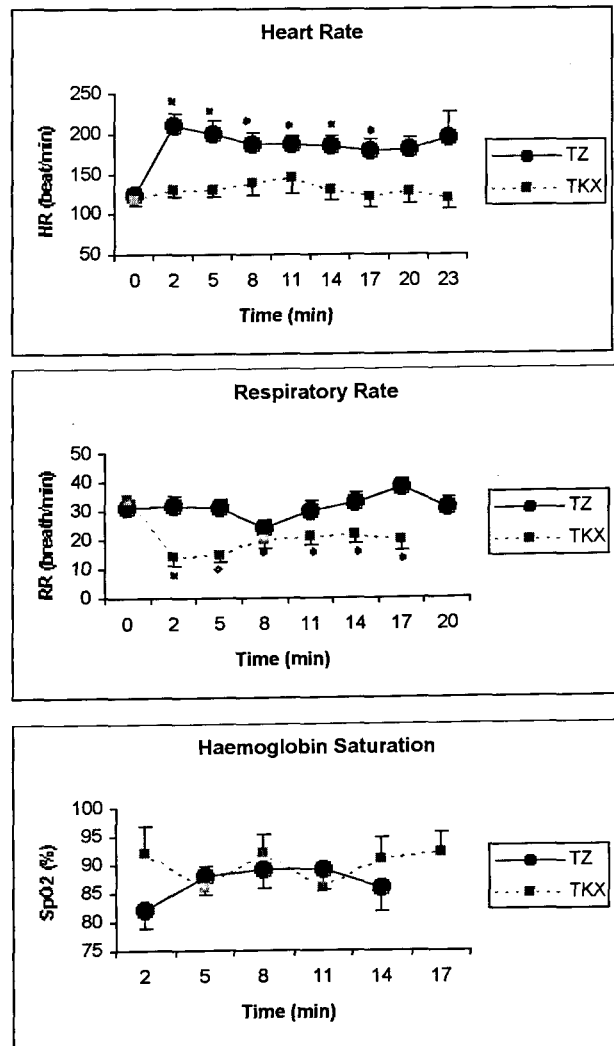
intubated without difficulty, although four dogs induced with TZ still maintained some degree of jaw tone. There was no difference between TZ and TKX for the duration of intubation.

The duration of skin clamp analgesia (time from injection to the presence of positive response to skin clamp) and absence of pedal reflex were significantly longer with TKX. Tail clamp analgesia also tended to last longer with TKX administration but was not significant. However, time from injection to righting reflex tended to be shorter with TKX. Time from injection to sternal recovery, and standing or walking was significantly shorter with TKX administration.

All dogs induced with TKX showed pallor of the mucous membrane immediately after induction, and returned to normal (pink) at 2 minutes. Mucous membranes remained pink following TZ administration in all dogs. All dogs had strong palpebral reflexes at two minutes following TZ administration, while 50% of the dogs had mild reflexes after TKX administration.

There was no significant change in the heart rate with TKX, but heart rate was elevated after injection of TZ (Figure 1). Respiratory rate decreased and remained low after TKX injection, while TZ-treated dogs had higher respiratory rate. Two of the dogs showed irregular and shallow breathing following TZ administration. Haemoglobin saturation was low immediately after induction and gradually increased over time in both groups. Following TZ administration, five dogs had SpO₂ less than 90%. With TKX administration, seven dogs did not register any SpO₂ reading at two minutes, and only 6 dogs registered readings thereafter.

The TKX-treated dogs showed significantly smoother recovery (median score of 4) compared to the TZ (median score of 2.5) treatment. Ataxia was present during all stages of recovery following TZ, and dogs tended to hit their head on the ground during sternal recovery if left unassisted.



Data are expressed as mean ± SEM

* Significantly different ($p < 0.05$) from baseline (0 min)

Fig. 1. Effects on heart rate, respiratory rate and haemoglobin saturation following intravenous administration of TZ (tiletamine-zolazepam) and TKX (tiletamine-zolazepam-ketamine-xylazine)

DISCUSSION

This study demonstrated that both the TZ and TKX anaesthetic mixtures resulted in rapid, smooth induction, and enabled intubation. This study also showed that the addition of ketamine (1.6 mg/kg) and xylazine (0.4 mg/kg) to a lesser dose of the TZ mixture resulted in longer duration of skin clamp analgesia and absence of pedal reflex, yet offered shorter recovery time and better recovery score. The longer duration of skin clamp analgesia and absence of pedal reflex in TKX-treated animals were likely attributed to xylazine. Xylazine is known to provide analgesia via stimulation of the central α_2 -receptors (Hsu, 1981). It is also known to cause good muscle relaxation (Hsu, 1981); this was manifested as better jaw relaxation during intubation in this study. In dogs given xylazine at a dose rate of 2.2 mg/kg intramuscularly, the mean arousal time and mean walk time were 15.5 and 24.8 minutes respectively, and these were shortened significantly following administration of yohimbine (Hatch *et al.*, 1985). Both yohimbine and atipamezole (α_2 -antagonists) have been used to reverse the residual effect of xylazine to hasten recovery following IV administration of TKX (Yeoh, personal communication). When reversal of an α_2 -agonist is needed, atipamezole, a more specific α_2 -antagonist would be preferred, as yohimbine can occasionally produce hypotension (α_2 blockade) and tachycardia (Muir, 2002). The undesirable effects of yohimbine may be prevented by slow IV administration to achieve the desired arousal, or by intramuscular injection (Muir, 2002).

The smoother recovery following TKX administration was likely a reflection of the residual sedative effect of xylazine and relatively smaller amount of tiletamine in the mixture. The characteristic rough recovery of the dogs given TZ alone may be explained by the longer plasma half-life of the dissociative drug tiletamine (1.2 hour), compared to zolazepam (1 hour) (Baukema and Glazko, 1975).

Intense vasoconstriction and increased vascular resistance following stimulation of the α_2 -receptors in the vascular smooth muscles by xylazine is most prominent following intravenous administration (Klide *et al.* 1975). This explains the pale mucous membranes and failure of the pulse oximeter to detect the vascular pulsation signal immediately after TKX administration in this study.

The significant increase in the heart rate following TZ was likely due to the combined sympathetic-stimulating effect of tiletamine and the vagolytic effect of atropine. Even without the addition of atropine, IV administration of TZ alone has been shown to increase the heart rate (Hellyer *et al.*, 1989). The absence of elevation in the heart rate following TKX administration was likely due to the sympathomimetic effect of the combination of atropine, ketamine and tiletamine being antagonized by the xylazine-induced reflex-bradycardia

(Tranquilli, 2002). Although blood pressure was not measured in this study, xylazine is well known to cause immediate hypertension due to the intensified vasoconstriction, leading to the baroreceptor-mediated reflex-bradycardia (Tranquilli, 2002). It is likely that all the dogs were hypertensive immediately following TKX. However, the vagolytic effect of atropine prevented the reflex-bradycardia, resulting in an unchanged heart rate. In this study, atropine was used with the rationale to prevent potential hypersalivation following TZ administration, and bradycardia following TKX administration. Besides atropine, glycopyrrolate (another anticholinergic agent) can be used for similar purpose. Whether an anticholinergic should be added to an α_2 -agonist to prevent bradycardia has been debated. A recent study (Sinclair *et al.*, 2003) showed that concurrent use of glycopyrrolate with romifidine (an α_2 -agonist) worsened cardiac performance, increased wall stress and myocardial workload. Therefore, routine use of an anticholinergic together with an α_2 -agonist is not recommended, especially in patients with cardiopulmonary dysfunction. In our study, all dogs showed tachycardia following concurrent administration of atropine and TZ. This raises concerns on the increased myocardial workload and oxygen consumption. In retrospect, this study should probably not have included atropine in the anaesthetic protocol. The degree to which potential hypersalivation or bradycardia could have been detrimental without an anticholinergic in the anaesthetic protocol remains to be determined.

Overall, the average respiratory rate was lower following TKX administration, but the period of apnoea was slightly longer immediately after TZ administration. The longer period of apnoea probably explained the lower mean SpO₂ at two minutes following TZ. However, the higher mean SpO₂ at two minutes following TKX was based on only 3 readings since the pulse oximeter failed to register any reading in the other 7 dogs. This higher mean value may be biased and not adequate for comparison with TZ to evaluate the pulmonary function. It is also important to remember that the SpO₂ reading can be influenced by ambient light and local vascular pulsation signal, which is in turn influenced by systemic blood pressure, volume status, vasoconstriction and hypothermia (Grubb, 2002). Ideally, measurement of the arterial carbon dioxide and oxygen tension would better evaluate adequacy of the ventilatory function; however, we were limited by cost and availability of equipment.

It is recommended that the haemoglobin saturation should be maintained at 90% or higher to prevent hypoxemia (Grubb, 2002). There is no definite recommendation on a maximum duration of hypoxemia that is 'safe' without causing detrimental effect. In this study, approximately 50% of the readings in the TZ-treated group, and 20% in the TKX-treated group registered readings that were lower than 90%. Therefore, it is advisable to standby supplemental oxygen in the event

that patients continue to desaturate when using either the TZ or TKX mixtures.

Both mixtures produced very short duration of tail clamp analgesia, indicating that these regimens are not suitable for invasive and painful procedures that last longer than 5 minutes. It may be possible to deepen and prolong the effects of both anaesthetic mixtures with additional top-ups. However, the total top-ups should be limited as this could result in cumulative effect and prolonged recovery. Furthermore, prolonged sub-optimal oxygenation in room air without supplemental oxygen may compromise normal tissue function and lead to potential tissue damage. Further study on the clinically relevant effects of additional top-up with these mixtures would be helpful to guide practitioners.

In this study, the cost of TKX was one-third that of TZ. It is an attractive alternative to TZ, as it produces longer duration of superficial analgesia and immobilization, better muscle relaxation, with shorter and smoother recovery. However, as with any anaesthetic protocols that contain an α_2 -agonist, its use should be restricted to patients without suspected or potential cardiopulmonary dysfunction (Tranquilli, 2002). Patients should be exercise tolerant at a minimum and should have no overt signs of cardiopulmonary disease.

In conclusion, TKX can be considered as an alternative injectable anaesthetic mixture to TZ. It can be used either for induction of anaesthesia prior to inhalant maintenance, or for short and minimally invasive procedures in patients without cardiopulmonary dysfunction.

REFERENCES

- Baukema, J. and Glazko, A.J. (1975). Metabolic disposition of C1-744 in cats and dogs. Data on file. Parke-Davis & Co. Ann Arbor, Michigan.
- Boyd, K.L. and Day T.K. (1995). Evaluation of intramuscular xylazine-ketamine and Telazol-ketamine-xylazine in Adult Emus. In: Scientific Abstract from the 1995 American College of Veterinary Anesthesiologists Meeting, Atlanta, American College of Veterinary Anesthesiologists. pp. 179.
- Dullard, S. (1994). TKX mixture successful in 80 cats - and a ferret. *Vet. Med.* **89**: 406.
- Grubb, T. (2002). Pulse oximetry. In: *Veterinary Anesthesia and Pain Management Secrets*, ed. Greene, S.A. Philadelphia: Hanley & Belfus, Inc. pp. 121-126.
- Hatch, R.C., Kitzman, J.V., Zahner, J.M. and Clark, J.D. (1985). Antagonism of xylazine sedation with yohimbine, 4-aminopyridine and doxapram in dogs. *Am. J. Vet. Res.* **46**: 371 - 375.
- Hellyer, P., Muir, W.W., Hubbell, J.A.E. and Sally, J. (1989). Cardiorespiratory effects of the intravenous administration of tiletamine-zolazepam to dogs. *Vet. Surg.* **18**: 160 - 165.
- Hsu, W.H. (1981). Xylazine induced depression and its antagonism by alpha-adrenergic blocking agents. *J Pharmacol Exp Ther* **218**: 188-192.
- Klide, A.M., Calderwood, H.W. and Soma, L.R. (1975). Cardiopulmonary effects of xylazine in dogs. *Am. J. Vet. Res.* **36**: 931 - 935.
- Ko, J.C.H., Thurmon, J.C., Benson, G.J. and Tranquilli, W.J. (1993a). An alternative drug combination for use in declawing and castrating cats. *Vet. Med.* **88**: 1061 - 1065.
- Ko, J.C.H., Thurmon, J.C., Benson G.J., Tranquilli, W.J. and Olson, W.A. (1993b). A new drug combination for use in porcine cesarean sections. *Vet. Med.* **88**: 466 - 472.
- Ko, J.C.H., Thurmon, J.C., Benson, G.J. and Tranquilli, W.J. (1994). Using Telazol-ketamine-xylazine anesthesia for castration of cryptochid pigs. *Vet. Med.* **89**: 999 - 1002.
- Lin, H.C. (1996). Dissociative anesthetics. In: *Lumbs and Jones' Veterinary Anesthesia*, ed. Thurmon, J.C., Tranquilli, W.J. and Benson, G.J. (Eds.), 3rd ed. Baltimore: Williams & Wilkins. pp. 241-296.
- Lin, H.C., Wallace, S.S., Tyler, J.W., Robbins, R.L., Thurmon, J.C. and Wolfe, D.F. (1994). Comparison of tiletamine-zolazepam-ketamine and tiletamine-zolazepam-ketamine-xylazine anaesthesia in sheep. *Aust. Vet. J.* **71**: 239 -242.
- Muir, W.W.III (2002). Drug antagonism and antagonists. In: *Handbook of Veterinary Pain Management*, ed. Gaynor, J.S. and Muir, W.W. III. St. Louis: Mosby. pp. 393 - 404.
- Short, C.E. (1989). Talking about telazol: Roundtable. *Vet. Med.* **84**:1.
- Sinclair, M.D., O'Grady, M.R., Kerr, C.L and McDonell, W.N. (2003). The echocardiographic effects of romifidine in dogs with and without prior or concurrent administration of glycopyrrolate. *Vet. Anaes. Anal.* **30**: 211-219.

Tranquilli, W.J. (2002). α_2 -agonist. In: *Veterinary Anesthesia and Pain Management Secrets*, ed. Greene, S.A. Philadelphia: Hanley & Belfus, Inc. pp. 83-86.

Williams, L.S., Levy, J.K., Robertson, S. A., Cistola, A.M., Centonze, L.A. (2002). Use of the anesthetic combination of tiletamine, zolazepam, ketamine and xylazine for neutering feral cats. *J. Am. Vet. Med. Assoc.* **10**: 1491-1495.