

Trisomy X and Myelodysplastic Syndrome (MDS) with Eosinophilia

¹RMT Eusni*, ²CF Leong & ²S Salwati

¹Department of Pathology, Faculty of Medicine & Health Sciences, University Putra Malaysia,

²Department of Pathology, Faculty of Medicine, National University of Malaysia.

ABSTRACT

We reported a young patient with myelodysplastic syndrome (MDS) with eosinophilia, in which her chromosomal analysis revealed the presence of trisomy X and a marker chromosome at chromosome 11. The technique used to detect the chromosomal abnormalities is a multicoloured –fluorescent *in situ* hybridization technique (M-FISH). Our observation suggested that these underlying chromosomal abnormalities were probably responsible for her development of MDS with eosinophilia.

Myelodysplastic syndrome (MDS) is a condition whereby there is ineffective production of haematopoietic stem cells and poor quality of cells produced. The cause can either be a primary bone marrow problem, de novo or therapy related. Most MDS cases are secondary rather than primary. Many chromosomal abnormalities have been found in cases of myelodysplastic syndrome. We described a case of MDS with eosinophilia in association with presence of trisomy X and a marker chromosome in chromosome 11.

Keywords: myelodysplastic syndrome, eosinophilia, trisomy X

INTRODUCTION

Myelodysplastic syndromes (MDS) are a group of clonal haematopoietic stem cell diseases characterized by dysplasia and ineffective haematopoiesis in one or more of the major myeloid cell lines [1]. It occurs predominantly in elderly individuals. MDS with eosinophilia is a rare entity under the syndromes. Most of the patients with these entities has chromosomal abnormalities, in particular chromosome 7. These patients usually have poor survival due to rapid evolution to acute leukaemia. We report here a case of a young patient who had myelodysplastic syndrome and with underlying abnormal cytogenetic findings involving trisomy X and presence of a marker chromosome at chromosome 11.

CASE REPORT

In our institution we were presented with a 21-year-old Malaysian student with worsening symptoms of anaemia and bleeding tendencies (spontaneous bruises, gum bleeding, menorrhagia) of 2-month duration. There were no other sources of bleeding tendencies or any evidence of blood loss. Physical examination revealed she had pallor and hepatosplenomegaly. Other systems examination was unremarkable.

Initial investigations showed severe anaemia with haemoglobin level of 52 G/L, her total white cell count was $10.2 \times 10^9/L$ and her platelet count was $67 \times 10^9/L$. Differential count showed moderate eosinophilia of $1.8 \times 10^9/L$. Peripheral blood picture showed hypochromic microcytic anaemia, thrombocytopenia and eosinophilia with dysplastic features (multilobulated and hypogranularity). Biochemical investigations and bone marrow aspirate Perl's stain revealed iron deficiency state. A bone marrow aspirate revealed hypercellular marrow with dysplastic features seen in erythroid, granulocytic & megakaryocytic lineage (Figure 1). Eosinophil precursors were increased up to 5% and morphologically dysplastic. The trephine biopsy showed dysplastic and megaloblastic features in the erythroid and megakaryocytic lineage. Abnormal localisations of immature precursors (ALIPs) were not seen. Eosinophil precursors were increased. The chromosomal analysis using conventional cytogenetic banding (G banding) initially showed presence of an extra chromosome X. For further confirmation, the investigation then proceeded further to multicoloured fluorescent *in situ* hybridization (M-FISH) which confirmed a trisomy X with an additional presence of a marker chromosome in chromosome 11. Microbiological & serological tests did not provide any evidence of bacterial or parasitic infection, nor autoimmune disease, to suggest secondary causes of her eosinophilia. Thus, a final diagnosis of iron deficiency anaemia with underlying myelodysplastic syndrome with eosinophilia, associated with trisomy X was proposed. Her eosinophilia was persistently elevated up to $4.6 \times 10^9/L$ after 1 month of presentation. She was treated with prednisolone for six months and eosinophils count normalized following the treatment. Her

*Corresponding author: eusni@medic.upm.edu.my

anaemia responded partially to haematinics therapy and blood product support. Her thrombocytopenia was worsening. Due to her young age and the presence of clonal chromosomal abnormalities, she was planned for allogeneic peripheral blood stem cell transplant (alloPBSCT) with an HLA matched siblings. However, she defaulted follow up when the option was made known to her.

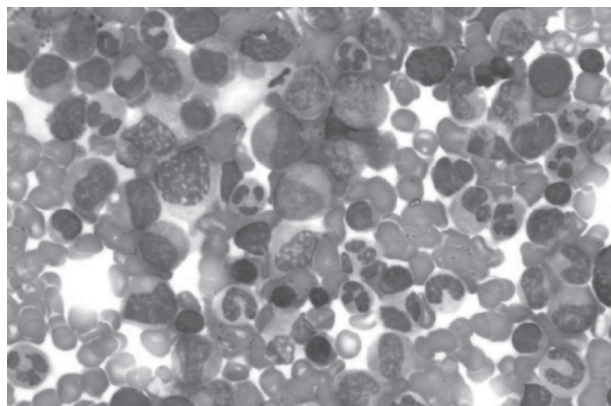


Figure 1. Bone marrow aspirate reveal hypercellular with dysplasia and megaloblastic changes seen in the erythropoietic and granulopoietic cell lines

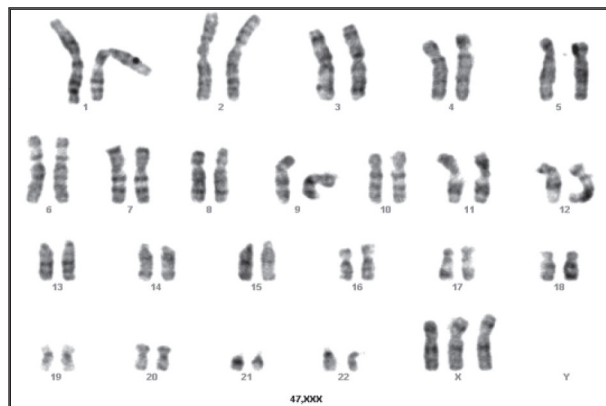


Figure 2. Cytogenetic G banding showing an extra chromosome X (arrow) ,47,XXX

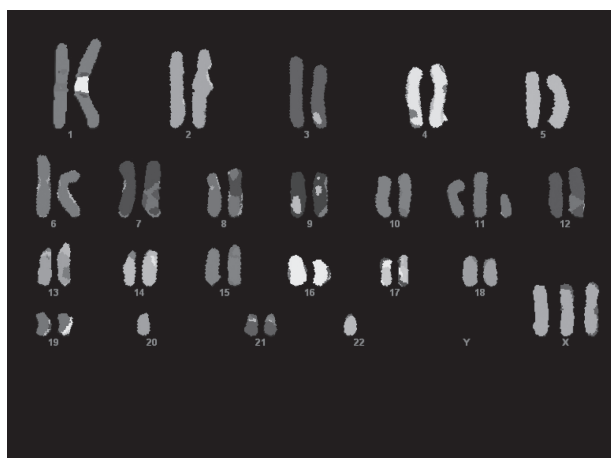


Figure 3. Further analysis using multicoloured fluorescent in situ hybridization (M-FISH) revealed trisomy X and a presence of marker chromosome at chromosome 11 (arrow)




Figure 4. The presence of trisomy X using CEPX, a specific probe targeted towards the centromere region of chromosome X

DISCUSSION

Myelodysplastic syndrome (MDS) is a condition whereby genetically injured haemopoietic stem cells populate the marrow and lead to ineffective production of haemopoietic cells and reduction in quality of cells produced. MDS with eosinophilia is not a well recognized entity. Cytogenetic abnormalities common in MDS with eosinophilia are trisomy 8^[1] and monosomy 7^[2]. However, the presence of primary MDS with eosinophilia & trisomy X was not reported before except for a report by Wan TS *et al* (2002) whereby he noted the presence of eosinophilia and trisomy X in which the patient developed acute leukaemia and she succumbed during induction treatment probably due to release of granules in eosinophils leading to diffuse alveolar damage and pulmonary hemorrhage leading to her death^[3]. The occurrence of these cytogenetic findings ie trisomy 8, monosomy 7 and trisomy X generally confers poor prognosis in term of shorten survival and rapid evolution toward acute leukaemia except for del5q which generally confers good prognosis but in del5q, eosinophilia was not a common association^[4].

The M-FISH technique used in this case had added value whereby an additional presence of a marker chromosome was identified in chromosome 11 which was not detected using GTG- banding technique. Patients presented with MDS with eosinophilia should be thoroughly investigated to rule out the secondary causes of eosinophilia, as shown

in this case and a complete cytogenetic analysis, which may or may not include M-FISH as the presence or absence of cytogenetic abnormality is helpful in the prognosis and management of these cases. However, the decision to embark on such specialized tools will depend on the technical skills available in the laboratory, the costs involved and the intensity of labour and it has to be weighed whether it will provide useful extra diagnostic information, which help to prognosticate and with the management of these cases.

Prognosis in MDS is related to the morphological classification, cytogenetic findings and percentage of blasts in the bone marrow aspirates.^[4] Using these criteria, the International Prognostic Scoring System (IPSS) has developed a scoring system in predicting survival and evolution to acute leukemia i.e: low 0, intermediate (INT) 1: 0.5-1, INT 2: 1.5-2.0 and high >2.5^[4]. As for this patient she would fall into the INT 1 risk group, with a score of 1, based on the bilineage cytopenia (anaemia and thrombocytopenia- a score of 0.5, bone marrow blast of < 5%, - a score of 0, and cytogenetic findings of intermediate risk: all other abnormalities, - a score of 0.5). Some investigators have put morphology of MDS with refractory cytopenias and multilineage dysplasia, as a high-risk morphology. The frequency of evolution into acute leukemia is 11%^[4]. However, considering her age is less than 60 her prognosis may be better. The overall median survival is 33 - 41 months^[4]. In British Journal of Hematology (BJH) guidelines for adult MDS, median survival for INT 1 less than 60 years old is 5.2 years^[4]. A recent study by Friedrich *et al* (2010) has reported that presence of eosinophilia and/or basophilia as part of presentation in MDS has an impact whereby the survival is shorter in this group of patient as compared to those without eosinophilia and /or basophilia^[5].

As for this case the presence of more than 1 cytogenetic abnormality add to the poor prognosis in myelodysplastic syndrome^[4]. Hence, the option for this patient was allogeneic stem cell transplantation, as stated above.

The association of MDS with eosinophilia and trisomy X is yet to be known. Further studies need to be done to precisely understand the association of trisomy X and development of MDS with eosinophilia.

In conclusion, the association of trisomy X and marker chromosome in chromosome 11 with MDS with eosinophilia has not been reported before and this adds to the list of clonal cytogenetic abnormalities present in primary myelodysplastic syndrome. Hence, further study is needed to look into the mechanisms behind the cytogenetic abnormalities leading to MDS with eosinophilia.

REFERENCES

- [1] Doorduijn JK, Van Lom K, Lowenberg B. Eosinophilia and granulocytic dysplasia terminating in acute myeloid leukaemia after 24 years. *British Journal of Haematology* 1996; 95: 531-4.
- [2] Kwong YL, Chan LC. Involvement of eosinophils in acute myeloid leukaemia with monosomy 7 demonstrated by fluorescence *in situ* hybridization. *British Journal of Haematology* 1994; 88: 389-91.
- [3] Wan TS, Yip SF, Yeung YM, Chan LC, Ma SK. Fatal diffuse alveolar damage complicating acute myeloid leukemia with abnormal eosinophils and trisomy X, *Ann Hematol* 2002; 81: 167-9.
- [4] Guidelines for the diagnosis and therapy of adult Myelodysplastic Syndrome, *Br J Hematol* 2003, 120, 187-200.
- [5] Friedrich W, Ulrich G, Michael K, Thomas N, Sabine B, Philip G *et al*, Evaluation of the prognostic significance of eosinophilia and basophilia in a larger cohort of patients with myelodysplastic syndromes. *Cancer* 2010; 116: 2372-81.

