

Case Report

MANAGEMENT OF DISTAL TARSOMETATARSAL FRACTURE IN A HILL MYNAH (*GRACULA RELIGIOSA*) BY USING EXTERNAL COAPTATION TECHNIQUE

A. Jalila, A. R. Nor Alimah and I. Aini

Faculty of Veterinary Medicine, University Putra Malaysia
43400 UPM Serdang, Selangor, Malaysia

SUMMARY

An adult Hill Mynah (*Gracula religiosa*) was presented with non weight-bearing lameness on the left leg. A distal transverse fracture of the left tarsometatarsus was diagnosed by using radiography techniques. A combination of external coaptation using tape splint and ball bandage was applied. It was found that this combination technique resulted in a clinical union of the fractured site at three weeks post-treatment. This technique also provided perching and movement stability in the cage. The success of this combination technique offers another alternative for external coaptation in avian species.

Keywords: Fracture, tarsometatarsus, tape splint, ball bandage, avian, hill mynah, *Gracula religiosa*

INTRODUCTION

External coaptation is an inexpensive, rapid method that provides increased comfort to a patient with fracture. Various fixation techniques have been used in avian species to stabilise fractured bones. The techniques include external coaptations, internal fixations and external fixation of various types (Redig, 1986; Martin and Ritchie, 1994; Redig *et al.*, 2001; Bennette and Kuzma, 1992). Commonly used external coaptation techniques to stabilise leg fracture or leg injuries in avian cases are bandaging and splinting such as Altman tape splint, ball bandage and Robert Jones bandage (Redig 2000a; Redig and Ackermann, 2000). This paper reports a case of fracture distal tarsometatarsus that was managed using a combination of tape splint and ball bandage techniques.

CASE REPORT

An adult male hill mynah (*Gracula religiosa*), weighing 200 g with a history of lameness resulting from a leg fracture was referred for further treatment at the Veterinary Teaching Hospital, Universiti Putra Malaysia. The bird was kept in a medium sized cage (50 cm x 50 cm x 30cm) with weekly cleaning. The bird was fed on commercial hill mynah diet, fresh fruits and water, provided on a daily basis. The owner noticed that the bird's leg was trapped in between the cage floor when the bird was attacked by the owner's dog. The owner applied a simple bandage on the affected leg as a temporary stabilisation technique. There was no topical medication applied on the wound area.

Physical examination revealed a bruised area and a swollen left tarsometatarsus that was twice the normal

size (Figure 1). Palpation revealed discontinuity of tarsometatarsal bone. A skin scar of 0.5 mm (Figure 2) was suggestive of an open fracture. No bones were exposed at the time of presentation. Ventral-dorsal and lateral radiographs revealed distal transverse fracture of the left tarsometatarsus (Figure 3). Topical dimethyl sulfoxide (AnalaR®, 78.13g/mol, VWR International Ltd England) was applied once every 3 days for two treatments. The tape splint using any ordinary masking tape from a stationery store was applied on the affected bone (Figure 4). Since the fractured area was very distal, movement of the digit would result in fracture site movement. Therefore, a ball bandage was applied to stabilise the affected area without compromising the ability to perch (Figures 5 and 6). The ball bandage and tape splint techniques used are as described by Degerness (1994) and Tully (2009).

At two weeks post-application of the external coaptation techniques, a callus was palpable. At three weeks post-application, the fracture site was stable. Radiography confirmed complete union of the left tarsometarsul fracture with acceptable bone alignment (Figure 7). The leg function was good and the bird was able to grab the perch and food as usual.

DISCUSSION

The pet Hill Mynah was presented with a left tarsus metatarsal fracture that was managed successfully by using a combination of tape splint and ball bandage. This technique is acceptable as a primary stabilisation technique with various factors that should be considered. Some of the factors to be considered in fracture cases are a limited post-fracture range of motion is satisfactory, a

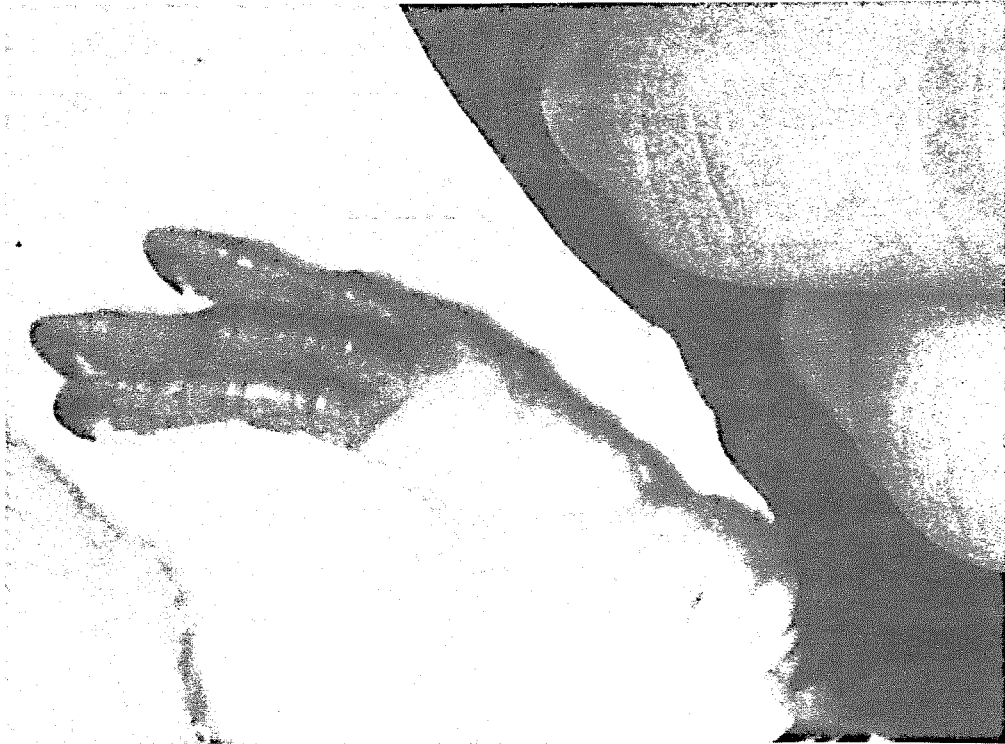

Figure 1: Bruised area on the affected leg on admission day and bandaging technique applied by the owner (white arrow)

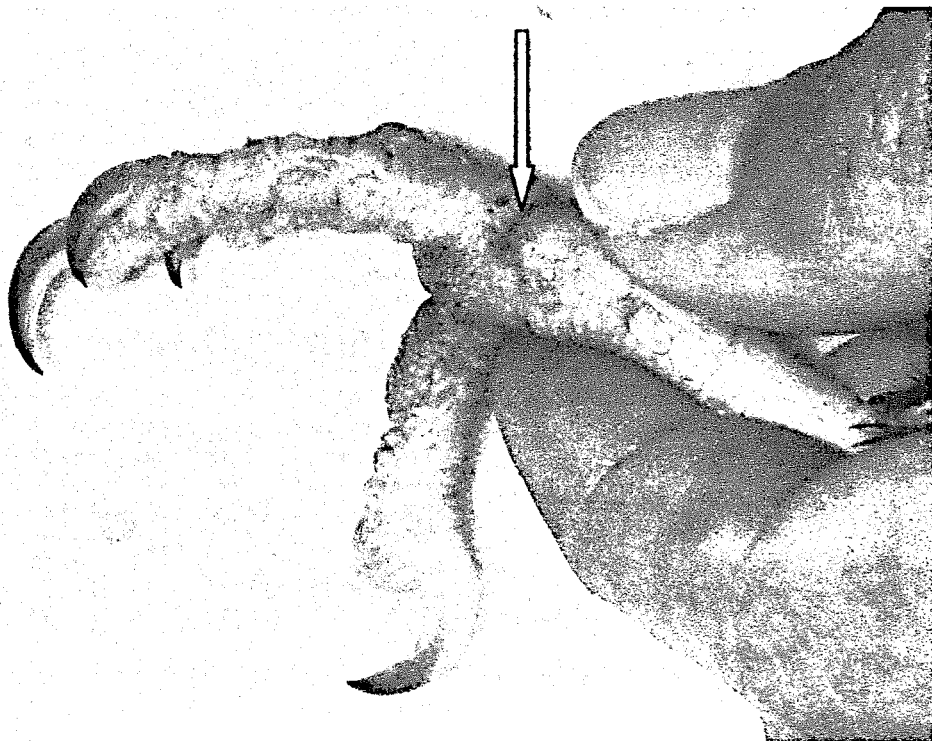


Figure 2: Healed skin tear on lateral left tarsometatarsas (white arrow)

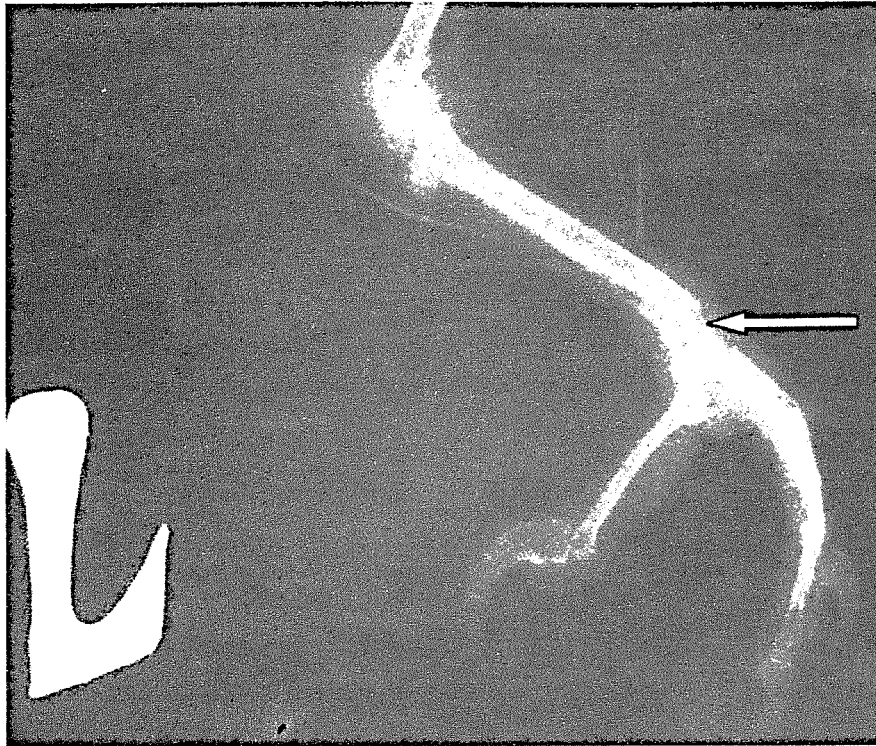


Figure 3: Radiograph showed distal oblique tarsometatarsal fracture taken on admission day (white arrow)

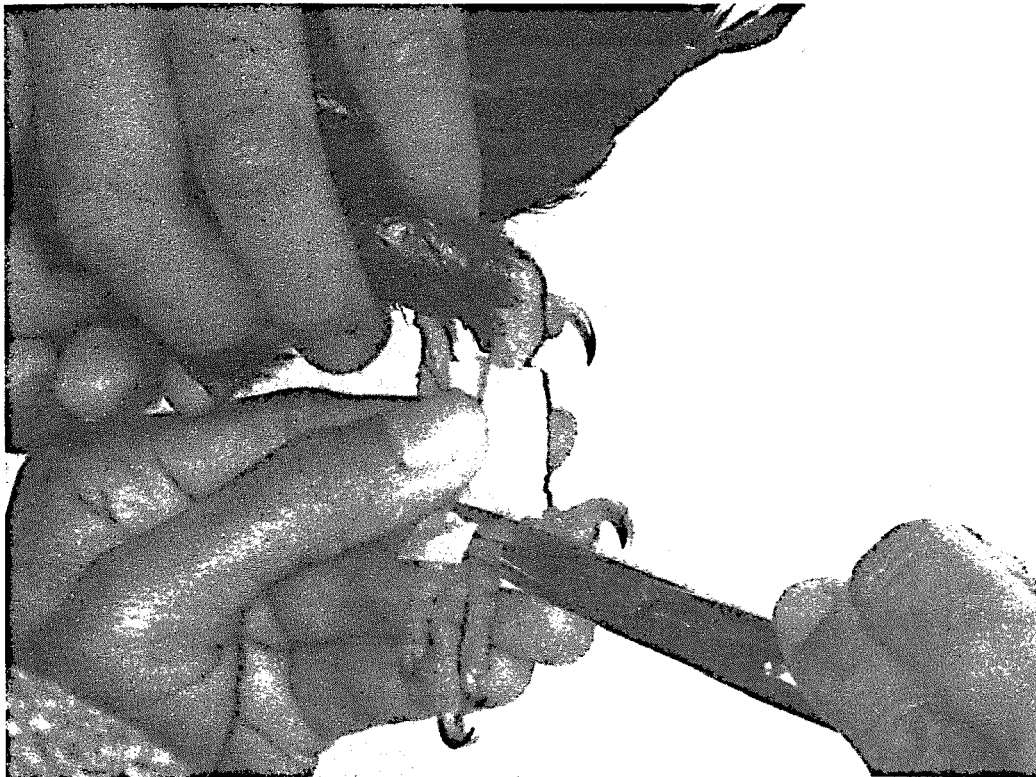


Figure 4: Application of tape splint on left tarsometatarsal bone

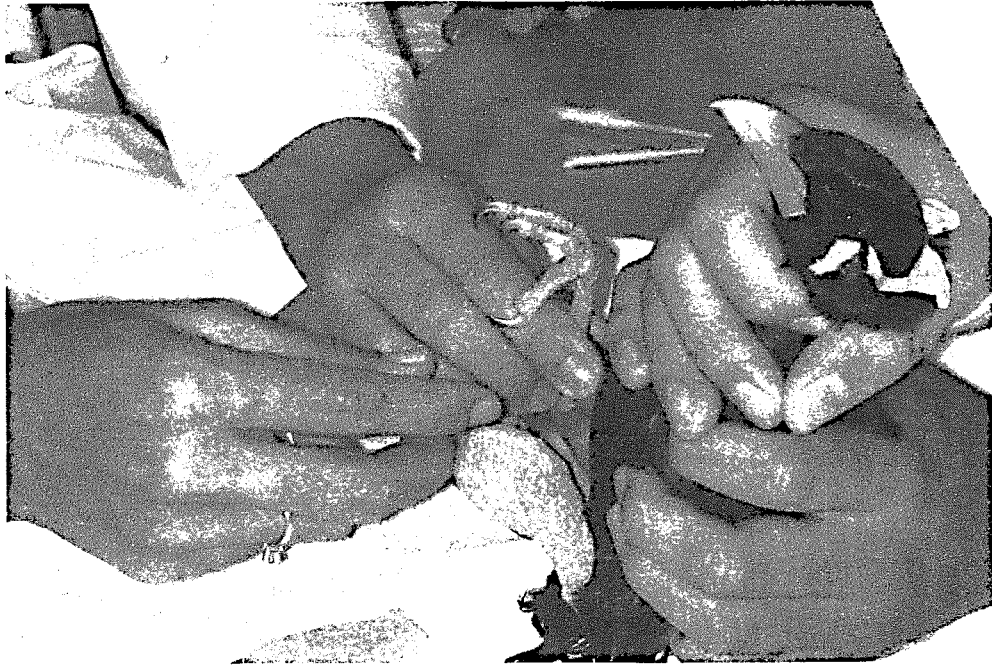


Figure 5: Application of ball bandage on the left tarsometatarsal, incorporated with tape splint



Figure 6: Combination external coaptation which did not impair perching activity




Figure 7: Radiograph showing clinical union achieved at 3 weeks post-application of bandages. Good callus formation united fractured ends (white arrow)

patient is too small to facilitate surgical repair, veterinarian skills, desire of the owner regarding the need for a return to full function, and health of the patient (Martin and Ritchie, 1994; Redig, 2000b).

In this case, clinical union of distal tarsometatarsal fracture was achieved at 3 weeks post-injury. This is in line with the healing process in avian fracture repair, which ranges from 3 to 4 weeks post-stabilisation, whether using coaptation, internal fixation or external fixation techniques (Jalila *et al.*, 2004; Redig *et al.*, 2002). Tape splint in combination with taping the hock in flexion is an acceptable choice for leg fracture stabilisation in small birds (Redig, 2000a). In this case, flexion technique was not used because the use of ball bandage technique provided better perching and movement stability. Ball bandage as well as DMSO topical treatment provides pressure which results in swelling reduction and provides comfort following trauma to the patient.

Potential complications of distal fracture of tarsus metatarsus may include damage to the nearby joint and delayed healing, or non-union as a result of poor blood supply to the distal end of the leg, a situation similar to dealing with fractures of end of forelimb such as major carpo-metacarpal bone (Redig *et al.*, 2001) as well as poor stability. Osteomyelitis also plays an important role when dealing with open fractures in avian species. In some cases with open, contaminated fractures and infected

bones, various types of antibiotics impregnated with bone cement beads or PMM beads are often implanted with successful results during surgery (Remple and Forbes, 2000). There was no evidence of osteomyelitis based on radiograph in this study.

In this case, the return to normal function following three weeks of external coaptation most likely suggests that the nearby joint and soft tissue had no damage as well as stability of the fracture stabilisation technique. External coaptation techniques are suitable for avian fracture cases depending on factors mentioned earlier and can be creatively applied by avian veterinarians in daily practice.

REFERENCES

- Bennette, R.A. and Kuzma, A.B. (1992). Fracture management in birds. *J Zoo & Wildlife Med.* **23**(1): 5-38.
- Degerness, L.A. (1994). Trauma medicine. In: *Avian Medicine: Principles and Application*. Ritchie, B.W., Harrison, G.J. and Harrison, L.R. (Eds.). Wingers Publishing, Inc., pp. 417-433, Lake Worth.

- Jalila, A., Wallace, L.J., Redig, P.T., Ogema, T.R. and Bechtold, J.E. (2004). Radiographic evaluation of transverse ulna fractures treated with the intramedullary pin-external skeletal fixator (IM-ESF) tie-in technique in pigeons (*Columba livia domestica*). In: Proceeding of the 11th International Conference of The Association of Institutions for Tropical Veterinary Medicine & 16th Veterinary Association Malaysia Congress, Kuala Lumpur, Malaysia. pp. 308-309.
- Martin, H. and Ritchie, B.W. (1994). Orthopedic surgical techniques. In: Avian Medicine: Principles and Application. Ritchie, B.W., Harrison, G.J. and Harrison, L.R. (Eds.). Wingers Publishing, Inc., Lake Worth. pp. 1137-1169.
- Redig, P.T. (1986). Evaluation and non surgical management of fractures. In: Clinical Avian Medicine and Surgery. Harrison, G. and Harrison L. (Eds.) Saunders, Philadelphia, PA. pp380-394.
- Redig, P.T.(a) (2000). Trauma –related Medical Conditions. In: Avian Medicine. Samour, J. (Ed.) Harcourt, London. pp. 131-165.
- Redig P.T.(b) (2000). The use of an external skeletal fixator-intramedullary pin tie-in (ESF-IM fixator) for treatment of long bone fractures in raptors. In: Raptor Biomedicine III. Lumeij, J.T., Remple, J.D., Redig, P.T., Lierz, M., and Cooper, J.E. (Eds.). Lake Worth, FL Zoological Education Network. pp. 239-254.
- Redig, P.T. and Ackermann, J. (2000). Raptors. In: Avian Medicine. Tully, T.N., Lawton, M.P.C., Dorrestein, G.M. (Eds.), Butterworth Heinemann. pp 180-214.
- Redig, P.T., Suzuki, Y., Jalila, A. and Jones, R. (2001). Management of orthopedic problems of the avian forelimb. In: Proceedings 22nd Annual Conference and Expo of Association of Avian Veterinarians, Florida USA. pp. 307-322.
- Remple, J.D. and Forbes, N.A. (2000). Antibiotic-impregnated polymethyl methacrylate beads in the treatment of bumblefoot in raptors. In: Raptor Biomedicine III including Bibliography of Diseases of Birds of Prey. Lumeij, J.T., Remple, J.D., Redig, P.T., Lierz, M., Cooper, J.E. (Eds.), Lake Worth, FL: Zoological Education Network, Inc: pp.255-264.
- Tully, T.N. Jr. (2009). Birds. In: Manual of Exotic Vet Pet Practice. Mitchell, M.A., Tully, T.N. Jr. (Eds). Saunders Elsevier Missouri. pp 250-298.