

FELINE HYPERTROPHIC CARDIOMYOPATHY – PREVALANCE, RISK FACTOR AND PATHOLOGICAL ASPECT

K.H. Khor*

Faculty of Veterinary Medicine, University Putra Malaysia, 43400 UPM Serdang, Malaysia

Hypertrophic Cardiomyopathy (HCM)

Prevalence of HCM

HCM is inherited as an autosomal dominant disease in both humans (Liu *et al.*, 1993; Maron *et al.*, 2003) and cats (Meurs *et al.*, 2007; Meurs *et al.*, 2005). It is the most prevalent cardiomyopathy disease in both species; however, several factors preclude accurate determination of the disease frequency. It has been estimated to affect 0.1 - 0.2% of the human population and is the leading cause of sudden cardiac death in adolescents (including competitive athletes) (Maron *et al.*, 1995). In cats the prevalence is high and it is estimated closed to 16% of the overtly healthy cat population are affected (Cote *et al.*, 2004; Paige *et al.*, 2009; Riesen *et al.*, 2007a). A retrospective echocardiographic study reported that 57.5% of cats initially diagnosed as idiopathic cardiomyopathy (n = 106) were found to have HCM (Ferasin *et al.*, 2003).

HCM is a disease of young-to-middle age cats between 8 months to 16 year (mean of onset around 6.5 year) (Kraus *et al.*, 1999; Nakagawa *et al.*, 2002). The youngest documented was 2 months old (Fujii *et al.*, 2001) and was commonly observed in males (Fujii *et al.*, 2001; Granstrom *et al.*, 2011; Liu *et al.*, 1981; Riesen *et al.*, 2007a; Tilley *et al.*, 1977), a pattern which is not seen in humans. Male cats were also observed predisposed to HCM earlier in life and with a more aggressive development of the disease (Atkins *et al.*, 1992; Rush *et al.*, 2002), compared to female cats.

Generally, cats are a sedentary animal by nature but stressful situations (e.g. cat fights or chased by dog – increased sympathetic activity of the heart), may induce sudden death in cats with asymptomatic HCM (Kittleson and Kienle, 1998). A cross-sectional echocardiographic study identified a high frequency of 8 - 10% HCM amongst overtly healthy cats (Riesen *et al.*, 2007a), which suggested that substantial changes to the heart were apparent well before any clinical signs were observed. This asymptomatic incidence of HCM partially explains episodes of sudden death or aortic thromboembolism that occurs in apparently young healthy cats without any obvious clinical signs (Baty *et al.*, 2001; Cote *et al.*, 2004; Liu and Tilley, 1980; Riesen *et al.*, 2007b). Two large retrospective studies reported that the median survival time for cats presented with aortic thromboembolism, congestive heart failure and

asymptomatic cats were between 2 to 6 months, 6 to 18 months and 3 to 5 years, respectively (Atkins *et al.*, 1992; Rush *et al.*, 2002).

Genetic factors of HCM

Abnormalities in the encoding sarcomeric proteins identified in HCM patients have led to a theory that it is a disease of contractile sarcomeric proteins (Marian and Roberts, 2001). HCM in humans is caused by a genetic mutation in one of the genes that encode for the sarcomeric proteins including β -myosin heavy chain (MyHC), cardiac troponin T and myosin binding protein C gene (MyBP-C) (Marian and Roberts, 2001; Maron, 2002). Other genes that accounted for a minority of human HCM cases were cardiac troponin I, regulatory and essential myosin light chain, titin, α -tropomyosin, α -actin and α -myosin heavy chain (Ommen and Nishimura, 2004). In human, HCM is inherited, usually as a heterogeneous autosomal dominant trait, in at least 2/3 of all HCM cases (Marian and Roberts, 2001; Solomon *et al.*, 1990). To date, more than 1000 different mutations have been identified within 13 myofilament-related genes in human (Alcalai *et al.*, 2008; Davies and Krikler, 1994; Solomon *et al.*, 1990).

In cats, recent studies in Maine Coon and Ragdoll breeds have identified defects in the same sarcomeric protein genes, MyBP-C, but in different locations (Kittleson *et al.*, 1998; Meurs *et al.*, 2008; Meurs *et al.*, 2007; Meurs *et al.*, 2005), heritable in an autosomal dominant pattern (Baty and Walkins, 1998; Fananapazir and Epstein, 1994; Kittleson *et al.*, 1999; Meurs *et al.*, 2005). In addition to these breeds, there is anecdotal evidence of the familial heritability of HCM in other breeds, including Persian, British Shorthair, Norwegian Forest Cat, Turkish Van, Scottish Fold, Siberian, Sphynx and others (Granstrom *et al.*, 2011; Meurs *et al.*, 2009; Tilley *et al.*, 2008), although the exact genetic cause in these breeds have not been well studied. The familial nature of HCM has also been reported in domestic (mixed-breed) cats (Kraus *et al.*, 1999; Nakagawa *et al.*, 2002). A long term observation on the progression of HCM in a family of domestic shorthair cat has been documented (Baty *et al.*, 2001).

HCM in Maine Coon cats closely resembles human familial HCM in terms of mode of inheritance, phenotypic expression and disease course (Fananapazir and Epstein, 1994; Kittleson *et al.*, 1999; Meurs *et al.*, 2005). Recent study have found that the MyBP-C gene mutation in Maine Coon cats is breed specific and may not appears to be

*Corresponding author: Dr Khor Kuan Hua (K.H. Khor);
Phone: +603 8609 3926; Email: khkhor@upm.edu.my.

associated with the familial HCM in other breed of cats. The mutation is inherited with incomplete penetrance (heterozygous) with variable expressivity where not all cats with the mutation will show the disease or the severity of the disease may varies among cats (Figure 1) (Carlos Sampedrano *et al.*, 2009; Lyons, 2010; Meurs *et al.*, 2005). Carlos Sampedrano *et al.* (2009) identified 18% of Maine Coon cats (n = 8/44) with MyBP-C has HCM, hence not all cats with the identified gene developed HCM. The actual prevalence may have been underestimated and probably a long-term follow-up would accurately establish the onset of disease and its effects on all ages of cats. It was also suggested that there are likely more than one mutation responsible for HCM in this breed (Carlos Sampedrano *et al.*, 2009). In Ragdoll cats, the substitution mutation identified in the MyBP-C, differs from the Maine Coon cats

because the mutation is located in a different region. Therefore, Maine Coon and Ragdoll cats' mutations were unlikely inherited from a common ancestor. The mode of inheritance in Ragdoll cats is yet to be identified and this breed-specific mutation has not been identified in other breeds of cats. In Ragdoll cats, it was shown that the homozygous cats appeared to be very severely affected, often before 2 years of age and the heterozygous cats appeared to have a milder form of the disease (Meurs *et al.*, 2007).

In summary, the identification of the first sarcomeric gene mutation, MyBP-C in Maine Coon cats is highly significant and supports a role for cats as an alternative to transgenic mice as a animal model of human familial HCM (Figure 1) (Baty, 2004; Baty and Walkins, 1998; Hasenfuss, 1998).

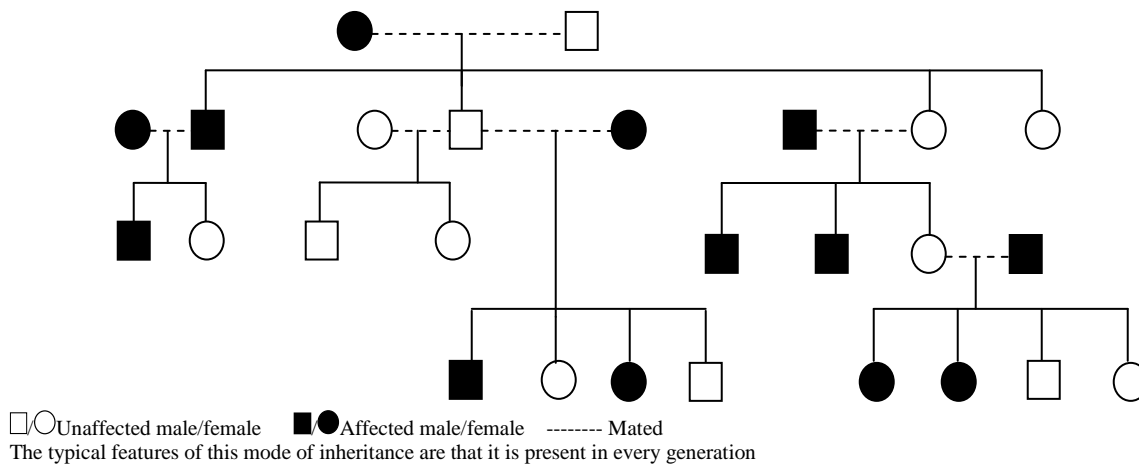


Figure 1: Example of a colony of cats with familial HCM [an autosomal dominant inheritance with incomplete penetrance (heterozygous)]

Pathogenesis and progression of HCM

It is a primary disorder of the myocardium characterised by concentric left ventricular hypertrophy, can be further described as mild-to-severe (thicken wall of a normal-to-small chamber size) (Kittleson and Kienle, 1998). To distinguish either: mild hypertrophy from normal, mild-to-moderate hypertrophy, severe hypertrophy or secondary due to other abnormalities are often not easy (Boon, 1998; Fox *et al.*, 1999; Moise *et al.*, 1986). HCM is phenotypically heterogeneous and no single distribution of left ventricular hypertrophy is typical of the disease (Kittleson and Kienle, 1998). Many have compared and correlated echocardiography findings with other diagnostic methods such as electrocardiography, necropsy, histopathology and computed magnetic resonant imaging to correlated the site or severity of hypertrophy and clinical findings (Fox, 2003; Sato *et al.*, 1998).

HCM consist of two forms; obstructive and non-obstructive. Hypertrophy obstructive cardiomyopathy (HOCM) occurs when the hypertrophied basilar

interventricular septum impinges and results in narrowing of the left ventricular outflow tract. The mitral valve is pushed into the outflow tract causing systolic anterior motion (SAM) of the mitral valve causing further obstruction of the outflow tract. At the onset of SAM of the mitral valve in HCM patients, the pushing force of flow is caused by the dominant hydrodynamic force (Sherrid *et al.*, 2000), although the Venturi force are present in the outflow tract but does not contribute to the mechanism of SAM. Hence, the obstruction may be either dynamic, fixed or both (Boon, 1998; French, 2008; Takemura *et al.*, 2003). SAM of the mitral valve is infrequently reported in cats with HCM but one isolated report by Fox *et al.* (1995) found that SAM was a common abnormality identified in 67% of the HCM cats (n=46). However, this condition may not present in all HCM cats and some cats may develop this condition before any evidence of wall thickening or some cats may have SAM of the mitral valve as a primary disease (Fox *et al.*, 1995; Kittleson and Kienle, 1998; Klues *et al.*, 1993) and similar has been widely studied and reported in HCM patients (Klues *et al.*, 1993; Spirito and Maron, 1984).

Therefore, it is important to distinguish between obstructive and non-obstructive forms of HCM, as clinical decisions depend on the presence or absence of outflow obstruction (Kittleson and Kienle, 1998). SAM of the mitral valve produce two abnormalities where: (i) it obstructs blood flows out of the left ventricle in systole (dynamic sub-aortic stenosis) causing an increase blood flow velocity through the sub-aortic region producing a turbulence and; (ii) the septal leaflet drawn out from its normal position creates a mitral regurgitation due to SAM (Kittleson and Kienle, 1998). Dynamic outflow tract obstruction if severe will be a stimulus for concentric hypertrophy and potentially worsen left ventricular diastolic dysfunction. Hence, coupled with other structural pathological change (i.e. myocardial fibre disarray, myocardial fibrosis), it may exacerbate or potentially accelerate progression to heart failure.

Gross pathology

Cats with severe HCM have severe thickening of the left ventricular myocardium [the interventricular septum (IVS) and left ventricular free wall (LVFW)], papillary muscle hypertrophy and left atrium enlargement with possible thrombus present. The left ventricular chamber is smaller than normal due to the inwards myocardial thickening into the left ventricular cavity (Cesta *et al.*, 2005; Fox, 2003; Liu *et al.*, 1981; Liu *et al.*, 1993; Tilley *et al.*, 1977). The distributions of the myocardium thickness in most cases may not be the same. The IVS and the LVFW are equally thickened (symmetric hypertrophy) in most cats with severe HCM. Other cats may have significantly thicker IVS compared to the LVFW or vice versa. Cats with mild-to-moderate HCM have lesser myocardial wall thickness, hypertrophy papillary muscle and probably a normal size of left ventricular and atrium chamber (Fox *et al.*, 1999; Kittleson and Kienle, 1998; Tilley *et al.*, 2008). Heart weight was reported to be a useful indicator for disease severity or to identify hearts with hypertrophy grossly. The heart weight in relation to the body weight has been reported to be 4.8 ± 1.8 g/kg in healthy cats versus 6.0 ± 1.4 g/kg in cats with HCM (Fox *et al.*, 1995).

Histopathology

HCM has a wide range of histopathological abnormalities but myocardial fibre disarray is a distinctive hallmark of HCM. The myocytes are arranged in chaotic, disorganised patterns at oblique and/or perpendicular angle which appeared in a bizarre disorganised cellular architecture (Baty *et al.*, 2001; Fox, 2003; Kittleson and Kienle, 1998; Liu *et al.*, 1993; Nakagawa *et al.*, 2002; Tilley *et al.*, 1977). Other histopathological findings are hypertrophied myocytes, increased collagen deposition resulting interstitial fibrosis and abnormalities of the intramyocardial small vessels (Cesta *et al.*, 2005; Fox, 2003; Liu *et al.*, 1993; Nakagawa *et al.*, 2002; Varnava *et*

al., 2000). It is likely that these abnormal structural changes disrupt the transmission of electrophysiology impulses predisposing the diseased heart to diastolic dysfunction and ventricular tachyarrhythmia (Fox, 2003; Kittleson and Kienle, 1998; Liu *et al.*, 1981; Liu *et al.*, 1993; Tilley *et al.*, 1977). The frequency of each abnormality observed varied between HCM cats (Liu *et al.*, 1993). Liu *et al.* (1981) found 25% of the HCM cats (n=51) observed with asymmetric left ventricular hypertrophy had myocardial fibre disarray in the IVS. In other HCM hearts, only myocyte hypertrophy was evident or some had moderate-to-severe interstitial. Replacement fibrosis was present in about 20 - 40% of HCM cases (Liu *et al.*, 1993). The histopathological findings differ between HCM hearts probably due to cardiac remodelling which occurs at different stages of the disease, maybe depending on the extent of the damage. Hence, whether the asymptomatic cats with HCM have similar histopathological findings at the early stage despite detectable functional changes is unknown and warrant investigation.

Pathophysiology

The pathogenesis of HCM in both humans and cats, to our knowledge is still not fully understood. It is a known genetic cardiovascular disease due to the mutations in genes encoding proteins of the cardiac sarcomere, but the molecular pathogenesis that leads to the development of hypertrophy and the variability in the common pathological phenotypes expression still remain unknown (Abbott, 2010; Braundwald *et al.*, 2012; Lind *et al.*, 2006; Marian, 2000; Maron *et al.*, 2009). A mouse model has recently been used to gain greater understanding of this complex genetic disorder (Berul *et al.*, 2001; Geisterfer-Lowrance *et al.*, 1996; James *et al.*, 1998; Prabhakar *et al.*, 2003; Shephard and Semsarian, 2009; Welikson *et al.*, 1999) as studies of molecular and pathophysiological mechanisms in cats or human HCM patients is difficult, particularly since the disease is often well established before diagnosis, especially

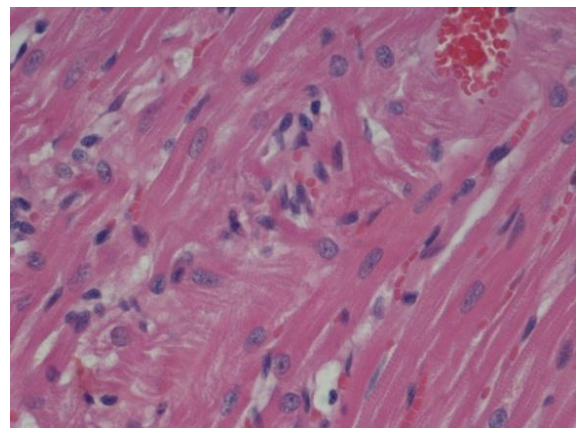


Figure 2: Representative photomicrographs of left ventricular myocardium from a cat with terminal HCM demonstrating myocardial fibre disarray (H&E stain; x40 magnification)

in cats. Pathophysiological changes and/or dysfunction presence at the early stage of HCM in cats well before the clinical sign was observed but actual mechanism is still widely debated. The genetic mutation or the pathophysiological mechanism is a trigger of the HCM is still unknown, to our knowledge.

What is understood now are that in any particular HCM cat, one or more of the pathophysiological changes and dysfunctions may occur including: (i) left ventricular diastolic dysfunction; (ii) ventricular and supraventricular tachyarrhythmias; and (iii) myocardial ischemia and fibrosis (Kittleson and Kienle, 1998; Maron *et al.*, 2009; Tilley *et al.*, 2008). Coupled with those important derangements, there are other under-recognised emerging pathophysiological concerns such as the possible presences of myocarditis (Bayes-Genis, 2007) and autonomic nervous dysfunction (Morner *et al.*, 2005) to our knowledge has not been given emphasis in cats with HCM.

Left ventricular diastolic dysfunction

The main functional implication in cats with HCM is diastolic dysfunction (Fox *et al.*, 1999; Kittleson and Kienle, 1998; Tilley *et al.*, 2008). The pathological changes of the concentric left ventricular hypertrophy from cardiac remodelling increased myocardial stiffness, increased end diastolic filling pressure and impaired early diastolic relaxation (Abbott, 2000; Fox, 2007; Liu *et al.*, 1993).

In HCM, diastolic function is compromised by several mechanisms. Ventricular compliance is reduced as a result of left ventricular hypertrophy and small arterial changes that impair left ventricular perfusion, causing myocardial ischemia, necrosis and replacement fibrosis (Kitamura *et al.*, 2001; Kittleson and Kienle, 1998). Compliance is further compromised by myocardial fibre disarray which has been shown as the most important factor related to diastolic dysfunction in humans HCM (Osato *et al.*, 1989) but assumed to contribute similar consequences in cats with HCM (Kittleson *et al.*, 1999). Besides that, impaired sarcolemmal calcium channel regulation and impaired calcium uptake by the sarcoplasmic reticulum leads to increased intracellular calcium concentration and impaired active relaxation (Gwathmey *et al.*, 1991; Opie, 2004).

Ventricular and supraventricular tachyarrhythmias

Correlation between left ventricular hypertrophy and arrhythmogenic sudden death is well established not only in HCM, but in other conditions that contribute to left ventricular hypertrophy (i.e. hypertensive and aortic stenosis) (Douglas and Tallant, 1991; Piorecka-Makula and Werner, 2009; Wolk, 2000). The most consistently observed abnormality that predisposed to arrhythmia is early or delayed afterdepolarisation and triggered activity leading to prolong action potential durations and refractoriness. In addition, non-uniform prolongation of the action potential may lead to increased dispersion of

repolarisation or refractoriness and favouring re-entry in the heart (Levick, 2003; Strickland, 1998; Wolk, 2000). In humans with HCM, the disorganised cellular architecture, myocardial fibrosis and scarring due to cardiac remodelling has been suspected as an arrhythmogenic substrate predisposing to the life-threatening electrical instability (Marian and Roberts, 2001; Ommen and Nishimura, 2004; Spirito *et al.*, 1987).

Spirito *et al.* (1987) documented a strong association of severe-to-moderate left ventricular hypertrophy with significantly increased occurrences of ventricular tachycardia in HCM patients. Cats with a history of episodic collapse or dyspnoea diagnosed with HCM were identified with a high frequency of severe ventricular arrhythmias (i.e. ventricular premature complexes, ventricular bigeminy, ventricular tachycardia, supraventricular tachycardia, supraventricular premature complex) (Bright and Cali, 2000; Ferasin *et al.*, 2003; Goodwin *et al.*, 1992).

Myocardial ischaemic and fibrosis

Application of positron emission topography and cardiovascular magnetic resonant has allowed evaluation of active myocardial ischemia as a determinant of progressive heart failure in human HCM patients (Harris *et al.*, 2006; O'Gara *et al.*, 1987; Olivotto *et al.*, 2004). The combination of increased left ventricular wall thickness (increased myocardial oxygen demand) and decreased capillary network (decreased myocardial oxygen supply) will increase heart rate and afterload, while decreased perfusion may predispose to myocardial ischemia (Ommen and Nishimura, 2004).

Presence of myocardial ischemia due to microvascular dysfunction in HCM has been suggested as an important pathophysiologic component of the disease progression (Maron *et al.*, 2009). Cats with HCM have coronary remodelling (arteriosclerosis or "small vessel disease") similar to that described in humans with HCM (Baty *et al.*, 2001; Nakagawa *et al.*, 2002; Takemura *et al.*, 2003). Liu *et al.* (1993) identified intramural coronary arteriosclerosis in 75% (38/51) of cats diagnosed with HCM. Both, Varnava *et al.* (2002) and Liu *et al.* (1993) described a common finding and relate that the intramural coronary arteriosclerosis are particularly prominent in tissue sections with moderate-to-severe fibrosis. There may therefore be a relationship between arteriosclerosis and myocardial fibrosis. With compromised blood flow in small vessels triggering myocardial ischemia, with subsequent cell death (necrosis) and scarring (fibrosis) affecting the clinical course of the disease.

Varnava *et al.* (2000) proposed that myocardial fibre disarray was a direct response to the functional and structural abnormalities of the mutated sarcomeric protein, although the authors also considered that fibrosis and small vessel disease were secondary response unrelated to disarray. Myocardial ischemia has been linked to

ventricular tachycardia and sudden death (Wolk, 2000) and its presence in the early stages of HCM may actually be a pathogenic factor.

REFERANCES

- Abbott, J.A., 2000. Small animal cardiology secret. Hanley & Belfus, Philadelphia, Pennsylvania, USA, 371.
- Abbott, J.A., 2010. Feline hypertrophic cardiomyopathy: An update. *Vet. Clin. North Am. Small Anim. Pract.*, 40(4): 685-700.
- Alcalai, R., Seidman, J.G. and Seidman, C.E., 2008. Genetic basis of hypertrophic cardiomyopathy: from bench to the clinics. *J. Cardiovasc. Electrophysiol.*, 19(1): 104-110.
- Atkins, C.E., Gallo, A.M., Kurzman, I.D. and Cowen, P., 1992. Risk factors, clinical signs, and survival in cats with a clinical diagnosis of idiopathic hypertrophic cardiomyopathy: 74 cases (1985-1989). *J. Am. Vet. Med. Assoc.*, 201(4): 613-618.
- Baty, C.J., 2004. Feline hypertrophic cardiomyopathy: An update. *Vet. Clin. North Am. Small Anim. Pract.*, 34(5): 1227-1234.
- Baty, C.J., Malarkey, D.E., Atkins, C.E., DeFrancesco, T.C., Sidley, J. and Keene, B.W., 2001. Natural history of hypertrophic cardiomyopathy and aortic thromboembolism in a family of Domestic shorthair cats. *J. Vet. Intern. Med.*, 15(6): 595-599.
- Baty, C.J. and Walkins, H., 1998. Familial hypertrophic cardiomyopathy: Man, mouse and cat. *Q. J. Med.*, 91: 791-793.
- Bayes-Genis, A., 2007. Hypertrophy and inflammation: Too much for one heart. *Eur. Heart J.*, 28(6): 661-663.
- Berul, C.I., McConnell, B.K., Wakimoto, H., Moskowitz, I.P., Maguire, C.T., Semsarian, C., Vargas, M.M., Gehrman, J., Seidman, C.E. and Seidman, J.G., 2001. Ventricular arrhythmia vulnerability in cardiomyopathic mice with homozygous mutant Myosin-binding protein C gene. *Circulation*, 104(22): 2734-2739.
- Boon, J.A., 1998. Manual of Veterinary Echocardiography. Lippincott Williams & Wilkins, Ames, Iowa, USA, 478 pp.
- Braundwald, E., Bonow, R.O., Mann, D.L., Zipes, D.P. and Libby, P., 2012. Braunwald's Heart Disease: A textbook of cardiovascular medicine. Elsevier Saunders, Philadelphia, PA.
- Bright, J.M. and Cali, J.V., 2000. Clinical usefulness of cardiac event recording in dogs and cats examined because of syncope, episodic collapse, or intermittent weakness: 60 cases (1997-1999). *J. Am. Vet. Med. Assoc.*, 216(7): 1110-1114.
- Carlos Sampedrano, C., Chetboul, V., Mary, J., Tissier, R., Abitbol, M., Serres, F., Gouni, V., Thomas, A. and Pouchelon, J.L., 2009. Prospective echocardiographic and tissue Doppler imaging screening of a population of Maine Coon cats tested for the A31P mutation in the myosin-binding protein C gene: A specific analysis of the heterozygous status. *J. Vet. Intern. Med.*, 23(1): 91-99.
- Cesta, M.F., Baty, C.J., Keene, B.W., Smoak, I.W. and Malarkey, D.E., 2005. Pathology of end-stage remodeling in a family of cats with hypertrophic cardiomyopathy. *Vet. Pathol.*, 42(4): 458-467.
- Cote, E., Manning, A.M., Emerson, D., Laste, N.J., Malakoff, R.L. and Harpster, N.K., 2004. Assessment of the prevalence of heart murmurs in overtly healthy cats. *J. Am. Vet. Med. Assoc.*, 225(3): 384-388.
- Davies, M.J. and Krikler, D.M., 1994. Genetic investigation and counselling of families with hypertrophic cardiomyopathy. *Br. Heart J.*, 72(2): 99-101.
- Douglas, P.S. and Tallant, B., 1991. Hypertrophy, fibrosis and diastolic dysfunction in early canine experimental hypertension. *J. Am. Coll. Cardiol.*, 17(2): 530-536.
- Fananapazir, L. and Epstein, N.D., 1994. Genotype-phenotype correlations in hypertrophic cardiomyopathy. Insights provided by comparisons of kindreds with distinct and identical beta-myosin heavy chain gene mutations *Circulation*, 89(1): 22-32.
- Ferasin, L., Sturgess, C.P., Cannon, M.J., Caney, S.M.A., Gruffydd-Jones, T.J. and Wotton, P.R., 2003. Feline idiopathic cardiomyopathy: a retrospective study of 106 cats (1994-2001). *J. Fel Med Surg*, 5(3): 151-159.
- Fox, P.R., 2003. Hypertrophic Cardiomyopathy. Clinical and pathologic correlates. *Journal of Veterinary Cardiology*, 5(2): 39-45.
- Fox, P.R., 2007. Managing feline heart disease - An evidence based approach, Proceedings of the World Small Animal Veterinary Association. IVIS, Sydney, Australia, IVIS.
- Fox, P.R., Liu, S.K. and Maron, B.J., 1995. Echocardiographic assessment of spontaneously occurring feline hypertrophic cardiomyopathy: An animal model of human disease *Circulation*, 92(9): 2645-2651.
- Fox, P.R., Sisson, D.D. and Moise, N.S., 1999. Textbook of canine and feline cardiology: Principles and clinical practice., 2nd ed. W.B. Saunders, Philadelphia, Pennsylvania, USA, 955 pp.
- French, A., 2008. Feline Cardiomyopathies - An update, Proceedings of the 33rd World Small Animal Veterinary Congress. IVIS, Dublin, Ireland, pp. 104-106.
- Fujii, Y., Masuda, Y., Takashima, K., Ogasawara, J., Machida, N., Yamane, Y., Chimura, S., Awazu, T., Yamane, T. and Wakao, Y., 2001. Hypertrophic cardiomyopathy in two kittens. *J. Vet. Med. Sci.*, 63(5): 583-585.
- Geisterfer-Lowrance, A.A., Christe, M., Conner, D.A., Ingwall, J.S., Schoen, F.J., Seidman, C.E. and Seidman, J.G., 1996. A mouse model of familial hypertrophic cardiomyopathy. *Science*, 272(5262): 731-734.
- Goodwin, J.K., Lombard, C.W. and Ginez, D.D., 1992. Results of continuous ambulatory electrocardiography in a cat with hypertrophic cardiomyopathy. *J. Am. Vet. Med. Assoc.*, 200(9): 1352-1354.
- Granstrom, S., Nyberg Godiksen, M.T., Christiansen, M., Pipper, C.B., Willesen, J.T. and Koch, J., 2011. Prevalence of Hypertrophic Cardiomyopathy in a cohort of British Shorthair Cats in Denmark. *J. Vet. Intern. Med.*
- Gwathmey, J.K., Warren, S.E., Briggs, G.M., Copelas, L., Feldman, M.D., Phillips, P.J., Callahan, M., Schoen, F.J., Grossman, W. and Morgan, J.P., 1991. Diastolic dysfunction in hypertrophic cardiomyopathy. Effect on active force generation during systole. *J. Clin. Invest.*, 87(3): 1023-1031.
- Harris, K.M., Spirito, P., Maron, M.S., Zenovich, A.G., Formisano, F., Lesser, J.R., Mackey-Bojack, S., Manning, W.J., Udelson, J.E. and Maron, B.J., 2006. Prevalence, clinical profile, and significance of left ventricular remodeling in the end-stage phase of hypertrophic cardiomyopathy. *Circulation*, 114(3): 216-225.
- Hasenfuss, G., 1998. Animal models of human cardiovascular disease, heart failure and hypertrophy. *Cardiovasc. Res.*, 39(1): 60.
- James, J.F., Hewett, T.E. and Robbins, J., 1998. Cardiac physiology in transgenic mice. *Circ. Res.*, 82(4): 407-415.
- Kitamura, M., Shimizu, M., Ino, H., Okeie, K., Yamaguchi, M., Funjio, N., Mabuchi, H. and Nakanishi, I., 2001. Collagen remodeling and cardiac dysfunction in patients with hypertrophic cardiomyopathy: The significance of type III and VI collagens. *Clin. Cardiol.*, 24(4): 325-329.
- Kittleson, M.D. and Kienle, R.D., 1998. Small Animal Cardiovascular Medicine. Mosby, St. Louis, USA, 603 pp.
- Kittleson, M.D., Meurs, K.M., Kittleson, J.A., Munro, M., Liu, S.K. and Towbin, J.A., 1998. Heritable characteristics, phenotypic expression, and natural history of hypertrophic cardiomyopathy in Maine Coon cats (Abstracts). *J. Vet. Intern. Med.*, 12: 198.
- Kittleson, M.D., Meurs, K.M., Munro, M.J., Kittleson, J.A., Liu, S.K., Pion, P.D. and Towbin, J.A., 1999. Familial hypertrophic cardiomyopathy in Maine coon cats - An animal model of human disease. *Circulation*, 99: 3172-3180.
- Klues, H.G., Roberts, W.C. and Maron, B.J., 1993. Morphological determinants of echocardiographic patterns of mitral valve systolic anterior motion in obstructive hypertrophic cardiomyopathy. *Circulation*, 87(5): 1570-1579.
- Kraus, M.S., Calvert, C.A. and Jacobs, G.J., 1999. Hypertrophic cardiomyopathy in a litter of five mixed-breed cats. *J. Am. Anim. Hosp. Assoc.*, 35(4): 293-296.
- Levick, J.R., 2003. An introduction to cardiovascular physiology. 3rd Ed. Arnold, London, UK.
- Lind, J.M., Chiu, C. and Semsarian, C., 2006. Genetic basis of hypertrophic cardiomyopathy. *Expert Review Cardiovascular Therapy*, 4(6): 927-934.
- Liu, S.K., Maron, B.J. and Tilley, L.P., 1981. Feline hypertrophic cardiomyopathy: Gross anatomic and quantitative histologic features. *Am. J. Pathol.*, 102(3): 388-395.

- Liu, S.K., Roberts, W.C. and Maron, B.J., 1993. Comparison of morphologic findings in spontaneously occurring hypertrophic cardiomyopathy in humans, cats and dogs. *Am. J. Cardiol.*, 72(12): 944-951.
- Liu, S.K. and Tilley, L.P., 1980. Animal models of primary myocardial diseases. *Yale J. Biol. Med.*, 53(3): 191-211.
- Lyons, L.A., 2010. Feline genetics: Clinical applications and genetic testing. *Top Companion Animal Medicine*, 25(4): 203-212.
- Marian, A.J., 2000. Pathogenesis of diverse clinical and pathological phenotypes in hypertrophic cardiomyopathy. *Lancet*, 355(9197): 58-60.
- Marian, A.J. and Roberts, R., 2001. The molecular genetic basis for hypertrophic cardiomyopathy. *J. Mol. Cell. Cardiol.*, 33(4): 655-670.
- Maron, B.J., 2002. Hypertrophic cardiomyopathy - A systematic review. *Journal of the American Medical Association*, 287(10): 1308-1320.
- Maron, B.J., Gardin, J.M., Flack, J.M., Gidding, S.S., Kurosaki, T.T. and Bild, D.E., 1995. Prevalence of hypertrophic cardiomyopathy in a general population of young adults: Echocardiographic analysis of 4111 subjects in the CARDIA study. *Circulation*, 92(4): 785-789.
- Maron, B.J., McKenna, W.J., Danielson, G.K., Kappenberger, L.J., Kuhn, H.J., Seidman, C.E., Shah, P.M., Spencer, W.H., III, Spirito, P., Ten Cate, F.J. and Wigle, E.D., 2003. ACC/ESC clinical expert consensus document on hypertrophic cardiomyopathy: A report of the American College of Cardiology Task Force on Clinical Expert Consensus Documents and the European Society of Cardiology committee for Practice Guidelines (Committee to Develop an Expert Consensus Document on Hypertrophic Cardiomyopathy). *J. Am. Coll. Cardiol.*, 42(9): 1687-1713.
- Maron, M.S., Olivotto, I., Maron, B.J., Prasad, S.K., Cecchi, F., Udelson, J.E. and Camici, P.G., 2009. The case for myocardial ischemia in hypertrophic cardiomyopathy. *J. Am. Coll. Cardiol.*, 54(9): 866-875.
- Meurs, K.M., Norgard, M., Haggstrom, J. and Kittleson, M., 2008. Mutational analysis of four sarcomeric genes in three breeds of cats with hypertrophic cardiomyopathy. *J. Vet. Intern. Med.*, 22(3): 758-758.
- Meurs, K.M., Norgard, M.M., Ederer, M.M., Hendrix, K.P. and Kittleson, M.D., 2007. A substitution mutation in the myosin binding protein C gene in ragdoll hypertrophic cardiomyopathy. *Genomics*, 90(2): 261-264.
- Meurs, K.M., Norgard, M.M., Kuan, M., Haggstrom, J. and Kittleson, M., 2009. Analysis of 8 sarcomeric candidate genes for feline hypertrophic cardiomyopathy mutations in cats with hypertrophic cardiomyopathy. *J. Vet. Intern. Med.*, 23(4): 840-843.
- Meurs, K.M., Sanchez, X., David, R.M., Bowles, N.E., Towbin, J.A., Reiser, P.J., Kittleson, J.A., Munro, M.J., Dryburgh, K., MacDonald, K.A. and Kittleson, M.D., 2005. A cardiac myosin binding protein C mutation in the Maine Coon cat with familial hypertrophic cardiomyopathy. *Hum. Mol. Genet.*, 14(23): 3587-3593.
- Moise, N.S., Dietze, A.E., Mezza, L.E., Strickland, D., Erb, H.N. and Edwards, N.J., 1986. Echocardiography, electrocardiography, and radiography of cats with dilatation cardiomyopathy, hypertrophic cardiomyopathy, and hyperthyroidism. *Am. J. Vet. Res.*, 47(7): 1476-1486.
- Morner, S., Wiklund, U., Rask, P., Olofsson, B.O., Kazzam, E. and Waldenstrom, A., 2005. Parasympathetic dysfunction in hypertrophic cardiomyopathy assessed by heart rate variability: Comparison between short-term and 24-h measurements. *Clinical Physiology & Functional Imaging*, 25(2): 90-99.
- Nakagawa, K., Takemura, N., Machida, N., Kawamura, M., Amasaki, H. and Hirose, H., 2002. Hypertrophic cardiomyopathy in a mixed breed cat family. *J. Vet. Med. Sci.*, 64(7): 619-621.
- O'Gara, P.T., Bonow, R.O., Maron, B.J., Damske, B.A., Van Lingen, A., Bacharach, S.L., Larson, S.M. and Epstein, S.E., 1987. Myocardial perfusion abnormalities in patients with hypertrophic cardiomyopathy: Assessment with thallium-201 emission computed tomography. *Circulation*, 76(6): 1214-1223.
- Olivotto, I., Cecchi, F. and Camici, P.G., 2004. Coronary microvascular dysfunction and ischemia in hypertrophic cardiomyopathy. Mechanisms and clinical consequences. *Ital. Heart J.*, 5(8): 572-580.
- Ommen, S.R. and Nishimura, R.A., 2004. Hypertrophic cardiomyopathy. *Curr. Probl. Cardiol.*, 29(5): 239-291.
- Opie, L.H., 2004. *Heart Physiology: From Cell to Circulation*, 4th edition. Lippincott Williams & Wilkins, Philadelphia, PA, USA, 648 pp.
- Osato, K., Shimizu, M., Sugihara, N., Konishi, K. and Takeda, R., 1989. Histopathological factors related to diastolic function in myocardial hypertrophy. *Jpn. Circ. J.*, 53(6): 595-596.
- Paige, C.F., Abbott, J.A., Elvinger, F. and Pyle, R.L., 2009. Prevalence of cardiomyopathy in apparently healthy cats. *J. Am. Vet. Med. Assoc.*, 234(11): 1398-1403.
- Piorecka-Makula, A. and Werner, B., 2009. Prolonged QT dispersion in children with congenital valvular aortic stenosis. *Medical Science Monitor*, 15(10): CR534-538.
- Prabhakar, R., Petrashevskaya, N., Schwartz, A., Aronow, B., Boivin, G.P., Molkentin, J.D. and Wiecek, D.F., 2003. A mouse model of familial hypertrophic cardiomyopathy caused by an alpha-tropomyosin mutation. *Mol. Cell. Biochem.*, 251(1-2): 33-42.
- Riesen, S.C., Kovacevic, A., Lombard, C.W. and Amberger, C., 2007a. Echocardiographic screening of purebred cats: An overview from 2002 to 2005. *Schweiz. Arch. Tierheilkd.*, 149(2): 73-76.
- Riesen, S.C., Kovacevic, A., Lombard, C.W. and Amberger, C., 2007b. Prevalence of heart disease in symptomatic cats: An overview from 1998 to 2005. *Schweiz. Arch. Tierheilkd.*, 149(2): 65-71.
- Rush, J.E., Freeman, L.M., Fenollosa, N.K. and Brown, D.J., 2002. Population and survival characteristics of cats with hypertrophic cardiomyopathy: 260 cases (1990-1999). *J. Am. Vet. Med. Assoc.*, 220(2): 202-207.
- Sato, T., Nakamura, K., Yamanari, H., Yoshinouchi, T. and Ohe, T., 1998. Relationship between electrocardiographic features and distribution of hypertrophy in patients with hypertrophic cardiomyopathy. *Japanese Circulation Journal-English Edition*, 62(7): 483-488.
- Shephard, R. and Semsarian, C., 2009. Role of animal models in HCM research. *Journal of Cardiovascular Translation Research*, 2(4): 471-482.
- Sherrid, M.V., Gunsburg, D.Z., Moldenhauer, S. and Pearle, G., 2000. Systolic anterior motion begins at low left ventricular outflow tract velocity in obstructive hypertrophic cardiomyopathy. *J. Am. Coll. Cardiol.*, 36(4): 1344-1354.
- Solomon, S.D., Jarcho, J.A., McKenna, W., Geisterfer-Lowrance, A., Germain, R., Salerni, R., Seidman, J.G. and Seidman, C.E., 1990. Familial hypertrophic cardiomyopathy is a genetically heterogeneous disease. *J. Clin. Invest.*, 86(3): 993-999.
- Spirito, P. and Maron, B.J., 1984. Patterns of systolic anterior motion of the mitral valve in hypertrophic cardiomyopathy: Assessment by two-dimensional echocardiography. *Am. J. Cardiol.*, 54(8): 1039-1046.
- Spirito, P., Watson, R.M. and Maron, B.J., 1987. Relation between extent of left ventricular hypertrophy and occurrence of ventricular tachycardia in hypertrophic cardiomyopathy. *Am. J. Cardiol.*, 60(14): 1137-1142.
- Strickland, K.N., 1998. Advances in antiarrhythmic therapy. *Veterinary Clinics of North America Small Animal Practice*, 28(6): 1515-1546.
- Takemura, N., Nakagawa, K., Machida, N., Washizu, M., Amasaki, H. and Hirose, H., 2003. Acquired mitral stenosis in a cat with hypertrophic cardiomyopathy. *J. Vet. Med. Sci.*, 65(11): 1265-1267.
- Tilley, L.P., Liu, S.K., Gilbertson, S.R., Wagner, B.M. and Lord, P.F., 1977. Primary myocardial disease in the cat. A model for human cardiomyopathy. *Am. J. Pathol.*, 86(3): 493-522.
- Tilley, L.P., Smith, F.W., Oyama, M.A. and Sleeper, M.M., 2008. *Manual of Canine and Feline Cardiology*. 4th ed. Saunders, Elsevier, St.Louis, Missouri, USA, 443 pp.
- Varnava, A.M., Elliott, P.M., Sharma, S., McKenna, W.J. and Davies, M.J., 2000. Hypertrophic cardiomyopathy: The interrelation of disarray, fibrosis, and small vessel disease. *Heart*, 84(5): 476-482.
- Welikson, R.E., Buck, S.H., Patel, J.R., Moss, R.L., Vikstrom, K.L., Factor, S.M., Miyata, S., Weinberger, H.D. and Leinwand, L.A., 1999. Cardiac myosin heavy chains lacking the light chain binding domain cause hypertrophic cardiomyopathy in mice. *Am. J. Physiol.*, 276(6 Pt 2): H2148-2158.
- Wolk, R., 2000. Arrhythmogenic mechanisms in left ventricular hypertrophy. *Europace*, 2(3): 216-223.