



## Case Report

# Management of Lower Urinary Tract Obstructive Disease using Bladder Tube Cystotomy in a Saanen Buck

Khairuddin, N. H.<sup>1\*</sup>, R. Mansor<sup>1</sup>, R. Radzi<sup>2</sup> and M. Y. Loqman<sup>3</sup>

<sup>1</sup>Department of Farm and Exotic Animal Medicine and Surgery, Faculty of Veterinary Medicine, Universiti Putra Malaysia, 43400 UPM Serdang, Selangor, Malaysia

<sup>2</sup>Department of Veterinary Clinical Studies, Faculty of Veterinary Medicine, Universiti Putra Malaysia, 43400 UPM Serdang, Selangor, Malaysia

<sup>3</sup>Department of Small Animal Medicine and Surgery, Faculty of Veterinary Medicine, Universiti Putra Malaysia, 43400 UPM Serdang, Selangor, Malaysia

## ABSTRACT

This report describes a procedure of bladder tube cystotomy to relieve progressing bladder distension in a goat diagnosed to have obstructive urolithiasis. This one-year old Saanen buck was presented with a complaint of not passing urine and being in discomfort for almost three days. On physical examination, pulsation of the urethra in the perineal region could be felt and swelling and pain along the prepuce and perineum were indicated on deep palpation. Amputation of the urethral orifice and attempt to catheterise the urethra failed to relieve bladder distension; thus, bladder tube cystotomy procedure was performed. Following this procedure, all vital parameters returned to normal and normograde cystourethrogram was performed to radiographically assess the lower urinary tract of the goat. The outcome of this case supports that the bladder tube cystotomy technique provides an effective method to allow immediate relief of a distended bladder, allowing the urethra to heal as the urine outflow is diverted through the catheter and allows normograde cystourethrography to be performed.

*Keywords:* Obstructive urolithiasis, bladder tube cystotomy, cystourethrogram, goat

## ARTICLE INFO

### Article history:

Received: 23 June 2014

Accepted: 8 October 2015

### E-mail addresses:

[nurulhayah@upm.edu.my](mailto:nurulhayah@upm.edu.my),

[nurul.leman82@gmail.com](mailto:nurul.leman82@gmail.com) (Khairuddin, N. H.),

[rozaihan@upm.edu.my](mailto:rozaihan@upm.edu.my) (R. Mansor),

[rozanaliza@upm.edu.my](mailto:rozanaliza@upm.edu.my) (R. Radzi),

[myloqman@gmail.com](mailto:myloqman@gmail.com) (M. Y. Loqman)

\* Corresponding author

## INTRODUCTION

Obstructive urolithiasis is a condition where insoluble mineral and salt precipitate and obstruct urine flow anywhere from

the renal pelvis to the distal urethra. The most common site for obstruction is at the sigmoid flexure of the urethra and at the urethral process (Tibary & Van Metre, 2004; Ewoldt *et al.*, 2008; Jones *et al.*, 2012). The clinical signs of urinary obstruction are dependent upon the degree of obstruction, location of obstruction and duration of disease, and the signs include persistent straining to urinate, restlessness, tail flagging, vocalisation, anorexia and azotemia. Without any relief of obstruction, this condition will eventually lead to urinary bladder or urethra rupture and result in abdominal distension (Jones *et al.*, 2012). Surgical intervention such as amputation of the urethral process, urethrotomy, perineal urethrostomy, cystotomy, tube cystotomy or bladder marsupialisation is necessary to relieve the obstruction either by removal of the urolith or by passing the urine flow past the obstruction (Van Metre & Fubini, 2006; Ewoldt *et al.*, 2008). The purpose of this report is to describe a case of obstructive urolithiasis in a Saanen goat managed with bladder tube cystotomy procedure followed by normograde contrast cystourethrography performed at the Universiti Veterinary Hospital, Universiti Putra Malaysia.

## CASE DETAILS

### *History*

A one-year old Saanen male goat with intact testicles was presented to the University Veterinary Hospital (UVH) with a complaint of not passing urine and being in discomfort for almost three days. The goat was managed intensively and served as breeding stock.

According to the owner, two weeks before the problem occurred, the goat's diet was changed to a self-mixed feed ration. The owner noticed that the goat was straining to urinate and treated it with ammonium chloride for three days prior to presentation to the hospital given that urine was not passed.

### *Clinical Findings*

Upon physical examination, the animal was bright and alert with a good body condition score (4 out of 5). The body temperature was within normal range, but the respiratory and heart rates were increased. Pulsation of the urethra in the perineal region could be felt, and swelling and pain along the prepuce and perineum were indicated on deep palpation. Based on the history and the presentation of clinical signs, the case was tentatively diagnosed to be of obstructive urolithiasis. Lateral and dorsoventral abdominal radiography to view the urinary bladder were performed. However, the outline of the bladder could not be appreciated due to the superimposition of the rumen and its content. Then a decision was made to amputate the urethral process as the first step to relieve any obstruction. Sedation was achieved with acepromazine (Calmivet Injectable Solution 0.05 mg/kg, Vetoquinol S.A.) given intramuscularly. The penis was exteriorised from the sheath, and the urethral process was amputated using sterile surgical blade (size 20). Several spherical small stones (diameter of less than 0.5 cm) were successfully removed with this procedure. However, amputation of the urethral process

could not re-establish urethral patency despite efforts to urinate. Then urinary catheterisation was attempted using a large dog urinary catheter [BUSTER Disposable Dog Catheter [2.0 x 500 mm; 2.6 x 500 mm) by Kruuse] to relieve the distended bladder (Fig.1). The catheter could be passed along the straight urethra, but resistance was felt as the catheter reached the distal part of the sigmoid flexure of the urethra. Due to concern of urethral trauma or rupture, this technique was not continued.

Ultrasound guided cystocentesis with a 7.5 MHz linear probe (Veterinary ultrasound model SIUI - CTS - 900V) was performed and about 230 mls of urine were aspirated (Fig.2). An ultrasound examination of the bladder revealed that the bladder was still intact but was very much distended with

thickened wall. The urethral lining was also scanned to identify any obstruction that could be picked up by the ultrasound probe. However, no uroliths were present in either the urethra or the bladder. The sigmoid flexure of the urethra was difficult to be scanned as the goat was restless and in pain whenever the probe was placed at that region.

On the first day of hospitalisation, the serum biochemistry result revealed azotemia, hypophosphatemia, hypochlorademia and lymphopenia. Urinalysis results revealed that the goat was having proteinuria, and presence of inflammatory cells with bacteria (1+), which is suggestive of lower urinary tract infection. The goat was observed throughout the night in case of a bladder rupture, as surgery could not be

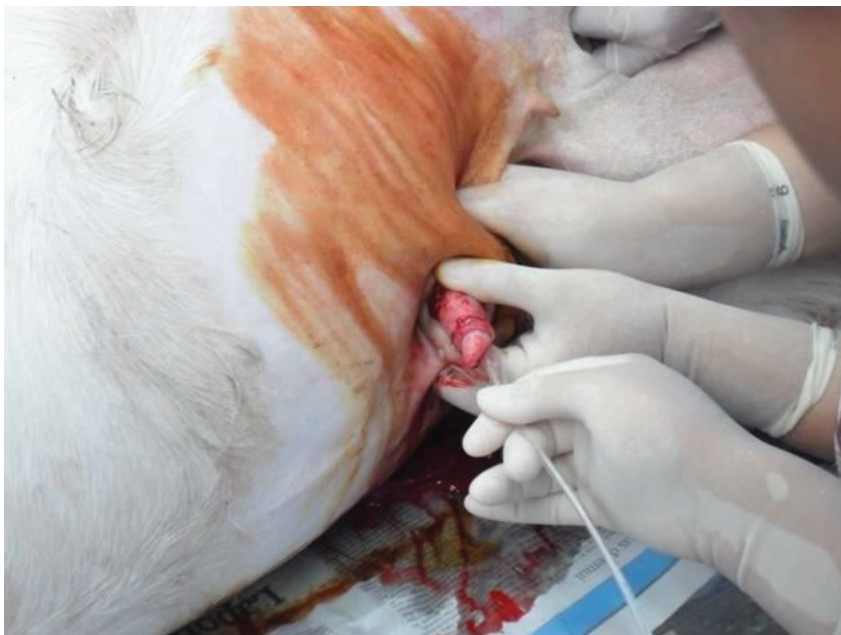

Fig.1: Attempt to catheterise the urinary bladder using a large dog urinary catheter to relieve the distended bladder.

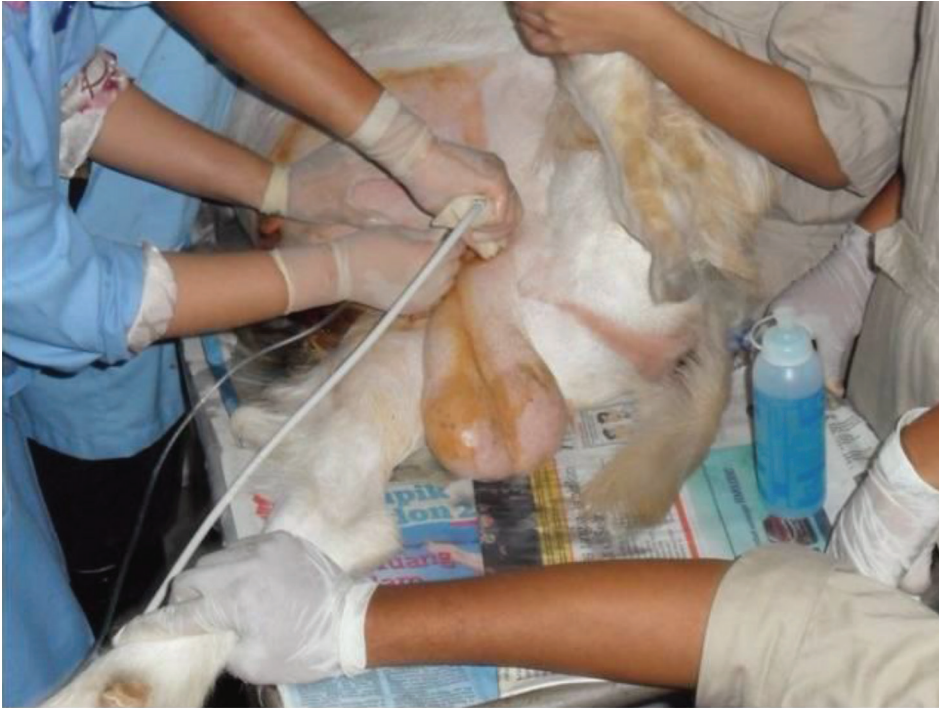

Fig.2: Ultrasound-guided cystocentesis was performed and about 230 mls of urine was aspirated out.

performed on that day. By late evening, it had started panting, tachycardic (112 beats per minute), having high rectal temperature ( $42^{\circ}\text{C}$ ) and anuric (despite the effort to urinate). Analgesic drug of flunixin meglumin (Flunixin 50 mg/ml, 2.2 mg/kg, intramuscularly, Norbrook Laboratories (GB) Limited) and broad spectrum antibiotic of penicillin (Benacillin 1 ml per 25 kg, intramuscularly, Troy Laboratories Pty. Limited) were administered. By midnight, the goat's strenuous straining efforts had only produced dribbling urine, and no more urination was observed after that.

#### *Surgical Procedure*

Bladder tube cystotomy was planned and performed on the second day of

hospitalisation. Anaesthesia was induced with xylazine (Ilium-xylazil-20, 0.11 mg/kg, intravenously, Troy Laboratories Pty. Limited) and was maintained with combination of xylazine (0.11 mg/kg, intravenously) and ketamine (Narketan-10, 2 mg/kg, intravenously, Vetoquinol UK Limited). Normal saline at maintenance rate was administered intravenously throughout the surgical procedure. For intraoperative anaesthesia, the goat received epidural anaesthesia using lidocaine hydrochloride (Xylocaine 2%, 0.2 mg/kg, Astrazeneca).

The goat was positioned on right lateral recumbency with the left hindlimb abducted. The ventral abdomen and inguinal region were clipped and surgically prepared. Local anaesthetic drug (lidocaine hydrochloride)



was instilled along the proposed incision line. A ventrolateral abdominal incision of about 5-10 cm was made at the caudal abdomen. The external rectus sheath was incised, and the underlying muscle was undermined with Mayo scissors, followed by incision of the internal rectus sheath and the peritoneum. Then the bladder was identified by deep palpation of the abdominal cavity and was carefully exteriorised. Stay sutures were placed on the wall of the bladder to ease handling and prevent slipping of the bladder into abdominal cavity. An 18-gauge indwelling catheter connected to an extension tube was inserted into the bladder to allow urinary drainage. Approximately 500 mls of urine were removed.

Then a purse string suture pattern using an absorbable suture material 2-0 Vicryl (Coated Vicryl [Polyglactin 910] Suture Undyed Braided, Ethicon LLC) was placed on the ventral surface of the bladder wall. A stab incision was made in the mid region of the purse string pattern, and the tip of the Foley catheter (size 8Fr) including the deflated balloon, was inserted into this small bladder opening. Once the catheter had been placed in the bladder, the purse string suture was tightened to secure the catheter, and then the balloon on the catheter was inflated with air. The abdomen was lavaged with warm sterile saline, followed by suctioning out of the fluid. Then the peritoneum and muscle layers were closed with continuous suture pattern (2-0 Vicryl), followed by

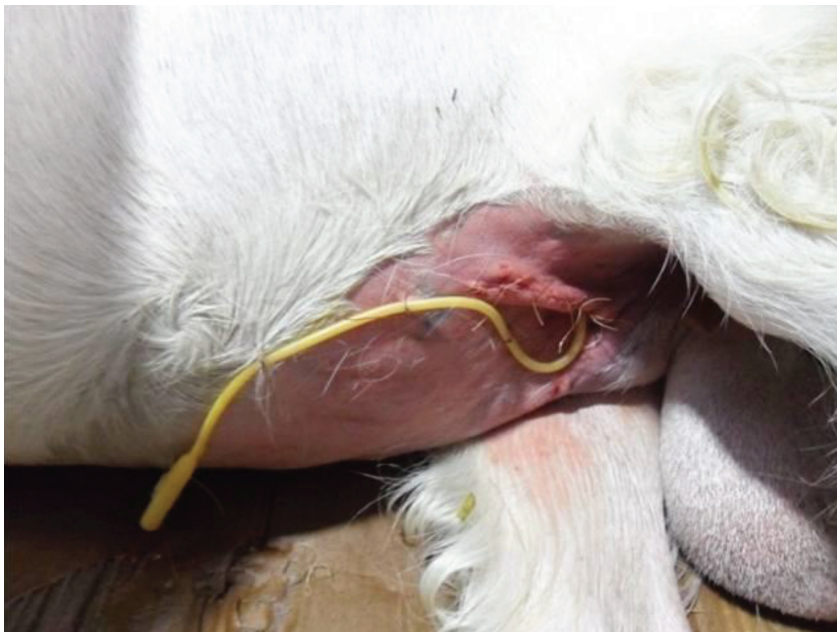

Fig.3: Post bladder tube cystotomy procedure where the end of the Foley catheter was hung outside the abdomen.

modified Cushing pattern for subcutaneous layer (2-0 Vicryl). The skin was closed with interrupted suture pattern using 1-0 Ethilon (Ethilon Polyamide 6, Ethicon LLC). The other end of the Foley catheter was hung outside the abdomen through a small, separate stab incision. The catheter end opening was closed with a clamp, and the catheter was secured to the abdominal wall with Chinese finger trap sutures (Fig.3).

#### *Post-Operative Care*

The goat was given 0.9 % NaCl fluids at replacement rate post-operatively. Antibiotic of penicillin streptomycin (Pen & Strep 1 ml per 25 kg, Norbrook Laboratories Limited) was administered for five days, followed by trimethoprim-sulfadiazine (Norodine 1 ml per 16 kg, Norbrook Laboratories Limited) for another three days. Flunixin meglumin (2.2 mg/kg) as analgesic and anti-inflammatory was given for three days, twice a day, followed by another three days, once daily. Aspiration of urine from the bladder tube was performed hourly, and about 3000 mls of urine was removed over 24 hours post-operatively. An Elizabethan collar was applied on the animal to prevent chewing or dislodging the Foley catheter. Twenty-four hours post-surgery, all vital parameters had returned to normal and the goat appeared bright and alert, and started to eat and drink on its own.

#### *Further Diagnostic Workout*

On the third day of hospitalisation, a day after the bladder tube cystotomy procedure, a cysto-urethrogram was performed to

diagnose if any urolith was present in the bladder and the urethra, as well as to assess the lower urinary tract structures in this goat. For this procedure, the goat was sedated with xylazine and was placed on lateral recumbency. At first, catheterisation of the urethra was attempted in order to infuse the urethra with 35 mls of positive contrast medium (Omnipaque [Iohexol], 0.5 ml/kg, GE Healthcare). However, this technique failed to opacify the outline of the urethra in the radiograph. Then the same contrast medium was infused into the bladder via the Foley catheter, followed by a lateral and dorsoventral view of the bladder and urethra a few minutes later. Radiographic findings revealed that the bladder was intact, the entire urethral lining was clear and the lumen was patent with no evidence of urolith present in either the bladder or urethra (Fig.4). At the end of the procedure, the urine and contrast medium cystocentesis was performed through the surgical cystotomy tube.

#### *Progress Post Surgery*

Post cysto-urethrogram, it was noted that the goat was having hematuric dribbling urine, which was likely due to mucosal injury following previous urinary catheterisation. By the fifth day, it had started to dribble clear yellow urine from the urethra. By the seventh day of hospitalisation, urine aspiration was performed twice daily, only to encourage spontaneous micturition. However, at day 10 post-surgery, the dribbling urine was still persisting. Urine sample at day-10 post cystotomy was

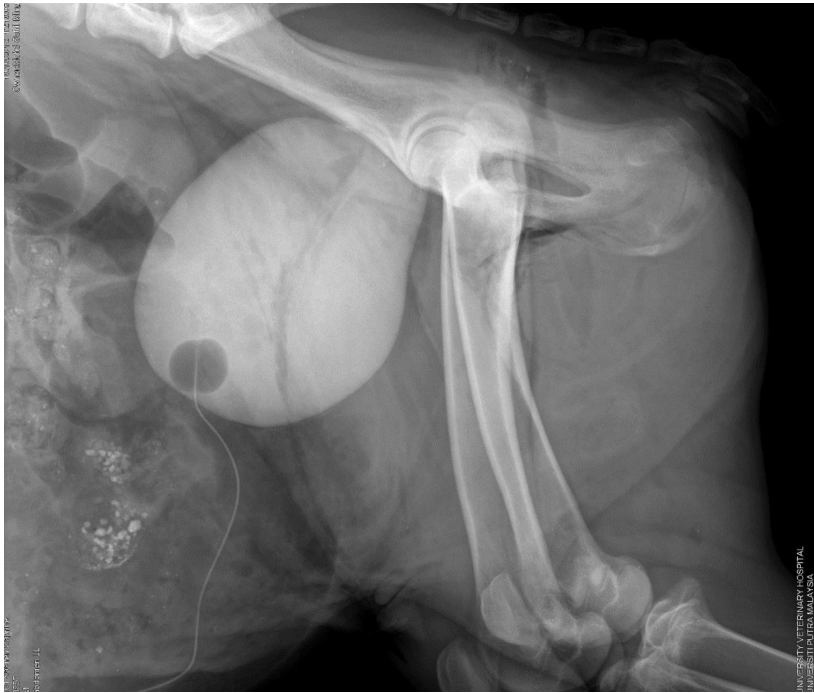


Fig.4: Cystourethrogram of the lower urinary structure of the goat. The bladder was intact, the entire urethral lining was clear and the lumen was patent with no evidence of urolith present in either the bladder or urethra.

taken and sent for bacterial culture and a sensitivity test. The result revealed high counts of bacteria and *Escherichia coli* was isolated from the urine sample. Antibiotic sensitivity test showed resistance towards amoxicillin, enrofloxacin, norodine and oxytetracycline but sensitivity towards gentamicin. Thus, gentamicin (Gentam 100, 6.6 mg/kg, Troy Laboratories Pty. Limited) was administered for another three days. On day 14 post-surgery, the urine flow had improved. The surgical cystotomy tube was then removed by deflating the catheter tip balloon, and immediate removal of the whole catheter from the animal. The catheter exit wound was examined and left open to allow drainage.

The goat was discharged on the 17th day of hospitalisation, and the owner was advised to provide plenty of water and fresh grass, and allow the animal to graze in a grass paddock if possible. Mating was only advised after two weeks of normal urination and penis function observed by the owner. To prevent any other cases of urolithiasis in the same or other animals in the farm, the owner was also advised to get the self-mixed feed concentrates to be analysed at the government nutrition laboratory at Salak Tinggi, Selangor. After a week, the owner reported that the urine quality and flow was back to normal.

## DISCUSSION

In male goats, the urolith's most common site for obstruction is at the sigmoid flexure of the urethra and at the urethral process (Haven *et al.*, 1993; Tibary & Van Metre, 2004; Ewoldt *et al.*, 2008; Jones *et al.*, 2012). Catheterisation of the urethra is difficult in this case due to the anatomy of the penile urethra, which forms a sigmoid flexure, and the catheter failed to pass through. Perhaps the catheter used in this case is not flexible enough to be bent along this flexure. Male goats possess a urethral diverticulum or recess that communicates with the urethra and contains the ducts of the bulbourethral glands (Jones *et al.*, 2012). Even if the catheter passed the sigmoid flexure, the presence of this urethral diverticulum will divert the catheter into this structure instead of entering the bladder, thus preventing catheterisation of the urinary bladder.

Thus, for obstructive urolithiasis in animals that are intended for breeding, surgical bladder tube cystotomy is the preferred technique to relieve a distended bladder and retain breeding capacity (Haven *et al.*, 1993; Rakestraw *et al.*, 1995; Ewoldt *et al.*, 2006; Van Metre & Fubini, 2006). This technique allows immediate relief of a distended bladder, allows the urethra to heal as the urine outflow is diverted through the catheter and allows normograde cystourethrography to be performed. A healing period of approximately 14 days was taken into consideration before removal of the catheter as reported by Rakestraw *et al.* (1995). Periodic occlusion of the

tube catheter was practised to monitor micturition ability of the goat.

Based on our experience, urine flow patency occurred only after day 14 post-surgery. Dysuria or dribbling urine in goats with a history of obstructive urolithiasis can be due to several causes: post-trauma healing of the urethra, cystitis or partial bladder atony from prolonged bladder distension. Furthermore, cystitis is one of the potential complications from urethral obstruction that causes dribbling of the urine (Ewoldt *et al.*, 2008). In this case, the dribbling urine discontinued after the administration of an antibiotic that the causative organism was sensitive to. Furthermore, urethral stricture due to trauma from the calculi was also considered as one of the important complications where the healing process may take longer to establish patent urethral flow of urine (Todhunter *et al.*, 1996).

Normograde cystourethrogram was made possible via the tube cystotomy, which allowed us to evaluate the presence of urolith and patency of the urethra. The contrast study performed here suggested that there was a possibility that the obstructive urolith had dislodged and was no longer obstructing the urethra; thus, patency of the urethra had been restored. Based on the radiographic finding, which ruled out the presence of urolith or urethral stricture, it could be suggested that the dribbling urine post-surgery might have been due to inflammation of the urethra and was not caused by the obstruction or stricture of



the lower urinary tract. Positive contrast normograde cystourethrography through the bladder tube cystotomy as in this case, provides the best visualisation of the lower urinary tract structures (Palmer *et al.*, 1998) and aids in the diagnosis of the problem.

The use of gentamicin antibiotic in food animals is not regulated in this country. In this case, it was only used as a last resort, where the cultured organism was resistant to all other antibiotics available and sensitive to gentamicin. It is important to note that the use of gentamicin in food animals is not allowed in certain countries like Australia and the United States (Australia, 1999). The reason for prohibition of gentamicin use in food animals is because the residual effects of this drug are extremely long and the withholding period is measured in years. The use of gentamicin in food-producing animals may increase the risk of bacterial resistance towards this drug that may be subsequently harmful to human medicines upon consumption of dairy or meat product of the treated animal (Australia, 1999).

Despite publications detailing the technique of bladder tube cystotomy in small ruminants, up to this point, there are no local case reports of successful surgical treatment using this technique in the management of urolithiasis in small ruminants in Malaysia. Local veterinarians would have the option to attempt this surgical procedure to relieve bladder distension and correct systemic imbalances during urinary obstruction, as an alternative to slaughter or euthanasia. It has to be taken into consideration that this procedure has the disadvantage of

having longer hospitalisation and increased intensity of case management.

## ACKNOWLEDGEMENTS

The authors would like to acknowledge the help of the staff of the Radiology Unit, Mr Osman Asnawi and Mr Farid, for assistance during the cystourethrography for this case. Gratitude also goes to the staff of the Large Animal Unit, Department of Farm and Exotic Animal Medicine and Surgery, Universiti Putra Malaysia, as well as to veterinary students involved in this case.

## REFERENCES

- Australia Joint Expert Advisory Committee on Antibiotic and Resistance. (1999). *The use of antibiotics in food producing animals: Antibiotic-resistant bacteria in animals and human*. Australia: Commonwealth of Australia, pp. 61-690.
- Ewoldt, J. M., Anderson, D. E., Miesner, M. D., & Saville, W. J. (2006). Short and long term outcome and factors predicting survival after surgical tube cystotomy for treatment of obstructive urolithiasis in small ruminants. *Veterinary Surgery*, 35(5), 417-422.
- Ewoldt, J. M., Jones, M. L., & Miesner, M. D. (2008). Surgery of obstructive urolithiasis in ruminants. *Veterinary Clinician of North America: Food Animal Practice*, 24(3), 455-465.
- Haven, M. L., Bowman, K. F., T. A., E., & Blikslager, A. T. (1993). Surgical management of urolithiasis in small ruminants. *Cornell Veterinary*, 83(1), 47-55.
- Jones, M., Miesner, M. D., Baird, A. N., & Pugh, D. G. (2012). Diseases of the urinary system. In D. G. Pugh, & A. N. Baird (Eds.). *Sheep and goat medicine (2nd ed.)*, Missouri: Saunders. pp.325-342.

- Palmer, J. L., Dykes, N. L., Love, K., & Fubini, S. L. (1998). Contrast radiography of the lower urinary tract in the management of obstructive urolithiasis in small ruminants and swine. *Veterinary Radiology and Ultrasound*, 39(3), 175-18.
- Rakestraw, P., Fubini, S. L., Gilbert, R., & Ward, J. (1995). Tube cystotomy for treatment of obstructive urolithiasis in small ruminants. *Veterinary Surgery*, 24(6), 498-505.
- Tibary, A., & Van Metre, D. C. (2004). Surgery of the sheep and goat reproductive system and urinary tract. In *Farm animal surgery*. St. Louis: Saunders.
- Todhunter, P., Baird, A. N., & Wolfe, D. F. (1996). Erection failure as a sequela to obstructive urolithiasis in a male goat. *Journal of American Veterinary Medicine Association*, 209(3), 650-652.
- Van Metre, D. C., & Fubini, S. L. (2006). Ovine and caprine urolithiasis: Another piece of the puzzle. *Veterinary Surgery*, 35(5), 413-416.