

Monoclonal Gammopathy with Systemic Amyloidosis: An Evaluation of Diagnostic Elements

¹C. T Subashini*, ¹E. George & ²U Nor Aini

¹Department of Pathology, Faculty of Medicine and Health Sciences,
Universiti Putra Malaysia, 43400 UPM Serdang, Selangor, Malaysia

²Department of Pathology, Faculty of Medicine,
Universiti Kebangsaan Malaysia, Jalan Yaacob Latif, Bandar Tun Razak,
56000 Cheras, Kuala Lumpur, Malaysia

ABSTRACT

Monoclonal gammopathies result from an overproduction of a single abnormal clone of plasma cell or B lymphocyte that produce an immunologically homogenous immunoglobulin (Ig) commonly referred to as paraprotein or monoclonal (M) protein. The circulating M-protein may consist of an intact immunoglobulin, the light chain only, or (rarely) the heavy chain only. The heavy chain is from one of the five immunoglobulin classes G, A, M, D or E, while the light chain is either kappa (κ) or lambda (λ) in type. Accurate detection and quantitation of monoclonal immunoglobulins is important for the diagnosis and management of monoclonal gammopathies. We report a case of a 71 year old lady with a history of chronic gastritis and recurrent lower respiratory tract infection whereby no specific diagnosis was made until a computed tomography (CT) guided lung biopsy and orogastroduodenoscopy (OGDS) 5 years later from the onset of initial symptoms revealed pulmonary and gastric amyloidosis, respectively.

Keywords: Monoclonal gammopathies, paraprotein, amyloidosis, light chain immunoglobulin (Ig), heavy chain Ig

INTRODUCTION

The monoclonal gammopathies encompass a number of diseases such as monoclonal gammopathy of undetermined significance (MGUS), smouldering multiple myeloma (SMM), multiple myeloma (MM), Waldenström's macroglobulinaemia (WM), solitary plasmacytoma, systemic amyloid light chain type (AL type) and POEMS (Polyneuropathy, Organomegaly, Endocrinopathy, Monoclonal gammopathy, and Skin changes) syndrome. Amyloidosis is a rare systemic disorder of protein metabolism with progressive extracellular deposition of insoluble fibrillary protein, disorganisation of tissue architecture, and subsequently organ dysfunction.^[1] This case highlights the importance of interpreting and correlating consecutive laboratory, radiological and invasive investigations in the diagnosis of monoclonal gammopathy whereby the clinical manifestations were not stereotypic of the disease.

THE CASE

A 71 year old lady initially presented to Universiti Kebangsaan Malaysia Medical Centre (UKMMC) in early April 2001 with a history of shortness of breath, lethargy, headache, palpitations, and was treated as community acquired pneumonia with oral antibiotics, based on the physical examination and chest X-ray (CXR) findings, which showed bilateral patchy opacities. Past medical history revealed chronic dyspepsia, relieved by antacids but she had never been investigated for and she had a history of passive smoking; her husband who had passed away from lung cancer was a chronic smoker.

Despite treatment, she presented frequently with similar respiratory symptoms. As such, bronchoscopy with bronchial and trans-bronchial biopsies was done, which ruled out lung malignancy. Culture of bronchial-alveolar lavage for acid-fast bacilli and fungus were negative. All blood investigations were unremarkable except for a raised erythrocyte sedimentation rate (ESR) at levels 71mm/hour and low serum creatinine between the ranges of 57-62 μ mol/L. She was started on empirical pulmonary tuberculosis treatment even though sputum for acid-fast bacilli and Mantoux test were negative and she had no history of contact with pulmonary tuberculosis.

Three months later, patient had clinically improved but there was still no change in CXR findings. Lung function tests showed a restrictive pattern and high resolution CT thorax showed consolidation of right lower zone and left lingula, suggestive of alveolar lung carcinoma. Fine needle aspiration cytology (FNAC) under CT guidance of both

*Corresponding author: shubha@medic.upm.edu.my

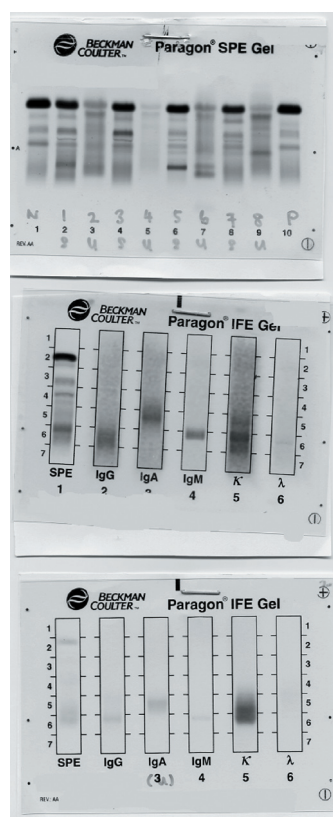
areas of the lungs revealed non-specific chronic inflammatory process with no malignant cells or granuloma seen. The patient was further planned for open lung biopsy but she refused.

Five years later in January 2006, she was readmitted with fever, productive cough, loss of appetite, loss of weight, epigastric pain, lethargy, weakness, bilateral leg swelling and decreased urine output. She had been seeking alternative treatment for the last 5 years and as such defaulted all treatment and follow-ups at UKMMC. On examination, she had oral candidiasis, bilateral, multiple, palpable submandibular lymph nodes, gross hepatomegaly of 5 finger breadths (fb) extending to epigastric region, pansystolic murmur, coarse crepitations and dullness of bilateral lungs. CXR showed bilateral pleural effusion with collapse consolidation. CT guided lung biopsy showed pulmonary amyloidosis, which was confirmed with congo red staining and apple-green birefringence under polarised light. Immunocytochemistry demonstrated lymphoplasmacytic cells negative for cytokeratin, chromogranin, neuron-specific enolase and positive for CD20. Few cells were positive for CD3. Kappa (κ) and lambda (λ) staining were equivocal. FNAC of bilateral submandibular lymph nodes showed scanty smears with no epithelial component and was reported as unsatisfactory for proper cytological examination. Echocardiogram (ECHO) revealed good left ventricular function with ejection fraction of 75%, dilated left atrium, global pericardial effusion (0.3cm), thickened mitral valve with trivial mitral regurgitation.

Laboratory investigations showed normocytic, normochromic anaemia (haemoglobin 9.8g/dL, MCV 77fl), raised platelet count ($553 \times 10^9/L$) with normal white cell counts. Full blood picture revealed mild rouleaux formation. No leukoerythroblastic picture was noted. Clotting times were prolonged; prothrombin time (PT) 16.1secs and activated partial thromboplastin time (APTT) 49.8secs. Renal profile was unremarkable except for a low serum creatinine ($44\mu\text{mol/L}$). Liver function tests revealed low albumin (28g/L) with a normal total protein. The albumin to globulin ratio was slightly reduced (0.8-1.0). Serum calcium levels were normal. Erythrocyte sedimentation rate (ESR = 119mm/hour), C-reactive protein (CRP = 13.25mg/dL) and lactate dehydrogenase (LDH = 311U/L) were elevated.

Patient was discharged 2 weeks later with further follow up at gastroenterology clinic for chronic dyspepsia, where she was planned for OGDS and sigmoidoscopy. OGDS showed amyloid deposits with chronic active gastritis and sigmoidoscopy revealed chronic non-specific colitis. Rectal biopsy was negative for amyloid.

Serum and urine protein electrophoresis were done considering the high ESR, low albumin, anaemia, clinical features of hepatomegaly, submandibular lymphadenopathy and the diagnosis of pulmonary and gastric amyloidosis. The electrophoresis results are summarised in Figure 1. A provisional diagnosis of IgM Kappa monoclonal gammopathy was made with complication of primary (systemic) amyloidosis.



Serum protein electrophoresis of the patient showed presence of monoclonal band in gamma region (labelled 1S)

← Urine protein electrophoresis of the patient showed generalised proteinuria. No Bence Jones protein seen (labelled 2U).

← Immunofixation of serum showed presence of IgM Kappa chain with paraprotein quantitation of 8.9g/L.

← Immunofixation of urine showed presence of free Kappa light chains. Paraprotein quantitation was not done.

Figure 1. Electrophoresis gel findings

She was also scheduled for an excision biopsy of bilateral submandibular lymph nodes and a bone marrow study to rule out haematological malignancy. Unfortunately, the hospital was informed by the patient’s next of kin that she had passed away at home one week before the given date for the excision biopsy of the submandibular lymph nodes. The exact cause of death was not ascertained, as clinical autopsy was not done. However, according to the patient’s next of kin, she was having fever with severe respiratory symptoms such as productive cough, wheezing, and shortness of breath over the last two days prior to her death but refused admission to hospital. Thus, the presumptive cause of death was an acute pulmonary complication of amyloidosis with IgM Kappa monoclonal gammopathy.

DISCUSSION

This is a case of systemic amyloidosis (AL type) that developed in a patient with IgM monoclonal gammopathy. A specific diagnosis of which type of IgM monoclonal gammopathy could not be made in this patient, as she did not undergo bone marrow examination.

In the Second International Workshop on Waldenstrom’s macroglobulinaemia (WM) held in Athens, Greece, in September 2002, a consensus panel of experts tried to define clear and reproducible criteria for the diagnosis of the clinicopathologic entities recognisable within the spectrum of IgM gammopathies. It was stated WM is characterised by “unequivocal evidence of bone marrow infiltration by lymphoplasmacytic lymphoma, irrespective of the serum IgM concentration. Moreover, WM should be considered symptomatic (S-WM) or asymptomatic (A-WM) according to the presence or absence of features attributable to tumour infiltration; constitutional symptoms, cytopenia(s), organomegaly, and/or symptoms attributable to the monoclonal protein (hyperviscosity syndrome, cryoglobulinaemia, amyloidosis, or autoimmune phenomena such as peripheral neuropathy and cold agglutinin disease). The clinical condition with symptoms attributable to monoclonal protein, but without evidence of lymphoma, was recognised as a distinct entity for which the term “Ig-M related disorders” was proposed. Finally, patients with IgM monoclonal protein but no morphologic evidence of bone marrow infiltration by lymphoma (or even equivocal marrow infiltrates without confirmatory phenotypic studies) should be classified as having a monoclonal gammopathy of undetermined significance (IgM-MGUS).”^[2] These criteria are summarised in Table 1:

Table 1. Criteria for IgM Monoclonal Gammopathies^[2]

	IgM monoclonal protein	BM infiltration	Symptoms attributable to IgM	Symptoms attributable to tumour infiltration
WM Symptomatic	+	+	+	+
WM Asymptomatic	+	+	-	-
IgM Related Disorders	+	-	+	-
MGUS	+	-	-	-

The panel did not assign a specific level of bone marrow infiltration that would be required to differentiate IgM MGUS from WM. The diagnostic criteria given in Table 1 have been updated in an evidence-based manner such that the diagnosis of WM requires 10% or greater lymphoplasmacytic infiltration. Presence of less than 10% lymphoplasmacytic infiltration in the absence of end-organ damage represents IgM MGUS and not WM; such patients have a risk of progression to symptomatic disease at a rate of only 1.5% per year.^[1]

World Health Organisation (WHO) criteria for the diagnosis of multiple myeloma (MM), is as follows: requires a minimum of one major and one minor criteria or three minor criteria which must include (1) and (2). These criteria include the following *major criteria*: 1) marrow plasmacytosis ≥ 30%, 2) plasmacytoma on tissue biopsy, 3) monoclonal protein (by densitometric scanning) – IgG > 35g/L, IgA > 20g/L and Bence Jones > 1g/24hour and *minor criteria*: 1) marrow plasmacytosis (10-29%), 2) monoclonal protein present but less than in major criteria, 3) lytic bone lesions, reduced normal Ig (< 50% normal) - IgM < 0.5g/L, IgA < 1g/L, IgG < 6g/L. These criteria must manifest in a symptomatic patient with progressive disease.^[3]

In this patient, however, the following features of IgM multiple myeloma which include presence of myeloma cells in bone marrow, suppression of normal IgG and IgA levels, presence of osteolytic bone lesions and presence of 14q32 translocation (IgH switch region rearrangements), were not investigated for to differentiate Waldenstrom’s macroglobulinaemia from IgM multiple myeloma.^[3]

Dimopoulos *et al.* mention that some individuals have presented with a complication caused by the macroglobulin, such as peripheral neuropathy, cold agglutinin disease, cryoglobulinaemia, or amyloidosis, but the concentration

of monoclonal IgM is low. In these patients, there is no evidence of organomegaly or lymphadenopathy, and a lymphoplasmacytic infiltration of the bone marrow is absent. Presumably, in such patients, the specific property of monoclonal IgM caused symptoms several years before overt WM developed.^[4]

This seems to have been the case with this patient who had considerably low levels of IgM detected on electrophoresis (8.9g/L), no signs and symptoms of bone marrow infiltration but presented with symptoms of systemic amyloid infiltration and immunosuppression such as oral candidiasis and recurrent respiratory infections. However, this patient had hepatomegaly and lymphadenopathy. Again, WM cannot be totally ruled out in this patient, as bone marrow examination which, is central to the diagnosis, was not done.

In a recent study at the Mayo clinic, amyloidosis developed in 2% of patients with monoclonal IgM and 76% showed a λ light chain. Cardiac, renal, hepatic and pulmonary involvements predominated, and were the cause of death more often than the underlying WM. The incidence of cardiac and pulmonary involvements seemed to be higher in patients with IgM related amyloidosis than in patients with other cases of primary amyloidosis.^[4] Amyloid is best identified from biopsy of an involved organ. The diagnostic biopsy sites generally are the abdominal subcutaneous fat-pad, bone marrow, or the rectum.^[3]

Rectal biopsy in this patient was negative. However, pulmonary and gastric amyloid involvements were confirmed by biopsy. She may have also had hepatic and cardiac amyloid infiltration considering she had hepatomegaly and signs and symptoms of congestive cardiac failure. Nevertheless, the hepatomegaly could have been due to direct tumour infiltration, which may also be the cause for her submandibular lymphadenopathy.

Anaemia is the most common finding in patients with symptomatic WM and is caused by mild decrease in red cell survival, impaired erythropoiesis, haemolysis, moderate plasma volume expansion, and blood loss from the gut. Blood smears are usually normocytic and normochromic, and rouleaux formation is often pronounced. In addition, the haemoglobin estimate can be inaccurate, ie. falsely high, because of interaction between the monoclonal protein and the diluent used in some automated analysers. Leukocyte and platelet counts are usually within the reference range at presentation.^[5]

In this case, there was normochromic, normocytic anaemia with mild rouleaux formation and white cell count was normal as expected. Thrombocytosis, however, was observed and may be a consequence of functional hyposplenism from possible amyloid replacement of the spleen.^[5]

ESR is a non-specific test that measures the speed of sedimentation of red cells in plasma over a period of 1 hour. The speed is mainly dependent on the plasma concentration of large proteins such as fibrinogen and immunoglobulins. The normal range in men is 1-5mm/hour and in women 5-15mm/hour but there is progressive increase in old age. A raised ESR is associated with marked rouleaux formation of red cells in the peripheral blood film. It is almost constantly observed in WM and may be the first clue to the presence of the macroglobulin.^[5] This seemed to have been the only clue initially in this patient.

The clotting abnormality detected most frequently is prolongation of thrombin time, which was not done in this patient. The prolongation of the PT and APTT in this case could be due to the macroglobulin interfering with the coagulation factors.^[1, 2]

Central to the diagnosis of WM is the demonstration of bone marrow infiltration by lymphoplasmacytic lymphoma. This is defined as a tumour of small lymphocytes showing evidence of plasmacytoid / plasma cell differentiation without any of the clinical, morphological or immunophenotypic features of other lymphoproliferative disorders.^[2, 3] A trephine biopsy is mandatory requirement for the assessment of patients while lymph node biopsies are encouraged in patients with accessible nodes.^[2] Unfortunately, this patient passed away before bone marrow examination and submandibular lymph node biopsy could be done to confirm if it was WM.

Biochemical investigations done in this patient revealed normal renal profile and serum calcium levels. Hypercalcaemia and Bence Jones proteinuria more than 1.0g/24hours occur in less than 5% of patients with WM. The low incidence of these abnormalities explains the rarity of renal tubular cast formation in these patients.^[4] Serum creatinine level was low probably because the patient was cachectic. Liver function tests were unremarkable except for a low albumin level. In this regard, if the ratio of albumin to globulin is low, further investigation for plasma cell disorder should follow. It is reported that low albumin may reflect effects on the liver by interleukin (IL)-6 produced by microenvironment of myeloma cells but it remains to be explored in WM.^[4]

C-reactive protein (CRP) is a crude 'early' immunoglobulin, which initiates the inflammatory reaction. CRP-antigen complexes can substitute for antibody fixation of C1q and trigger the complement cascade initiating the inflammatory response to antigens or tissue damage. After tissue injury, an increase in CRP and other acute phase reactants may be detected within 6-10 hours. Immunoassays of CRP are now widely used for early detection of acute inflammation or tissue injury and for monitoring of remission, eg. response of infection to an antibiotic. IL-6 is a major plasma cell growth factor, and elevated serum levels have been associated with short survival in multiple myeloma. IL-6 also influences the hepatic synthesis of several acute phase proteins such as CRP. Thus, CRP represents a surrogate marker for IL-6 concentration. There is evidence that the spontaneous differentiation of the malignant B-cells in WM to monoclonal IgM-

secreting plasma cells in the absence of cell proliferation is dependent on autologous production of IL-6 by these cells.^[1] In this case CRP was raised but there is no current literature on the prognostic value of CRP in WM.

Lactate Dehydrogenase (LDH) activity is increased in some patients with a very aggressive form of multiple myeloma despite intensive treatment. Although this increase occurs in only a minority of myeloma patients, it indicates poor prognosis.¹ There is an increase of LDH in this patient but, again, there is no consensus on it being a measure of tumour burden in WM.

Serum β_2 microglobulin, which was not done in this patient, is used as a predictor of malignant evolution in smoldering/asymptomatic WM and as a prognostic marker in systemic amyloidosis. A value of $> 3\text{mg/L}$ in a patient with monoclonal gammopathy with no renal insufficiency strongly suggest malignant disease. Serum β_2 microglobulin was found to be $> 3\text{mg/L}$ in approximately 60% of WM patients at diagnosis.^[1]

Serum troponin T, a sensitive marker for ischemic cardiac injury, and N-terminal-pro brain natriuretic peptide (NT-proBNP), which has been shown to correlate with left ventricular dilatation, dysfunction, and congestive cardiac failure in a non-amyloidosis setting, have been shown to be powerful predictors of survival in amyloidosis, and were feasible even in the setting of end-stage renal disease.^[2]

Electrophoretic studies of serum and urine are necessary for the diagnosis, staging and serial follow-up of patients with plasma cell disorders. A high index of suspicion is often required when symptoms are vague or inconsistent, overt physical findings are not evident, and standard laboratory data are negative; as in this case whereby there was no typical features of WM such as lymphocytosis ($> 4 \times 10^9/\text{L}$), symptoms of hyperviscosity syndrome or severe anaemia. Amyloidosis has often been recognised after many months of unexplained fatigability, weight loss, or peripheral oedema; also proven to be the case in this patient.^[5]

After monoclonal abnormality has been detected on serum electrophoresis, immunofixation is necessary to confirm heavy-chain and light chain types. Once defined, a repeat immunofixation is not justified unless a new clonal abnormality is suspected, such as after a stem cell transplant-supported treatment. The quantitation of uninvolved immunoglobulins by nephelometry provides supplemental information. A high level for one component coupled with low or normal levels for other components confirms the definition by immunofixation of a specific monoclonal protein elevation.^[5] The light chain is of the monoclonal IgM is κ in 75-80% of patients.^[4] However, λ chains occur more frequently in systemic amyloidosis than κ chains ($\lambda - \kappa$ ratio 4:1).^[1]

In this case, IgM κ was detected by serum electrophoresis and immunohistochemistry of amyloid deposits showed CD20⁺ lymphoplasmacytic cells with equivocal κ and λ staining, consistent with a diagnosis of IgM monoclonal gammopathy with a complication of systemic amyloidosis. Unfortunately, the patient passed away before bone marrow examination was done to determine which type of IgM monoclonal gammopathy in order to commence treatment.

CONCLUSION

In this patient, the clinical manifestations were not stereotype of multiple myeloma or Waldenstrom's macroglobulinaemia but the elevated ESR from the initial presentation 5 years ago, low albumin, recurrent infections, constitutional symptoms such as fever, weight loss, lethargy, fatigue should have raised a suspicion of a plasma cell disorder. Having said that, if the patient had diligently followed up and not defaulted for 5 years, the diagnosis would have probably been made much earlier and appropriate treatment could have been commenced.

REFERENCES

- [1] Rajkumar SV, Dispenzieri A, Kyle RA. Monoclonal Gammopathy of Undetermined Significance, Waldenstrom's Macroglobulinemia, AL Amyloidosis, and related plasma cell disorders: diagnosis and treatment. *Mayo Clinical Proceedings* 2006; 81(5): 693-703.
- [2] Owen RG, Treon SP, Al-Katib A *et al.* Clinicopathological definition of Waldenstrom's Macroglobulinemia. Consensus panel recommendations from the Second International Workshop on Waldenstrom's Macroglobulinaemia. *Seminars in Oncology* 2003; 30(2): 110-115.
- [3] Jaffe ES, Harris NL, Stein H, Vardiman JW. WHO Classification of tumour: Pathology and genetics of tumours of haemopoietic and lymphoid tissues. Lyon: IARC Press, 2001.
- [4] Dimopoulos MA, Panayiotidis P, Moulopoulos LA, Sfikakis P, Dalakas M. Waldenstrom's Macroglobulinemia: Clinical features, complications, and management. *Journal of Clinical Oncology* 2000; 18(1): 214-226.
- [5] Gertz MA, Merlini G, Treon SP. Amyloidosis and Waldenstrom's Macroglobulinaemia. *Hematology* 2004; 257-282.

