



Platoni, Kalliopi and Diamantopoulos, Stefanos and Dilvoi, Maria and Delinikolas, Panagiotis and Kypraiou, Efrosyni and Efstathopoulos, Efstathios and Kouloulis, Vassilios (2018) First application of hemi-body electron beam irradiation for Kaposi sarcoma at the lower extremities. Journal of B.U.ON., 23 (1). pp. 268-272. ISSN 2241-6293 ,

This version is available at <https://strathprints.strath.ac.uk/63590/>

Strathprints is designed to allow users to access the research output of the University of Strathclyde. Unless otherwise explicitly stated on the manuscript, Copyright © and Moral Rights for the papers on this site are retained by the individual authors and/or other copyright owners. Please check the manuscript for details of any other licences that may have been applied. You may not engage in further distribution of the material for any profitmaking activities or any commercial gain. You may freely distribute both the url (<https://strathprints.strath.ac.uk/>) and the content of this paper for research or private study, educational, or not-for-profit purposes without prior permission or charge.

Any correspondence concerning this service should be sent to the Strathprints administrator: strathprints@strath.ac.uk

SHORT COMMUNICATION

First application of hemi-body electron beam irradiation for Kaposi sarcoma at the lower extremities

Kalliopi Platoni¹, Stefanos Diamantopoulos¹, Maria Dilvoi¹, Panagiotis Delinikolas², Efrosyni Kypraiou¹, Efstathios Efstathopoulos¹, Vassilis Kouloulis¹

¹2nd Department of Radiology, Radiotherapy Unit, "Attikon" Hospital, University of Athens, Athens, Greece; ²Space Radiobiology Research, Physics Department, Strathclyde University, Glasgow, UK

Summary

Kaposi's sarcoma (KS) is a systemic neoplastic disease that can present cutaneous symptoms and is usually treated with a systematic approach due to its extent. Due to its radiosensitivity, radiotherapy is considered one of its main treatments, for palliation and local control of the skin and mucosal lesions.

The aim of this paper was to report the first case of KS treated by hemi-body electron irradiation protocol in Greece. A fractionated 40 Gy hemi-body electron irradiation was prescribed to a 60-year-old male patient with KS at his legs. Dose uniformity was verified on a daily basis by thermo-

luminescence dosimetry (TLD). The treatment resulted to complete clinical response. Limited irradiation-derived side effects appeared.

This is the first case ever to be treated with hemi-body electron irradiation protocol in Greece. To the best of our knowledge, this is also the first time that a single field hemi-body electron beam irradiation at a total skin electron beam (TSEB)-like configuration is reported to be used for KS.

Key words: hemi-body electron beam irradiation, radiotherapy, Kaposi sarcoma

Introduction

KS is a systemic neoplastic disease that can present cutaneous symptoms without excluding visceral involvement. It is usually treated with a systematic approach due to its extent. As KS is a radiosensitive disease, radiation therapy is considered one of the main treatments, for pain relief, edema palliation, bleeding control, as well as local control of the skin and mucosal lesions [1,2].

As in most cases, skin is the target organ for radiation therapy of KS, and electron beams produced by linear accelerators are utilized with energies of 4-9 MeV, which have the appropriate therapeutic range. Typically, KS is spread all over the patient's body (similarly to mycosis fungoides-MF), therefore dose delivery is performed

in a rather non conventional off-couch setup with an extended source-skin distance (SSD), in an attempt to cover all skin. This technique in literature is referred to as TSEB therapy [3-6]. In case of high concentration of symptoms either on upper or lower part of the body, TSEB could be modified to a half-body electron irradiation technique (HBE⁻), focusing only in the malignant area and minimizing dose to the healthy skin.

Based on the already established TSEB technique of our department [7], we developed a HBE⁻ technique, to enable provide treatment to such patients. We describe the case of the first KS patient that was treated in this modality in our department, as well as our technique and dosimetry during treatment.

Case description history

In March 2011 a 60-year-old patient developed a cutaneous lesion of 1.3 cm in his right ankle that was haemorrhagic and ulcerous. In April 2011, the lesion was surgically removed and the histology showed KS with clear boundaries. The patient received systemic therapy with interferon- α 1,000,000 IU 3 times per week. In May 2013, the patient presented again with a relapsed lesion in the right leg at the anatomical area of gastrocnemius, whereas the histology showed again KS. The patient received again systemic therapy with interferon- α 1,000,000 IU 3 times per week with partial response. In June 2015 the patient presented again with a relapsed lesion in the right leg (histologically proven as KS) and he received again the same systemic treatment with interferon- α again with partial response. In July 2016, the patient presented with more and extended lesions of the already known disease at the right and left leg (Figure 1, a-b). This time the local tumor board decided to change the systemic treatment into liposomal doxorubicin (caelyx). At first administration of caelyx the patient developed grade III toxicity with palmar / plantar syndrome related to doxorubicin. After that, it was decided to deliver an irradiation schedule of electron beams to both legs. Computerized tomography (CT) images of the thorax, as well as of the upper and lower abdomen for clinical staging, showed no evidence of metastatic disease.

Radiation treatment

Since only the lower part of the body was involved, half-body electron irradiation was initiated. A modification of the TSEB technique of our department was utilized [7]. The patient was irradiated by a single angled 6 MeV electron field (gantry angle of 279.5 degrees) at a SSD of 388 cm produced by a Varian 2100C linear accelerator (Varian Medical Systems Inc, Palo Alto, CA, USA). The field dimensions were 36 \times 36 cm² and the dose rate 2500 MU/min at isocenter. The patient was standing on the homemade TSEB device, which was equipped with a large polymethyl methacrylate (PMMA) panel (203 \times 111 cm) of 0.5 cm thickness, located 30 cm from the treatment plane. Treatment positions were similar to the typical TSEB postures, with beam incidence of 0, 60, 120, 180, 240 and 300 degrees (Figure 2, a-f). This setup produced a field of 3.2 MeV average energy at treatment plane, which was translated to a practical range of 1.91 g/cm². Bremsstrahlung contaminating photon radiation was kept under 0.7%, since the central axis of the beam was pointing between the legs of the patient. The upper part of the body was sufficiently shielded (transmission < 5%) by a custom crafted and adjustable lead (Pb) shielding (0.2 cm) attached to the immobilization device. To avoid radiation-induced toxicity to toe nails (e.g melanonychia), additional Pb shielding of 0.4 cm was utilized during each fraction, as well as a shielded jockstrap for genitalia sparing (Figure 2).

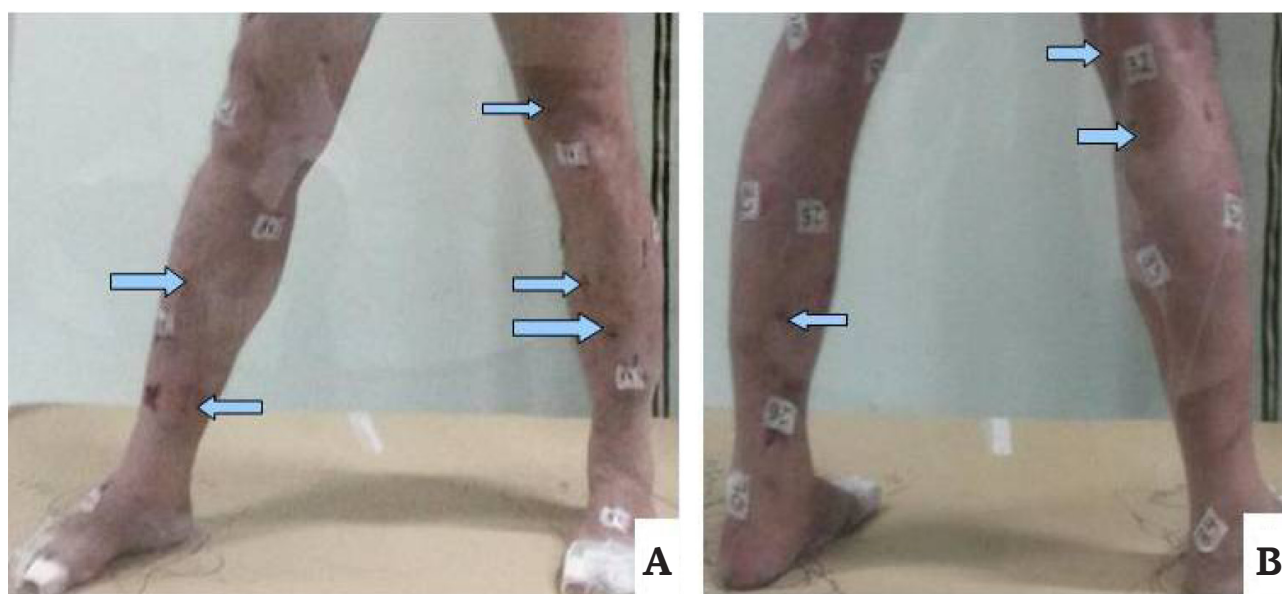


Figure 1. Anterior (A) and posterior (B) view of cutaneous lesions. Arrows are showing some of the lesions. TLDs are also shown sited at the skin before irradiation.




Figure 2. Irradiation setup of patient: (A) 60, (B) 0, (C) 300, (D) 120, (E) 180 & (F) 240 degrees.

The prescribed dose was 40 Gy, fractionated in a daily dose of 2 Gy, following a 5-day per week irradiation schedule, in order to fully cover the malignant skin surface. The radiotherapy course was started in 17th October 2016 and was completed in 17th November 2016.

Daily dose verification was performed by TLD (GR200A). Dosimeters were distributed uniformly to skin, on marked positions for repeatability of measurements (Figure 1). Six more dosimeters were positioned on blocked areas (upper part of the body) in order to verify sufficient protection of the healthy skin. Detectors were handled within opaque paper envelopes. Procedures of calibration, annealing and reading were performed by an ETT annealing oven and a LTM manual TLD reader (Fimel, Vélizy, France).

Discussion

In vivo measurements reveal a homogeneous dose distribution on the skin with mean percentage dose of 100% of the prescription (2 Gy), with a standard deviation of $\pm 15\%$. The maximum recorded percentage dose value was 130% (thighs) and the minimum 65% (soles). Dosimeters placed

on the blocked area recorded only background signal ($<0.3\%$) (Figure 3).

During irradiation the patient developed grade III radiation-induced morbidity according to EORTC/RTOG toxicity criteria [8]. Three months postirradiation the patient had only a slight erythema (grade I skin toxicity, EORTC/RTOG criteria) [8]. Six months post irradiation the patient had no skin toxicity with complete remission of the KS lesions (Figure 4, a-d).

Nicolini et al. [2] investigated the potential of utilizing a volumetric arc (VMAT) technique for the irradiation of leg KS. In their work they presented the dosimetric superiority of VMAT in terms of planning treatment volume (PTV) coverage, dose homogeneity and healthy tissue sparing in comparison to multiple electron field-matching technique. They also emphasized the treatment time aspect, which is in favor of VMAT as well. In our work, we used previous experience with TSEB to irradiate a similar case. As the patient was irradiated with a large electron field at the highest dose rate, beam-on time was kept under 6 min. Dose homogeneity did not reach VMAT reported values, nevertheless, the clinical outcome was excellent. In our technique no need

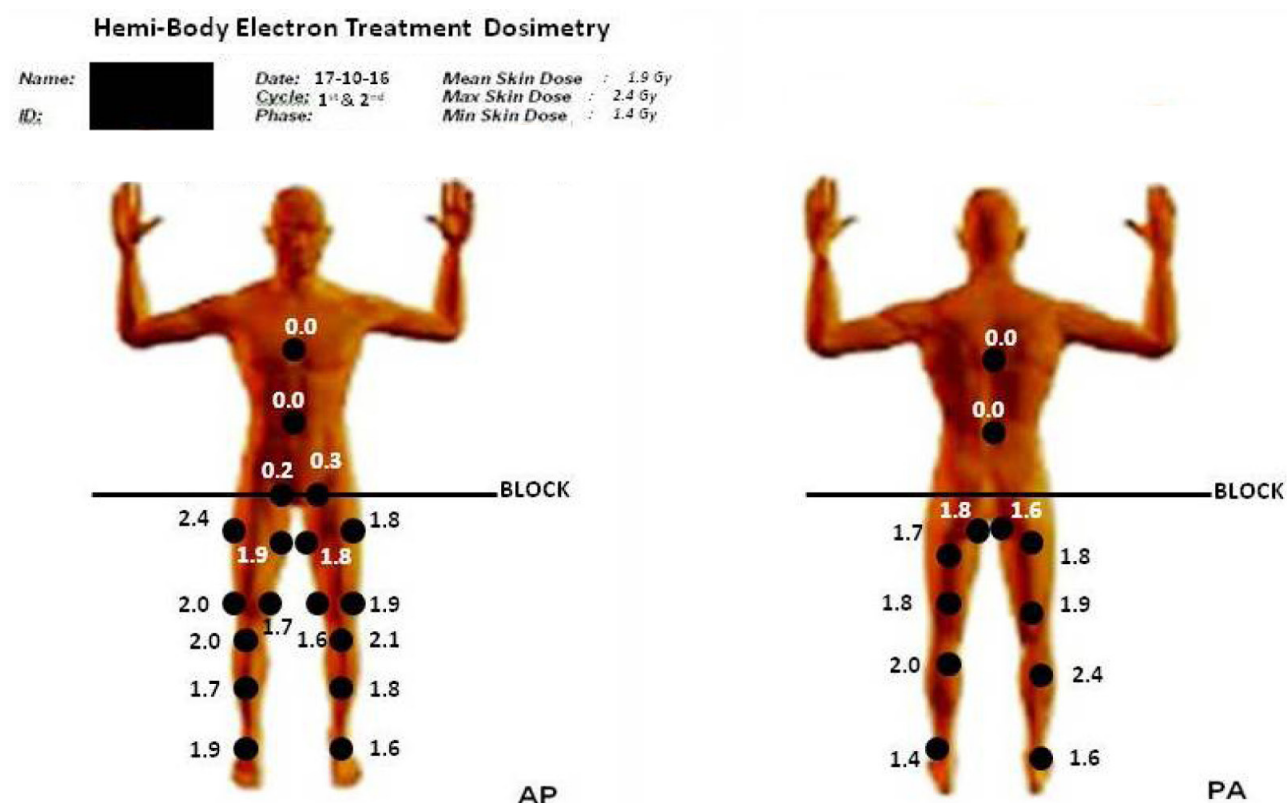


Figure 3. Form of dosimetric recording from the first session of the patient. Dots represent the positions of TLDs on skin. Values are expressed in Gy.

of CT scan is required, which could be a limiting factor for some clinics.

This is the first case with KS ever to be treated with hemi-body electron irradiation protocol in Greece. To the best of our knowledge, this is also the first time that a single field hemi-body

electron beam irradiation at a TSEB-like configuration is reported to be used for KS.

Conflict of interests

The authors declare no conflict of interests.

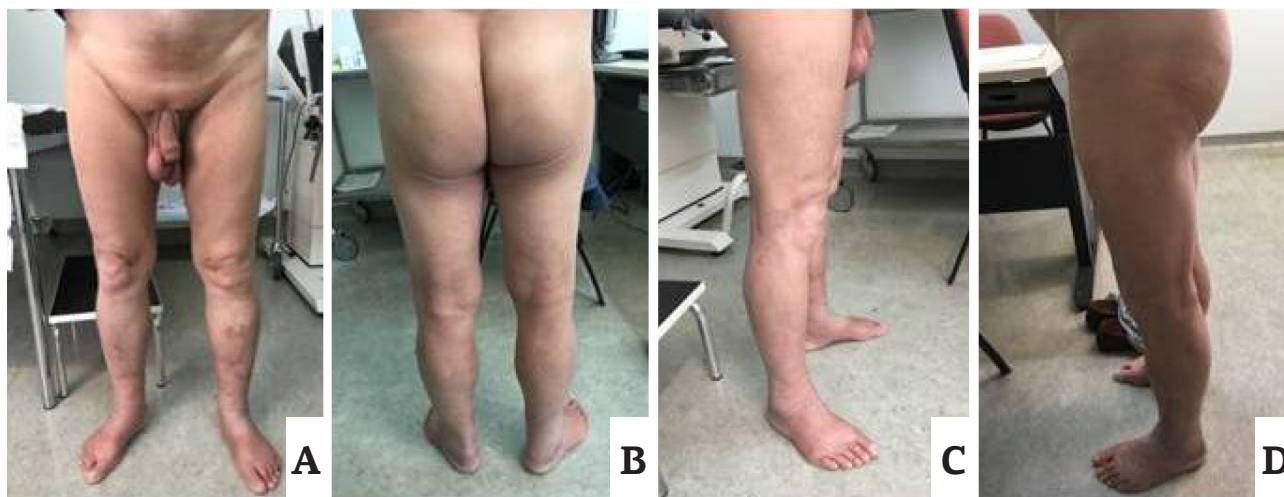

Figure 4. Complete remission of the Kaposi sarcoma lesions after six months post irradiation with a 40 Gy hemi-body electron irradiation scheme at (A) front, (B) back, (C) right side, and (D) left side.

References

1. Donato V, Guarnaccia R, Dognini J et al. Radiation therapy in the treatment of HIV-related Kaposi's sarcoma. *Anticancer Res* 2013;33:2153-7.
2. Nicolini G, Abraham S, Fogliata A et al. Critical appraisal of volumetric-modulated arc therapy compared with electrons for the radiotherapy of cutaneous Kaposi's sarcoma of lower extremities with bone sparing. *Br J Radiol* 2013;86:20120543.
3. American Association of Physicists in Medicine AAPM. Report no.23: Total skin electron therapy: Technique and dosimetry, Report of Group 30 Radiation Therapy Committee. AAPM, 1987. http://www.aapm.org/pubs/reports/rpt_23.pdf. Accessed February 12, 2017.
4. Diamantopoulos S, Platoni K, Dilvoi M et al. Clinical implementation of total skin electron beam (TSEB) therapy: a review of the relevant literature. *Phys Med* 2011;27:62-8.
5. Diamantopoulos S, Platoni K, Kouloulias V et al. First treatment of mycosis fungoides by total skin electron beam (TSEB) therapy in Greece. *Rep Pract Oncol Radiother* 2014;19:114-9.
6. Piotrowski T, Milecki P, Skorska M et al. Total skin electron irradiation techniques: a review. *Adv Dermatol Alergol* 2013;30:50-5.
7. Platoni K, Diamantopoulos S, Panagiotakis G et al. First application of total skin electron beam irradiation in Greece: setup, measurements and dosimetry. *Phys Med* 2012;28:174-82.
8. Cox JD, Stetz J, Pajak TF. Toxicity criteria of the Radiation Therapy Oncology Group (RTOG) and the European Organization for Research and Treatment of Cancer (EORTC). *Int J Radiat Oncol Biol Phys* 1995;31:1341-6.