

# Argon Laser in Human Tympanoplasty

Luiz H. Escudero, MD; Aluysio O. Castro, MD; Milton Drumond, MD; Sergio P. S. Porto, PhD; Dimitrios G. Bozinis, PhD; Antonio F. S. Penna, PhD; Eliseo Gallego-Lluesma, PhD

• We describe the use of an argon laser in human tympanoplasty. The laser was used in two different ways: (1) to stop the bleeding of small vessels in the external auditory channel and eardrum remains; and (2) to spot-weld the new eardrum graft in the proper position. Seven operations were performed. We report the results.

(*Arch Otolaryngol* 105:252-253, 1979)

Ever since the advent of the laser, numerous applications have been suggested and put into practice. Its potentiality as a surgeon's tool has been demonstrated, and current use of the laser in some fields is now well established. Some of these applications include the use of the carbon dioxide laser in general surgery as well as in throat surgery. Others include the well-known use of the laser in the treatment of diabetic retinopathy, in which the visible argon laser radiation photocoagulates and prevents the bleeding of vessels on the retina. What makes the laser different from ordinary radiative sources is both its spatial and temporal coherence. In other words, radiation from a laser source can be collimated to a much higher degree than the noncoherent light sources; and at the same time, it is selectively absorbed or transmitted by a specific medium depending on the particular choice of the laser. For example, the ocular medium will transmit the blue-green lines of the argon laser, but the hemo-

globin will absorb them within a few microns of depth. It is now possible to choose from a variety of laser sources to suit almost any application. For example, the CO<sub>2</sub> and neodymium lasers are used in dentistry, general surgery, urology, and the treatment of wounds. The ruby laser, the first one to be constructed (1960), is used in all fields of biomedical research. Similarly, the argon and krypton lasers have been tried in such areas as cytology, dermatology, and oncology. Since the development of new laser sources is constantly innovated, so are its uses in various fields, including medicine.<sup>1</sup>

We describe the first successful attempt of the use of the argon laser in tympanoplasty.

## SURGICAL METHODS IN TYMPANOPLASTY

Some of the results described herein have been reported elsewhere.<sup>2</sup> As it is known, the conventional tympanoplastic surgery follows the techniques described widely in the literature.<sup>3</sup> When the perforation of the tympanic membrane is small, the surgery is done through the auditory canal. When the perforation is large or the pathologic features of the case requires, we use the classical postauricular access described by Portmann et al.<sup>3</sup> In the last case, subsequent steps including the postauricular incision, the detachment of the anterior and posterior pedicle flaps, the removal of the epithelium of the remainder of the eardrum will frequently cause bleeding in different proportions in the small vessels affected. This bleeding causes two well-known problems for the surgeon. First, due to the smallness of the surgical field, the vision is reduced by even the smallest amount of bleeding. Second, after the implantation of the "fascia temporalis" graft, the bleeding may displace it into a wrong position, and in more

extreme cases the bleeding may bring about detachment and final rejection. In the classical procedure, electrocautery is used to produce hemostasis in the external canal, while in the interior canal and in the middle ear the bleeding is only alleviated by aspiration. This is sometimes difficult and time-consuming. Even in the outside part of the postauricular incision where electrocautery is used, tissue damage may be extensive and not restricted to the small vessels alone.

After shaping, the "fascia temporalis" graft is implanted over the bone surface, the old eardrum and anulus following the classical onlay procedure. After being placed in correct position, the anterior and posterior pedicle flaps are repositioned, and absorbable gelatin sponge is used to maintain these in the correct position.

Unfortunately, in some cases the ideal position is not achieved and the graft moves, losing direct contact with the ossicular chain due to the previously mentioned bleeding or mechanical problems such as air pressure from the Eustachian tube, or sudden movement during the postoperative period.

## THE APPARATUS

For all of the operations we used an argon ion laser with maximum working output power of 3 W. For the delivery of the laser radiation to the ear we used a 100- $\mu$  quartz fiber approximately 2 m long. Both ends of the fiber were polished down to 1  $\mu$  with alumina powder and then encapsulated for its protection. An X-Y slide positioned the focused light into one end of the fiber, while the other end was coupled with a syringe tube that served both as protective shield and guide. An electronically controlled shutter delivered the laser radiation in intervals of 0.1, 0.2, 0.5, and 1.0

Accepted for publication June 29, 1978.

From the Departments of Otolaryngology, Universidade Católica de Campinas (Dr Escudero) and Hospital de Beneficência Portuguesa (Drs Castro and Drumond), and the Instituto de Física, Universidade Estadual (Drs Porto, Bozinis, Penna, and Gallego-Lluesma), Campinas, Brazil.

Reprint requests to Instituto de Física, UNICAMP, CP 1170, 13100 Campinas, SP, Brazil (Dr Bozinis).

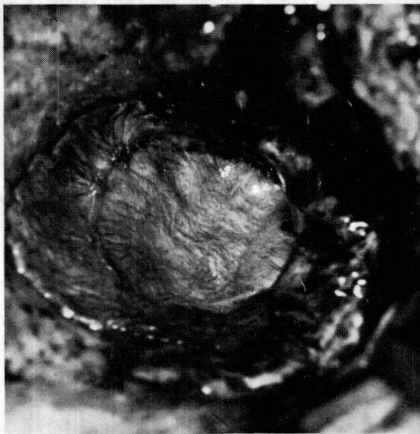

Fig 1.—Fascia graft in place. Argon laser spots are visible immediately after irradiation.

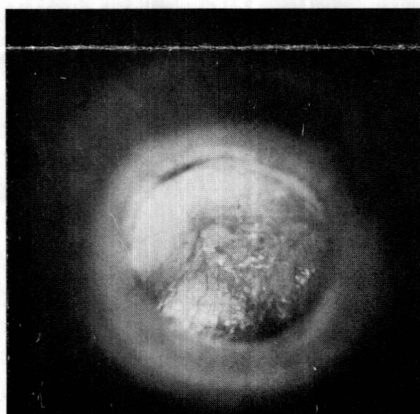


Fig 2.—Neotympanum of patient recently operated on. Preferred vascularization around laser spots is visibly abundant.

seconds. The surgeon worked with the help of a microscope (Zeiss) while manipulating the fiber tip manually. Periodically, the fiber tip was immersed into physiological solution to clean it, because contact with the surrounding tissues possibly could increase the absorption at the fiber tip, resulting in damage of the fiber. For the safety of the physician's sight against the magnified laser light, we used two orange filters attached directly to the viewing microscope.

#### THE LASER-ASSISTED OPERATION

The first indication that an argon laser could be used successfully in ear surgery was the experimental evidence in irradiated guinea pigs. Of course, there was the analogy of the ophthalmic experience, but concrete

evidence was needed before we could attempt to use laser radiation in humans. For this purpose, we performed several operations on dogs and rabbits, exposing the outer and inner ear to different levels of power and time exposures using the apparatus described earlier. The spot size was varied from a minimum of 100  $m\mu$  in diameter. The subsequent histological tests have shown the effects of such application.

We used the electrocautery simultaneously with the laser to compare the effects of the two methods. The results of both methods indicate that the laser produces far less tissue damage while allowing a better control of the penetration and the selectivity of the radiated area. These experiments are continuing at the present time and will be published.

After the determination of the feasibility of the method by previously understanding the overall results of the laser parameters such as power levels, time exposure, and spot size, we undertook the task of applying the argon laser in human tympanoplasty. We have used the laser in seven cases. All of the patients were prepared using routine preoperative and postoperative examinations, and the results were recorded several times during the follow-up period. Pictures were taken during the operation and the following visits in order to establish the possible beneficial effect of argon laser radiation.

We use the laser as a means of hemostasis by applying the laser beam directly to the bleeding vessel. In most cases, the time exposure was 0.2 seconds with powers varying between 500 and 1,000 mW. Bleeding was halted in all cases with remarkable efficiency. After placing the "fascia temporalis" in position, we applied the laser radiation around the tympanic area so that it would coincide with the underlying cone of the external auditory canal. The power level used here was around 500 mW, with exposures of 0.2 and 0.5 seconds. An average of ten spots was applied in each case, as shown in Fig 1. One of the immediate effects caused by the laser was the contraction of the tissue (Fig 1). In order to increase the

absorption of the laser radiation by the tissue and improve the adhesion of the graft on the bone, in some cases we used traces of blood as "flux" by impregnating slightly the two surfaces before the application of the laser. In all cases, we tested the adhesion of the graft by actually pulling the edge of the tissue near the laser spot. The fascia temporalis adhered to the bone, thus defining the areas of vascularization of the graft immediately after the operation.

#### COMMENT

During the postoperative and follow-up examinations we determined the proper position of the neotympanum and no rejection of any form was observed. The most striking effect was the observation of preferred abundant vascularization around the laser spots. These vascularizations started to appear immediately after the operation, as seen in Fig 2. The auditory tests that followed established the proper response of the graft to sound stimulation.

The important question as to whether these operations would have had different results without the laser must be answered by further operations to establish a sufficiently large number of experiments to be tested statistically. It is now our opinion that the laser is a tool that can considerably improve the fixation chances of the graft during tympanoplasty with apparently no harmful effects to the patient. Nevertheless, due care must be taken to prevent damage to the tissue by the use of excessive laser power. Because the laser beam is focused, there can be no damage to the inner ear, since its power drops inversely proportional to the square of the distance beyond its focal point even if no absorption occurs.

#### References

1. Eichler J, Lenz H: Laser applications in medicine and biology: A bibliography. *Appl Optics* 16:27-45, 1977.
2. Escudero LH, Castro AO, Porto SPS, et al: Laser radiation in ear surgery. Read before the 11th World Congress of Otorhinolaryngology, Buenos Aires, March 1977.
3. Portmann G, Portmann M, Clavierie G: *La Chirurgie de la Surdit , son  tat actuel, son avenir*. Paris, Soci t  Francaise D'oto-rhino-Laryngologie, Librairie Arnette, 1960.