

ARTICULO ORIGINAL

Expression of Vascular endothelial growth factor in normal and tumoral liver mouse cells

Errecalde Ana Lía¹, Inda Ana María^{2*}, García Marcela³, Andrini Laura³,
García Adriana², Furnus Cecilia^{2**}

Cátedra de Histología y Embriología "A". Facultad de Ciencias Médicas. U.N.L.P.

Calle 60 y 120 (1900) La Plata. Buenos Aires. Argentina

⁽¹⁾ Profesora Titular, ⁽²⁾ Jefe de Trabajos Prácticos; ⁽³⁾ Ayudante Diplomado

*CIC, Buenos Aires, Argentina. ** CONICET, Argentina.

Abstract

In previous studies have been reported a controversy between the reactivity of mono and polyclonal antibodies in different cells populations of the mouse. In this study we focus on the immunoreactivity of the monoclonal antibody VEGF (C-1) in order to analyze its expression in two cell populations of regenerating mouse liver (hepatocytes and endothelial cells) after partial hepatectomy, and two transplanted hepatocarcinomas (ES2 and SS1K). C3H/S male mice were divided into two groups and kept under standard conditions for circadian periodicity analysis, one group were transplanted with the tumors into the subcutaneous tissue of the animal flank and the other group were subjected to a partial hepatectomy (70 %). The animals were killed by decapitation and exsanguination. Samples of regeneration liver, ES2 and SS1K tumors were processed for histology and immunostained with VEGF (C-1) mouse monoclonal IgG_{2a} antibody. The results showed strongly immunopositivity reaction for VEGF either in hepatocytes or endothelial cells of mouse regenerating liver. We also demonstrated positive immunoreaction in both malignant tumors ES2 and SS1K endothelial and parenchymal cells. We conclude that the use of VEGF (C-1) mouse monoclonal IgG_{2a} antibody can be applied successfully in experimental design leading to study processes involved in mice's angiogenesis.

Key words: mouse, regeneration liver, hepatocarcinoma, VEGF.

Introduction

Several growth factors have been described with angiogenic activity (Ferrara and Davis-Smyth, 1997; Plate et al., 1992) but vascular endothelial growth factor (VEGF) is the most potent and specific for both angiogenesis and vasculogenesis (Mustonen and Alitalo, 1995; Shibuya, 1995).

In regenerating liver, after partial hepatectomy, both hepatocytes and nonparenchymal cells express VEGF mRNA (Mochida et al., 1996), suggesting that VEGF plays a significant role in rat liver regeneration (Shimizu et al., 2001; Taniguchi et al., 2001). However, this situation has not been examined in detail in mouse.

In addition to the crucial role in physiological angiogenesis, VEGF is also a key player in pathological neovascularization (Veikkola and Alitalo, 1999).

The onset of angiogenesis is believed to be an early event in tumorigenesis and may facilitate tumor progression and metastasis (Folkman et al., 1989). It has been speculated that VEGF may function as a tumor angiogenesis factor in vivo because the expression pattern of VEGF is consistent with a role in embryonic angiogenesis (Breier et al., 1992).

On the other hand, some authors have studied the reactivity of a broad panel of antibodies directed to human antigens, looking for cross-reactivity with mouse epitopes (Martín and Badrán, 1998). As a result, they found a group of mono and polyclonal antibodies reacting to different cells of the mouse, and others that did not (Martín et al., 2001).

Bearing in mind these results we used the monoclonal antibody VEGF (C-1) in order to study its expression in two cell populations of regenerating mouse liver (hepatocytes and endothelial cells), and two transplanted, fast growing undifferentiated hepatocarcinomas (ES2 and SS1K).

Material and Methods

Animals C3H/S male mice kept under standard conditions for circadian-periodicity analysis, caged singly with food and water ad libitum, were used. When they were 90 days old, they were divided in two groups. Tumors were transplanted into the subcutaneous tissue of each animal flank of one of the groups, while the mice of the other group were subjected to a partial hepatectomy (70 %) at 10:00 hours.

Tumor grafts For the grafting technique, small pieces of the tumor without necrotic changes were trimmed with scissors, suspended in saline (1, 2) and injected (0.2 ml) into the hosts. The whole procedure was carried out aseptically.

Tissue samples The animals were killed by decapitation and exsanguination. The hepatectomized mice were killed 26 hours post hepatectomy, and the tumor bearing ones, ES2 and SS1K tumors were removed promptly and fixed in 10 % buffered formalin for 24 h. All tissue samples were processed routinely and embedded in paraffin. Five-micrometer sections were cut, placed on positive-charge slides, and dried at 58°C overnight.

Immunohistochemistry

Sections were deparaffinized in xylene, rehydrated through graded alcohols and washed in Tris buffer saline (TBS) pH 7.4. After blocking endogenous peroxidase with 3% H₂O₂ for 15 minutes, heat-induced epitope retrieval (HIER) was used (Shi et al., 1991; Cattoretti et al., 1993). Briefly, slides were washed in TBS and placed in a microwavable plastic container filled with 250 ml of 0.01 M of citrate buffer pH 6 and irradiated in a household microwave oven, with a rotating carousel, at 750 W for 10 minutes (2 cycles of 5 minutes). Distilled water was used to refill the container after each cycle to maintain the buffer concentration.

After microwaving the slides were allowed to cool in the solution for 20 minutes (Battifora et al., 1995), then washed in TBS and incubated with primary antibody VEGF (C-1) mouse monoclonal IgG2a antibody (Santa Cruz Biotechnology, California, USA) at 1/40 dilution in a

humid chamber during 1 hour at room temperature. As detection system Envision (Dako, Carpinteria, California, USA) was used. The reaction was developed using 3'3-diaminobenzidine (Sigma) in TBS with 0.03 % H₂O₂. The sections were slightly counterstained with Mayer's Hematoxylin and mounted. Negative controls were run in parallel, omitting primary antibody.

Results

The results showed strongly immunopositivity reaction with intracytoplasmic localization for VEGF in hepatocytes (Figure 1) as well as in the sinusoid endothelial cells (Figure 2) of mouse regeneration liver.

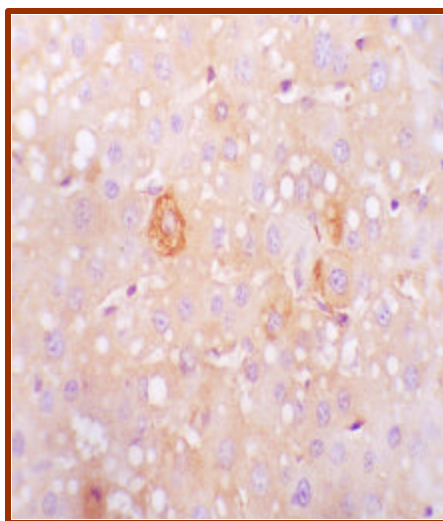


Figure 1: Hepatocytes of regenerating liver showing VEGF (C-1) reactivity (40X).

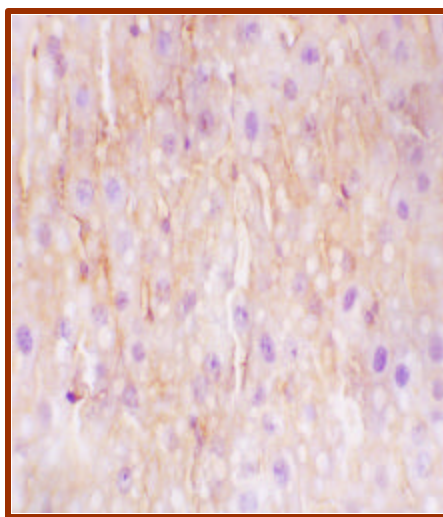


Figure 2: Endothelial cells of regenerating liver showing positive reaction to VEGF (C-1) (40X).

We also demonstrated positive immunoreaction in both malignant tumor ES2 (Figure 3) and SS1K (Figure 4). In both tumors we can see a positive reaction in parenchymal and endothelial cells.

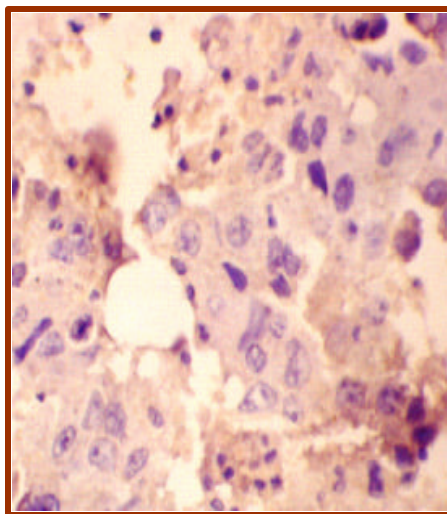


Figure 3: ES2 malignant tumor. Endothelial and parenchymal cells positive to VEGF (C-1) (40X).

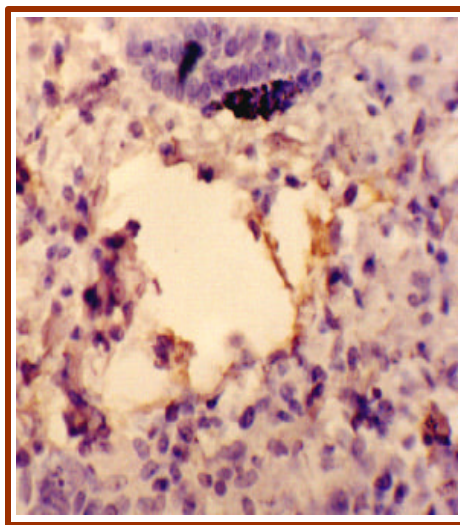


Figure 4: SS1K malignant tumor endothelial and parenchymal cells are positive (40X).

Discussion

Previous studies support the concept that VEGF mRNA is formed in some primary tumors, VEGF is produced by tumor cells lines in vitro (Breier et al., 1992) and that its mitogenic activity appears to be restricted to endothelial cells (Conn et al., 1990). Others authors demonstrated that

neoplastic cells are thought to be the main source of VEGF in tumors (Veikkola and Allitalo, 1991). Our findings supported the idea that in both transplanted mouse tumors, VEGF expressed itself either in endothelial cells or in the parenchymal ones.

On the other hand, there are many authors that using immunohistochemistry in different laboratory species found unreactivity of some of the antibodies tested. This would be explained by differences in the epitope structure among species as has been reported by Zeng et al. (1996). In their study of reactivity of antihuman macrophage antibodies in 10 different species, except in mouse, they found very variable results according to the animal tested.

As we want to study the behavior of VEGF in different tissues of the mouse, we used the VEGF (C1) which is a mouse monoclonal IgG2a antibody corresponding to aminoacids 1-140 of VEGF of human origin. We based the selection of this antibody on our intention to avoid the difficulties previously demonstrated by other authors (Zeng et al., 1996, Martín and Badrán, 1998) in the selection of the animal specie but with the uncertainty of obtained positive results or not, because until now the antibody has been used in rats, but not in mice. However, these positive results in C3HS mice may not be generalized to other mice strains because of possible intraspecies differences.

References

Battifora H, Alsabeh R, Jenkins KA (1995). Epitope retrieval (unmasking) in immunohistochemistry. *Adv Pathol Lab Med.* 8: 101-118.

Breier G, Albretch U, Sterrer S, Risau W (1992). Expression of vascular endothelial growth factor during embryonic angiogenesis and endothelial cell differentiation. *Development.* 114: 521-532.

Cattoretto G, Pileri S, Parravicini C, Becker MH, Poggi S, Bifulco C, Key G, D'Amato L, Sabattini E, Feudale E (1993). Antigen unmasking on formalin-fixed, paraffin-embedded tissue sections. *J Pathol.* 171: 83-98.

Conn G, Soderman DD, Schaeffer MT, Wile M, Hatcher VB, Thomas KA (1990). Purification of a glycoprotein vascular endothelial cell mitogen from errat glioma derived cell line. *Proc Natl Acad Sci. USA.* 87: 1323-1327.

Ferrara N, Davis-Smyth T (1997). The biology of vascular endothelial growth factor. *Endocrine Rev.* 18: 4-25.

Folkman J, Watson K, Ingber D, Hanadan D (1989). Induction of angiogenesis during the transition from hyperplasia to neoplasia. *Nature.* 339: 58-61.

Martín CA, Badrán AF (1998). Evaluation of antibody crossreactivity in mouse tissues: study of a panel of antibody reacting to human antigens. *Appl Immunohistochem.* 6: 84-88.

Martín CA, Salomoni PD, Badrán AF (2001). Cytokeratin immunoreactivity in mouse tissues: study of different antibodies with a new detection system. *Appl Immunohistochem.* 9: 71-73.

Mochida S, Ishikawa K, Inao M, Shibuya M, Fujiwara K (1996). Increased expressions of vascular endothelial growth factor and its receptors, flt-1 and KDR/flk-1, in regenerating rat liver. *Biochem Biophys Res Commun.* 226: 176-179.

Mustonen T, Alitalo K (1995). Endothelial receptor tyrosine kinases involve in angiogenesis. *J Cell Biol.* 129: 895-898.

Plate KH, Breier G, Weich HA, Risau W (1992). Vascular endothelial growth factor is a potential tumour angiogenesis factor in human gliomas in vivo. *Nature.* 359: 845-848.

Shi SR, Key ME, Kalra KL (1991). Antigen retrieval in formalin-fixed, paraffin-embedded tissues: an enhancement method for immunohistochemical staining based on microwave oven heating of tissue sections. *J Histochem Cytochem.* 39: 741-748.

Shibuya M (1995). Role of VEGF-flt receptor system in normal and tumor angiogenesis. *Adv. Cancer Res.* 67: 281-316.

Shimizu H., Miyazaki M., Wakabayashi Y., Mitsuhashi N., Kato A., Ito H., Nakagawa K., Yoshidome H., Kataoka M., Nakajima N. (2001). Vascular endothelial growth factor secreted by replicating hepatocytes induces sinusoidal endothelial cell proliferation during regeneration after partial hepatectomy in rats. *J Hepatol.* 34: 683 - 689.

Taniguchi E., Sakisaka S., Matsuo K., Tanikawa K., Sata M. (2001). Expression and role of vascular endothelial growth factor in liver regeneration after partial hepatectomy in rats. *J. Histochem and Cytochem.* 49: 121 - 129.

Veikkola T, Alitalo K (1999). VEGFs, receptors and angiogenesis. *Seminars in Cancer Biol.* 9: 211-220.

Zeng L, Takesha M, Ling X, Nagasaki A, Takahashi K (1996). Interspecies reactivities of antihuman macrophage monoclonal antibodies to various animal species. *J Histochem Cytochem.* 44: 845-853.