



ISSN: 0975-766X
CODEN: IJPTFI
Research Article

Available Online through
www.ijptonline.com

ENDOSCOPIC BILIARY STENTING FOR POST-CHOLECYSTECTOMY BILE LEAKS

Vladimir F. Kulikovsky, Alexander A. Karpachev, Alexander V. Soloshenko,
Andrei L. Yarosh*, Sergei B. Nikolaev, Yurii Y. Vlasuk, Boris V. Kasyanov, Angela V. Gnashko.

Belgorod State National Research University, 85, Pobedy Str., Belgorod, 308015, Russia.

Email: yarosh_a@icloud.com

Received on 08-06-2016

Accepted on 29-06-2016

Abstract.

This paper deals analyzes the treatment experience of 15 patients with bile leakage after laparoscopic cholecystectomy. All patients have undergone endoscopic transpapillary interventions in the bile ducts, including a retrograde cholangiography, papillotomy, biliary stenting, either individually or in combination with traditional surgery.

The authors have shown that the endoscopic transpapillary stenting of the bile ducts in patients with external and internal post-cholecystectomy bile leakage allows in most cases restoring the bile outflow into the duodenum lumen and avoiding the laparotomy.

Keywords: cholecystectomy, bile leaks, endoscopy interventions, biliary stenting

Introduction

The transpapillary biliary stenting today is the "gold" standard in the treatment of hepatopancreatobiliary diseases characterized by obstruction of the bile ducts (Dasari et al, 2013; Fan et al, 2011; Garcia-Cano et al, 2010; Liberato et al, 2012; Bakhru et al, 2011; Mitesh et al, 2013; Kwon et al, 2013; Tazuma et al, 2006). One of the important aspects of the clinical use of stents in the biliary surgery is the normalization of the internal bile outflow in the damaged bile ducts, accompanied by bile leakage. The analysis of foreign literature has identified a number of works devoted to this problem.

Biliary stents are used for different types of injuries of the bile duct: its longitudinal dissection, intersection or resection with further sewing of the prosthesis in the form of a patch or graft, upon application of a biliodigestive anastomosis and elimination of post-cholecystectomy bile leakage from the cystic duct (Nawaz et al, 2011; Krokidis et al, 2013; Machado, 2011).

However, despite the obvious advantages, the question of applying the retrograde endobiliary stenting for injuries of the bile duct as the main method of treatment remains controversial.

Materials and Methods

During the period of 2012-2015, total 15 patients with bile leakage after laparoscopic cholecystectomy were under our observation. Cholecystectomy was performed on the background of chronic calculous cholecystitis in 11 patients (73.3%), and acute calculous cholecystitis in 4 patients (26.7%).

Table 1: Nosological distribution of patients.

Disease	Number of patients
Gallstone disease. Acute calculous cholecystitis.	4
Gallstone disease. Chronic calculous cholecystitis.	11
Complications	Number of patients
Peritonitis.	3
External biliary fistula in the drainage of the cystic duct	4
Subhepaticbiloma.	3
External biliary fistula.	5

All patients have undergone transpapillary endoscopic stenting as the main method of surgical correction of bile diversion. The stent was inserted proximal of the defect so that the bile could flow freely into the duodenum, bypassing the problem area. For this purpose, plastic stents Soehendra-Tannenbaum™ by Wilson-Cook® 8.5 - 11 Fr were used. To prevent their early dysfunction due to obstruction with the bile duct content, as well as to prevent purulent-septic complications, their surface was modified with the original nano-sized diamond-like carbon coating with silver nanoclusters (patent RF No. 84226, patent No. 29397).

Results and Discussion

In all cases, the injury of ductal system was diagnosed in a period of 1 to 7 days after cholecystectomy. Bile discharge through the drainage from the subhepatic space was observed in 6 (33.3%) patients, limited fluid accumulation in subhepatic space (biloma) - in 3 (20%) patients, and bile peritonitis - in 3 (46.7%) patients.

Four patients were admitted to the hospital with the bile outflow through the drainage from the subhepatic space. The daily volume of bile ranged from 250 to 1200 ml. In one case, an injury of right lobe duct was diagnosed, which required its isolated stenting (Figure 1).

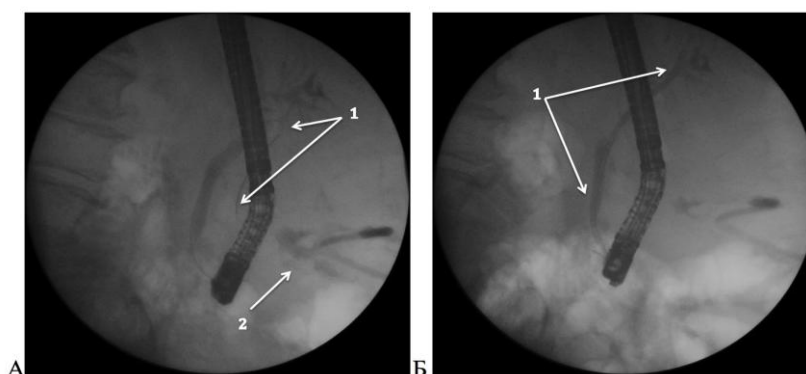


Figure 1. Cholangiography. Injury of the right lobe duct. A - conductor penetration (1) into a free peritoneal cavity through a duct defect. Accumulation of contrast medium (2). B - Selective stenting of the right lobe duct. The arrow shows the biliary stent with the original coating

One patient was diagnosed with bile leakage post laparoscopic cholecystectomy and giant liver cyst fenestration. In this case, the endoscopic retrograde cholangiography revealed the inflow of contrast medium into the subhepatic space from the left lobe duct, which required its selective stenting, as in the previous case.

Four patients were diagnosed with bile peritonitis. The 44-year-old patient was diagnosed with peritonitis on the 7th day after laparoscopic cholecystectomy, choledocholithotomy with the closure of the common bile duct defect with machine stitch. The latter was the source of bile leakage in the postoperative period. The development of bile peritonitis in three patients is associated with damage of the cystic duct caused by electrocoagulator and its subsequent failure. All patients had endobiliary stenting, laparoscopic debridement and drainage of the abdominal cavity performed (Krokidis et al, 2013; Machado, 2011).

Three patients in different post-cholecystectomy periods were diagnosed with subhepatic biloma. The percutaneous puncture under ultrasound control, followed by X-ray examination revealed the penetration of contrast into the bile ducts. Injury of the right lobe duct was diagnosed in one case. After the retrograde endobiliary stenting all patients underwent puncture drainage of fluid accumulations under ultrasound control (Machado, 2011).

Conclusion. Transpapillary stenting has significant advantages over other surgical interventions for post-cholecystectomy bile leakage, and allows in most cases restoring the bile outflow into the duodenum lumen and avoiding the laparotomy.

References

1. Bakhru, M.R., M. Kahaleh, 2011. Expandable metal stents for benign biliary disease. *Gastrointestinal endoscopy clinics of North America*, 21(3):447-62, viii.
2. Bhalala, M., K. Rude, A. Wang, B. Sauer, G.E. White, M. Kahaleh and V.M. Shami, 2013. Analysis of complications after EUS-FNA in patients with obstructive jaundice and drained with plastic biliary stents or self-expandable metal stent (SEMS): do complications differ between the type of stent? *J Interv Gastroenterol.*, 3(4): 128–132.
3. Dasari, B.V, C.J Tan, K.S Gurusamy, D.J Martin, G. Kirk, L. McKie, T. Diamond, M.A. Taylor., 2013. Surgical versus endoscopic treatment of bile duct stones. *Cochrane Database Syst Rev.*, 2013 3(9):CD003327.

4. Fan, Z., R. Hawes, X. Zhang, X. Zhang, W. Lv, 2011. Analysis of plastic stents in the treatment large common bile duct stones in 45 patients. *Digestive endoscopy*, 23 (1):86-90.
5. Garcia-Cano, J., L. Taberna-Arana, C. Jimeno-Ayllón, R. Martínez-Fernández, L. Serrano-Sánchez, A.K. Reyes-Guevara, M. Viñuelas-Chicano, C.J. Gómez-Ruiz, M.J. Morillas-Ariño, J.I. Pérez-García, G. Pérez-Vigara, A. Pérez-Sola, 2010. Use of fully covered self-expanding metal stents for the management of benign biliary conditions. *Revista española de enfermedades digestivas: organooficial de la Sociedad Española de Patología Digestiva*, 102(9):526-532.
6. Kwon, C.I, K.H. Ko, K.B. Hahm, D.H. Kang, 2013. Functional Self-Expandable Metal Stents in Biliary Obstruction. *ClinEndosc.*, 46(5):515-521.
7. Krokidis, M, G. Orgera, M. Rossi, M. Matteoli and A. Hatzidakis, 2013. Interventional radiology in the management of benign biliary stenoses, biliary leaks and fistulas: a pictorial review. *Insights Imaging*, 4(1): 77–84.
8. Liberato, M. J., J.M. Canena, 2012. Endoscopic stenting for hilar cholangiocarcinoma: efficacy of unilateral and bilateral placement of plastic and metal stents in a retrospective review of 480 patients. *BMC gastroenterology*, 9(12):103.
9. Machado, N. O., 2011. Biliary Complications Post Laparoscopic Cholecystectomy: Mechanism, Preventive Measures, and Approach to Management: A Review. *Diagnostic and Therapeutic Endoscopy*. Volume 2011, Article ID 967017, 9 pages. <http://dx.doi.org/10.1155/2011/967017>
10. Nawaz, H., G.I. Papachristou, 2011. Endoscopic treatment for post-cholecystectomy bile leaks: update and recent advances. *Ann Gastroenterol.*, 24(3): 161–163.
11. Tazuma, S., 2006. Gallstone disease: Epidemiology, pathogenesis, and classification of biliary stones (common bile duct and intrahepatic). *Best Pract Res ClinGastroenterol.*, 20(6):1075-83.

Corresponding Author:

AndreiL. Yarosh*,

Email: yarosh_a@icloud.com