

Melanoma brain metastases presenting as delirium: a case report

SOFIA MORAIS^{1,2}, ANA CABRAL^{1,2}, GRAÇA SANTOS¹, NUNO MADEIRA^{1,2}

¹Department of Psychiatry, Coimbra Hospital and University Centre (CHUC), Coimbra, Portugal.

²Faculty of Medicine, University of Coimbra (FMUC), Coimbra, Portugal.

Received: 12/14/2016 – Accepted: 12/19/2016

DOI: 10.1590/0101-6083000000118

Abstract

Background: Metastatic tumours sometimes present with neuropsychiatric symptoms, however psychiatric symptoms as rarely the first clinical manifestation. Cutaneous melanoma is the third most common cause of brain metastasis, with known risk factors increasing the chance of such central nervous system metastization. **Objectives:** We present a clinical report of delirium as the first clinical manifestation of melanoma brain metastases, illustrating the relevance of an adequate and early differential diagnosis. **Methods:** In addition to describing the clinical case, searches were undertaken in PubMed and other databases using keywords such as “brain metastasis”, “melanoma”, “agitation”, “psychiatric” and “delirium”. **Results:** We here report the case of a 52-year-old female patient evaluated by Liaison Psychiatry after sudden onset of delirium while admitted at the Gastroenterology Department to study a hypothesis of pancreatitis. A head CT scan identified brain metastases, and after further examination, including brain biopsy, melanoma brain metastization was confirmed. **Discussion:** Some of the diagnostic challenges of psychiatric symptoms associated with secondary brain tumours are discussed, underlining the importance of an adequate differential diagnosis when working in Psychiatry Liaison.

Morais S et al. / *Arch Clin Psychiatry*. 2017;44(2):53-4

Keywords: Brain neoplasms secondary, melanoma secondary, delirium.

Dear Editor,

We report a clinical case of sudden onset of delirium, with psychomotor agitation and behavioural changes, in addition to reported depressive symptoms of subacute onset, as the initial manifestation of melanoma brain metastasis in the right posterior frontal lobe.

Our Psychiatry Liaison Unit was requested to attend a female patient, 52-year-old, that was admitted from the Emergency Department with nausea, vomiting and headache, initiated 2 days before. She had no psychiatry history other than depressive symptoms, about 9 months long, apparently reactive to work conflicts, medicated with paroxetine 20 mg id. Medical history included the excision of an ulcerated malignant melanoma in the right thigh 4 years before, in apparent remission, and hysterectomy for uterine fibroid. Her neurological exam was unremarkable. Blood analysis showed hepatic cholestasis and abdominal ultrasound showed a pancreatic mass; she was hospitalized at the Gastroenterology Department with a hypothetic pancreatitis.

After three days she initiated during the night psychomotor agitation and disinhibited behaviour, motivating Psychiatry Liaison consultation. When interviewed next morning, she was still restless and fidgeting in the sheets, with spatiotemporal disorientation, speaking quickly with a somehow incoherent speech, keeping her eyes closed and stating: “Doctor I have flatulence, but you know me and this is funny..”

An urgent head computerized tomography (CT) scan was performed evidencing an expansive lesion within the right posterior frontal lobe, heterogeneous and hyperdense, conditioning mass effect on adjacent structures. She started oral haloperidol 5 mg id and performed a head magnetic resonance imaging (MRI) (Figure 1).

Later, a chest/abdomen/pelvis CT scan and a whole-body Positron Emission Tomography (PET) scan identified multi-organic metastatic disease affecting the lungs, pancreas and peritoneum. The patient was also medicated with oral dexamethasone and transferred to the Neurosurgery Department. She underwent surgical removal of part of the brain lesion, with a biopsy consistent with melanoma brain metastases.

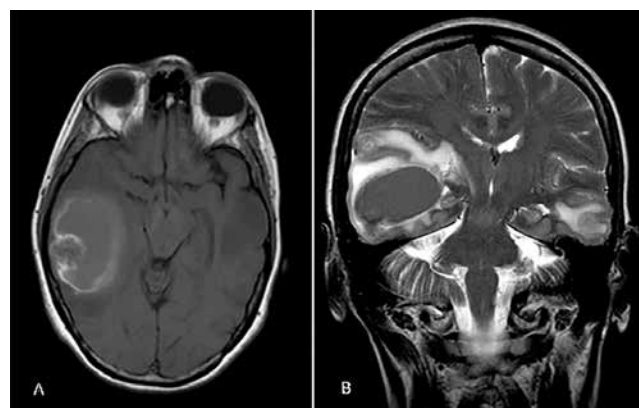


Figure 1. Brain MRI. (A) Axial T1-weighted image showing a cortico-subcortical tumoral lesion at temporal lobe with predominant moderate hyperintensity and an irregular halo of higher signal. The spontaneous high signal on T1 is probably due to both a hemorrhagic component and the melanocytic content. (B) Coronal T2-weighted image showing the lesion described in (A) and additional two smaller cortico-subcortical masses located at right posterior frontal lobe and at left inferior temporal gyrus. All the lesions had low signal on T2, particularly the inferior solid component of the major tumoral mass, which is also compatible with a melanocytic content. Another milimetric lesion was found at left precuneus (not shown). The hypointensity on T2-weighted image (B) may also be associated at lung or gastrointestinal adenocarcinoma metastasis, however with the (A) axial T1-weighted image the hyperintense signal is typical of melanoma melanocytic.

Cutaneous melanoma is the third most common cause of brain metastasis, reflecting its distinctive neurotropism¹. Central nervous system (CNS) metastasis occur in 10 to 40% of melanoma patients in clinical studies and up to 90% in autopsy studies². Nonetheless, to our knowledge, this is the first report in the literature of delirium as a presenting syndrome of melanoma brain metastases.

Factors that have been shown to increase the risk for development of CNS metastasis in melanoma patients included male sex, thickness or ulceration of the skin lesion, primary site in the head and neck, mucosal or acral lentiginous tumors and nodular primary lesions³. Metastatic tumors often present with more neuropsychiatric symptoms⁴. Most brain tumors present with specific neurologic signs due to mass effect, and 78% of patients with brain tumors had psychiatric symptoms, but only 18% presented only with these symptoms as the first clinical manifestation of a brain tumor⁵. Depression was found in 44% of all brain tumor patients, primary and metastatic⁶.

We report a rare case associating delirium with the early presentation of brain metastization of melanoma. Clinical suspicion is critical when working in Psychiatry Liaison, and an adequate differential diagnosis is key to the early treatment of potentially fatal CNS conditions.

References

1. Barnholtz-Sloan JS, Sloan AE, Davis FG, Vignea FD, Lai P, Sawaya RE. Incidence proportions of brain metastases in patients diagnosed (1973 to 2001) in the Metropolitan Detroit Cancer Surveillance System. *J Clin Oncol.* 2004;22(14):2865-72.
2. Chiarion-Sileni V, Murr R, Pigozzo J, Sarti S, Tomassi O, Romani A. Brain metastases from malignant melanoma. *Forum (Genova).* 2003;13(2):170-82; quiz 190.
3. Zakrzewski J, Geraghty LN, Rose AE, Christos PJ, Mazumdar M, Polsky D, et al. Clinical variables and primary tumor characteristics predictive of the development of melanoma brain metastases and post-brain metastases survival. *Cancer.* 2011;117(8):1711-20.
4. Madhusoodanan S, Ting MB, Farah T, Ugur U. Psychiatric aspects of brain tumors: A review. *World J Psychiatry.* 2015;5(3):273-85.
5. Keschner M, Bender MB, Strauss I. Mental symptoms associated with brain tumor: a study of 530 verified cases. *JAMA.* 1938;110(10):714-8.
6. Rooney AG, Carson A, Grant R. Depression in cerebral glioma patients: a systematic review of observational studies. *J Natl Cancer Inst.* 2011;103(1):61-76.