



THE UNIVERSITY *of* EDINBURGH

Edinburgh Research Explorer

Catheter-associated venous air embolism in hospitalized horses: 32 cases

Citation for published version:

Parkinson, N, McKenzie, H, Barton, M, Davis, J, Dunkel, B, Johnson, A & MacDonald, E 2018, 'Catheter-associated venous air embolism in hospitalized horses: 32 cases' *Journal of Veterinary Internal Medicine*. DOI: 10.1111/jvim.15057

Digital Object Identifier (DOI):

[10.1111/jvim.15057](https://doi.org/10.1111/jvim.15057)

Link:

[Link to publication record in Edinburgh Research Explorer](#)

Document Version:

Publisher's PDF, also known as Version of record

Published In:

Journal of Veterinary Internal Medicine

Publisher Rights Statement:

This is an open access article under the terms of the Creative Commons Attribution-NonCommercial License, which permits use, distribution and reproduction in any medium, provided the original work is properly cited and is not used for commercial purposes.

General rights

Copyright for the publications made accessible via the Edinburgh Research Explorer is retained by the author(s) and / or other copyright owners and it is a condition of accessing these publications that users recognise and abide by the legal requirements associated with these rights.

Take down policy

The University of Edinburgh has made every reasonable effort to ensure that Edinburgh Research Explorer content complies with UK legislation. If you believe that the public display of this file breaches copyright please contact openaccess@ed.ac.uk providing details, and we will remove access to the work immediately and investigate your claim.



Catheter-associated venous air embolism in hospitalized horses: 32 cases

Nicholas J. Parkinson^{1,2}  | Harold C. McKenzie¹ | Michelle H. Barton³ |

Jennifer L. Davis¹  | Bettina Dunkel⁴ | Amy L. Johnson⁵  |

Elizabeth S. MacDonald⁶

¹Virginia Maryland College of Veterinary Medicine, Blacksburg, Virginia

²Royal (Dick) School of Veterinary Studies, University of Edinburgh, Easter Bush Campus, Midlothian, United Kingdom

³University of Georgia College of Veterinary Medicine, Athens, Georgia

⁴The Royal Veterinary College, Hawkshead Lane, Hatfield, Hertfordshire, United Kingdom

⁵New Bolton Center, University of Pennsylvania School of Veterinary Medicine, Kennett Square, Pennsylvania

⁶Marion duPont Scott Equine Medical Center, Virginia Maryland College of Veterinary Medicine, Leesburg, Virginia

Correspondence

Nicholas J. Parkinson. Royal (Dick) School of Veterinary Studies, University of Edinburgh, Easter Bush Campus, Midlothian, EH25 9RG, United Kingdom. Email: nick.parkinson@ed.ac.uk

Background: Venous air embolism is a potentially life-threatening complication of IV catheter use in horses. Despite widespread anecdotal reports of their occurrence, few cases have been reported in the literature and the prognosis is currently unknown.

Hypothesis/Objectives: Our objective was to describe the surrounding circumstances, clinical signs, treatment, progression, and outcome of venous air embolism in hospitalized horses.

Animals: Thirty-two horses with acute onset of compatible clinical signs associated with IV catheter disconnection or damage.

Methods: Multicenter retrospective study. Data extracted from clinical records included signalment, presenting complaint, catheter details, clinical signs, treatments, and outcome.

Results: Most cases resulted from extension set disconnection occurring within approximately 24 hours after catheter placement. In fewer horses, extension set damage was cited as a cause. Common clinical signs included tachycardia, tachypnea, recumbency, muscle fasciculations and agitation, with abnormal behavior including kicking and flank biting. Less commonly, pathological arrhythmias or more severe neurologic signs, including blindness and seizures, were noted. Progression was unpredictable, with some affected horses developing delayed-onset neurologic signs. Mortality was 6/32 (19%), including 2 cases of sudden death and other horses euthanized because of persistent neurologic deficits. Negative outcomes were more common in horses with recorded blindness, sweating or recumbency, but blindness resolved in 5/8 affected horses.

Conclusions and Clinical Importance: The prognosis for resolution of clinical signs after air embolism is fair, but permanent neurologic deficits or pathologic cardiac arrhythmias can arise. Unpredictable progression warrants close monitoring. Systematic clinic-based surveillance could provide additional useful information to aid prevention.

*Where the work described in this manuscript was performed: Virginia Maryland College of Veterinary Medicine, Blacksburg, VA, USA; North Carolina State University College of Veterinary Medicine, Raleigh, NC, USA; University of Georgia College of Veterinary Medicine, Athens, GA, USA; The Royal Veterinary College, Hawkshead Lane, Hatfield, Hertfordshire, United Kingdom; New Bolton Center Hospital for Large Animals, University of Pennsylvania, School of Veterinary Medicine, Kennett Square, PA, USA; Marion duPont Scott Equine Medical Center, Virginia Maryland College of Veterinary Medicine, Leesburg, VA, USA; Royal (Dick) School of Veterinary Studies, University of Edinburgh, Easter Bush Campus, Midlothian, United Kingdom.

†A 250-word abstract describing the work in this report was presented at the British Equine Veterinary Association Annual Congress, 15th September 2017. The work has not otherwise been reported elsewhere.

This is an open access article under the terms of the Creative Commons Attribution-NonCommercial License, which permits use, distribution and reproduction in any medium, provided the original work is properly cited and is not used for commercial purposes.

© 2018 The Authors. Journal of Veterinary Internal Medicine published by Wiley Periodicals, Inc. on behalf of the American College of Veterinary Internal Medicine.

KEYWORDS

arrhythmia, central blindness, cerebral infarct, embolism, horse

1 | INTRODUCTION

Venous air embolism is an uncommon but potentially fatal complication of IV catheter use. The pathophysiological consequences of an air embolus can result from blood flow obstruction in the right side of the heart and pulmonary circulation, or from passage of the embolus into the systemic circulation. This latter scenario can lead to ischemia in other organs, such as the central nervous system or myocardium.¹⁻³

In humans, the condition is encountered with manipulation, exchange, or accidental disconnection of central venous catheters.^{4,5} Vascular air embolism also can result from surgery, particularly obstetric procedures⁶ and procedures of the cranium performed in the sitting position, because of the favorable pressure gradients produced.^{1,7}

To date, only 7 cases of suspected air embolism associated with catheter disconnection have been reported in horses, 2 of which occurred during or immediately after general anesthesia.⁸⁻¹² One further suspected case was reported during urinary tract endoscopy.¹³ The horses in these reports displayed a variety of clinical signs including agitation, apparent pruritus, muscle fasciculations, tachycardia, tachypnea, pulmonary edema, and neurologic signs including blindness, vestibular dysfunction, and seizures. All horses survived, but 1 had persistent unilateral blindness. However, anecdotal evidence suggests that the problem is much more widespread than the literature suggests, and can on occasion be fatal. Currently, little information is available on which to base a management plan or prognosis when this unfortunate complication is encountered.

The aim of our retrospective study was to describe the surrounding circumstances, clinical signs, progression and outcome of venous air embolism in hospitalized horses, to facilitate prevention, case management, and prognostication of future cases. A secondary aim was to provide some preliminary data as to whether outcome differed between horses with different clinical presentations.

2 | MATERIALS AND METHODS

Catheter-associated venous air embolism was defined as sudden death or acute onset of clinical signs, not readily explainable by another cause, that were temporally associated with catheter disconnection or another catheter-related event resulting in air aspiration. Medical records from 3 referral institutions were searched systematically for references to air embolism or catheter disconnection, and data were extracted from cases meeting the above definition. Additional cases were identified by personal communication with diplomates of the American College of Veterinary Internal Medicine from 4 other referral hospitals. Data extracted from medical records included details of signalment, presenting complaint, catheter details, circumstances surrounding the disconnection event, clinical signs, treatments, and outcome. A negative outcome was defined as non-survival or

persistence of clinically relevant physical or functional abnormalities (attributed to the embolism) for the duration of follow-up. Medical record search capabilities or formal adverse event recording permitted identification of incidents of catheter disconnection without clinical sequelae at 2 clinics only. Statistical analysis was performed using commercial and open-source software (SPSS Statistics, Version 22, IBM Corp., Armonk, NY and OpenEpi Version 3.01, A.G. Dean and K.M. Sullivan, Atlanta, GA). Descriptive statistics were used to summarize clinical data. Differences in proportion of negative outcomes between groups of cases, with or without specific recorded clinical signs or pre-incident factors, were evaluated using a 2-sided Fisher's exact test with mid-P correction, with conditional maximum likelihood estimation of the odds ratios. Insufficient cases were available for multivariable modeling. A Mann-Whitney *U* test was used to compare times because catheter placement for catheter disconnections versus extension set damage. Significance was set at $P < .05$.

3 | RESULTS

3.1 | Animals

Thirty-two cases met the inclusion criteria dating from 2003 to 2017. All were adult horses. Details of signalment and presenting complaint are given in the Supporting Information.

3.2 | Incidence of clinical sequelae after catheter disconnection

In formal adverse event records in 1 hospital, 25 disconnection events were recorded from 931 catheter placements over 3.5 years (2.7% of catheter placements), constituting 25% of recorded catheter-associated complications. Of these, 1 had immediate onset of clinical signs attributed to air embolism (4% of disconnections; 0.1% of catheter placements), whereas 2 additional horses had delayed onset of colic signs only, potentially attributable to the primary condition, for which air embolism was a differential diagnosis. These were not included in the present case series. In a 2nd hospital, 41 disconnection events were identified from free-text search of clinical records, from 6,016 catheter placements over 9 years (0.7% of catheter placements), of which 13 horses displayed clinical signs (32% of disconnections; 0.2% of catheter placements).

3.3 | Catheter characteristics and circumstances surrounding disconnection events

All catheters involved were placed in the jugular vein and directed toward the heart. Fourteen of 32 (44%) were placed on the left side, 10 (31%) on the right, and in 8 cases the side was not recorded. For the 28 cases in which catheter details were available, 3 (11%) were 12-

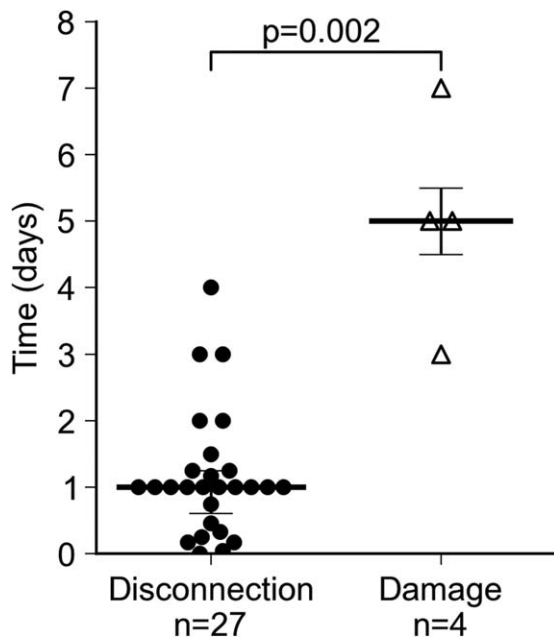


FIGURE 1 Differences in timing of catheter disconnection and extension set damage, in relation to catheter placement. Data were available for 31 horses; 1 case has been excluded in which disconnection occurred outside hospital. Where exact timings were not recorded, the maximum potential time interval (on the basis of the medical records) has been used. The horizontal line and error bars represent median time and interquartile range, respectively, for each event category

gauge whereas the remainder (89%) were 14-gauge catheters. All were over-the-needle 5.25-inch catheters. Both short and long extension sets, and injection caps alone, were involved, although full details seldom were recorded. The catheter had been placed by a qualified veterinarian in 7 of the 9 cases for which this information was available. In 28/32 cases (88%), the horse was in the stall at the time of the incident; other cases occurred during hand-walking or small pen turnout, in the induction stall before anesthesia, or before referral. No cases were identified associated with recovery from anesthesia or after removal of a catheter. Horses had been connected to fluids at the time of the incident in 18/32 cases (56%).

The cause of air aspiration was disconnection of the extension set or injection cap from the hub of the catheter in the majority of cases (26/32, 81%). In 2 cases, the site of disconnection was between the fluid line and extension set, and in 4 cases air entry occurred as a result of damage to the extension set, fluid line, or 3-way stopcock. In at least 4 cases, the horse had been observed rubbing its neck before or shortly after the incident. Disconnection events occurred at a median of 24 hours (range, <10 minutes to 4 days) after catheter placement, whereas extension set damage occurred significantly later (median, 5 days after placement; range, 3–7 days; $P = .0020$; Figure 1).

3.4 | Clinical signs

Sudden death was reported in 2 cases, with subsequent discovery of a disconnected catheter. Incidence of reported clinical signs in the other 30

cases is given in Table 1. The most commonly reported clinical signs included tachypnea (32–70 breaths per minute where recorded), tachycardia (60–120 beats per minute), muscle fasciculations, transient recumbency, apparent colic, and agitation. Initial signs were observed concurrently with or within minutes of detection of catheter disconnection in all but 1 case (which developed seizures after 2 hours), but varying delays in onset of individual clinical signs occurred in some horses (see Table 1).

Acute behavioral changes included variable degrees of excitement, ranging from mild hyper-reactivity to erratic behavior, compulsive circling, flank biting, and kicking. A small number of horses exhibited lethargy or obtundation rather than excitement. In most cases, these signs resolved within hours, but in 2 horses behavioral changes persisted for > 4 months (up to the time of euthanasia). These 2 horses became difficult to handle and displayed intermittent agitation and unpredictable behavior such as running through fences. Besides behavioral change, 12/30 horses showed specific neurologic signs in the acute phase, including seizures, apparent central blindness, and head tilt. Suspected generalized seizures occurred immediately after the initial insult in 3 horses: in 2 cases this was a single event, whereas the 3rd horse developed recurrent focal seizures. In the other 4 horses affected by seizures, only focal seizures were observed. Focal seizure signs were predominantly right-sided in 1 horse with concurrent right-sided blindness; seizure lateralization was not recorded in other horses. Blindness, as assessed by absent menace response with an intact pupillary light reflex, was unilateral in 5 cases (all right-sided, 4 of which had left-sided catheters), bilateral in 3 cases, and suspected on the basis of behavior but not fully characterized in 1 additional case. Delayed onset of blindness (4 hours to 4 days) was common, and onset was asynchronous between eyes in at least 1 bilateral case. Absence of the menace response was intermittent in 2 eyes, and in 1 case blindness was a transient post-ictal event. Head tilt was right-sided in 2 cases and left-sided in a 3rd, and in individual cases was accompanied by intermittent nystagmus, ptosis and ear droop, ipsilateral facial paresis, and delayed loss of response to auditory stimuli.

Further clinical signs reported in isolated cases included pale mucous membranes with cold extremities, transient pigmenturia, bruxism, hyperesthesia, pruritus, head pressing, decreased facial sensation, and delayed-onset dysphagia. A heart murmur (not fully described in the clinical record but considered consistent with intracardiac gas) was noted in a single case.

In 12/32 cases (38%), the course of disease consisted of a single episode of clinical signs resolving within 6 hours. Other horses showed more sustained clinical signs (12/32; 38%), and in many an initial clinical improvement was followed by recrudescence or appearance of delayed onset of clinical signs (13/32; 41%). In 1 extreme case, pharyngeal dysphagia of presumed neurological origin developed 2 weeks after the initial insult but resolved in a further 3 weeks, whereas in a 2nd case blindness and head tilt developed after 4 days, followed by ataxia and lack of response to auditory stimuli after 10 days.

3.5 | Diagnostic tests

In the majority of cases, no specific diagnostic tests were performed. In a single case, an air bubble was observed in the right atrium by

TABLE 1 Common clinical signs observed in 30 cases of catheter-associated venous air embolism

Clinical sign	No. of cases recorded		Onset (number of cases, where recorded):			Biphasic/ intermittent	Resolved	Median (range) time to resolution
	Immediate	Delay ≤2 hours	Delay >2 hours	Delay ≤2 hours	Delay >2 hours			
Tachypnea	24/30 (80%)	15	2	0	0	2	22/24 (92%)	2 hours (<30 minutes–>14 days) ^a
Tachycardia	23/30 (77%)	14	4	1 (12–24 hours)	0	5	20/23 (87%)	2 hours (<30 minutes–>14 days) ^a
Muscle fasciculations	19/30 (63%)	12	3	2 (2–12 hours)	0	5	19/19 (100%)	2 hours (<15 minutes–8 days)
Recumbency	17/30 (57%)	14	1	0	0	0	17/17 (100%)	< 30 minutes (<5 minutes–2 hours)
Agitation	17/30 (57%)	8	4	2 (4–24 hours)	0	5	15/16 (94%)	2.5 hours (<30 minutes–5 days)
Circling/stall walking	13/30 (43%)	4	4	3 (3 hours–4 days)	0	3	11/13 (85%)	1 hour (30 minutes–5 days)
Ataxia	12/30 (40%)	8	2	2 (24 hours–10 days)	0	2	10/12 (83%)	9 hours (<30 minutes–2 weeks)
Colic ^b	12/30 (40%)	8	1	1 (24 hours)	0	0	12/12 (100%)	30–60 minutes (<15 minutes–5 days)
Kicking	10/30 (33%)	4	6	0	0	1	10/10 (100%)	3 hours (<30 minutes to 5 hours)
Blindness/absent menace response	8/30 (27%) ^c	2 (2 eyes)	0	7 (9 eyes; 4 hours–4 days)	0	2 (2 eyes)	5/8 (63%); 6/11 eyes (55%)	7 days (<30 minutes–2 months)
Biting at flank/hindlimb	7/30 (23%)	2	4	1 (12 hours)	0	0	7/7 (100%)	1.5 hours (<30 minutes–4 hours)
Seizure(s)	7/30 (23%)	4	0	3 (3–8 hours)	0	4	6/7 (86%)	Single: 3 horses Recurrent: 3 horses (6 hours–2 days)
Sweating	7/30 (23%)	3	0	0	0	2	7/7 (100%)	Not recorded in most cases
Pathologic arrhythmia ^d	5/30 (17%)	2	0	2 (12–36 hours)	0	1	4/5 (80%)	24 hours (<30 minutes–3 days)
Lethargy	5/30 (17%)	2	0	2 (≤24 hours)	0	2	4/5 (80%)	3 days (12 hours–5 days)
Head tilt (+/– nystagmus or facial paresis)	3/30 (10%)	2	0	1 (4 days)	0	1	1/3 (33%)	4 weeks

Two cases of sudden death have been omitted. Time to 1st observation of clinical signs from detection of catheter disconnection, and duration of signs from 1st observation, were estimated from clinical records. Sufficient data were not available in every case.

^aPersistence of moderate tachypnea or tachycardia caused by primary disease could not always be distinguished from that associated with air embolism.

^bColic signs with onset before the air embolism have been excluded.

^cA further case of blindness was suspected on the basis of behavior but not confirmed.

^dOnly electrocardiographically confirmed pathologic arrhythmias have been included.

ultrasonography 2 hours after the catheter had been recapped. In the other cases, a presumptive diagnosis was made based on clinical signs and surrounding circumstances.

Arterial blood gas analysis was performed in 3 cases and showed moderate hypoxemia (partial pressure of oxygen, 72 mm Hg) in 1 horse with pre-existing respiratory disease, mild respiratory alkalosis in a 2nd case and no abnormalities in the 3rd. Blood lactate concentration was increased (>2 mmol/L) in 4/8 cases. Electrocardiography was performed in 9 horses with persistent tachycardia or arrhythmia. In 3 horses, no abnormalities were detected except for sinus tachycardia or sinus arrhythmia. Pathological arrhythmias in 5 horses included ventricular tachycardia (3 horses, including unifocal or multifocal, sustained or intermittent arrhythmia), atrial fibrillation, or transient narrow complex tachycardia with atrioventricular dissociation, whereas a 6th horse had sinus tachycardia with ST segment elevation. Echocardiography performed within 48 hours of the initial insult was normal in 3 horses, whereas a 4th horse had decreased left ventricular internal diameter and increased left ventricular wall thickness suggestive of hypovolemia, and mild pericardial effusion. Cardiac troponin I concentration was markedly increased in 2 horses: an initial concentration of 10.28 ng/mL (reference range, <0.06 ng/mL) was recorded in the horse that developed persistent atrial fibrillation, decreasing to 0.5 ng/mL within 3 weeks, and a horse with suspected pokeweed toxicosis that developed ventricular tachycardia after the air embolism had a measured cardiac troponin I concentration of 3.58 ng/mL.

Cerebrospinal fluid cytology was normal in 2 horses with neurologic deficits (1 of which was sampled after euthanasia). Magnetic resonance imaging (MRI) of the head was performed 17 months after the insult in 1 horse with persistent seizures, progressive ataxia, and chronic behavioral change; right-sided blindness in this horse had resolved within 8 days of the initial insult. A wedge-shaped lesion was evident in the left occipital cortex, crossing into the medial aspect of the right occipital lobe, involving both gray and white matter, with associated hydrocephalus ex vacuo. The lesion showed T1 hypointensity and moderate T2 hyperintensity indicating the presence of fluid (Figure 2).

3.6 | Treatment

A wide range of treatment combinations was used. Three horses received no specific treatment, beyond removing or reconnecting the IV catheter. The most common treatments included non-steroidal anti-inflammatory drugs, sedatives, dexamethasone, dimethyl sulfoxide, and oxygen insufflation. Further treatment details are given in the Supporting Information. Because of the wide range of treatment combinations and non-random allocation, statistical analysis of associations between treatment and outcome was not possible.

3.7 | Outcome

Overall mortality was 6/31 cases (19%), including 2 instances of sudden death, 2 horses euthanized in hospital, and 2 that survived to discharge (after 17–20 days) but were later euthanized as a consequence of continuation of signs attributed to the air embolism, 4 to 17 months after the incident. The reason for euthanasia was in most cases persistent or progressive neurologic disease including behavior change, seizures, ataxia or blindness, although 1 horse was euthanized as a result of acute early clinical signs in combination with age and the presenting complaint. One further case was considered to have a poor outcome because of persistence of atrial fibrillation, whereas in a 2nd horse blindness persisted to discharge, 3 days after onset, but the horse was lost to follow-up; this horse was excluded from statistical analysis of outcomes. Complete resolution of clinical signs attributed to the air embolism was documented in 24/32 cases (75%), at a median of approximately 6 hours after detection, with 10/32 (31%) cases resolving within 2 hours. Time to resolution of neurologic deficits was highly variable (see Table 1), and in 3 horses blindness or head tilt only resolved after discharge from hospital, 7 days to 2 months after onset. Follow-up after resolution of clinical signs was recorded in 12 cases (median, 2.5 months after onset); no recurrence was reported in any case. The proportion of negative outcomes was higher in cases with recorded blindness, sweating or recumbency (Table 2), but no differences in outcome between groups could be demonstrated based on any

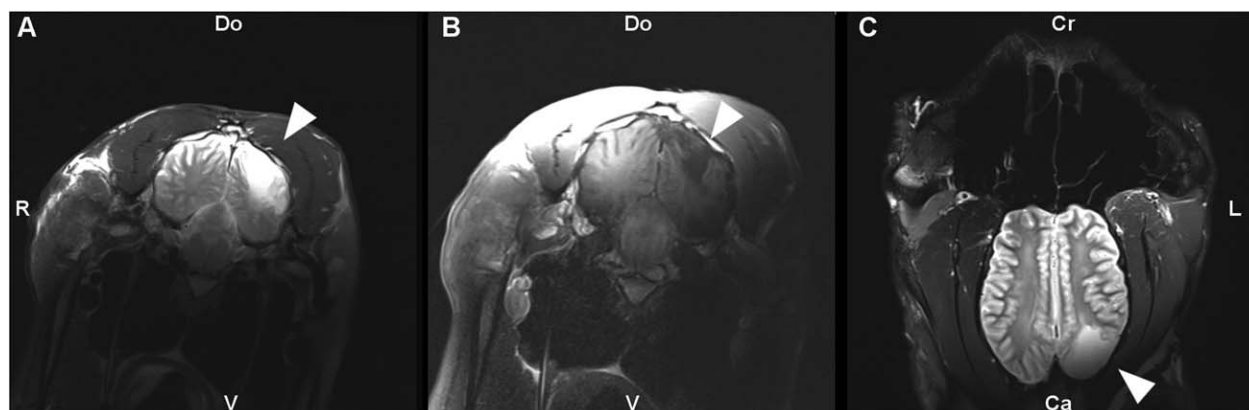

FIGURE 2 MRI images of a brain infarct attributed to a catheter-associated air embolism. A, T2-weighted image in the transverse plane at the level of the tympanic bulla. B, T1-weighted transverse image just cranial to (A). C, T2-weighted image in the dorsal plane at the level of the frontal sinuses. The lesion predominantly affects the left occipital lobe, but extension across the midline is evident. Abbreviations: R, right; L, left; do, dorsal; V, ventral; cr, cranial; ca, caudal

TABLE 2 Outcome in 29 horses with or without particular recorded clinical signs

Clinical sign	Negative outcome		Odds ratio (95% CI)	P value
	Clinical sign recorded	Not recorded		
Tachypnea	4/23 (17%)	1/6 (17%)	1.1 (0.10–31)	.99
Tachycardia	5/22 (23%)	0/7 (0%)	N/A ^a	.22
Muscle fasciculations	4/19 (21%)	1/10 (10%)	2.3 (0.25–66)	.52
Recumbency	5/16 (31%)	0/13 (0%)	N/A ^a	.037
Agitation	4/17 (24%)	1/12 (8%)	3.3 (0.35–91)	.34
Circling/box walking	2/12 (17%)	3/17 (18%)	0.94 (0.10–7.4)	.96
Ataxia	3/11 (27%)	2/18 (11%)	2.9 (0.36–28)	.32
Colic	1/12 (8%)	4/17 (24%)	0.31 (0.01–2.9)	.34
Kicking	2/10 (20%)	3/19 (16%)	1.3 (0.13–11)	.78
Biting at flank/hindlimb	0/7 (0%)	5/22 (23%)	N/A ^a	.22
Blindness/absent menace response	4/7 (57%)	1/22 (5%)	23 (2.2–718)	.0068
Seizure	2/6 (33%)	3/23 (13%)	3.2 (0.30–29)	.31
Cardiac arrhythmia	1/5 (20%)	4/24 (17%)	1.2 (0.04–14)	.84
Lethargy	2/5 (40%)	3/24 (13%)	4.9 (0.44–50)	.18
Sweating	4/7 (57%)	1/22 (5%)	23 (2.2–718)	.0068
Head tilt (+/– nystagmus or facial paresis)	2/3 (67%)	3/26 (12%)	13 (0.80–468)	.071

The conditional maximum likelihood estimate of the odds ratio given is for negative outcome in cases for which the clinical sign was recorded, compared to those in which it was not. One horse with persistent blindness has been excluded from the analysis because of insufficient follow-up (3 days). All P-values that appear in bold are <0.05.

^aOdds ratio was not calculable because of absence of negative outcomes in 1 category. CI: confidence interval.

other patient- or catheter-related variable assessed (Supporting Information Table 1).

3.8 | Post mortem findings

Necropsy results were available in 4 non-survivors. The cause of death was not definitively established in either case of sudden death. Pulmonary edema was identified in 1, and congestion and hemorrhage of the laryngeal and tracheal mucosa and submucosa in the other horse, although these were suspected to be agonal changes. Additional findings included subepicardial petechial hemorrhage, and congestion of the brain parenchyma and leptomeninges with rare evidence of leptomeningeal hemorrhage. Air in the heart or great vessels was not identified in either horse. Two horses were examined after euthanasia for progressive neurologic disease, 1 in the acute stages (3 days post-injury) and 1 in the chronic stage (17 months). Both had areas of cerebrocortical malacia consistent with infarction or hypoxic insult. In the acute case, in which the horse had exhibited intermittent blindness, apparent vestibular signs and progressive behavior change, lesions were multifocal and centered on the most dorsal gyri and sulci bilaterally, adjacent to the falx cerebri. In the chronic case, described above and in Figure 2, a focal, well-demarcated lesion was present in the gray and white matter of the left occipital lobe. This corresponded to the region supplied by the left caudal cerebral artery, and was consistent with the appearance on MRI. Microscopic lesions in both cases

included neuronal cytoplasmic eosinophilia and nuclear pyknosis or karyolysis. Intercellular edema and endothelial hypertrophy were evident in the acute case, whereas marked rarefaction of gray and white matter, increased numbers of gemistocytic astrocytes and mild perivascular accumulations of pigment-laden macrophages were noted in the chronic case. Inflammation was not a feature of either case.

4 | DISCUSSION

Air embolism associated with catheter disconnection is an ever-present risk when indwelling IV catheters are used in horses. Definitive diagnosis can be challenging. In this case series, intracardiac gas was confirmed ultrasonographically in 1 horse only. The diagnosis was therefore founded on a number of complementary clinical factors. First, all horses had an open portal for air entry. Second, the temporal association was strong, with clinical signs developing within minutes of detection of the catheter problem in almost all cases. Third, the clinical signs observed were consistent with those seen in experimental air embolism in horses, in which “acceleration of the heart and respiration, shivering, movements of the head and neck, tonic spasms of the limbs, paralysis and sometimes death” are described.¹⁴ The spectrum of signs, including focal neurologic signs, also is consistent with clinical reports in humans.^{4,15} Finally, few plausible differential diagnoses could be identified to explain the full spectrum of clinical signs in any case, and the probability of other rare conditions occurring coincidentally with

catheter disconnection was deemed exceedingly low. The diagnosis could thus be made with high confidence in most cases, the possible exceptions being the 2 cases of sudden death. In these, air embolism was strongly suspected but it is also possible that catheter disconnection occurred during agonal events. Necropsy findings could not confirm or refute the diagnosis. Ideally, the heart and great vessels should be opened underwater in suspect cases to facilitate detection of air bubbles, but air in other locations such as brain or more distal pulmonary vessels may be difficult to detect, and any delay in performing the necropsy may result in reabsorption of air or gas production from autolysis.

The diagnosis may not always be so straightforward in clinical practice, for example, when non-specific signs such as colic occur in isolation or after a longer time delay, or when the concurrent disease or drug administration could plausibly result in similar clinical signs. Associating particular clinical signs with air embolism in individual cases also can be problematic, especially if these signs are common and non-specific (eg, tachycardia), atypical, or delayed in onset. It is thus possible that some of the clinical signs reported here were coincidental. Demonstrating air in the circulation, although difficult after the acute stages, could be useful for diagnostic confirmation in less clear-cut cases. In particular, MRI or computed tomography, considered the diagnostic tests of choice for cerebral air embolism in humans, could be useful early in the course of neurologic manifestations.

The majority of cases in this series arose from accidental disconnection between the catheter hub and the extension set or injection cap while the horse was resting in a stall. Unlike in humans,⁴ catheter manipulations or removal do not seem to be major inciting events in horses, although events after removal may be more difficult to identify from medical records. Catheter disconnections could arise from operator error (eg, insufficient tightening of the screw attachment between catheter and extension set), poor compatibility between specific extension set and catheter models, patient-induced damage to the connection, or from progressive cyclical loosening caused by neck movement. At least 4 animals were seen rubbing their necks before or after the incident, and multiple disconnection incidents were recorded in at least 2 others, suggesting that the problem could have been self-inflicted. The difference in timing between events involving disconnection and those involving damage (Figure 1) indicates that the 2 have different risk factors, and suggests that operator error or extension set incompatibility are more important than cyclical loosening. Preventive strategies employed by individual hospitals have included checking of all catheters by a clinician immediately after placement, tightening the joint at every routine check, changing catheter or extension set type after a perceived increase in disconnection incidence, or using additional sutures or tissue glue to help secure the extension set. Ultimately, awareness of the potential problem on the part of all staff involved in catheter placement and maintenance is essential to aid prevention. Systematic adverse event records could play a critical role in facilitating wider recognition within an institution. Notably, in the 1 clinic investigated here, these records identified many cases without clinical sequelae, that were not otherwise recorded in the medical

records. Systematic recording also may identify local factors associated with changes in incidence.

The development of an air embolism depends on the presence of an open vessel and establishment of a suitable pressure gradient. With a jugular catheter placed toward the heart in a standing horse, as with every case reported here, such a pressure gradient is readily established by the weight of the blood column. Conversely, with catheters directed toward the head, the resulting pressure gradient will predispose to bleeding rather than air aspiration. Upward-directed jugular catheters are not however considered suitable for fluid administration and are rarely used. The volume of air required to cause clinical signs is not well established, and depends on the speed of aspiration, but a 1934 study found that rapid jugular injection of 500 mL air was rapidly fatal in a horse, whereas 100 mL caused no clinical signs.¹⁴ This volume could easily be aspirated via the large bore catheters typically used in equine medicine. In 1 study, it was calculated that a 14-gauge needle with a 5 cm H₂O pressure gradient could aspirate 100 mL air per second.¹⁶ Wider bore catheters logically would be expected to entail greater risk, but there was insufficient evidence to support catheter bore as a risk factor in the present case series. Fourteen-gauge catheters are by far the most commonly used in adult horses, and although 1 of the cases presented here with a 12-gauge catheter died, the other 2 had only short-lived clinical signs. It is notable that only a minority of disconnection events resulted in clinical signs of air embolism, which suggests that in many cases air aspiration is either self-limiting or restricted to a lower, tolerable rate. Head position, catheter kinking, or clotting all could restrict air entry. It is however unclear whether air aspiration has truly been avoided in such cases, or whether they constitute a spectrum of subclinical disease. Small volumes of air could cause tissue injury that may not result in immediate overt clinical signs, but could have long-term consequences. Although examples of return to athletic use after severe insult were seen in this study, we do not have sufficient data to assess more subtle impact on long-term health or performance.

The consequences of air embolism depend in part on the destination of the embolus after it enters the circulation. A large embolus could cause right ventricular outflow obstruction,² with associated signs of pulmonary and systemic hypoperfusion, and this could have caused sudden death or the transient recumbency observed as the 1st clinical sign in many cases. In contrast to previously reported cases, a murmur compatible with intracardiac gas was only detected in 1 horse. It is more likely that smaller air bubbles will pass through the right ventricle to the pulmonary circulation. In humans, this causes arterial hypoxemia largely because of ventilation-perfusion mismatching,³ often associated with chest pain. Experimental models indicate that air also causes microvascular injury, leading to pulmonary edema.¹⁷⁻¹⁹ A similar clinical syndrome has been reported in previous equine cases,¹⁰⁻¹² and although arterial blood gases were rarely investigated in the cases in this report, pulmonary involvement is 1 possible explanation for the tachycardia and tachypnea commonly observed. Thoracic pain could also plausibly give rise to the signs of agitation and distress which were frequently a prominent feature, including violent kicking and flank-biting behavior sometimes interpreted as colic or pruritus.

Central nervous system stimulation is another possible explanation of both the behavioral signs and the tachycardia and tachypnea. Cerebral involvement was undoubtedly present in at least a subset of cases, characterized by central blindness and seizures. Passage of air to the systemic arterial circulation, to reach the brain, could occur by overwhelming the filtration capacity of the pulmonary capillary bed, by passing through an intracardiac right-to-left shunt (unlikely in horses), or by retrograde flow up the jugular veins. The former 2 mechanisms, collectively termed "paradoxical" embolism, also could lead to coronary involvement, which could explain the arrhythmias and evidence of myocardial injury observed in some cases.^{5,20} Paradoxical embolism is thought to be the primary mechanism underlying cerebral air embolism in humans, although individual cases have been attributed to retrograde flow.^{4,15,21,22} The mechanism in horses has not been established. An experimental model in dogs found that the pulmonary vasculature could completely remove air bubbles up to a rate of 0.3 mL/kg/min.²³ If pulmonary filtration capacity is similar in horses, it could be exceeded by rates of air entry observed with commonly used large bore catheters. The lesion distribution at necropsy in 2 of the horses reported here was suggestive of arterial occlusion. The difference in lesion distribution between species also suggests an arterial route. Left-sided cerebral lesions, as indicated by right-sided central blindness, predominate in horses. Including 2 cases from previous reports,^{10,11} 6/10 reported cases have been blind on the right side only, including cases with both left- and right-sided catheters, and the rest have been bilateral. This finding contrasts with reports in humans of a predisposition to right-sided lesions.⁴ This observation could relate to differences in the anatomy of aortic branching. In humans, the 1st major branch is the brachiocephalic artery, which leads to the right common carotid and subclavian arteries, whereas in the horse, the left subclavian artery (from which the vertebral artery and thus the predominant cerebral circulation originates) branches 1st from a common brachiocephalic trunk.

The rare sporadic nature of this condition renders evaluation of treatment efficacy in a clinical setting problematic. The low incidence of adverse outcomes, variability of treatment protocols and non-random treatment allocation precluded such analysis in this case series, and indeed even in humans, systematic reviews have not been able to draw any conclusions in this regard.^{4,22} Elucidation of the pathophysiology may however help identify rational therapeutic strategies. Experimental evidence suggests that the mechanisms of neuronal injury could involve both hypoxic-ischemic injury and inflammation secondary to endothelial damage, leading to brain swelling, glucose depletion, and increased anaerobic metabolism.^{4,24–26} Histopathology of 2 cases in this series was consistent with an ischemic lesion, with no evidence of inflammation, although acute inflammation could have resolved before euthanasia. Anti-inflammatory treatments (including glucocorticoids) were widely used in affected horses. The use of glucocorticoids in horses with neurologic disease is controversial, and although their membrane-stabilizing effects theoretically could be beneficial, they have been shown to increase mortality after acute stroke in humans.^{27,28} Their use thus should be approached with caution in the absence of evidence of an inflammatory lesion, although limited conclusions can be drawn from the small number of horses with available

histopathology. Hyperbaric oxygen therapy has been described as a useful treatment in humans, with possible beneficial actions including compression of air bubbles to decrease their size, encouragement of bubble dissolution, and enhancing oxygenation of ischemic tissue. This approach was not used in any of the horses in this report, but as facilities are available in a number of equine hospitals, it is worthy of consideration as a treatment option.²⁹

Aggressive treatment was not necessary for full recovery in many transiently affected horses without specific neurologic signs. Identification of animals requiring more intensive treatment is complicated by the unpredictable progression of the disease. There was often a time delay between the embolism and development of neurologic signs, of up to 4 days for loss of menace response and longer in individual horses developing dysphagia or hearing loss. Initial clinical signs could not differentiate these horses from those with transient uncomplicated disease. Cardiac effects also can have delayed onset, in some cases occurring 12–36 hours after the initial event. Many cases showed a 2-phase clinical syndrome, with early improvement of clinical signs after cessation of air aspiration followed by later development of more severe signs of anxiety. Thus, monitoring affected horses in the hospital for 2 to 4 days would be a wise precaution, and owners should be advised of the possibility of delayed complications.

Notwithstanding the likely inherent bias toward overrepresentation of more severe cases in this dataset, the overall prognosis in this case series was fair to good for both survival to discharge and for complete resolution of clinical signs. For horses found alive, the prognosis was excellent for those that did not develop neurologic sequelae, but guarded for horses developing blindness, with permanent behavior change or neurologic deficits often leading to euthanasia. Our study had very low power to detect effects of patient or catheter-related factors in survival, and low case numbers precluded multivariable modeling, and so it is likely that differences in outcomes exist between subgroups of cases, that could not be detected here. The proportion of positive outcomes appeared higher for horses that did not sweat or become recumbent, despite the rapid resolution of these signs in most cases, but the clinical relevance of this finding is uncertain. It could reflect a less severe initial insult in horses not exhibiting these signs, or it could be an artifact of more complete recording in non-survivors. The poorer outcomes after blindness likely reflect both severity of the cerebral injury and the influence of this factor in prompting a decision for euthanasia. It is notable that although blindness resolved in 5/8 horses, this did not necessarily lead to a positive outcome, because other signs such as behavioral change or pathologic cardiac arrhythmia could still persist. Full recovery did however occur in some horses with severe neurologic signs. This observation is consistent with previous reports in horses, in which blindness was reported in 2/7 horses and was permanent in 1 (1/3 affected eyes), with the other case resolving within 6 weeks. Attempts at treating horses with neurologic manifestations are therefore justified.

Our findings were limited by the usual constraints of retrospective data collection. Because clinical data were not recorded in a systematic fashion, there were many gaps in the dataset, and the documented prevalence of individual clinical signs is likely to be an underestimate.

Submission and recollection biases are likely to have resulted in over-representation of more severe cases. In addition, variable record keeping and search capabilities of medical record systems hindered systematic identification of both clinical cases and catheter disconnections without clinical sequelae. Estimates of incidence and probability of clinical sequelae were consequently limited to 2 institutions, and cannot necessarily be extrapolated to the wider hospital population. Although a prospective multicenter study would overcome these problems and would be desirable to investigate treatment efficacy, the sample size needed for such a study is unlikely to be achievable given the rarity of the problem and the low incidence of adverse long-term outcomes. The most efficient way to collect more reliable data about this problem thus may be via wider adoption of systematic adverse event monitoring and recording protocols. Prevention of catheter disconnections must be a primary goal of any catheter maintenance protocol, and good surveillance data will provide invaluable assistance in formulating such a strategy.

ACKNOWLEDGMENTS

The authors acknowledge the assistance of Penny Archer, (Marion duPont Scott Equine Medical Center, Virginia Maryland College of Veterinary Medicine, Leesburg, VA, USA) with data retrieval. This work was not supported by any external funding.

CONFLICT OF INTEREST DECLARATION

Authors declare no conflict of interest.

OFF-LABEL ANTIMICROBIAL DECLARATION

Authors declare no off-label use of antimicrobials.

INSTITUTIONAL ANIMAL CARE AND USE COMMITTEE (IACUC) OR OTHER APPROVAL DECLARATION

Authors declare no IACUC or other approval was needed.

ORCID

Nicholas J. Parkinson  <http://orcid.org/0000-0001-6336-5654>

Jennifer L. Davis  <http://orcid.org/0000-0002-7930-4589>

Amy L. Johnson  <http://orcid.org/0000-0003-2507-0040>

REFERENCES

- [1] Gordy S, Rowell S. Vascular air embolism. *Int J Crit Illness Injury Sci.* 2013;3:73–76.
- [2] Taylor PM. Suspected venous air embolism. *Equine Vet Educ.* 2009; 21:89–90.
- [3] Souders JE. Pulmonary air embolism. *J Clin Monit Comput.* 2000;16: 375–383.
- [4] Pinho J, Amorim JM, Araujo JM, et al. Cerebral gas embolism associated with central venous catheter: Systematic review. *J Neurol Sci.* 2016;362:160–164.
- [5] Wosko J, Dabrowski W, Zadora P, et al. Coronary air embolism during removal of a central venous catheter. *Anaesthesiol Intens Therapy.* 2012;44:21–24.
- [6] Mushkat Y, Luxman D, Nachum Z, et al. Gas embolism complicating obstetric or gynecologic procedures. Case reports and review of the literature. *Eur J Obstet Gynecol Reprod Biol.* 1995;63: 97–103.
- [7] Albin MS, Carroll RG, Maroon JC. Clinical considerations concerning detection of venous air embolism. *Neurosurgery.* 1978;3: 380–384.
- [8] Bradbury LA, Archer DC, Dugdale AHA, et al. Suspected venous air embolism in a horse. *Vet Rec.* 2005;156:109–111.
- [9] Caporelli F, McGowan CM, Tulamo RM. Suspected venous air embolism in a Finnhorse. *Equine Vet Educ.* 2009;21:85–88.
- [10] Holbrook TC, Dechant JE, Crowson CL. Suspected air embolism associated with post-anesthetic pulmonary edema and neurologic sequelae in a horse. *Vet Anaesth Analg.* 2007;34:217–222.
- [11] Pellegrini-Masini A, Rodriguez Hurtado I, Stewart AJ, et al. Suspected venous air embolism in three horses. *Equine Vet Educ.* 2009; 21:79–84.
- [12] Sacks M, Mosing M. Volumetric capnography to diagnose venous air embolism in an anaesthetised horse. *Vet Anaesth Analg.* 2017;44: 189–190.
- [13] Romagnoli N, Rinnovati R, Lukacs RM, et al. Suspected venous air embolism during urinary tract endoscopy in a standing horse. *Equine Vet Educ.* 2014;26:134–137.
- [14] Lapolla L. Pathogenesis of air embolism. *Clin Vet.* 1934;57:593–606.
- [15] Yesilaras M, Atilla OD, Aksay E, et al. Retrograde cerebral air embolism. *Am J Emerg Med.* 2014;32:1562.e1–1562.e1562.
- [16] Flanagan JP, Gradisar IA, Gross RJ, et al. Air embolus—a lethal complication of subclavian venipuncture. *N Engl J Med.* 1969;281: 488–489.
- [17] Albertine KH, Wiener-Kronish JP, Koike K, et al. Quantification of damage by air emboli to lung microvessels in anesthetized sheep. *J Appl Physiol.* 1984;57:1360–1368.
- [18] Ohkuda K, Nakahara K, Binder A, et al. Venous air emboli in sheep: reversible increase in lung microvascular permeability. *J Appl Physiol.* 1981;51:887–894.
- [19] Wang D, Li MH, Hsu K, et al. Air embolism-induced lung injury in isolated rat lungs. *J Appl Physiol.* 1992;72:1235–1242.
- [20] Nims M, Hallonquist H, Camann W. Coronary arterial air embolus occurring during cesarean delivery. *Int J Obstet Anesth.* 2006;15: 166–169.
- [21] Raposo N, Faiz F, Albucher JF, et al. Embolie gazeuse cérébrale iatrogène d'origine veineuse sans signe respiratoire: un mécanisme rétrograde? *Revue Neurologique.* 2011;167:615–618.
- [22] Cheng CK, Chang TY, Liu CH, et al. Presence of gyriform air predicts unfavorable outcome in venous catheter-related cerebral air embolism. *J Stroke Cerebrovasc Dis.* 2015;24:2189–2195.
- [23] Butler BD, Hills BA. Transpulmonary passage of venous air emboli. *J Appl Physiol.* 1985;59:543–547.
- [24] Warren BA, Philp RB, Inwood MJ. The ultrastructural morphology of air embolism: platelet adhesion to the interface and endothelial damage. *Br J Exp Pathol.* 1973;54:163–172.
- [25] Mitchell S, Gorman D. The pathophysiology of cerebral arterial gas embolism. *J Extra Corpor Technol.* 2002;34:18–23.
- [26] van Hulst RA, Lameris TW, Hasan D, et al. Effects of cerebral air embolism on brain metabolism in pigs. *Acta Neurol Scand.* 2003; 108:118–124.
- [27] Zuliani G, Cherubini A, Atti AR, et al. Prescription of anti-oedema agents and short-term mortality in older patients with acute ischaemic stroke. *Drugs Aging.* 2004;21:273–278.

- [28] Sundboll J, Horvath-Puho E, Schmidt M, et al. Preadmission use of glucocorticoids and 30-day mortality after stroke. *Stroke*. 2016;47:829–835.
- [29] Murphy BP, Harford FJ, Cramer FS. Cerebral air embolism resulting from invasive medical procedures. Treatment with hyperbaric oxygen. *Ann Surg*. 1985;201:242–245.

SUPPORTING INFORMATION

Additional Supporting Information may be found online in the supporting information tab for this article.

Table 1. Outcomes in 31 horses grouped by catheter- or patient-related factors.

How to cite this article: Parkinson NJ, McKenzie HC, Barton MH, et al. Catheter-associated venous air embolism in hospitalized horses: 32 cases. *J Vet Intern Med*. 2018;00:1–10. <https://doi.org/10.1111/jvim.15057>