

# Intralipotherapy, the State of the Art

Roberto Amore, MD\*

Hernán Pinto, MD†

Kostas Gritzalas, MD‡

Carlota Hernández, MD§

Katarzyna Skwara-Guzikowska,

MD, PhD¶

Domenico Amuso, MD\*

Vincenza Leonardi, MD\*

**Background:** Reconstruction intralipotherapy is a term commonly used in the field of aesthetic medicine, above all in Europe, which defines a specific injection technique developed for the treatment of localized fat with substances that provoke the lysis of adipocytes by means of an injection directly into the adipose tissue with a long needle.

The aim of this study is to define the technique in detail and everything that is associated with it, on the basis of years of multicenter experience by doctors who perform it.

**Materials and Methods:** From January 2010 to December 2014, 3,080 European physicians were trained in intralipotherapy technique, and approximately 152,500 patients were treated. The adipocytolytic agent used is a Conformité Européenne-certified device. The technique, equipment, protocol, posology, postoperative management, and adverse events are described below.

**Results:** The intralipotherapy technique combined with the appropriate adipocytolytic agent has been shown to be effective in every zone on the average of 76.7% of the cases. The variability is due to the area treated and the patient. The standardization of the technique, homogeneity of the protocol, and the posttreatment management have been essential for standardizing the results and minimizing any adverse events. The latter occurred only in a small percentage of the cases, while those more serious have been extremely rare.

**Conclusion:** This study shows how the intralipotherapeutic technique, when performed properly with an appropriate adipocytolytic device and when proper precautions are taken, can be effective and safe for reducing undesirable subcutaneous fat deposits.

(*Plast Reconstr Surg Glob Open* 2016;4:e1085; doi: 10.1097/GOX.0000000000001085; Published online 27 October 2016.)

In the world of possible nonsurgical therapies for the reduction of localized fat, intralipotherapy is now well established and in use for over 15 years: a widespread technique in the field of aesthetic medicine that involves the use of adipocytolytic substances (substances that lyse adipocytes) by direct injection into fatty tissue with a long needle. The availability of a broad range of preparations used to perform the technique, with nonstandardized dosages and nonstandardized protocols, has created widespread confusion and a myriad of results, which are often very different one from another.

The study aims to evaluate—based on the many years of multicenter experience of the authors—each aspect of the technique, namely, materials used, protocol, dosages, technique, postoperative management, and association with other methods.

## MATERIALS AND METHODS

### Population

From January 2010 to December 2015, the authors have conducted 187 intralipotherapy courses, qualifying 3,590 doctors who were trained to use an CE-registered device,<sup>1</sup> in the following countries: Italy, Spain, Portugal, England, Germany, Greece, Turkey, Poland, Slovenia, Croatia, Norway, Czech Republic, Russia, Serbia, and Middle East (UAE, Saudi Arabia, Kuwait, and Qatar). In these 6 years, the 3,590 physicians have used 808,000 vials to perform intralipotherapy treatments in different areas of the body in the way and according to the dosages described as follows in subjects suitable for the treatment aged between

From the \*University of Palermo, Palermo, Italy; †Instituto de Investigaciones para las Especialidades Estéticas y del Envejecimiento, Barcelona, Spain; ‡Al Najat Medical Center, Kuwait City, Kuwait; §Clínica Arts Médica, Valencia, Spain; and ¶Katowice School of Economics, Katowice, Poland.

Received for publication March 30, 2016; accepted August 23, 2016.

Copyright © 2016 The Authors. Published by Wolters Kluwer Health, Inc. on behalf of The American Society of Plastic Surgeons. All rights reserved. This is an open-access article distributed under the terms of the Creative Commons Attribution-Non Commercial-No Derivatives License 4.0 (CCBY-NC-ND), where it is permissible to download and share the work provided it is properly cited. The work cannot be changed in any way or used commercially without permission from the journal.

DOI: 10.1097/GOX.0000000000001085

**Disclosure:** All authors, except Vincenza Leonardi, are external medical advisors for distributors of Aqualyx and trainers for intralipotherapy. The Article Processing Charge was paid for by the authors.

18 and 65 years old. The authors and their colleagues (total 37 doctors) treated 1,832 patients (Table 1).

**Adipocytolytic Agent**

The adipocytolytic agent used was a Class III CE-marked medical device (approved in 2009) for the reduction of localized fat in combination with ultrasound therapy: Aqualyx (Marllor International, San Giovanni in Marignano, Italy) is a mix of biocompatible detergents with a short half-life and biodegradable materials (sodium salt of 3 $\alpha$ ,12 $\alpha$ -dihydroxy-5 $\beta$ -chol-6-en-24-oic acid 0.7%), slow release, immersed in a sugar matrix (polymer of 3: 6-anhydro-L-galactose and D-galactose), and a buffer system.<sup>1,2</sup>

**Patient Selection**

The patients presented with various forms and degrees of localized fat in the following areas: double chin, jowl, buffalo hump, pseudogynecomastia, back rolls, flanks, arm, abdomen, saddlebag thighs, inner thighs, and inner knee. They did not present with any exclusion criteria for the treatment: psychological (indecisive or immature personalities, anxiety, dismorphophobia, with fictitious disorders, or family members disapproving the treatment),<sup>3,4</sup> minors, pregnancy, women who are lactating, obesity, severe allergic reactions or known allergies to the device, severe autoimmune diseases, acute infections in progress, immunosuppressive diseases with weakened immune systems, organ diseases uncompensated, or functional deficits (diabetes, kidney failure, liver disease, severe dyslipidemia, dysthyroidism, etc.). Before the treatment was performed, the patient underwent an objective examination; informed consent and photographic documentation were made. Physical examination provided important information such as follows:

- Location, extent, and thickness of the localized adiposity (essential parameters needed for calculating the quantity to be injected);
- Local contraindications for the treatment are acute skin diseases (wounds, acute dermatological lesions);
- Documenting the coexistence of additional blemishes such as irregularities, asymmetries, cellulite, vascular malformations, skin tightening, and stretch marks.

**Intralipotherapy**

The technique involves the following steps:

Marking the treatment area and access points (2–3 per area, opposing if possible) when the patient is in an orthostatic position (legs slightly apart, arms folded) and the calculation for the quantity of the device required (see dosage);

In each 8 mL vial, 0.2 mL of lidocaine 2% was added before starting the injections, as suggested by the manufacturer. If the intralipotherapy needle is used (23 gauge  $\times$  10 cm), it is not necessary to perform additional anesthesia (topical or local) in the area to be treated because the treatment is minimally painful and well tolerated. In the case where a cannula is used instead of a needle, it will be necessary to perform a minimum infiltration of a local anesthetic (0.5 mL of a local anesthetic common to 2% infiltrate in the dermis with a 30-gauge needle, creating a papule) at the site where the cannula will be introduced. This is due to the fact that to insert the cannula, you must first create an access point with an 18-gauge needle and this can be particularly painful if performed without local anesthesia; In a decubitus position, the best position according to the area to be treated, infiltration of the device is performed after first disinfecting the area to be treated (Fig. 1);

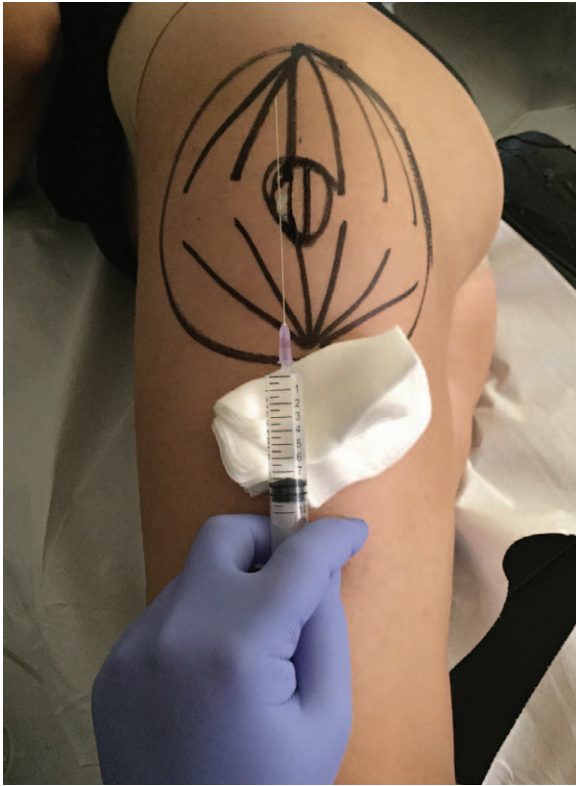From the access point that was marked, the needle is inserted into the subcutaneous fat parallel to the cutaneous surface, avoiding contact with the skin and muscle. The total amount of the device previously calculated to be used is distributed using a retrograde release with the intralipotherapy needle (a long, 23-gauge  $\times$  10 cm needle, very similar to the needles used for spinal anesthesia) and a fan technique, releasing 0.2–0.4 mL of product during each passage. The fan technique consists of an advancing and retracting movement of the needle, very similar to that used with liposuction (Fig. 2). It is a 3-step technique (Fig. 3):

Step 1: Introduction. *The long needle is completely inserted into the subcutaneous fat.* At this stage, the doctor must focus on where to direct the needle (direction and depth).

**Table 1. Data Related to the Treatment and Infusion-related Success Rates in Different Anatomical Areas**

Area Treated	Treatment per Area					Medical Evaluation (Percentage Satisfied) (%)	Patient Evaluation (Score, 6–10, Percentage Satisfied) (%)
	Vials Injected per Session	Percentage of the Treatments	Range of the Sessions Performed	Interval Between the Sessions (wk)			
Double chin/jowl	0.5–1.5	9.3	1–3	4–5		76.9	71.4
Buffalo hump	1–2	1.6	2–3	6		85.5	70.3
Pseudogynecomastia	2–4	2.2	2–4	4		74.3	62.9
Back rolls	2–4	6.5	2–4	6		77.3	68.6
Flanks	3–6	18.0	2–4	<b>6</b>		88.2*	72.4*
Arm	2–4	2.3	3–5	4		64.4	42.1
Abdomen	3–6	<b>19.1</b>	3–5	6		81.0	67.7
Saddlebag thighs	2–6	18.8	3–6	5–6		69.9	61.0
Inner thighs	2–4	12.1	3–5	4–5		63.1	51.3
Inner knee	1–2	10.1	2–4	7–8		68.7	63.3

\*Higher value.



**Fig. 1.** The image shows a patient placed in a lateral decubitus position for the treatment of saddlebag thighs. The area to be treated and access points had previously been marked when the patient was in an orthostatic position. For didactic purposes, the two opposing fans were drawn. Centrally, the area with a greater thickness of fatty tissue has been marked. The adipocytolytic agent in the syringe is injected directly into the adipose tissue with the needle using a retrograde release. The intralipotherapy technique with respect to mesotherapy allows a more even distribution of the adipocytolytic agent, a more accurate selection of the plane to be treated, the possibility to maneuver (either more superficially or deeper) reducing the risk of infiltrating the dermis and muscle.

Once he has decided where to place the needle, he penetrates the skin with an inclination of  $45^\circ$  at the previously established point (usually at the margin of the treatment area which was previously outlined), passes the dermis, and advances the needle toward the set point. The needle is inserted with a constant uniform movement without varying the direction of the needle during this phase. In the event that the doctor realizes that the needle was not positioned correctly (ie, too deep or too shallow), the needle should be retracted without releasing the solution until it is repositioned to the initial starting position (needle slightly inserted into the subcutaneous fat, without leaving the skin), and the first step is repeated. If the patient complains of sudden pain, it is a good indication that the needle is positioned incorrectly. The needle should not be palpable or visible and the skin should not be everted because it indicates the needle has engaged the dermis during the insertion.

- ☑ Choose the direction and depth.
- ☑ Advance the needle in a straightforward direction, without changing direction.

**Step 2: Retraction.** *After the needle is properly positioned, it is retracted.* When the needle is retracted, the dose of the therapeutic solution (0.2–0.4 mL) is released. At this stage, the doctor must focus only on the release of the solution, which must be uniform and in the correct amounts. The retraction is a passive movement, that is, the needle returns to its initial position and no special precautions must be taken.

- ☑ Retract the needle without thinking to the direction.
- ☑ It is preferable to release less solution than too much.
- ☑ Press the plunger of the syringe using a gentle and constant pressure, interrupting the flow of the device before arriving at the initial starting position (approximately 1 cm).

**Step 3: Change of Direction.** *Changing the direction from the initial starting position.* After the needle has been completely retracted, without removing it from the skin, change the direction by a few degrees and repeat step 1. At this stage, the doctor must focus only on the variation of the angle, taking into consideration the entire area to be covered with the fan technique (he must execute a sufficient number of steps to homogeneously distribute the solution, considering the greater thickness of the central area and reduced thickness of the peripheral areas). The central zone must be infiltrated several times, varying the depth. In the peripheral areas, a single superficial treatment is sufficient (respecting the basic rule: no palpable needle, the needle is not visible, the skin is not everted).

- ☑ Do not make excessive changes to the angulation (a few degrees are sufficient).
- ☑ It is important to assure that the needle changes direction and does not return in the same direction.

### Posology

Treatments were performed 4 to 7 weeks apart and until the clinical result was obtained.

### Dosage

It is necessary to distinguish the treatment of adiposity in the head and neck region from treatment in the rest of the body. In the first case, the calculation for the dosage must evaluate the extent of the subcutaneous fat, whereas in the second case, the extent and the thickness must be evaluated. The posological calculation that follows refers to the CE-registered device (1 vial contains 8 mL of the device).

In the head and neck region, a half vial is used for each  $25\text{ cm}^2$  (for example, a half vial for a double chin and a quarter vial per part in the mandibular border).

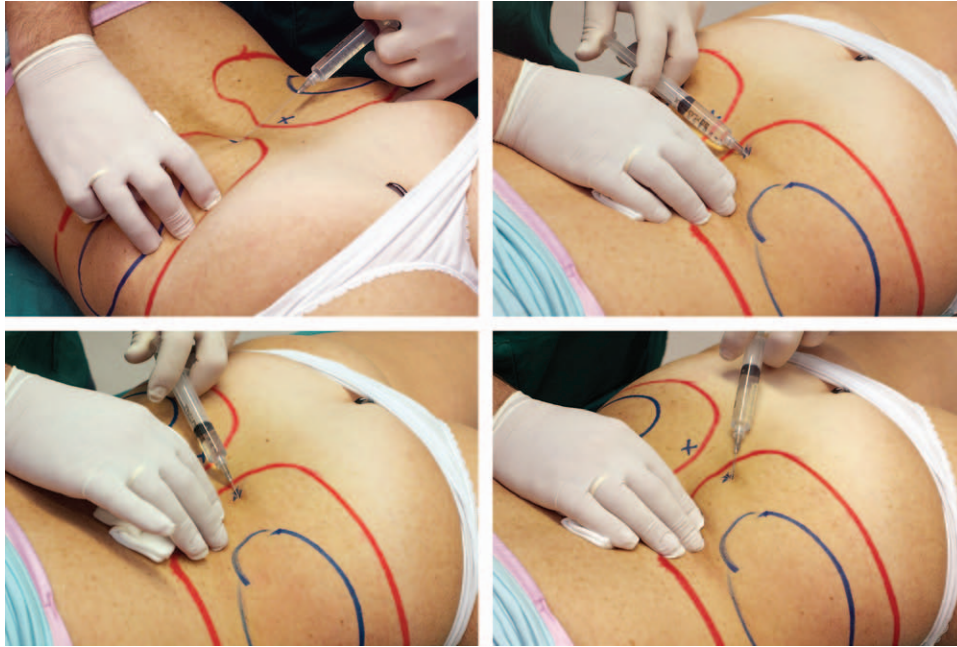
In the body, 1 vial for each  $100\text{ cm}^2$  ( $10 \times 10\text{ cm}$ ) is used, on the average, for subcutaneous fat of a limited degree (pinch test  $<3\text{ cm}$ ) and 1.5 vials for subcutaneous fat of a greater entity (pinch test  $>3\text{ cm}$ ).

Clinical evidence has shown that larger dosages significantly increase the risk of onset of adverse effects.<sup>5</sup>

### Posttreatment Management

After the treatment, the use of contentive elastic sheaths or a pressure bandage is highly recommended during the





**Fig. 2.** The sequence of images shows the correct execution of the intralipotherapy technique. The long needle is inserted and retracted several times to cover, with a fanning motion, the area to be treated.

first 48 to 72 hours. These, in addition to reducing the initial pain, which is typical during the first 12 to 24 hours, also reduce edema and in general, the posttreatment phase.

Lymphatic drainage or pressure therapies are also advised to reduce the postoperative phase and accelerate a full recovery (2 sessions per week for 2 to 3 weeks post-treatment starting from the third day after the treatment).

#### Evaluation of the Results

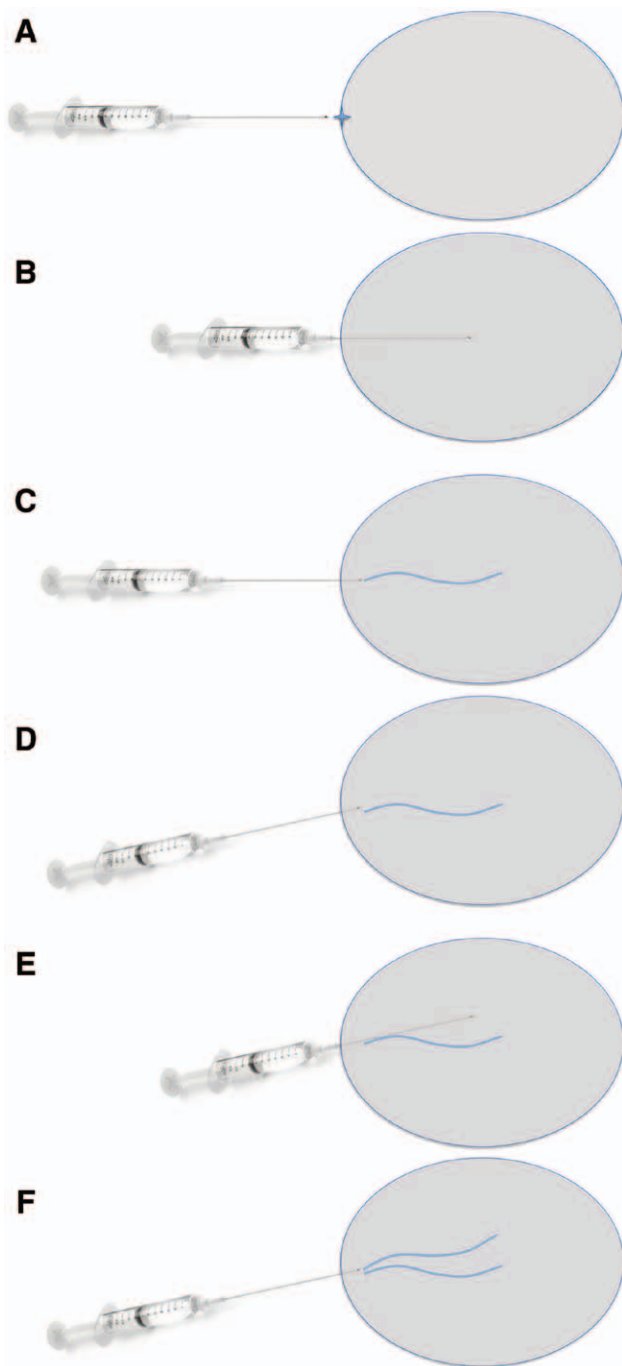
Aesthetic outcomes were evaluated by the authors and their colleagues (total 37 doctors) in 1,832 patients treated by them directly, using preoperative and postoperative photographic documentation. In patients who had been treated in several different areas simultaneously, each area was evaluated independently. Each case was assessed by two doctors who did not perform the treatment; they did not know the characteristics of the treatment (number of sessions, the quantity infiltrated, and the doctor who performed the treatment). The question put to the two doctors was divided into two categories: liporeduction change—significant or nonsignificant. The outcome was considered positive only if observed by both doctors. The patients also evaluated the results: their level of satisfaction was rated and the occurrence of adverse events (especially minor ones that were very frequent) was evaluated by filling out an anonymous form in the waiting room and given to nonmedical personnel (the results were rated from 0 to 10, where 0 is “no result at all” and 10 is “the best result achievable”). In some cases, pre- and postultrasound and/or centimetric evaluations were made. The postevaluations were not performed before 3 months after the last treatment (for the inner knee not earlier than 5 months). Follow-up ranged from a minimum of 3 months to a maximum of 24. Aesthetic outcome was evaluated only in patients who completed the

right follow-up. Patients evaluated with variations of  $\pm 5\%$  of initial body weight were not considered in this study. Minor adverse events were assessed by monitoring the activity of the 3,590 physicians' ability to use the device in the 6 years that were analyzed: requests for advice and communications with the reference trainers, reports from distributors in various countries, and the parent company.

#### RESULTS

Of the 1,832 patients treated, 77.95% (1,428) are female and 22.05% (404) are male. In total, 26.64% (488) patients were not taken into consideration in the study because they presented with a body weight variation greater than  $\pm 5\%$ . The subjective evaluation of patients demonstrated the success of the treatments (that is, a score  $\geq 6$ ) in 67.2% of cases. The medical evaluation performed by photographic comparisons (or with other methods, ie, ultrasound) showed therapeutic success in 76.7% of the cases (Figs. 4–7). The best results have been reported on hips, double chin, and buffalo humps. The worst results were obtained on the arms and inner thighs (Fig. 8). No significant difference was evaluated when comparing the results in males and females in the same area. However, irrespective of sex, localized android fat-type (abdomen and hips) showed increased responsiveness to treatment over the gynoid-type liporeductive adiposity (culot thighs, inner thighs, and inner knee).

As with other methodologies even with intralipotherapy, there may be occasional adverse effects, which can be classified as major and minor. In both cases, they can be attributed to local phenomena. According to the literature<sup>5–7</sup> and the experience of the authors, the only occurrences of systemic adverse events were allergic reactions (in our experience with Aqualyx  $<0.003\%$ ). Minor adverse



**Fig. 3.** Intralipotherapy technique. A, The needle is inserted into the access point. B, The needle completely penetrates the adipose tissue parallel to the skin surface. C, The needle is retracted releasing 0.2 to 0.4 mL of solution. D, Without removing the needle from the skin, its direction is changed. E, Again the needle penetrates the adipose tissue repeating the same procedure as in point B. F, The solution is again released while retracting the needle as in (C). The procedure continues until the area of interest has been completely covered, forming a fan design into which small quantities of solution have been released.

events are extremely common and can be considered as a normal consequence of the treatment.<sup>5,7,8</sup> These include

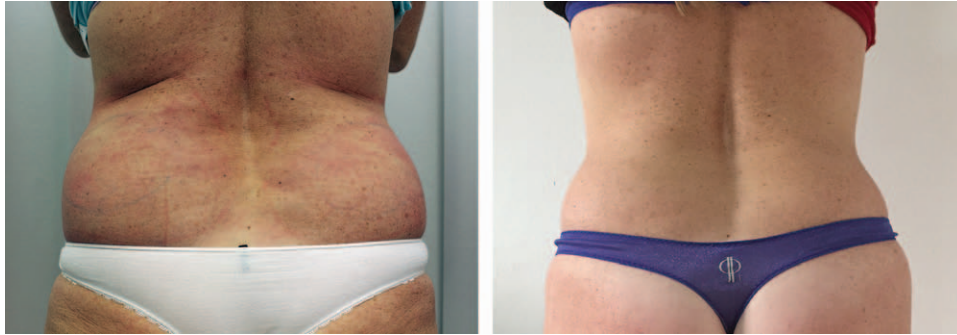
edema in the first 72 hours (88.76%), pain lasting more than 48 hours (48.54%), bruising (72.58%), and transient nodules (16.36%). Major adverse events are rare<sup>9</sup>: hyperpigmentation (<0.002%), permanent paresthesia/dysesthesia (<0.01%), skin necrosis (<0.01%), permanent nodules (0.005%), and skin irregularities (<0.03%). Risk factors for occurrence of major adverse events are incorrect execution of the intralipotherapy technique (uneven release of the agent, bolus, and placement which is too superficial), patients over 60 years of age, overdosing, and a shortened interval between 2 treatments.

## DISCUSSION

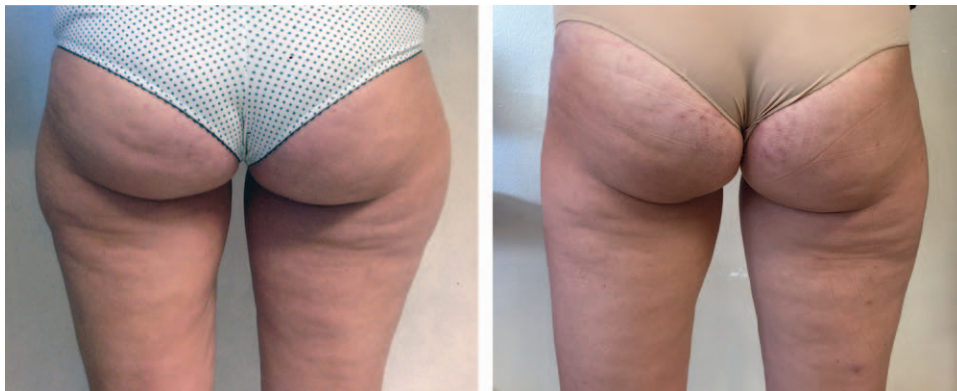The use of prepared injectable materials for the reduction of subcutaneous adipose deposits dates back to the turn of the century. These preparations are all derived from the so-called Natterman formula (EPL Natterman—Essentiale/Lipostabil, NATTERMANN & Cie GmbH—Cologne Germany)<sup>10</sup> (Table 2) developed for the intravenous treatment of a number of diseases: hepatic steatosis from alcohol and conditions of dysmetabolism (diabetes, lipoprotein over nutrition, obesity, and malnutrition), adjuvant therapy for intoxication from toxic agents and by some groups of drugs (antituberculosis, antipsychotics, antiepileptics, and immunosuppressants), hypertriglyceridemia and hypercholesterolemia type IV, IIb, IIa, and prevention of fat emboli.

The studies published at the beginning of the new millennium<sup>11–14</sup> show the actual effectiveness for reducing unwanted fat, first in the lower eyelid, and then all other parts of the body.

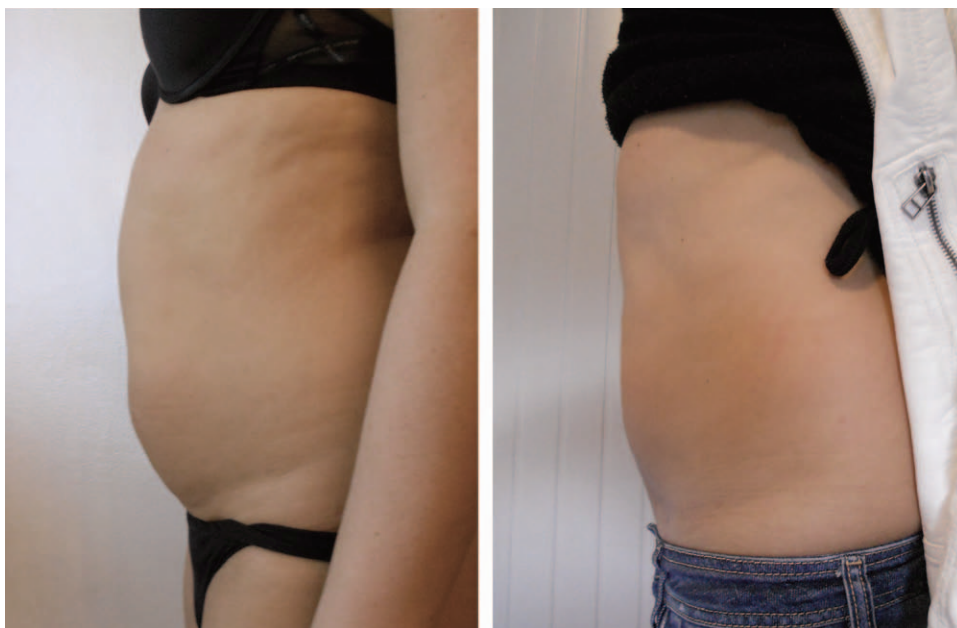
In parallel, to affirm and spread preparations of this type for off-label use (or on the basis of scientific evidence used in a clinical situation not foreseen in the technical data sheet and/or the instructions for use), studies show that the actual agent capable of lysing the cell is sodium deoxycholate and not phosphatidylcholine.<sup>15–17</sup> Today it is universally accepted that the adipocytolytic formulations based on phosphatidylcholine have a therapeutic effect (necrosis of the adipocytes) due to its solvent or sodium deoxycholate. The latter is a surfactant that emulsifies lipids, a biliary acid produced in the liver and secreted into the intestine to digest dietary fats; when injected into the adipose tissue, it induces necrosis by means of emulsification (micelles) of the adipocytes.<sup>18</sup> Sodium deoxycholate and all the formulations containing it induce adipocytolysis and not lipolysis.<sup>19</sup> To date, despite the widespread use and almost worldwide diffusion, the preparations of phosphatidylcholine and sodium deoxycholate (FC/DC) still have not been endorsed by the competent authorities for the treatment of localized fat; therefore, it continues to be used off-label. In Europe, only one Class III medical device has received CE certification (approved in 2009) for the reduction of localized fat in combination with ultrasound therapy: Aqualyx (Marllor International, San Giovanni in Marignano, Italy) is a mix of biocompatible detergents with a short half-life and biodegradable materials (sodium salt of 3 $\alpha$ ,12 $\alpha$ -dihydroxy-5 $\beta$ -24-oic cholic acid 0.7%), slow release, immersed in a sugar matrix



**Fig. 4.** Pretreatment and posttreatment photographs of the lumbar region of a 48-year-old female patient. Two sessions with Aqualyx (48mL per session). The patient lost 3 kg during the period in which the intralipotherapy was performed.

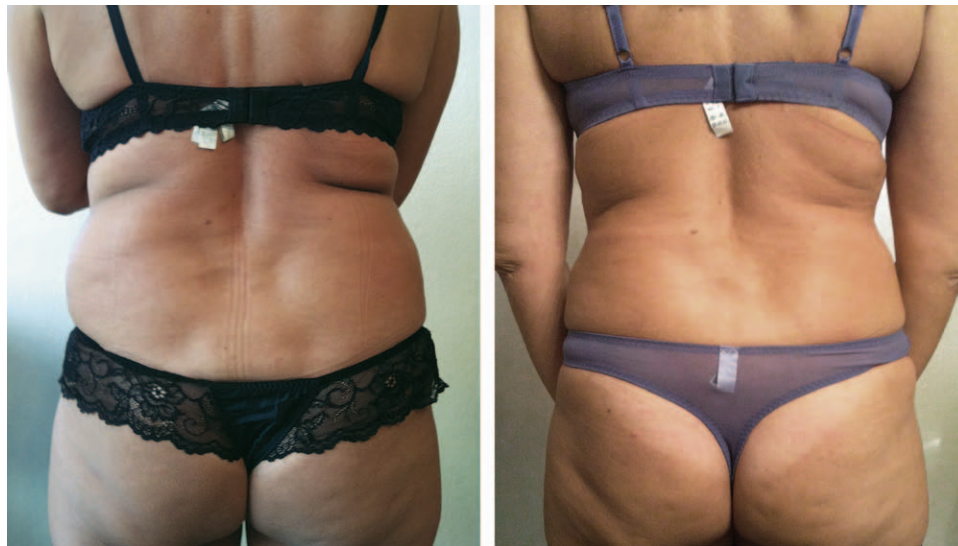

**Fig. 5.** Pretreatment and posttreatment photographs of saddlebag thighs in a 34-year-old female patient. Five combine Aqualyx-US sessions (40mL per session). The patient did not undergo any weight changes during the period in which the intralipotherapy was performed.

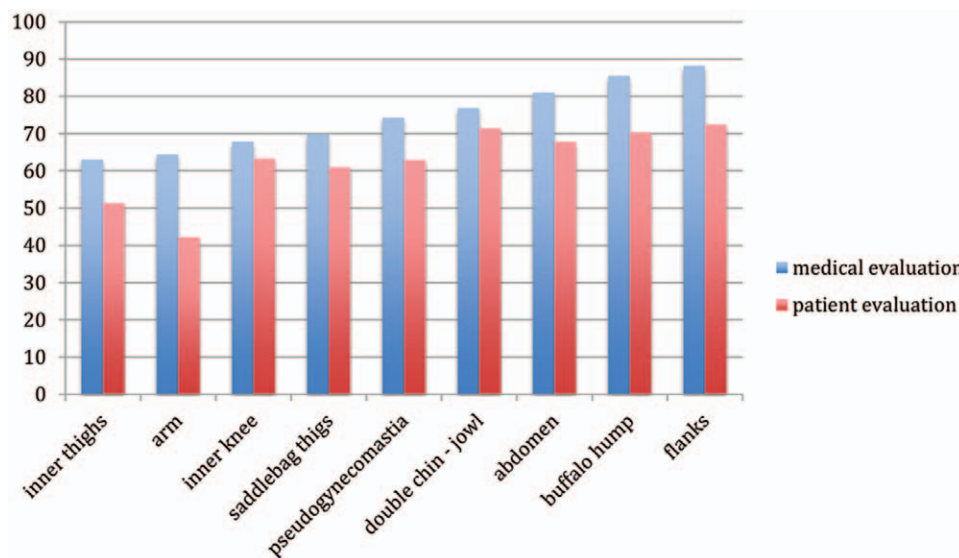


**Fig. 6.** Pretreatment and posttreatment photographs of the abdomen of a 41-year-old female patient. Six sessions of FC-SD (50 mL per session). The patient did not undergo any weight changes during the period in which the intralipotherapy was performed.





**Fig. 7.** Pretreatment and posttreatment photographs of flanks and back rolls of a 55-year-old female patient. Five sessions of Aqualyx (48 mL per session). The patient did not undergo any weight changes during the period in which the intralipotherapy was performed.



**Fig. 8.** Evaluation of results per area according to the medical assessment and the patient. Photographic comparisons, ultrasound evaluation, skinfold thickness test, and centimetric evaluation have not shown significant differences in evaluating results. Patient satisfaction has been considered with a score of 6 to 10.

**Table 2. Composition of Essentiale Phospholipids–Lipostabil**

Formula of Natterman	
Phosphatidylcholine	5%
Sodium deoxycholate	2.5%
Benzyl alcohol	0.9%
Sodium hydroxide	0.26%
Vitamin E	0.1%
Sterile water	quantum satis

(polymer of 3: 6-anhydro-L-galactose and D-galactose), and a buffer system.<sup>1,2</sup> In the United States, the Food and Drug Administration has recently approved Kybella (Kythera

Biopharmaceuticals Inc., Westlake Village, California, approved on 04.29.2015), a sodium deoxycholate-based drug indicated for the treatment of double chin in adults (Table 3).<sup>20</sup> Both Aqualyx and Kybella do not contain phosphatidylcholine in their composition, which makes them more effective in the treatment, but gives them less manoeuvrability.<sup>21,22</sup>

To the adipocytolytic substances based on DC formulations, vitamin C has recently been added. Although they are still being studied and waiting for an initial assessment (for off-label use), they represent a real innovation in intralipotherapy because—unlike the previously mentioned agents—they induce adipocyte apoptosis instead of necrosis.

**Table 3. Composition of the Kybella (ATX-101) Drug**

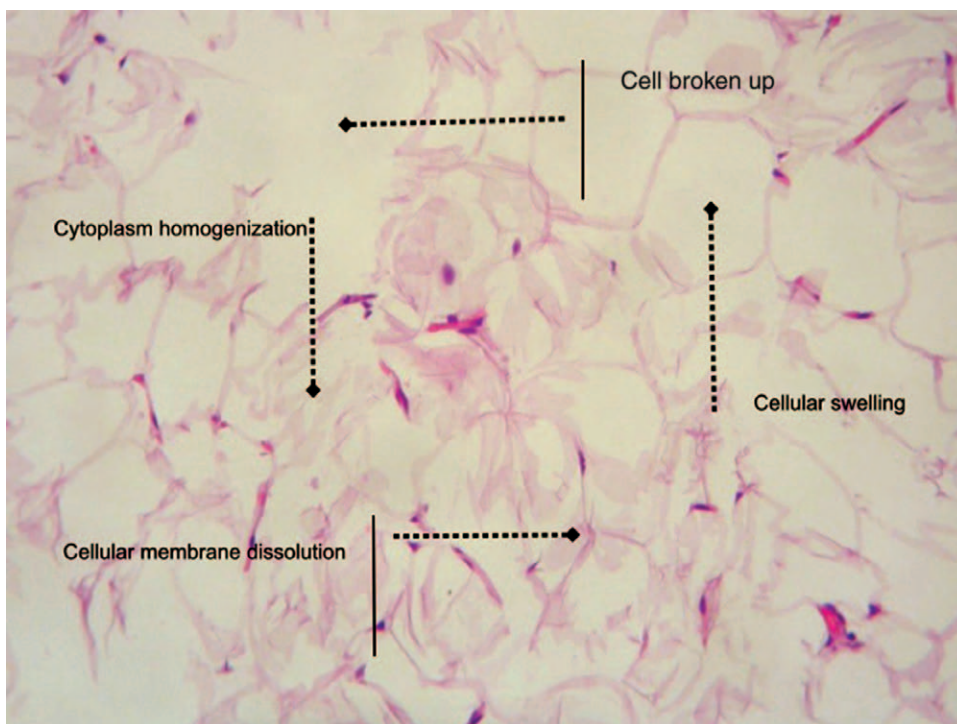
ATX-101	
Sodium deoxycholate	1%
Benzyl alcohol	0.9%
Sodium phosphate dibasic	0.142%
Sodium chloride	0.438%
Sodium hydroxide	0.143%
Hydrochloric acid and sodium Hydroxide	quantum satis pH 8.3
Sterile water	quantum satis

The vitamin C, in certain concentrations with ionic Iron added to it and diluted with double-distilled water, induces the Fenton reaction in the adipose cells with cell damage resulting from oxidation/free radicals and apoptosis.<sup>23-25</sup>

The intralipotherapy is the most suitable technique for administering adipocytolytic substances in subcutaneous fat. These substances are totally nonselective and induce cytolysis directly in the area where the device was injected, unlike other substances used subcutaneously, leading to functional alterations.<sup>9</sup> However, it is important to emphasize that it has been demonstrated *in vitro* and *in vivo* that DC decreases its ability to lyse cells in relation to the protein concentration of the tissue. This shows that the deterging effect of DC is preferentially directed to adipocytes although other tissues with an elevated protein content are protected (muscle, etc.).<sup>26</sup> The adipocytolytic substances need to be released directly into the fatty tissue as homogeneously as possible and at different levels. In the case of substances having a functional effect (ie, carnitine and theophylline), the recourse to the mesothera-

py method is justified because the release of boluses spaced apart at a predetermined depth ensures good homogeneity by diffusion through the concentration gradient on the same plane.<sup>27</sup> Contrary to what is indicated in the Kybella<sup>20</sup> explanatory leaflet, we strongly advise against using adipocytolytic agents with the mesotherapy technique because of the high risk of irregularities of the skin (pseudocellulite effect) and nodules.<sup>28</sup> The selectivity of nonsurgical liporeduction with the use of sodium deoxycholate is guaranteed by the injection technique. (i) The intralipotherapy allows targeting only the subcutaneous adipose tissue without affecting the dermis and deep structures (fascia, muscles, etc.). (ii) The intralipotherapy allows to distribute DC as evenly and smoothly as possible to ensure proper liporeduction, avoiding the formation of irregularities and treating localized fat dimensionally, that is, considering an extension and a nonuniform thickness (thicker in the more central areas and thinner on the margins), similar to the surgical technique of liposculpture. (iii) The intralipotherapy reduces the number of cutaneous accesses drastically compared to traditional mesotherapy (1-3 to the area to be treated) reducing the risk of infections. (iv) The intralipotherapy reduces the risk of skin irregularities due to a distribution in boluses and an application that is too shallow as in mesotherapy. (v) The intralipotherapy reduces the risk of skin necrosis as the release is deeper and more homogenous.

Evaluations of histological biopsies taken 3 weeks post-treatment show that even several days after the treatment, the cytolysis effect continues to act on the adipocytes. In the preparations, indicators of early and late damage



**Fig. 9.** Histological biopsy performed 3 weeks after treatment with a CE-marked device. In the image are visible early signs of cell damage (cell swelling and cytoplasmic homogenization), late findings (duplication and division of the 2 phases of the cell membrane), and cell lysis (image of Professor Motelese).





**Fig. 10.** Intralipotherapy cannula can either be disposable or reusable. The single hole has a diameter smaller than 1 mm and ensures an optimum flow (0.2–0.4 mL of product per passage).

(Fig. 9) coexist. This is particularly evident with the CE-approved device because the chemical formulation controls a modulated aggressiveness combined with a slow release. The histological findings suggested that the interval between sessions should be spaced further apart with respect to the past where the treatments were performed at 2-week intervals. Today we realize that it is essential to wait at least 4 to 7 weeks before the next session. This interval is subject to change based on the area of the body treated (ie, the knee needs at least 8 weeks), the individual response, and the quantity used.

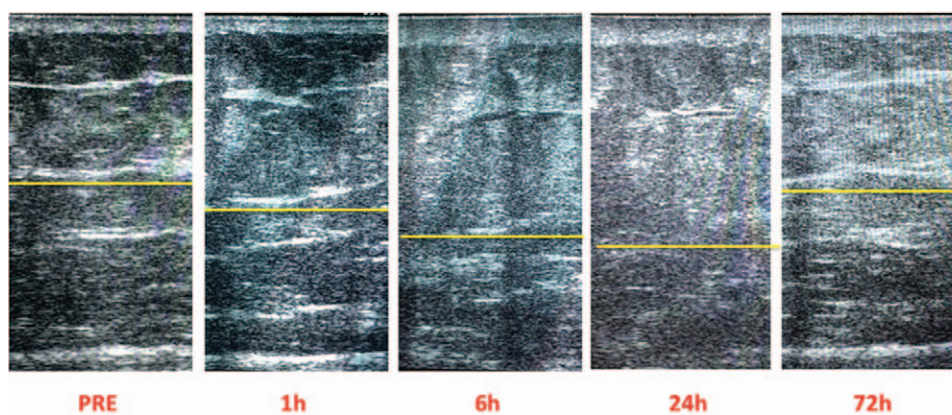
As in any technique, the intralipotherapy also has a technical failure rate and that deserves some consideration. The difference in rates of success perceived by the patient (average 67.2%) and medical evaluation (76.7%) is mainly due to the fact that patients generally have a high expectation from the treatment. Furthermore, when patients rated, they did not have a means to compare the current status with the previous treatment that dates back many months before. Often patients do not remember the original situation and this leads to underestimate the result. Instead, physicians' evaluators have at their disposal photographs, US, or centimetric evaluations of pretreatment and posttreatment.

The variability of results on different anatomical areas treated is due to different intrinsic characteristics of the subcutaneous adipose tissue. Localized fat deposits that are prevalently hypertrophic have more therapeutic results unlike those prevalently hyperplastic and this is mainly due to two factors: (i) different tissue regenerating capacity (higher in hyperplastic forms) and (ii) the various vulnerabilities of sodium deoxycholate (higher in hypertrophic forms).

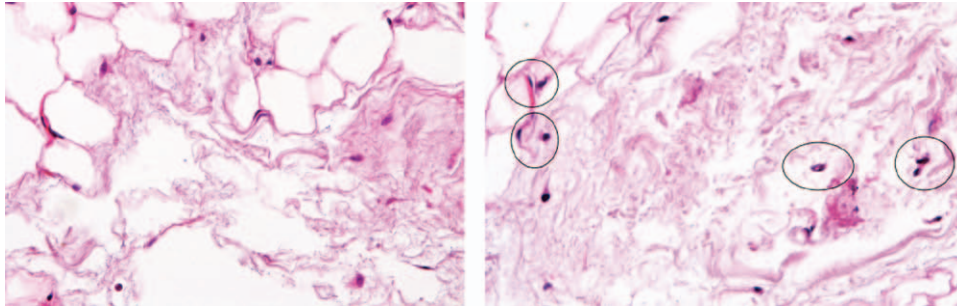
However, it must be stressed that to have a more correct and efficient evaluation of the results, the procedure needs deeper analysis and statistical tests.

Only recently have intralipotherapy cannulas (Fig. 10) been introduced. These, unlike the Klein cannulas and those used in liposuction, have unique characteristics and were specifically designed for this technique, allowing for an optimal flow and release of the adipocytolytic agent (minimum at each step, from 0.2 to 0.4 mL). The advantages of the cannula consist in the fact that they reduce vascular damage and injury to other important structures (ie, nerves), reducing the risk of major adverse events (skin necrosis, permanent paresthesia/dysesthesia) and decreasing the number and extent of the bruising. The use of a cannula necessitates the application of a local anesthetic before creating the access site and subsequently to creating the access with an 18-gauge needle.

Unlike other authors, we strongly believe in the synergy between intralipotherapy and other techniques, in particular, the use of ultrasound and carboxytherapy. External ultrasound has a damaging effect on adipose tissue through thermal agitation, which induces its interstitial fluids (most likely with a cavitation effect, proved theoretically but never demonstrated in vivo).<sup>29–32</sup> The increase of fluids in the interstitial tissues induced by the adipocytolytic agent (inflammatory edema) provides a greater amount of substrate, which is exposed to the ultrasound for the reduction of the subcutaneous adipose tissue, which has already been damaged by the effect of injected surfactants from the intralipotherapy. Serial echography performed at time 0, 10 minutes, 1 hour, 6 hours, 24 hours, 48 hours, and 72 hours postintraipotherapy sessions have shown that the edema effect induced by the adipocytolytic agent reaches a maximum level between 6 and 24 hours (Fig. 11). The ultrasound session should therefore be performed 24 hours after the intralipotherapy session. In addition, weekly sessions are recommended. The difference between intralipotherapy alone and in combination with ultrasound is not success rate that has remained the same but consists essentially in the fact that ultrasound determines a more homogeneous and uniform result in subcu-



**Fig. 11.** Serial images of the adipose tissue; it is evident that the edema induced by treatment with the adipocytolytic agent increases in the first 24 hours and then starts to reduce and disappear 72 hours posttreatment. The maximum level is reached between 6 and 24 hours.



**Fig. 12.** Images of histological sections stained with hematoxylin-eosin of biopsies performed 10 to 5 days posttreatment. On the left, the preparation on the fifth day shows the characteristic signs of insult with the adipocytolytic agent: cell swelling, cytoplasm homogenization, and cell lysis. On the right, preparation on the 10th day always shows clear signs of adipocyte necrosis but with “reminiscent structures” of adipocytes in which the nuclei are much darker (circled structures). These nuclei are characteristic signs of apoptosis.

taneous fat reduced, without irregularity of surface, with no changes in tissue texture from that of the surrounding untreated, avoiding that anomalous effect that often shows after liposculpture treatments and intralipotherapy. The association with carboxytherapy<sup>33–37</sup> showed a greater efficiency histologically when compared to intralipotherapy alone. To the necrotic process induced by the intralipotherapy detergents, clear signs of adipocyte apoptosis are seen (Fig. 12). The treatment with gas is performed immediately after the intralipotherapy treatment, with inoculations of 4 mL of medical carbon dioxide. The inoculation is made with a 30-gauge needle 13-mm-long placed perpendicular to the skin plane and submerged completely into the adipose tissue, which had previously been treated with intralipotherapy. The inoculations are made 3 cm apart from each other, the flow is 80 mL/min and the gas has a temperature of 42°C. Dr Amuso used intralipotherapy only in association with carboxytherapy, treating 47 patients: success rate has remained the same but he needed a lower number of sessions (1 session on average) and a shorter interval between sessions (1–2 weeks on average).

The importance of adequate training for the physician is essential and this has also been emphasized in the international field.<sup>1</sup> The physician who wants to perform intralipotherapy treatments must be able to deal competently with each anatomical district and to achieve maximum results with a minimum risk. For this reason, the company distributing Aqualyx has organized a course for certifying the use of the device.

## CONCLUSIONS

Clinical evidence and scientific studies have proven the effectiveness of adipocytolytic substances for the non-surgical reduction of antiaesthetic subcutaneous fat.<sup>1,5–8,11–19,21,22,28</sup> The products on the market that have obtained approval from competent bodies (CE and Food and Drug Administration) do not contain FC and have been proven to be more efficient with respect to first-generation products.<sup>1,2,20,38,39</sup> However, all of them having a nonenzymatic mechanism of action, based only on a deterging effect, the selectivity is mainly determined by the position in which the substance is released. Nevertheless, among all

the tissues, the adipose tissue is the most vulnerable because of poor protective factors (albumin and proteins in general).<sup>26</sup>

Intralipotherapy is the correct technique for administering adipocytolytic agents because it allows them to be distributed evenly over the entire area and at all levels although avoiding the dermis and muscle. It is necessary that the practitioner must be adequately trained.<sup>1</sup> The standardization of the technique (protocol, dosage, post-operative management, etc.) must have basic references to obtain optimal results and minimize adverse events.

**Roberto Amore, MD**

University of Palermo

P.zza Alessandrini 2, Cecina

Livorno, Italy

E-mail: robertoamore@hotmail.com

## REFERENCES

- Duncan D. Response to “injection lipolysis with phosphatidylcholine and deoxycholate”. *Aesthet Surg J.* 2013;33:1073–1075.
- Aqualyx – explanatory leaflet. Aqualyx product information website. <http://www.aqualyx.com>. Accessed January 25, 2016.
- Gorney M, Martello J. Patient selection criteria. *Clin Plast Surg.* 1999;26:37–40, vi.
- Martello J, Bailey CW Jr. Doctor-patient relationship. The consultation. *Clin Plast Surg.* 1999;26:53–5, vi.
- Pinto H, Hernandez C, Turra C, et al. Evaluation of a new adipocytolytic solution: adverse effects and their relationship with the number of vials injected. *J Drugs Dermatol.* 2014;13:1451–1455.
- Yagima Odo ME, Cucé LC, Odo LM, et al. Action of sodium deoxycholate on subcutaneous human tissue: local and systemic effects. *Dermatol Surg.* 2007;33:178–188.
- Duncan DI, Chubaty R. Clinical safety data and standards of practice for injection lipolysis: a retrospective study. *Aesthet Surg J.* 2006;26:575–585.
- Rittes PG. Complications of Lipostabil Endovena for treating localized fat deposits. *Aesthet Surg J.* 2007;27:146–149.
- Gupta A, Loboeki C, Singh S, et al. Actions and comparative efficacy of phosphatidylcholine formulation and isolated sodium deoxycholate for different cell types. *Aesthet Plast Surg.* 2009;33:346–352. Accessed November 1, 2015.
- IBCMT, International Board of Clinical Metal Toxicology. Available at: <http://www.ibcmt.com/2013-04-14-Lipostabil-Phosphatidylcholine-Essentiale303.pdf>.

11. Rittes PG. The use of phosphatidylcholine for correction of lower lid bulging due to prominent fat pads. *Dermatol Surg.* 2001;27:391–392.
12. Rittes PG. The use of phosphatidylcholine for correction of localized fat deposits. *Aesthet Plast Surg.* 2003;27:315–318.
13. Ablon G, Rotunda AM. Treatment of lower eyelid fat pads using phosphatidylcholine: clinical trial and review. *Dermatol Surg.* 2004;30:422–427; discussion 428.
14. Young VL. Lipostabil: the effect of phosphatidylcholine on subcutaneous fat. *Aesthet Surg J.* 2003;23:413–417.
15. Motolese P. Phospholipids do not have lipolytic activity. A critical review. *J Cosmet Laser Ther.* 2008;10:114–118.
16. Rose PT, Morgan M. Histological changes associated with mesotherapy for fat dissolution. *J Cosmet Laser Ther.* 2005;7:17–19.
17. Rotunda AM, Suzuki H, Moy RL, et al. Detergent effects of sodium deoxycholate are a major feature of an injectable phosphatidylcholine formulation used for localized fat dissolution. *Dermatol Surg.* 2004;30:1001–1008.
18. Rittes PG, Rittes JC, Carriel Amary MF. Injection of phosphatidylcholine in fat tissue: experimental study of local action in rabbits. *Aesthet Plast Surg.* 2006;30:474–478.
19. Klein SM1, Schreml S, Nerlich M, et al. In vitro studies investigating the effect of subcutaneous phosphatidylcholine injections in the 3T3-L1 adipocyte model: lipolysis or lipid dissolution? *Plast Reconstr Surg.* 2009;124:419–427. Accessed November 20, 2016.
20. Available at: [http://www.accessdata.fda.gov/drugsatfda\\_docs/label/2015/206333Orig1s000lbl.pdf](http://www.accessdata.fda.gov/drugsatfda_docs/label/2015/206333Orig1s000lbl.pdf).
21. Hasengschwandtner F, Gundermann KJ. Injection lipolysis with phosphatidylcholine and deoxycholate. *Aesthet Surg J.* 2013;33:1071–1072.
22. Salti G, Rauso R. Comments on “Injection lipolysis with phosphatidylcholine and deoxycholate”. *Aesthet Surg J.* 2014;34:639–640.
23. Hamton MB, Orrenius S. Redox regulation of apoptotic cell death. *Biofactors* 1998;8:1–5.
24. Sakagami H, Satoh K, Ohata H, et al. Relationship between ascorbyl radical intensity and apoptosis-inducing activity. *Anticancer Res.* 1996;16:2635–2644.
25. Gao Y, Wei Q, Chen SH. The effect of local injection with vitamin C to adipocytes apoptosis. *J Chin Med Res.* 2009;9:325–329.
26. Thuangtong R, Bentow JJ, Knopp K, et al. Tissueselective effects of injected deoxycholate. *Dermatol Surg.* 2010;36:899–908.
27. Rotunda AM, Kolodney MS. Mesotherapy and phosphatidylcholine injections: historical clarification and review. *Dermatol Surg.* 2006;32:465–480.
28. Hasengschwandtner F, Gundermann KJ. Response to “Injection lipolysis with phosphatidylcholine and deoxycholate”. *Aesthet Surg J.* 2013;33:1071–1072.
29. Hotta TA. Nonsurgical body contouring with focused ultrasound. *Plast Surg Nurs.* 2010;30:77–82; quiz 83–84.
30. Ascher B. Safety and efficacy of UltraShape Contour I treatments to improve the appearance of body contours: multiple treatments in shorter intervals. *Aesthet Surg J.* 2010;30:217–224.
31. Coleman KM, Coleman WP 3rd, Benchetrit A. Non-invasive, external ultrasonic lipolysis. *Semin Cutan Med Surg.* 2009;28:263–267.
32. Brown SA1, Greenbaum L, Shtukmaster S, et al. Characterization of nonthermal focused ultrasound for noninvasive selective fat cell disruption (lysis): technical and preclinical assessment. *Plast Reconstr Surg.* 2009;124:92–101.
33. Brandi C, D’Aniello C, Grimaldi L, et al. Carbon dioxide therapy in the treatment of localized adiposities: clinical study and histopathological correlations. *Aesthet Plast Surg.* 2001;25:170–174.
34. Campos V, Bloch L, Cordeiro T. Carboxytherapy for gynoid lipodystrophy treatment: the Brazilian experience. *J Am Acad Dermatol.* 2007;56:AB196.
35. Koutná N. Carboxytherapy—a new non-invasive method in aesthetic medicine. *Cas Lek Cesk* 2006;145:841–843.
36. Brandi C, D’Aniello C, Grimaldi L, et al. Carbon dioxide therapy: effects on skin irregularity and its use as a complement to liposuction. *Aesthet Plast Surg.* 2004;28:222–225.
37. Georgia S, Lee K. Carbon dioxide therapy in the treatment of cellulite: an audit of clinical practice. *Aesthet Plast Surg.* 2010;34: 239–243.
38. Wollina U, Goldman A. ATX-101 for reduction of submental fat. *Expert Opin Pharmacother.* 2015;16:755–762.
39. Walker P, Fellmann J, Lizzul PF. A phase I safety and pharmacokinetic study of ATX-101: injectable, synthetic deoxycholic acid for submental contouring. *J Drugs Dermatol.* 2015;14:279–287.