

SPECIAL REPORT

For reprint orders, please contact: reprints@futuremedicine.com

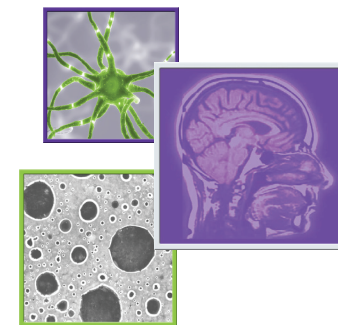
Brain metastases: an overview

F Bertolini¹, A Spallanzani^{*1}, A Fontana¹, R Depenni¹ & G Luppi¹

SUMMARY So far brain metastases represent a critical stage of a disease course and the frequency is increasing over the years. The treatment of brain metastases should be individualized for each patient: in case of single brain metastasis, surgery or radiosurgery should be considered as first options of treatment; in case of multiple lesions, whole-brain radiotherapy is the standard of care in association with systemic therapy or surgery/radiosurgery. Chemotherapy should be considered when surgery or radiation therapy are not possible. In the last decades, TKIs or monoclonal antibodies have shown increase in overall response rate and overall survival in Phase II–III trials. The aim of this paper is to make an overview of the current approaches in management of patients with brain metastases.

Brain metastases (BMs) are the most frequent cause of malignant tumor of the central nervous system (CNS), four-times higher than primary tumors; about 20–40% of patients with cancer will develop BM in their clinical course. Furthermore, the frequency of BM is increasing over the years as a result of the increase in overall survival (OS) in cancer patients and of the improvement in diagnostic tools for BM detecting, as magnetic resonance imaging (MRI). Primary tumors that most frequently metastasize to brain are in order of frequency: lung ($\geq 50\%$), breast (15–25%), melanoma (5–20%) and, less frequently, testis, kidney, colon–rectum, thyroid, but more in general any cancer subtype can metastasize to the brain. In 15% of cases, the primary site is unknown. BMs usually develop in advanced stages of disease, less frequently BMs are the first clinical sign of cancer and/or synchronous with primary tumor diagnosis. The most recent data in the literature describe a modification of this scenario, in particular, a recent study by Nieder *et al.* [1] brings out a clear difference in the presentation of patients with BM between the period 1983–1989 and 2005–2009. Over time it has been described a greater representation of the female sex (due to a high prevalence of BM from breast cancer), an increase in the number of diagnosis of BM and a lengthening of the interval between the diagnosis of primary tumor and BM detection [2]. Inside the brain the most common sites of metastasis are: cerebral hemispheres (80%), cerebellum (15%) and basal nuclei (about 5–10%) [2]. The clinical presentation of the patient with BM is similar to patients with primary tumors: intracranial hypertension (space-occupying mass), headache, seizures and/or focal neurological symptoms. Headache is the presenting symptom in 40–50% of patients, often secondary to increased intracranial pressure [3]. Focal neurological deficits, such as hemiparesis, aphasia and hemianopia are observed in 40% of cases and in 15–20% of patients seizures are the first symptom. In some cases, BMs have a clinical presentation similar to an acute stroke, often correlated to an intratumoral hemorrhage (melanoma, renal cell carcinoma) or to a transient ischemic attack [4,5]. Patients with multiple metastases and/or intracranial hypertension could have an altered mental state and cognitive slowing, as in case of metabolic encephalopathy. With best supportive care only, median

CNS Oncology



KEYWORDS

- brain metastases
- individualized treatment
- radiotherapy • systemic therapy

¹Department of Oncology, Azienda Ospedaliero-Universitaria Modena, via Del Pozzo, 71, 41124, Modena, Italy

^{*}Author for correspondence: andrea.spallanzani@gmail.com

overall survival time is 1–3 months; radiation therapy (RT) increases survival 3–5 months. Up to now neurosurgical resection, if possible, and whole-brain radiotherapy (WBRT) are the mainstay of treatment.

Moreover surgery, stereotactic RT and/or systemic treatments may improve survival, depending on cancer subtype, number of metastases and extracranial disease control.

Prognostic factors

The prognosis of patients with BM is generally poor and significantly impairs patients quality of life, median survival of patients with BM does not usually exceed 5 months despite the current treatment options available. Nevertheless, the definition of well recognized prognostic subgroups is essential for the choice of a tailored therapeutic strategy. It is important to identify subgroups of patients with favorable prognostic factors that can benefit from an intensive treatment with the goal of improving survival and quality of life. On the contrary in patients without an optimal extracranial disease control and/or co-morbidities (that could limit the tolerability of aggressive treatments), treatment goal is to stabilize BM, to control symptoms and to limit toxicity. The most important prognostic factors are key performance status (KPS), the number of BM, absence of systemic metastases, primary tumor control and age. The ‘Radiotherapy Oncology Group’ (RTOG) designed a prognostic scoring system derived from the analysis of independent prognostic factors for patients with BM and identified three different sub-groups (RPA classes) (Table 1) [6]. It was subsequently developed a new and more detailed prognostic index (Graded Prognostic Assessment, GPA) that takes into account four variables: age, KPS, presence of extra-cerebral metastases and number of BM (Tables 2 & 3) [7,8]. Recently updates were published with refinements to create diagnosis-specific GPA indices [9].

Diagnosis

In the evaluation of brain tumors (primary and BM), magnetic resonance imaging (MRI) is superior to CT scan. MRI is able to detect a greater number of lesions and to better define their pattern (site, dimensions, characteristics): almost 1/3 of patients with single lesion at CT have multiple metastases on MRI [10]. CT may have a role in identifying bone lesions or to exclude hemorrhage within the lesion [11].

In the clinical work-up of a patient with a single BM, a contrast enhanced MRI should be considered to exclude the presence of other smaller lesions and to better define the correct therapeutical approach [12]. In case of diagnosis of a single brain lesion at MRI (i.e., done for neurological symptoms) and no history of cancer, the patient must be submitted to a contrast-enhanced chest and abdomen CT and/or PET-CT to detect the primary tumor outside the CNS or to highlight other neoplastic lesions, more easily approachable for the histotype characterization. If CT or PET-TC do not detect any neoplastic lesions outside the CNS, a neurosurgical approach to obtain histological diagnosis must be considered.

The surgical excision or stereotactic biopsy for diagnostic confirmation might be considered in doubtful cases also in patients with a known history of cancer.

Supportive care

Steroids, in particular dexamethasone, have the greatest initial clinical impact on quality of life in patients with BM. Typically, within the first 24 h after the introduction of steroid treatment, an improvement in neurological symptoms is shown. The clinical improvement is achieved even before the reduction of brain edema and this is due to the effect on the reduction of the permeability of the blood–brain barrier [13]. In patients without signs of intracranial hypertension, low doses of dexamethasone have similar efficacy than

Table 1. The radiotherapy oncology group prognostic classification.

Classes	Prognostic factors	Median survival (months)
I	KPS \geq 70, controlled primary tumor, age <65 years, nonextracranial metastatic disease	7.1
II	KPS \geq 70, primary tumor not controlled or age 65 years, or extracranial metastatic disease	4.2
III	KPS <70	2.3

Key: Key performance status.

Table 2. Graded prognostic assessment classification.

Variable	Score = 0	Score = 0.5	Score = 1
Age (years)	>60	50–59	<50
Key performance status	<70	70–80	90–100
Number of brain metastases	>3	2–3	1
Extra-cranial metastases	Present	None	Absent

higher doses and the clinical improvement based on KPS is similar [14]. Therefore, after the diagnosis of BM, the steroid treatment is recommended, even in the absence of symptoms because of the risk of rapid clinical deterioration. The dose of dexamethasone is modulated according to response to treatment and the patient's condition, and the aim is to identify the lowest effective dose. The initial dose should be 4 mg/day/orally, up to 16 mg/day in cases of brainstem or cerebellum BM or altered state of consciousness or other signs of intracranial hypertension [15]. Prophylactic antiepileptic therapy does not reduce the onset of seizures, then there is no indication to its use. Treatment should be started only in symptomatic patients [16,17]. The enzyme-inducing antiepileptic drugs (enzyme-inducing antiepileptic drugs [EIAEDs]), metabolized by P450 cytochrome (such as phenytoin, carbamazepine and phenobarbital) should be avoided, if possible, as it may cause significant drug interactions with chemotherapeutic agents (i.e., CPT-11, nitrosoureas, navelbine, teniposide, vinblastine, paclitaxel, cyclophosphamide, ifosfamide, topotecan, thiotepa, doxorubicin and methotrexate) and with biological drugs (i.e., imatinib, gefitinib and erlotinib).

Principles of treatment

The treatment of BM should always be individualized for each patient, according to the different sensitivity of the primary cancer to RT and/or chemotherapy (CT), the different clinical history (extracranial disease control, previous treatments, survival, disease-free interval) [17] and especially to the number of metastases. A multidisciplinary discussion of each case

from diagnosis to treatment planning is always recommended.

Single brain metastasis

Only 10% of patients presented with a single BM and only 50% of these patients are resectable. Surgical resection immediately improves symptoms of intracranial hypertension, focal neurological deficits and seizures and reduces the need for steroid. Two of three randomized trials that compared WBRT alone to surgery followed by radiotherapy have shown a benefit in terms of survival of patients treated with surgery compared with radiotherapy alone (median survival of 10.9 vs 6.3 months) and a reduction in local recurrence rate from 52% for surgical patients to 20% for RT patients. The third study did not show a benefit in survival for surgical patients, but a greater number of patients with active systemic disease and poor performance status were included [18–21]. Therefore, surgery is the option of choice in the case of single metastasis in patients with extracranial controlled disease and good performance status (KPS \geq 70).

Stereotactic radiosurgery (SR) (using gamma knife or linear accelerator) has the goal to limit the risk of damage to the surrounding healthy brain tissue and it is characterized by the administration of a single fraction of radiotherapy at higher dose. Target lesions might have a maximum diameter of 3–3.5 cm and might be located at any site inside the brain. The local control at 1 year ranges from 80 to 90% with a median survival of 6–12 months. SR might be purposed even in BM from radioresistant tumors such as melanoma, renal cell carcinoma and colon cancer [22–26].

Table 3. Outcome of the scores from graded prognostic assessment classification.

Score	Median survival (months)
0–1	2.6
1.5–2.5	3.8
3	6.9
3.5–4	11

A randomized trial showed that the addition of SR to WBRT improves survival of patients with unresectable single metastasis at diagnosis [27]. Moreover, SR can be effective as salvage treatment in recurrences after WBRT [28]. Nevertheless, up to now literature data are not so solid to show if SR might replace surgery in the treatment of single BM [29]. Currently, the choice between surgery and SR depends on multiple factors, including size and location of the lesion to be treated, but also extracerebral disease control and performance status. The role of adjuvant WBRT (30–40 Gy in 2–3 weeks) after surgery or SR is controversial: adjuvant WBRT after surgical resection or SR reduces intracranial relapses, maintaining a better neurological function, but does not influence survival [30].

In case of larger lesions, stereotactic radiotherapy (SRT) of BM should be an alternative option and differs from SR for the dose used per fraction and for the duration of treatment, longer than in case of SR [31].

Multiple brain metastases ≤ 3

No randomized studies regarding the use of surgery on multiple metastases have been published, although it can be proposed for selected patients. A complete surgical resection might be purposed in case of younger patients, good KPS, surgically feasible, limited number of lesions (≤ 3) and controlled systemic disease. In these selected cases, the efficacy of surgery in achieving a local control is similar than in a single BM [32].

SR is used as an alternative to WBRT in patients with a number of metastases equal to or less than 3, in good KPS and with controlled systemic disease. For smaller lesions (< 2.5 cm), SR may be a possible therapeutic alternative to surgery, whether or not followed by WBRT. In selected patients with multiple BM (up to 3 or 4, in a randomized study) and small lesions (< 4 cm), the addition of SRT to WBRT improves local control of disease but not survival [25]. In patients with good KPS and controlled extracranial disease, the role of adjuvant WBRT after locoregional treatment is similar than in patients with single BM [33].

In case of patients with active systemic disease and/or poor KPS, WBRT alone achieves a median survival of 3–6 months and may be the treatment of choice. There is no evidence to support the choice of any particular dose/fractionation regimen based on histopathology [34]. Soffiatti *et al.* recently published the results of an

EORTC study regarding quality of life (QoL) in patients with BM (up to 3) treated with adjuvant (postsurgery or RS) WBRT versus observation: the study showed that WBRT may negatively impact on some aspects of health-related QoL, even if they are transient. Observation with neuroradiological close follow-up is not detrimental on health-related QoL [35].

Multiple brain metastases > 3

The role of surgery is more restricted in this condition and aimed at obtaining the diagnosis if the primary site of disease is unknown or as treatment in case of larger lesions causing mass effect. In selected cases with newly diagnosed BM, SR alone could be an option, because it is comparable to WBRT in terms of survival. However, the omission of WBRT after SR reduces the intracranial disease control with no differences in overall survival [36]. Quality of life in terms of neurocognitive function after treatment with RS or WBRT (with or without RS) is unknown and never been adequately tested. However, there is a statistically significant difference in overall toxicity in patients treated with SR alone if compared with patients treated with WBRT plus stereotactic boost (based on an interim analysis of a single randomized trial) [37]. The clinical benefits/risks associated with the use of SR in case of progression or recurrence of BM is not supported by strong evidence. Based on these considerations, the use of SR as salvage therapy can only be considered as an option in selected patients with controlled extracranial disease and good KPS [28]. WBRT (30–40 Gy in 10–15 daily fractions) is the standard treatment for patients with multiple BM greater than 3, prolonging median survival from 3 to 6 months and proving good control of symptoms. Higher doses of RT do not increase survival or local control. Moreover, daily fractions higher than 3 Gy may increase the risk of neurotoxicity [38]. Retrospective studies have shown that nearly 50% of patients treated with WBRT die for systemic progression rather than for brain disease. The available literature data on the decline of neurocognitive function after WBRT are limited. Despite the fact that therapeutic approach is influenced by the decline in neurocognitive function after WBRT in long survivors [39,40], more recent studies have suggested that neurocognitive function is strongly and mainly influenced by the brain tumor control [41]. In patients with KPS less than 70, best supportive care is recommended.

Radiosensitizers

A randomized Phase III study of association between a radiation sensitizer called motexafin-gadolinium (MGd) and WBRT in patients with BM from non-small-cell lung cancer (n = 554) showed that MGd is able to prolong the time to neurological progression from 8.8 to 24.2 months (p = 0.004; HR = 0.53), with acceptable toxicity [42].

Chemotherapy

Systemic therapy is rarely used as first-line approach in patients with BM, especially as single treatment (Table 3). Patients with BM from chemosensitive tumors (lung, breast, testicle) should always be evaluated for surgery in relation to the number of BM and the extent/control of systemic disease. BM presents often the same chemo-responsiveness of the primary tumor or extracranial metastases; however, the limited drug levels crossing the blood-brain barrier, the possible interaction with concomitant therapies (i.e., AEDs and EIAEDs) and the possible increased resistance of the neoplastic cells in BM (i.e., due to genotypic or molecular alterations) may be limiting factors. For these reasons, chemotherapy is usually considered as the last therapeutic option when surgery or RT are not possible [43]. The choice and efficacy of chemotherapy depend on chemosensitivity of the primary tumor. In patients not suitable for surgery, although systemic chemotherapy can achieve objective responses, the use of WBRT is extremely important [44,45]. In a large variety of non-small-cell lung cancer (NSCLC) trials, chemotherapy has shown the same response rates in cranial and extracranial disease [46]. For example, in a Phase III study, ftemustine has shown an increase in response rate and time to progression when compared with dacarbazine in patients with BM from melanoma [47]; moreover, ftemustine has shown an increase in response rate also in association with cisplatin in BM from NSCLC [48]. Temozolomide has shown some efficacy in patients with chemo-naïve BM from melanoma [49]. In some randomized studies, several different chemotherapeutic agents, including carboplatin and temozolomide, have been used in addition to WBRT in the treatment of patients with BM from NSCLC and breast cancer: these studies reported an increased local disease control, but no differences in overall survival [50,51]. Therefore, their use can be considered in patients with favorable prognostic factors,

in absence of systemic disease progression. In patients with BM only after chemotherapy for an extra CNS disease, the benefit obtained with further chemotherapy is not significant, but it can be considered in case of chemosensitive forms in combination with radiotherapy. The combined chemo- and radiotherapy may improve response rate and progression-free survival, not overall survival [52,53]. Prophylactic WBRT for patients with small-cell lung cancer in complete response to chemotherapy is the standard treatment and it can reduce the risk of developing BM from 59 to 33% in 3 years and increase the 3-year survival from 15 to 21% [54].

Targeted therapies

Targeted therapies (TT) have been initially employed in extra- central nervous system (CNS) disease, more recently in BM patients (Table 4) [55,56]. Most clinical trials with target therapies in BM enrolled patients with CNS disease progression after WBRT and limited clinical data support the prevention instead of the treatment of BM.

Among TT, both monoclonal antibodies and small molecules have been tested. Several Phase I–II trials with anti-VEGF and in particular bevacizumab (already approved in colorectal cancer, ovarian cancer, metastatic renal carcinoma) are ongoing [57–62].

Ipilimumab (anti-CTLA-4 monoclonal antibody), approved as first line therapy in metastatic melanoma, has been studied in a Phase II trial in patients with BM from melanoma: among 51 patients, 9 (18%) achieved a disease control in both extra-CNS and CNS disease [63].

In the last decade, a large variety of Phase I–II trial with TKIs gave us some answers about their efficacy in the treatment of BM.

Data on the use of sunitinib, an oral TKI that targets VEGFR 1–3 and PDGFR α - β approved in the treatment of metastatic renal cancer and GIST, derive from the expanded access program with an overall response rate (ORR) of 12% (26/213) among 213 patients with advanced renal cell carcinoma and BM [64]. However, sunitinib showed a marginal antitumor activity in a Phase II study in patients with previously irradiated BM from NSCLC with median PFS 9.4 weeks and median (overall survival) OS 25.1 weeks [65].

Sorafenib, an oral VEGFR and RAF-kinase inhibitor approved in HCC and metastatic renal carcinoma, seems to decrease the incidence of

Table 4. Chemotherapy in brain metastases.

Chemotherapy	Study	Phase of trial	Patient population	Patients (n)	ORR	OS (months)
Fotemustine vs DTIC	Avril <i>et al.</i> [47]	III	Melanoma	112	15.2%	7.3
Temozolomide	Agarwala <i>et al.</i> [49]	II	Melanoma	151	7%	3.5
Fotemustine + CDDP	Cotto <i>et al.</i> [48]	II	NSCLC	31	28%	4.0
CBDCA + RT vs RT	Guerrieri <i>et al.</i> [50]	III	NSCLC	21	29%	3.7
CDDP + VP16	Franciosi <i>et al.</i> [46]	II	Breast, NSCLC, melanoma	43	30%	8.0
Temozolomide + WBRT vs WBRT	Verger <i>et al.</i> [51]	II	Brain metastases	41	17%	4.5
Temozolomide + WBRT vs WBRT	Antonadou <i>et al.</i> [52]	II	Brain metastases	25	96%	8.6

NSCLC: Non-small-cell lung cancer; ORR: Overall response rate; OS: Overall survival; RT: Radiation therapy; WBRT: Whole-brain radiotherapy.

BM in a *post hoc* analysis of patients enrolled in the treatment approaches in renal cancer global evaluation trial (TARGET) [66].

BM from NSCLC with activating EGFR mutations have been shown to respond to oral EGFR TKI's gefitinib and erlotinib. They have similar efficacy profile achieving an ORR of 10–38%, with a median duration of response of 9–13.5 months [67–73]. Up to now, no data are available on the activity of crizotinib (oral selective inhibitor of activated ALK) in the same setting.

In breast cancer, BM are frequently diagnosed in HER-2 positive or triple negative patients. The brain seems to be the first site of relapse in HER-2 positive patients treated with trastuzumab (anti-HER-2 monoclonal antibody) and biological subtypes are independent prognostic factors [74,75].

Lapatinib (an orally dual inhibitor of EGFR and HER-2 TKI used in metastatic breast cancer) reaches therapeutic levels in BM. Data of the lapatinib efficacy in patients with active BM have been published in several prospective trials [76,77]. However, there are not randomized trial comparing lapatinib versus radiotherapy alone:

only one study analyzed the combination of lapatinib + capecitabine prior to WBRT, showing an impressive CNS response rate [78]. This trial opens the door for studies comparing WBRT against capecitabine + lapatinib as first line in HER-2 positive patients with brain metastases.

In patients with BM from melanoma, several Phase II trials with vemurafenib (a specific inhibitor of BRAF V600E mutated protein) are ongoing; preliminary results from a single-arm pilot study are promising, showing a partial response in patients with pretreated BM [79,80]. OR in extra-CNS and BM has also been described in a Phase I–II trial with dabrafenib (BRAF inhibitor) [81].

Follow-up treatment to relapse/progression

Patients with BM should be controlled, especially if treated, using MRI every 3 months during the first year, then if clinically indicated. The treatment of recurrent disease is directly related to previous treatments, histotype, extra-CNS disease control and KPS. If the disease progresses locally (failure on local control disease), patients previously treated with surgery could be

Table 5. Target therapies in brain metastases.

Agent	Study	Phase of trial	Patient population	Patients (n)	ORR (%)	OS (months)
Bevacizumab + VP16 + CDDP	Lu <i>et al.</i> [59]	II	Breast	16	75	Ongoing
Bevacizumab + CBDCA	Lin <i>et al.</i> [60]	II	Breast	38	45	Ongoing
Lapatinib	Lin <i>et al.</i> [76]	II	Breast	39	3	6.0
Lapatinib + Xeloda	Bachelot <i>et al.</i> [78]	II	Breast	45	66	17.0
Sunitinib	Gore <i>et al.</i> [64]	III	mRCC	321	12	9.2
Sorafenib	Massard <i>et al.</i> [66]	III	mRCC	139	NA	8.9
Sunitinib	Novello <i>et al.</i> [65]	II	NSCLC	64	1.6	6.0
Gefitinib	Ceresoli <i>et al.</i> [67]	II	NSCLC	41	9.7	5.0
Gefitinib	Wu <i>et al.</i> [68]	II	NSCLC	40	32	15.0
Erlotinib + RT	Welsh <i>et al.</i> [69]	II	NSCLC	40	86	11.8
Vemurafenib	Dummer <i>et al.</i> [80]	II	Melanoma	24	42	5.3
Ipilimumab	Margolin <i>et al.</i> [63]	II	Melanoma	72	16–5	7–3.7

NA: Not available; NSCLC: Non-small-cell lung cancer; ORR: Overall response rate; OS: overall survival; RT: Radiation therapy; WBRT: Whole-brain radiotherapy.

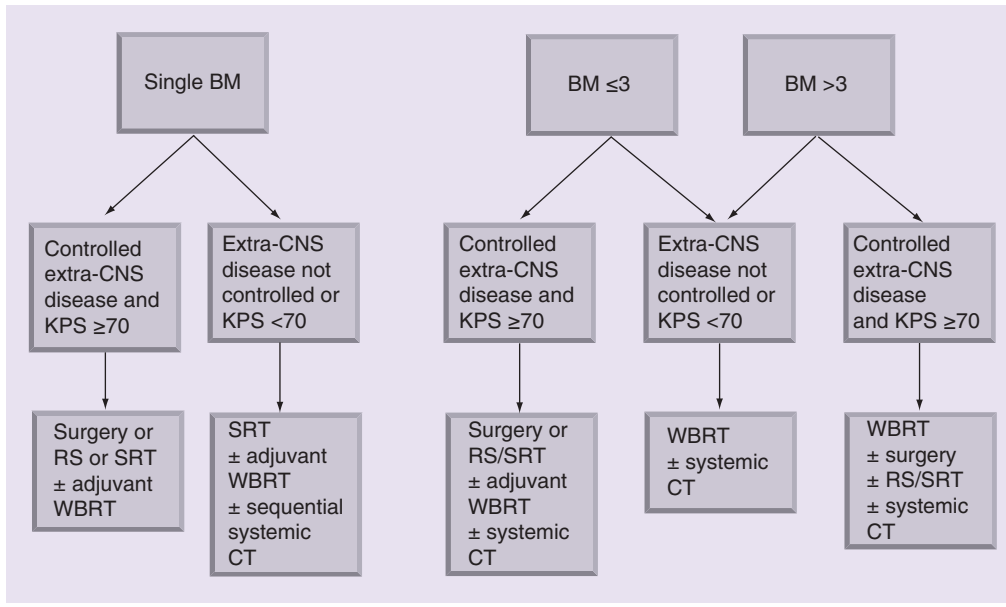


Figure 1. Treatment algorithm.

treated with surgery again, RS, SRT or systemic chemotherapy.

If the disease progresses to other locations regardless of the presence of local recurrence or not, patients not previously treated with WBRT should receive this treatment and a systemic therapy based on histotype. If the KPS is poor and there are no further treatment options available, best supportive care alone may be the only acceptable strategy.

Conclusion & future perspective

The treatment of BM is still controversial, especially in some setting of patients. Aim of the present study is to review literature and try to suggest a possible work-up for these patients (Figure 1).

In particular, we highlighted the importance of a multidisciplinary discussion for the choice of a tailored treatment based on patients characteristics. Surgery and radiotherapy have a consolidated role in this setting. Only few drugs

EXECUTIVE SUMMARY

Background

- The frequency of brain metastases is increasing over the years.
- The treatment of brain metastases should be individualized for each patients based on multiple prognostic factors.
- Systemic treatment with steroids is the first step at diagnosis of symptomatic brain metastases.

Local treatment

- In case of single brain metastasis, surgery or radiosurgery should be considered as first options of treatment.
- In case of multiple brain metastases less than equal to 3, a complete surgical resection might be purposed in case of good prognostic factors and controlled systemic disease.
- In case of multiple brain metastases greater than 3, whole-brain radiotherapy is the standard of care in association with systemic therapy or surgery/radiosurgery.

Systemic treatment

- Chemotherapy has limited efficacy on brain metastases and is usually considered as the last therapeutic option when surgery or radiation therapy are not possible.
- In the last decades, novel agents such as tyrosine kinase inhibitors or monoclonal antibodies have shown increase in overall response rate and overall survival in Phase II–III trials.

may reach proper concentrations within the CNS and efficacy of systemic therapies is limited. Actually few data on the clinical activity of targeted agents are available, but novel agents as TKI's or monoclonal antibodies have shown increase in ORR and OS in Phase II–III trials.

In the immediate future, it would be hopeful that new molecules may demonstrate efficacy and may take a leading role alone or in combination with locoregional therapies in treatment of BM patients (Table 5).

Financial & competing interests disclosure

The authors have no relevant affiliations or financial involvement with any organization or entity with a financial interest in or financial conflict with the subject matter or materials discussed in the manuscript. This includes employment, consultancies, honoraria, stock ownership or options, expert testimony, grants or patents received or pending, or royalties.

No writing assistance was utilized in the production of this manuscript.

References

Papers of special note have been highlighted as:

• of interest

- 1 Nieder C, Spanne O, Mehta MP, Grosu AL, Geinitz H. Presentation, patterns of care, and survival in patients with brain metastases: what has changed in the last 20 years? *Cancer* 117(11), 2505–2512 (2011).
- **Multi-institutional time-staggered analysis that shows that patterns of care in patients with brain metastases (BM) have changed significantly in the last 20 years.**
- 2 Eichler AF, Loeffler JS. Multidisciplinary management of brain metastases. *Oncologist* 12(7), 884–898 (2007).
- 3 Christiaans MH, Kelder JC, Arnoldus EP, Tijssen CC. Prediction of intracranial metastases in cancer patients with headache. *Cancer* 94(7), 2063–2068 (2002).
- 4 Davey P. Brain metastases: treatment options to improve outcomes. *CNS Drugs* 16(5), 325–338 (2002).
- 5 Tosoni A, Franceschi E, Brandes AA. Chemotherapy in breast cancer patients with brain metastases: have new chemotherapeutic agents changed the clinical outcome? *Crit. Rev. Oncol. Hematol.* 68(3), 212–221 (2008).
- 6 Gaspar LE, Scott C, Murray K, Curran W. Validation of the RTOG recursive partitioning analysis (RPA) classification for brain metastases. *Int. J. Radiat. Oncol. Biol. Phys.* 47(4), 1001–1006 (2000).
- 7 Sperduto PW, Berkey B, Gaspar LE, Mehta M, Curran W. A new prognostic index and comparison to three other indices for patients with brain metastases: an analysis of 1960 patients in the RTOG database. *Int. J. Radiat. Oncol. Biol. Phys.* 70(2), 510–514 (2008).
- 8 Nieder C, Marienhagen K, Geinitz H, Molls M. Validation of the graded prognostic assessment index for patients with brain metastases. *Acta Oncol.* 48(3), 457–459 (2009).
- 9 Sperduto PW, Kased N, Roberge D *et al.* Summary report on the graded prognostic assessment: an accurate and facile diagnosis-specific tool to estimate survival for patients with brain metastases. *J. Clin. Oncol.* 30(4), 419–425 (2012).
- 10 Arnold SM, Patchell RA. Diagnosis and management of brain metastases. *Hematol. Oncol. Clin. N. Am.* 15(6), 1085–1107 (2001).
- 11 Schellinger PD, Meinck HM, Thron A. Diagnostic accuracy of MRI compared with CCT in patients with brain metastases. *J. Neurooncol.* 44(3), 275–281 (1999).
- 12 Kaal EC, Taphoorn MJ, Vecht CJ. Symptomatic management and imaging of brain metastases. *J. Neurooncol.* 75(1), 15–20 (2005).
- 13 Ostergaard L, Hochberg FH, Rabinov JD *et al.* Early changes measured by magnetic resonance imaging in cerebral blood flow, blood volume, and blood–brain barrier permeability following dexamethasone treatment in patients with brain tumors. *J. Neurosurg.* 90(2), 300–305 (1999).
- 14 Vecht CJ, Hovestadt A, Verbiest HB, Van Vliet JJ, Van Putten WL. Dose–effect relationship of dexamethasone on Karnofsky performance in metastatic brain tumors: a randomized study of doses of 4, 8, and 16 mg per day. *Neurology* 44(4), 675–680 (1994).
- 15 Glantz MJ, Cole BF, Forsyth PA *et al.* Practice parameter: anticonvulsant prophylaxis in patients with newly diagnosed brain tumors: report of the Quality Standards Subcommittee of the American Academy of Neurology. *Neurology* 54(10), 1886–1893 (2000).
- 16 Mikkelsen T, Paleologos NA, Robinson PD *et al.* The role of prophylactic anticonvulsants in the management of brain metastases: a systematic review and evidence-based clinical practice guideline. *J. Neurooncol.* 96(1), 97–102 (2010).
- 17 Tosoni A, Ermani M, Brandes AA. The pathogenesis and treatment of brain metastases: a comprehensive review. *Crit. Rev. Oncol. Hematol.* 52(3), 199–215 (2004).
- 18 Kalkanis SN, Kondziolka D, Gaspar LE *et al.* The role of surgical resection in the management of newly diagnosed brain metastases: a systematic review and evidence-based clinical practice guideline. *J. Neurooncol.* 96(1), 33–43 (2010).
- 19 Mintz AH, Kestle J, Rathbone MP *et al.* A randomized trial to assess the efficacy of surgery in addition to radiotherapy in patients with a single cerebral metastasis. *Cancer* 78(7), 1470–1476 (1996).
- 20 Patchell RA, Tibbs PA, Walsh JW *et al.* A randomized trial of surgery in the treatment of single metastases to the brain. *N. Engl. J. Med.* 322(8), 494–500 (1990).
- **In this trial patients with single BM who receive the association of surgery and radiotherapy have fewer recurrences of cancer in the brain, and have a better quality of life than similar patients treated with radiotherapy alone.**
- 21 Vecht CJ, Haaxma-Reiche H, Noordijk EM *et al.* Treatment of single brain metastasis: radiotherapy alone or combined with neurosurgery? *Ann. Neurol.* 33(6), 583–590 (1993).
- 22 Warnick RE, Darakchiev BJ, Breneman JC *et al.* Stereotactic radiosurgery for patients with solid brain metastases: current status. *J. Neurooncol.* 69, 125–37 (2004).
- 23 Linskey ME, Andrews DW, Asher AL *et al.* The role of stereotactic radiosurgery in the management of patients with newly diagnosed brain metastases: a systematic review and evidence-based clinical practice guideline. *J. Neurooncol.* 96(1), 45–68 (2010).
- 24 Nieder C, Grosu AL, Gaspar LE. Stereotactic radiosurgery (SRS) for brain metastases: a systematic review. *Radiat. Oncol.* 9, 155 (2014).

- 25 Gerosa M, Nicolato A, Foroni R. The role of gamma knife radiosurgery in the treatment of primary and metastatic brain tumors. *Curr. Opin. Oncol.* 15(3), 188–196 (2003).
- 26 Peterson HE, Larson EW, Fairbanks RK *et al.* Gamma knife treatment of brainstem metastases. *Int. J. Mol. Sci.* 15(6), 9748–9761 (2014).
- 27 Andrews DW, Scott CB, Sperduto PW *et al.* Whole brain radiation therapy with or without stereotactic radiosurgery boost for patients with one to three brain metastases: Phase III results of the RTOG 9508 randomised trial. *Lancet* 363, 1665–72 (2004).
- 28 Shaw E, Scott C, Souhami L *et al.* Single dose radiosurgical treatment of recurrent previously irradiated primary brain tumors and brain metastases: final report of RTOG protocol 90–05. *Int. J. Radiat. Oncol. Biol. Phys.* 47(2), 291–298 (2000).
- 29 Mehta MP, Tsao MN, Whelan TJ *et al.* The American Society for Therapeutic Radiology and Oncology (ASTRO) evidence-based review of the role of radiosurgery for brain metastases. *Int. J. Radiat. Oncol. Biol. Phys.* 63(1), 37–46 (2005).
- 30 Patchell RA, Tibbs PA, Regine WF *et al.* Postoperative radiotherapy in the treatment of single metastases to the brain: a randomized trial. *JAMA* 280(17), 1485–1489 (1998).
- 31 Wiggenraad R, Verbeek-De Kanter A, Kal HB, Taphoorn M, Vissers T, Struikmans H. Dose-effect relation in stereotactic radiotherapy for brain metastases: a systematic review. *Radiother. Oncol.* 98(3), 292–297 (2011).
- 32 Pollock BE, Brown PD, Foote RL, Stafford SL, Schomberg PJ. Properly selected patients with multiple brain metastases may benefit from aggressive treatment of their intracranial disease. *J. Neurooncol.* 61(1), 73–80 (2003).
- 33 Kocher M, Soffietti R, Abacioglu U *et al.* Adjuvant whole-brain radiotherapy versus observation after radiosurgery or surgical resection of one to three cerebral metastases: results of the EORTC 22952–26001 study. *J. Clin. Oncol.* 29(2), 134–141 (2011).
- 34 Gaspar LE, Mehta MP, Patchell RA *et al.* The role of whole brain radiation therapy in the management of newly diagnosed brain metastases: a systematic review and evidence-based clinical practice guideline. *J. Neurooncol.* 96(1), 17–32 (2010).
- 35 Soffietti R, Kocher M, Abacioglu U *et al.* A European Organisation for Research and Treatment of Cancer Phase III trial of adjuvant whole-brain radiotherapy versus observation in patients with one to three brain metastases from solid tumors after surgical resection or radiosurgery: quality-of-life results. *J. Clin. Oncol.* 31(1), 65–72 (2013).
- 36 Tsao MN, Lloyd N, Wong RK *et al.* Whole brain radiotherapy for the treatment of newly diagnosed multiple brain metastases. *Cochrane Database Syst. Rev.* 4, CD003869 (2012).
- 37 Chang EL, Wefel JS, Hess KR *et al.* Neurocognition in patients with brain metastases treated with radiosurgery or radiosurgery plus whole-brain irradiation: a randomised controlled trial. *Lancet Oncol.* 10(11), 1037–1044 (2009).
- 38 Rades D, Haatanen T, Schild SE, Dunst J. Dose escalation beyond 30 grays in 10 fractions for patients with multiple brain metastases. *Cancer* 110(6), 1345–1350 (2007).
- 39 Conill C, Berenguer J, Vargas M *et al.* Incidence of radiation-induced leukoencephalopathy after whole brain radiotherapy in patients with brain metastases. *Clin. Transl. Oncol.* 9(9), 590–595 (2007).
- 40 Deangelis LM, Delattre JY, Posner JB. Radiation-induced dementia in patients cured of brain metastases. *Neurology* 39(6), 789–796 (1989).
- 41 Li J, Bentzen SM, Renschler M, Mehta MP. Regression after whole-brain radiation therapy for brain metastases correlates with survival and improved neurocognitive function. *J. Clin. Oncol.* 25(10), 1260–1266 (2007).
- 42 Mehta MP, Shapiro WR, Phan SC *et al.* Motexafin gadolinium combined with prompt whole brain radiotherapy prolongs time to neurologic progression in non-small-cell lung cancer patients with brain metastases: results of a Phase III trial. *Int. J. Radiat. Oncol. Biol. Phys.* 73(4), 1069–1076 (2009).
- 43 Walbert T, Gilbert MR. The role of chemotherapy in the treatment of patients with brain metastases from solid tumors. *Int. J. Clin. Oncol.* 14(4), 299–306 (2009).
- 44 Franciosi V, Cocconi G, Michiara M *et al.* Front-line chemotherapy with cisplatin and etoposide for patients with brain metastases from breast carcinoma, nonsmall cell lung carcinoma, or malignant melanoma: a prospective study. *Cancer* 85(7), 1599–1605 (1999).
- 45 Postmus PE, Smit EF, Berendsen HH, Sleijfer DT, Haaxma-Reiche H. Treatment of brain metastases of small cell lung cancer with teniposide. *Semin. Oncol.* 19(2 Suppl. 6), 89–94 (1992).
- 46 Bartolotti M, Franceschi E, Brandes AA. EGF receptor tyrosine kinase inhibitors in the treatment of brain metastases from non-small-cell lung cancer. *Expert Rev. Anticancer Ther.* 12(11), 1429–1435 (2012).
- 47 Avril MF, Aamdal S, Grob JJ *et al.* Fotemustine compared with dacarbazine in patients with disseminated malignant melanoma: a Phase III study. *J. Clin. Oncol.* 22(6), 1118–1125 (2004).
- 48 Cotto C, Berille J, Souquet PJ *et al.* A Phase II trial of fotemustine and cisplatin in central nervous system metastases from non-small cell lung cancer. *Eur. J. Cancer* 32A(1), 69–71 (1996).
- 49 Agarwala SS, Kirkwood JM, Gore M *et al.* Temozolomide for the treatment of brain metastases associated with metastatic melanoma: a Phase II study. *J. Clin. Oncol.* 22(11), 2101–2107 (2004).
- 50 Guerrieri M, Wong K, Ryan G, Millward M, Quong G, Ball DL. A randomised Phase III study of palliative radiation with concomitant carboplatin for brain metastases from non-small cell carcinoma of the lung. *Lung Cancer* 46(1), 107–111 (2004).
- 51 Verger E, Gil M, Yaya R *et al.* Temozolomide and concomitant whole brain radiotherapy in patients with brain metastases: a Phase II randomized trial. *Int. J. Radiat. Oncol. Biol. Phys.* 61(1), 185–191 (2005).
- 52 Antonadou D, Paraskevaidis M, Sarris G *et al.* Phase II randomized trial of temozolomide and concurrent radiotherapy in patients with brain metastases. *J. Clin. Oncol.* 20(17), 3644–3650 (2002).
- **In this Phase II trial, the combined chemo- and radio-therapy in patients with BM may improve response rate and progression-free survival, not overall survival.**
- 53 Korfel A, Thiel E. Chemotherapy of brain metastases. *Front. Radiat. Ther. Oncol.* 33, 343–348 (1999).
- 54 Auperin A, Arriagada R, Pignon JP *et al.* Prophylactic cranial irradiation for patients with small-cell lung cancer in complete remission: Prophylactic Cranial Irradiation Overview Collaborative Group. *N. Engl. J. Med.* 341(7), 476–484 (1999).
- 55 Papadatos-Pastos D, Banerji U. Revisiting the role of molecular targeted therapies in patients with brain metastases. *J. Neurooncol.* 105(3), 467–474 (2011).
- 56 Lin NU. Targeted therapies in brain metastases. *Curr. Treat. Options Neurol.* 16(1), 276 (2014).

- 57 Besse B, Lasserre SF, Compton P, Huang J, Augustus S, Rohr UP. Bevacizumab safety in patients with central nervous system metastases. *Clin. Cancer Res.* 16(1), 269–278 (2010).
- 58 De Braganca KC, Janjigian YY, Azzoli CG *et al.* Efficacy and safety of bevacizumab in active brain metastases from non-small cell lung cancer. *J. Neurooncol.* 100(3), 443–447 (2010).
- 59 Lu YS, Chen WW, Ling CH, Tseng LM, Yeh DC *et al.* Bevacizumab, etoposide, and cisplatin (BEEP) in brain metastases of breast cancer progressing from radiotherapy: results of the first stage of a multicenter Phase II study. *J. Clin. Oncol.* 30, Abstract 1079 (2012).
- 60 Lin NU, Gelman R, Younger J *et al.* Phase II trial of carboplatin (C) and bevacizumab (BEV) in patients (Pts) with breast cancer brain metastases (BCBM). *J. Clin. Oncol.* 31, Abstract 513 (2013).
- 61 Levy C, Allouache D, Lacroix J *et al.* REBECA: a Phase I study of bevacizumab and whole-brain radiation therapy for the treatment of brain metastasis from solid tumours. *Ann. Oncol.* 25 (12), 2351–2356 (2014).
- 62 Franceschi E, Bartolotti M, Poggi R, Di Battista M, Palleschi D, Brandes AA. The role of systemic and targeted therapies in brain metastases. *Expert Rev. Anticancer Ther.* 14(1), 93–103 (2014).
- 63 Margolin K, Ernstoff MS, Hamid O *et al.* Ipilimumab in patients with melanoma and brain metastases: an open-label, Phase 2 trial. *Lancet Oncol.* 13(5), 459–465 (2012).
- **This Phase II trial shows that the activity of ipilimumab is similar in patients with advanced melanoma with and without brain metastases.**
- 64 Gore ME, Hariharan S, Porta C *et al.* Sunitinib in metastatic renal cell carcinoma patients with brain metastases. *Cancer* 117(3), 501–509 (2011).
- 65 Novello S, Camps C, Grossi F *et al.* Phase II study of sunitinib in patients with non-small cell lung cancer and irradiated brain metastases. *J. Thorac. Oncol.* 6(7), 1260–1266 (2011).
- 66 Massard C, Zonierek J, Gross-Goupil M, Fizazi K, Szczylik C, Escudier B. Incidence of brain metastases in renal cell carcinoma treated with sorafenib. *Ann. Oncol.* 21(5), 1027–1031 (2010).
- 67 Ceresoli GL, Cappuzzo F, Gregorc V, Bartolini S, Crino L, Villa E. Gefitinib in patients with brain metastases from non-small-cell lung cancer: a prospective trial. *Ann. Oncol.* 15(7), 1042–1047 (2004).
- 68 Wu C, Li YL, Wang ZM, Li Z, Zhang TX, Wei Z. Gefitinib as palliative therapy for lung adenocarcinoma metastatic to the brain. *Lung Cancer* 57(3), 359–364 (2007).
- 69 Welsh JW, Komaki R, Amini A *et al.* Phase II trial of erlotinib plus concurrent whole-brain radiation therapy for patients with brain metastases from non-small-cell lung cancer. *J. Clin. Oncol.* 31(7), 895–902 (2013).
- **In this Phase II trial, erlotinib was well tolerated in combination with whole-brain radiation therapy, with a favorable objective response rate regardless of EGFR status.**
- 70 Altavilla G, Arrigo C, Santarpia MC *et al.* Erlotinib therapy in a patient with non-small-cell lung cancer and brain metastases. *J. Neurooncol.* 90(1), 31–33 (2008).
- 71 Paz-Ares L, Sanchez JM, Garcia-Velasco A *et al.* A prospective Phase II trial of erlotinib in advanced nonsmall-cell lung cancer (NSCLC) patients with mutations in the tyrosine kinase (TK) domain of the epidermal growth factor receptor (EGFR). *J. Clin. Oncol.* 24 (369s), Abstract 7022 (2006).
- 72 Rosell R, Carcereny E, Gervais R *et al.* Erlotinib versus standard chemotherapy as first-line treatment for European patients with advanced EGFR mutation-positive non-small-cell lung cancer (EURTAC): a multicentre, open-label, randomised Phase 3 trial. *Lancet Oncol.* 13(3), 239–246 (2012).
- 73 Lukas RV, Lesniak MS, Salgia R. Brain metastases in non-small-cell lung cancer: better outcomes through current therapies and utilization of molecularly targeted approaches. *CNS Oncology* 3(1), 61–75 (2014).
- 74 Musolino A, Ciccolallo L, Panebianco M *et al.* Multifactorial central nervous system recurrence susceptibility in patients with HER2-positive breast cancer: epidemiological and clinical data from a population-based cancer registry study. *Cancer* 117(9), 1837–1846 (2011).
- 75 Braccini AL, Azria D, Thezenas S, Romieu G, Ferrero JM, Jacot W. Prognostic factors of brain metastases from breast cancer: impact of targeted therapies. *Breast* 22(5), 993–998 (2013).
- 76 Lin NU, Carey LA, Liu MC *et al.* Phase II trial of lapatinib for brain metastases in patients with human epidermal growth factor receptor 2-positive breast cancer. *J. Clin. Oncol.* 26(12), 1993–1999 (2008).
- 77 Lin NU, Eierman W, Greil R *et al.* Randomized Phase II study of lapatinib plus capecitabine or lapatinib plus topotecan for patients with HER2-positive breast cancer brain metastases. *J. Neurooncol.* 105(3), 613–620 (2011).
- 78 Bachelot T, Romieu G, Campone M *et al.* Lapatinib plus capecitabine in patients with previously untreated brain metastases from HER2-positive metastatic breast cancer (LANDSCAPE): a single-group Phase 2 study. *Lancet Oncol.* 14(1), 64–71 (2013).
- **Phase II study that showed the efficacy of capecitabine–lapatinib combination against BM before radiotherapy.**
- 79 Rochet NM, Dronca RS, Kottschade LA *et al.* Melanoma brain metastases and vemurafenib: need for further investigation. *Mayo Clin. Proc.* 87(10), 976–981 (2012).
- 80 Dummer R, Rinderknecht J, Goldinger SM *et al.* An open-label pilot study of vemurafenib in previously treated metastatic melanoma patients with brain metastases. *J. Clin. Oncol.* 29(Suppl.), Abstract 8548 (2011).
- 81 Long GV, Kefford RF, Carr PJA *et al.* Phase 1/2 study of GSK2118436, a selective inhibitor of V600 mutant BRAF kinase: evidence of activity in melanoma brain metastases (LBA27). *Ann. Oncol.* 21, Abstract LBA27 (2010).