

# Interposition Arthroplasty Versus Hematoma and Distraction for the Treatment of Osteoarthritis of the Trapeziometacarpal Joint

Massimo Corain, Nicola Zampieri\*, Raffaele Mugnai, Roberto Adani

*Departments of Hand Surgery, \*Surgical Sciences, University Hospital of Verona, Verona, Italy*

**Background:** Various surgical techniques were reported with excellent result for the treatment of trapeziometacarpal joint arthritis. However, the best treatment option was not defined yet.

**Methods:** This randomized prospective study compared the result of two surgical techniques: tendon interposition arthroplasty (64 patients) and K. wire distraction (56 patients) after trapeziectomy for stage 3 or 4 osteoarthritis of the trapeziometacarpal joint.

**Results:** After a mean follow-up period of 6.8 (range, 3-10) years it was possible to observe a higher rate of pain relief following trapeziectomy with K. wire suspension, but no significant differences in strength, range of motion and DASH score between the two groups. On lateral unloaded radiographs the height of the space between the base of the thumb metacarpal and the scaphoid showed a mean value of 6.5 mm for both groups; the average distance between the metacarpal base and the trapezium was not statistically significant in the two groups. Complications were observed only in patients treated with trapeziectomy and interposition arthroplasty and were represented by tendinitis of the FCR in 15% of cases.

**Conclusions:** We demonstrate that the trapezium excision and bone space distraction technique requires a smaller incision, a shorter surgical time, an easier surgical technique, and a less painful recovery, maintaining overlapping levels of functional restore.

**Keywords:** *Arthroplasty, Hematoma, Trapeziometacarpal joint arthritis, Trapeziectomy*

## INTRODUCTION

Different authors described several options for the treatment of osteoarthritis of the trapeziometacarpal joint during the years. The most of the techniques tend to remove the conflict between the two arthritic surfaces of the joint; Gervis<sup>1)</sup> in 1949 reported a simple excision of the trapezium registering a remarkable reduction of pain. Other surgical procedures include fusion, trapeziectomy combined with interposition arthroplasty<sup>2-4)</sup> and total

joint replacement.<sup>5)</sup>

We considered that what is really important is to avoid that the degenerated trapeziometacarpal joint moves causing pain and therefore loss of strength. For this reason trapeziectomy is the way we prefer but we considered different ways to maintain the first metacarpal height to the scaphoid, important aspect for force restoring.

The aim of this study is to compare midterm follow-up results of two different techniques: trapeziectomy with tendon interposition arthroplasty and trapeziectomy with K. wire distraction.

## METHODS

Between January 2003 and January 2010 a prospective study was carried out using two different surgical techniques to treat osteoarthritis of the trapeziometacar-

Received: Jun. 4, 2015; Revised: Nov. 4, 2015; Accepted: Nov. 8, 2015

Correspondence to: Roberto Adani

Department of Surgical Sciences, University Hospital of Verona, U.O.C. di Chirurgia della Mano e Microchirurgia, Policlinico G.B.Rossi, Verona-Italy  
Tel: +39-45-8124473, Fax: +39-45-8124836

E-mail: roberto.adani@ospedaleuniverona.it

pal joint in two groups of patients. Group 1: interposition arthroplasty using abductor pollicis longus (APL) as proposed by Sigfusson and Lundborg;<sup>4)</sup> Group 2: temporary K. wire distraction after trapeziectomy as suggested by Kuhns et al.<sup>2,3,6)</sup>

Patients were randomized into one of the two homogeneous groups using a computer database program. The following inclusion criteria were created for the study: no previous surgeries affecting the same arm; no diabetes or connective tissues disorders; symptomatic stage 3 or 4 osteoarthritis according to the Eaton classification.<sup>7)</sup> Patients with rheumatoid arthritis, previous hand surgery, previous bone fracture at same side of upper limb were excluded.

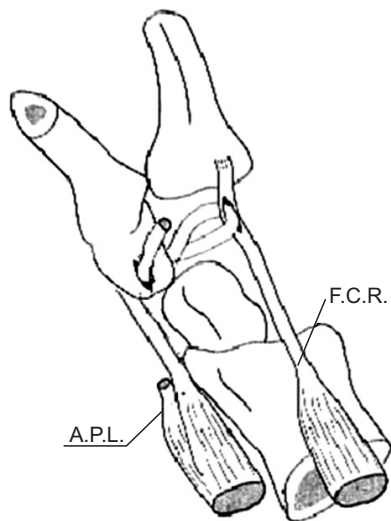
Group 1 had an average age at surgery of 61.5 years and a sex distribution of 53 (83%) female and 11 (17%) male; Group 2 had a 63.5 average age and a sex distribution of 41 (73%) female and 15 (27%) male.

### Surgical techniques and groups

All surgical procedures were performed by two different surgeons with level of experience IV according to the expertise scales.<sup>8)</sup> Each surgeon performed both procedures during the study.

Group 1 received trapeziectomy and interposition arthroplasty using APL.<sup>4)</sup> After surgery a splint was used for 3 weeks to hold the joint protected in opposition and light abduction.

Also Group 2 received trapeziectomy and the first metacarpal was stabilized using a K. wire (1.5 mm)

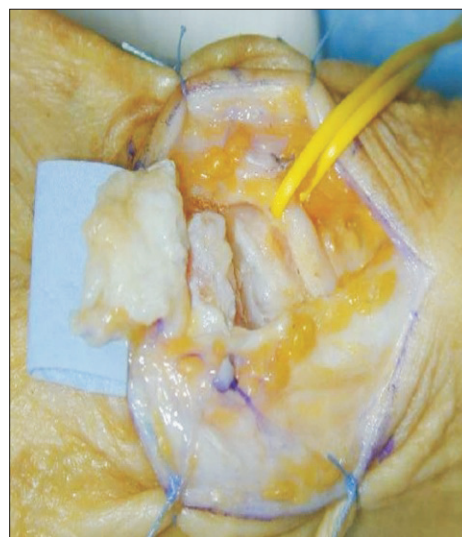

**Fig. 1.** Tenosuspension technique - the strip of the APL dissected proximally is used to stabilize the first metacarpal. The strip is passed through the radial flexor tendon and anchored to the U-shaped capsular flap.

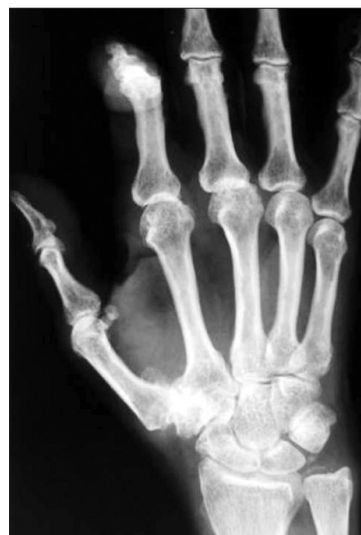placed between the thumb and the index finger metacarpals to hold its base at the level of the base of the index finger metacarpal (Fig. 1-5). A thumb spica splint was used for 3 weeks to maintain the correct position. The K. wire was then removed 4 weeks after surgery.

### Assessment

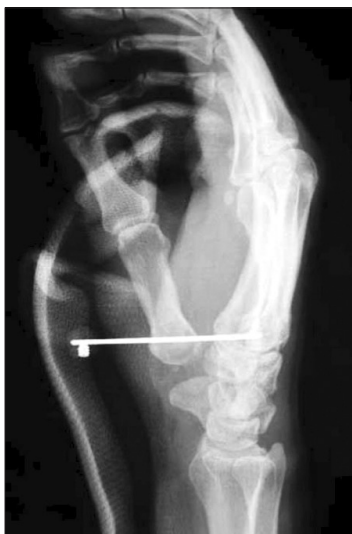All the patients included were evaluated during the usual checks in the first post-operative month for dressing and K. wire removal; than after 3 and 12 months post-operative with X-Rays check. In 2013 we revised all the patients enrolled at an average 6.8 years follow-



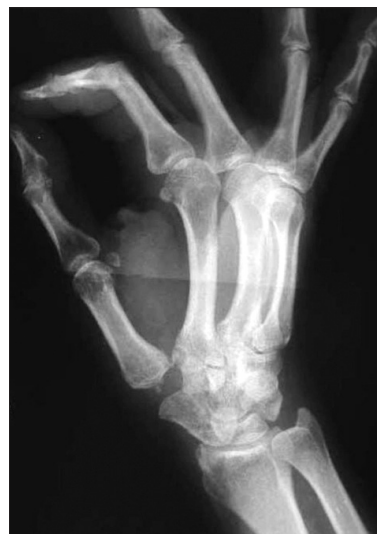**Fig. 2.** U-shaped incision prepared for the surgical procedure: abductor pollicis longus dissected proximally at the snuffbox.



**Fig. 3.** Clinical case 1- pre-op x-Ray.



**Fig. 4.** Clinical case 1- post-op x-Ray - see K wire position in light distraction (usually a temporary rolled wet gauze 5 x 5 cm is placed between the metacarpal and the scaphoid after trapeziectomy with K wire insertion).



**Fig. 5.** post-op x-Ray follow-up at 5.5 years.

up (range, 3-10 years). The mean follow-up of the two groups was similar; in particular 7 years (range, 3-10 years) for the group treated with trapeziectomy and interposition arthroplasty, and 6.6 years (range, 3-10 years) for the group treated with trapeziectomy with K. wire suspension.

We considered an objective evaluation to register range of motion (Kapandji test) and grip strength tests (Jamar test); three pinch tests were used to assess strength with a finger dynamometer: key test; tip to tip test, tripod test. For a subjective evaluation a visual analogue scale (VAS 0-10) and DASH score (score 1-100) were administered. The maintained scaphometacarpal gap was measured with x-ray imaging (Fig. 5).

The diagnosis of FRC tendinitis was based on clinical signs (pain elicited with passive extension and active flexion of the wrist against resistance, slight swelling and tenderness over the tendon at the wrist) and confirmed with ultrasound or magnetic resonance imaging.

#### Statistical analysis

Statistical analysis was performed using the student t-test, chi-square and Fischer exact tests where indicated. Significance value was set at  $p < 0.05$ . The analysis was conducted with the Statistical Package for Social Sciences (SPSS) software version 15 for Windows SPSS Inc., Chicago, USA. Approval to carry out the study was obtained from the local Ethics Committee.

## RESULTS

There were 120 patients enrolled in the study with a mean age of 63 (range 45-77) years, 64 patients in Group 1 and 56 in Group 2. The demographic characteristics of the two groups were comparable for sex and age. The mean preoperative pain in the two groups was similar:  $8.5 \pm 1.2$  according to the VAS for the patients of Group 1 and  $9.5 \pm 0.9$  for the patients of Group 2. The post-operative pain was  $2 \pm 0.4$  for the patients of Group 1 and  $0.9 \pm 0.3$  for the patients of Group 2; Group 2 had less pain respect to Group 1 ( $p < 0.05$ ); in Group 2 we didn't detect flexor carpi radialis (FCR) tendinitis as in 11 cases in Group 1. The Kapandji test showed 9 (SD 1.3) for Group 1 and 9 (SD 1.6) for Group 2. These results demonstrate no difference between the two techniques, in term of functional tests. Postoperative clinical data and results for the pinch and grip strength tests and the DASH score are reported in Table 1. These show no significant differences between the two groups (Table 1). On lateral unloaded radiographs the height of the space between the base of the thumb metacarpal and the scaphoid showed a mean value of 6.5 mm, range 4-12 mm, for both groups; the average distance between the metacarpal base and the trapezium was not statistically significant in the two groups. It was not possible to observe any increase in thumb metacarpal collapse onto the distal pole of the scaphoid (Fig. 5).

Complications: nine cases (15%) in Group 1 had complications with tendinitis of the FCR. No complications were reported in Group 2 ( $p < 0.05$ ); none had changes in sensibility after surgery.

**Table 1.** Clinical data of patients treated: explanation of tests per group

		Pain (VAS), mean (SD)	ROM (Kapandji test), mean (SD)	Valgus stress test, mean (SD)	Key test, mean (SD)	Tip to tip test, mean (SD)	Tripodal test, mean (SD)	Grip strength, mean (SD)	DASH, mean (SD)
Group 1	Preop	8.5 (1.2)	9 (1.3)	2 (0.3)	17.6 (4.9)	20.6 (7.8)	20.6 (1.9)	123.6 (12.7)	
	Postop	2 (0.4)			54.9 (4.9)	42.1 (2.9)	40.2 (10.7)	181.3 (1.7)	18.2 (1.2)
Group 2	Preop	9.5 (0.9)	9 (1.6)	2 (0.4)	16.7 (2.9)	15.3 (6.8)	18.6 (5.8)	109.8 (22.5)	
	Postop	0.9 (0.3)*			48 (4.9)	41.2 (8.8)	42.1 (14.7)	176.5 (6.8)	17 (1.9)

Statistical tests: Chi-square test for categorical variables and the student t tests for paired samples.

Group 1: trapeziectomy and interposition arthroplasty.

Group 2: hematoma technique.

\* $p < 0.05$ : the difference between pre and post operative pain in both groups was significant only in Group 2. No other differences were detected.

No cases of infection or migration of metacarpal to trapezium were detected.

## DISCUSSION

The most effective surgical treatment for trapeziometacarpal osteoarthritis is yet to be defined. Thumb metacarpal (TM) arthrodesis requires a prolonged period of immobilization to reach fusion and often results in a decreased range of motion if compared to other techniques.<sup>9)</sup> with the risk of developing scaphotrapeziotrapezoid and metacarpophalangeal arthritis.<sup>10)</sup> By observing the good clinical outcome of a failed arthrodesis of the thumb carpometacarpal joint, recently some authors have shown good results by deliberately creating a narrow pseudoarthrosis in the TM joint, although this is not recommended for stage IV.<sup>11)</sup>

TM joint arthroplasty is another option which aims at preserving the length of the thumb with soft tissue balancing but this technique is weighted down by its high rate of complications, such as radiographic subsidence into the trapezium, bone loosening, migration and dislocation, especially when using Moje Acamo CMC 1 implants and Elektra and Pyrocarbon implants.<sup>12-15)</sup> Good results were presented by Goubau et al.<sup>16)</sup> after joint replacement with ivory prosthesis (Memometal, Stryker Corporate) in 22 patients included in a 5-year prospective follow-up study. Similar positive experience was presented by Burke et al.<sup>17)</sup> with a retrospective study of 69 cases treated using Swanson Silastic trapezium replacement prosthesis with a mean follow-up of 7.7 years.

The resection-suspension arthroplasty and its variants gave generally good results,<sup>18-20)</sup> although with a significant incidence of specific complications, such as instability at the site of resection, complex regional pain syndrome (CRPS) and, in the Authors' experience, flexor carpi radialis tendinitis.

Vandenberghe et al.<sup>21)</sup> compared the results of the implantation of a cemented TM prosthesis (De La Caffiniere–Stryker, Howmedica; Roseland–DePuy) with trapeziectomy with ligament reconstruction and tendon interposition (LRTI) in 322 patients. The clinical findings showed no significant differences on impairment, pain, patient's satisfaction and disability so they concluded that LRTI should be the first choice in the treatment of basal joint osteoarthritis of the thumb.

Trapeziectomy reduces pain but the dispute is how to approach the scaphometacarpal space. Trapeziectomy alone as described by Gervis was modified adding a K. wire to stabilize the first metacarpal to avoid metacarpal collapse.<sup>22-24)</sup> This demonstrated to give no significant differences in pain, grip strength or scaphometacarpal distance if compared to a tenosuspension technique. It was also demonstrated that there is no correlation between the height of the scaphometacarpal space and the clinical outcome.<sup>24)</sup> In these cases a scaphometacarpal arthritis is possible, thus suggesting the use of tenosuspension,<sup>25)</sup> however this approach also demonstrated that collapse may cause greater postoperative problems. The method used in this study is the association with a K. wire to maintain the scaphometacarpal height although study results showed no loss of height of the first metacarpal nor cases of first metacarpal collapse in either group. This means that the fibrosis created in the scaphometacarpal 153 space in the trapezium excision and bone space distraction technique group allowed the formation of a cushion during the four-week period of metacarpal distraction with the K. wire.

Field and Buchanan as well as Vadstrup et al.<sup>26,27)</sup> confirmed the results by Downing and Davis on the scaphometacarpal height,<sup>24)</sup> showing that it did not influence grip or pinch strength, so they concluded that there was no benefit in the use of suspension with FCR sling after trapeziectomy.

In the present research, after a mean follow-up period of 6.8 years, it was possible to observe a higher rate of pain relief following trapeziectomy with K. wire suspension but no significant differences in strength, range of motion and DASH score between the two groups.

The complication rate for trapeziectomy and tenosuspension was higher than for trapeziectomy alone both in previous studies,<sup>26)</sup> and in the Authors' experience; moreover tenosuspension required longer operating time.

The current's study results are in line to the comparative studies reported in literature. Belcher and Nicholl compared the results of simple trapeziectomy with trapeziectomy combined with LRTI using the APL tendon in forty-three patients. At a mean 13 months of follow-up both groups expressed equal satisfaction with the operation and there were no significant differences between the two treatment groups. However LRTI lengthened the operation by approximately 15 minutes. Complications reported were represented by 3 cases of recurrent pain (1 case in the simple trapeziectomy group and 2 cases in the trapeziectomy combined with LRTI group); 2 cases of neuroma due to damage of the terminal branches of the radial nerve (1 case in the simple trapeziectomy group and 1 case in the trapeziectomy combined with LRTI group); moreover in the trapeziectomy combined with LRTI group 3 patients respectively reported instability, sensory loss on part of the dorsum of the thumb, and FRC rupture.<sup>28)</sup>

Davis et al. in 1997 performed a prospective randomized comparison of simple trapeziectomy and trapeziectomy either combined with palmaris lungus (PL) interposition or LRTI using FCR tendon in seventy-six consecutive women. The authors found that the results of these three techniques were indistinguishable at 3 months and 1 year regarding pain, thumb stiffness and weakness, functional disability, range of movement, hand grip and thumb pinch strength. Complications were reported respectively in 27% of cases in the simple trapeziectomy group; 26% in the trapeziectomy with PL interposition; 52% in the LRTI group. Complications were mainly represented by radial neuritis (5 cases in the simple trapeziectomy group), palmar median neuritis (1 case in the simple trapeziectomy group, and 2 cases in both trapeziectomy with PL interposition and LRTI groups), and FCR/PL pulling (2 cases in the trapeziectomy with PL interposition group, and 5 cases in the LRTI group).<sup>22)</sup>

More recently Davis et al. extended their study including a larger sample size represented by 162 women that underwent to 183 surgical procedures for painful

trapeziometacarpal osteoarthritis of Eaton and Littler grades 2 through 4. Each patient was randomized for treatment by either simple excision of the trapezium, excision of the trapezium and PL interposition or excision of the trapezium and LRTI using half the width of the FCR tendon. At the 1-year follow-up evaluation, pain levels and thumb strength were similar and not significantly different for each of the 3 surgeries at both the 3-month and 1-year assessments.<sup>23)</sup>

Possible complications reported in literature following simple excision of the trapezium are represented by cases of painful subluxation and degenerative change at the pseudarthrosis.<sup>25)</sup>

However retrospective surveys of the outcome of simple excision of the trapezium including 2 studies with mean follow-up of more than 5 years and 1 with a mean follow-up of 11 years have reported satisfactory results without the occurrence of these complications.<sup>29-31)</sup>

Field and Buchanan in 2007 performed a randomized single blind study including 65 patients with Eaton and Glickel Grade III or IV arthritis of the carpometacarpal joint that were randomised into either undergoing trapeziectomy alone (with no wiring) or a trapeziectomy with FCR suspension. This study showed no significant differences between the two groups in respect of grip strength, key pinch strength, tip pinch strength, and pain scores at a mean 1 year of follow-up. The complication rate was higher in the trapeziectomy + LRTI group, with more patients complaining of irritation over the wounds used to harvest the FCR tendon and of symptoms of CRPS Type 1. The trapeziectomy + LRTI group had a greater scaphometacarpal height, and this difference was maintained at 12 months of follow-up; however the clinical results of this study suggest that the scaphometacarpal height makes no difference to grip or pinch strength.<sup>26)</sup>

Recently Gangopadhyay et al. in 2012 compared the results of trapeziectomy alone, trapeziectomy with PL tendon interposition, and trapeziectomy with LRTI in 153 thumbs after a minimum follow-up of 5 years. Pain relief, grip strength, key and tip pinch strengths, and range of motion of the thumb did not differ among the 3 groups. Few complications persisted after 5 years, and these were distributed evenly among the 3 groups.<sup>32)</sup>

Our results support the concept that trapezium excision and bone space distraction technique without formal interposition or ligament reconstruction requires shorter surgical time and allows similar results in terms of pain relief, range of motion and grip strength when compared with the other previously reported techniques.

This study presents some limits and possible bias: two different surgeons performed the procedures with potentially different outcomes although the procedure was properly carried out in all cases; patients' professional activities were not considered in the study and these could have had an influence on the outcome. Stress radiographs could have shown differences in the scapho-metacarpal space but this assessment was not included in the study. It is interesting to report that about VAS score some patients had 10 value, and this data is correlated strongly with age of patients; older patients reported higher score respect to others, but without statistically differences.

In conclusion, this study reveals that trapeziectomy associated with stabilization of the first metacarpal with a K. wire gives better results than tenosuspension in terms of pain relief and rate of complications, while there are no significant differences on grip and pinch strength. For these reasons it is recommended that trapeziectomy with K. wire suspension is used instead of trapeziectomy and ligament reconstruction.

## REFERENCES

- Gervis WH. Excision of the trapezium for osteoarthritis of the trapezio-metacarpal joint. *J Bone Joint Surg Br.* 1949;31B(4):537-9.
- Fitzgerald BT, Hofmeister EP. Treatment of advanced carpometacarpal joint disease: trapeziectomy and hematoma arthroplasty. *Hand Clin.* 2008;24(3):271-6.
- Kuhns CA, Emerson ET, Meals RA. Hematoma and distraction arthroplasty for thumb basal joint osteoarthritis: a prospective, single-surgeon study including outcomes measures. *J Hand Surg Am.* 2003;28(3):381-9.
- Sigfusson R, Lundborg G. Abductor pollicis longus tendon arthroplasty for treatment of arthrosis in the first carpometacarpal joint. *Scand J Reconstr Surg Hand Surg.* 1991;25(1):73-7.
- Eecken SV, Vanhove W, Hollevoet N. Trapeziometacarpal joint replacement with the Arpe prosthesis. *Acta Orthop Belg.* 2012;78(6):724-9.
- Sandvall BK, Cameron TE, Netscher DT, Epstein MJ, Staines KG, Petersen NJ. Basal joint osteoarthritis of the thumb: ligament reconstruction and tendon interposition versus hematoma distraction arthroplasty. *J Hand Surg Am.* 2010;35(12):1968-75.
- Eaton RG, Glickel SZ, Littler JW. Trapeziometacarpal osteoarthritis: staging as a rationale for treatment. *Hand Clin.* 1987;3(4):455-71.
- Tang JB. Levels of experience of surgeons in clinical studies. *J Hand Surg Eur Vol.* 2009;34(1):137-8.
- Hartigan BJ, Stern PJ, Kiefhaber TR. Thumb carpometacarpal osteoarthritis: arthrodesis compared with ligament reconstruction and tendon interposition. *J Bone Joint Surg Am.* 2001;83-A(10):1470-8.
- Rizzo M, Moran SL, Shin AY. Long-term outcomes of trapeziometacarpal arthrodesis in the management of trapeziometacarpal arthritis. *J Hand Surg Am.* 2009;34(1):20-6.
- Rubino M, Civani A, Pagani D, Sansone V. Trapeziometacarpal narrow pseudarthrosis: a new surgical technique to treat thumb carpometacarpal joint arthritis. *J Hand Surg Eur Vol.* 2013;38(8):844-50.
- Hernández-Cortés P, Pajares-López M, Robles-Molina MJ, Gómez-Sánchez R, Toledo-Romero MA, De Torres-Urrea J. Two-year outcomes of Elektra prosthesis for trapeziometacarpal osteoarthritis: a longitudinal cohort study. *J Hand Surg Eur Vol.* 2012;37(2):130-7.
- Kaszap B, Daecke W, Jung M. High frequency failure of the Moje thumb carpometacarpal joint arthroplasty. *J Hand Surg Eur Vol.* 2012;37(7):610-6.
- Klahn A, Nygaard M, Gvozdenovic R, Boeckstyns MEH. Elektra prosthesis for trapeziometacarpal osteoarthritis: a follow-up of 39 consecutive cases. *J Hand Surg Eur Vol.* 2012;37(7):605-9.
- Maru M, Jettoo P, Turret L, Jones M, Irwin L. Thumb carpometacarpal osteoarthritis: trapeziectomy versus pyrocarbon interposition implant (Pi2) arthroplasty. *J Hand Surg Eur Vol.* 2012;37(7):617-20.
- Goubau JF, Goorens CK, Van Hoonacker P, Berghs B, Kerckhove D, Scheerlinck T. Clinical and radiological outcomes of the Ivory arthroplasty for trapeziometacarpal joint osteoarthritis with a minimum of 5 years of follow-up: a prospective single-centre cohort study. *J Hand Surg Eur Vol.* 2013;38(8):866-74.
- Burke NG, Walsh J, Moran CJ, Cousins G, Molony D, Kelly EP. Patient-reported outcomes after Silastic replacement of the trapezium for osteoarthritis. *J Hand Surg Eur Vol.* 2012;37(3):263-8.
- Burton RI, Campolattaro RM, Ronchetti PJ. Volar plate arthroplasty for osteoarthritis of the proximal joint: a preliminary report. *J Hand Surg Am.* 2002;27(6):1065-72.
- Nordback S, Erba P, Wehrli L, Raffoul W, Egloff DV. Trapeziectomy and tendon suspension with or without a Mitek anchor fixation in the thumb basal joint osteoarthritis. *J Hand Surg Eur Vol.* 2012;37(7):625-31.
- Salem H, Davis TRC. Six year outcome excision of the trapezium for trapeziometacarpal joint osteoarthritis: is it improved by ligament reconstruction and temporary Kirschner wire insertion? *J Hand Surg Eur Vol.* 2012;37(3):211-9.
- Vandenbergh L, Degreef I, Didden K, Fieus S, De Smet

- L. Long term outcome of trapeziectomy with ligament reconstruction/tendon interposition versus thumb basal joint prosthesis. *J Hand Surg Eur Vol.* 2013;38(8):839-43.
22. Davis TR, Brady O, Barton NJ, Lunn PG, Burke FD. Trapeziectomy alone, with tendon interposition or with ligament reconstruction? *J Hand Surg Br.* 1997;22(6):689-94.
23. Davis TRC, Brady O, Dias JJ. Excision of the trapezium for osteoarthritis of the trapeziometacarpal joint: A study of the benefit of ligament reconstruction or tendon interposition. *J Hand Surg Am.* 2004;29(6):1069-77.
24. Downing ND, Davis TRC. Trapezial space height after trapeziectomy: mechanism of formation and benefits. *J Hand Surg Br.* 2001;26(5):862-8.
25. Conolly WB, Rath S. Revision procedures for complications of surgery for osteoarthritis of the carpometacarpal joint of the thumb. *J Hand Surg Br.* 1993;18(4):533-9.
26. Field J, Buchanan D. To suspend or not to suspend: a randomized single blind trial of simple trapeziectomy versus trapeziectomy and flexor carpi radialis suspension. *J Hand Surg Eur Vol.* 2007;32(4):462-6.
27. Vadstrup LS, Schou L, Boeckstyns ME. Basal joint osteoarthritis of the thumb treated with Weilby arthroplasty: a prospective study on the early postoperative course of 106 consecutive cases. *J Hand Surg Eur Vol.* 2009;34(4):503-5.
28. Belcher HJ, Nicholl JE. A comparison of trapeziectomy with and without ligament reconstruction and tendon interposition. *J Hand Surg Br.* 2000;25(4):350-6.
29. Dhar S, Gray ICM, Jones WA, Beddow FH. Simple excision of the trapezium for osteoarthritis of the carpometacarpal joint of the thumb. *J Hand Surg Br.* 1994;19:485-8.
30. Gibbons CER, Gosal HS, Choudri AH, Magnussen PA. Trapeziectomy for basal thumb joint osteoarthritis: 3- to 19-year follow-up. *Int Orthop.* 1999;23:216-8.
31. Varley GW, Calvey J, Hunter JB, Barton NJ, Davis TRC. Excision of the trapezium for osteoarthritis at the base of the thumb. *J Bone Joint Surg Br.* 1994;76:964-8.
32. Gangopadhyay S, McKenna H, Burke FD, Davis TR. Five- to 18-year follow-up for treatment of trapeziometacarpal osteoarthritis: a prospective comparison of excision, tendon interposition, and ligament reconstruction and tendon interposition. *J Hand Surg Am.* 2012;37(3):411-7.