

**UNIVERSITÀ DEGLI STUDI DI NAPOLI “FEDERICO II”
FACOLTÀ DI MEDICINA E CHIRURGIA**



**SCUOLA DI DOTTORATO DI RICERCA IN
TERAPIE AVANZATE MEDICO-CHIRURGICHE
XXIX CICLO**

Direttore: Prof. Giovanni Di Minno

TESI DI DOTTORATO DI RICERCA

**Pituitary aggressive tumors and carcinomas:
epidemiological, molecular, clinical, radiological,
pathological and therapeutic characterization**

Relatore:
Ch.mo Prof.
Rosario Pivonello

Candidata:
Renata S. Auriemma

ANNO ACCADEMICO 2016-2017

INDEX

1. Introduction	Page 3
2. Aggressive pituitary tumors and carcinomas: classification, definition and epidemiology	
2.1 <i>Classification of pituitary tumors</i>	Page 7
2.2 <i>Definition of pituitary tumor aggressiveness</i>	Page 9
2.3 <i>Epidemiology of aggressive pituitary tumors and carcinomas</i>	Page 12
3. Molecular basis of pituitary tumor aggressiveness	Page 14
3.1 <i>Genetics</i>	Page 14
3.2 <i>Cell cycle regulators</i>	Page 16
3.3 <i>Growth factors</i>	Page 18
3.4 <i>Receptor modulation</i>	Page 19
3.5 <i>Cell signaling pathways</i>	Page 23
4. Treatment for pituitary aggressive tumors and carcinomas	Page 27
4.1 <i>Surgery</i>	Page 27
4.2 <i>Radiotherapy</i>	Page 29
4.3 <i>Chemotherapy</i>	Page 31
4.4 <i>Medical treatment: role and perspectives of target therapies</i>	Page 32
4.4.1 <i>Temozolomide</i>	Page 32
4.4.2 <i>Pasireotide</i>	Page 35
4.4.3 <i>Everolimus</i>	Page 37
5. Aim	Page 39
6. Patients and Methods	Page 40
6.1 <i>In vitro study</i>	Page 40
6.1.1 <i>Pharmacological compounds</i>	Page 41
6.1.2 <i>RNA isolation and RT-qPCR</i>	Page 42
6.1.3 <i>Pharmacological study</i>	Page 44
6.2 <i>In vivo study</i>	Page 45
6.2.1 <i>Study design</i>	Page 45
6.2.2 <i>Inclusion and exclusion criteria</i>	Page 46
6.2.3 <i>Patients</i>	Page 47

6.3 <i>Statistical Analysis</i>	Page 48
7. Results	Page 49
7.1 <i>In vitro study</i>	Page 49
7.1.1 <i>Characterization of SSTR, IGF1R, IRA, IRB and mTOR pathway components</i>	Page 49
7.1.2 <i>Functional study: DNA assay</i>	Page 49
7.1.3 <i>Functional study: Hormonal assay</i>	Page 50
7.2 <i>In vivo study</i>	Page 51
7.2.1 <i>Whole patient cohort</i>	Page 51
7.2.2 <i>Atypical tumors</i>	Page 54
7.2.3 <i>Carcinomas</i>	Page 56
7.2.4 <i>Non-atypical non-malignant vs atypical and malignant tumors: comparison study</i>	Page 58
8. Discussion	Page 63
9. Conclusion	Page 73
10. References	Page 75
Table 1	Page 97
Table 2	Page 98
Table 3	Page 99
Table 4	Page 100
Table 5	Page 101
Legend to figures	Page 102

1. INTRODUCTION

Pituitary tumors are common intracranial neoplasms, accounting for up to 15% of intracranial tumors at surgery and 6-23% at autopsy (1). They include 20% of all primary brain and central nervous system tumors and represent the second most common type by histology in young-adults (20-34 years) according to the Central Brain Tumor Registry of the USA (2). Pituitary adenomas are generally associated with hormone overproduction and/or compression signs and symptoms due to the impingement of adjacent structures. For years, pituitary adenomas have been considered a rare clinical entity on the basis of population studies reporting a prevalence of 1:3571 – 1:5263 or even lower (3, 4). A meta-analysis based on autopsy and radiology series (5) reported a high prevalence of pituitary adenomas in unselected general population (16.7%). More recently, a population-based study in the province of Liège, Belgium, reported a 3-5 times higher prevalence of clinically relevant pituitary tumors (1:1064) than previously estimated (6). The vast majority of pituitary tumors are non-invasive, benign, slow-growing lesions (7), but some might require careful follow-up: local invasion is reported in up to 40% of surgically treated

pituitary adenomas (8, 9), resistance to medical treatment or recurrence leading to multi-modal therapy is not unusual (8), and the time between surgery and recurrence can be short because of a high proliferation rate (8,9). Such tumors may correspond to "atypical adenomas" as defined by the World Health Organization (WHO) classification (10), mainly characterized by invasive growth, elevated mitotic index, Ki-67 labelling index >3 % and extensive nuclear reactivity for p53 (10). Conversely carcinomas, accounting for <1% of all pituitary tumors, can result in distant metastases (11, 12). Most are hormonally active tumors, mainly adrenocorticotropin (ACTH) and prolactin (PRL) secreting tumors. Prognosis is poor since both aggressive tumors and carcinomas commonly relapse after radical surgical excision with a scarce responsiveness to radiotherapy or chemotherapy, with specific target treatments being still lacking (9-12). Recent evidence has documented the successful use of temozolomide (TMZ), an alkylating chemotherapeutic agent, in the management of aggressive pituitary tumors and carcinomas (9, 13-27), with greater efficacy (up to 60%) being reported in aggressive PRL and ACTH-secreting pituitary tumors (9, 18).

On the other hand, somatostatin receptors (SSTR), mainly subtypes SSTR2 and SSTR5, are abundantly expressed on pituitary tumor

cells. However, an appreciable proportion of tumors fail in responding to conventional somatostatin analogs (SA) despite expressing high levels of one or more SSTR. A series of mechanisms have been hypothesized to explain the resistance to SA treatment. Among them, the recently identified two novel truncated *sstr5* variants, *sst5TMD5* and *sst5TMD4*, absent in normal pituitary but expressed in pituitary tumors, have been shown to reduce ability of the conventional SA octreotide (OCT) at normalizing hormone secretion in poorly responsive tumors *in vivo* (28, 29), also suggesting the potential use of *sst5TMD4* expression in surgically removed pituitary adenomas as a predictor of the subsequent response of different pituitary tumors to OCT therapy (28, 29). Recent *in vitro* studies have highlighted G protein-coupled receptor kinase (GRK) 2 and beta-arrestins as important players in driving SSTR desensitization and trafficking, with beta-arrestin 1 and GRK2 having a role in modulating GH secretion during SA treatment (30). The novel SA pasireotide (PAS) exhibits a high binding affinity for 4 out of 5 SSTR, mainly for SSTR2, SSTR3 and SSTR5 (31, 32). In primary cultures PAS potently suppresses GH, PRL and ACTH secretion (31, 32), and recent phase III clinical trials have demonstrated drug effectiveness in terms of hormonal excess

control and tumor shrinkage in patients with acromegaly and Cushing's disease (33-35), raising the question of whether it may represent a promising therapy also aggressive pituitary tumors and carcinomas.

More recently, the PI3K/Akt/mammalian target of rapamycin (mTOR) pathway has been proposed as a promising alternative target for treatment of aggressive pituitary tumors. The mTOR inhibitor everolimus (EVE) has been recently showed to exert an antineoplastic activity in several human neuroendocrine tumors, particularly when combined with SA (36-40). *In vitro* studies on both pituitary cell lines (41) and primary cultures (42, 43) have shown that EVE potently inhibits cell proliferation, reducing cell viability and promoting apoptosis, so suggesting that mTOR inhibitors might represent a promising alternative antiproliferative therapeutic option for pituitary aggressive tumors and carcinomas.

2. AGGRESSIVE PITUITARY TUMORS AND CARCINOMAS: CLASSIFICATION, DEFINITION AND EPIDEMIOLOGY

2.1 Classification of pituitary tumors

Pituitary adenomas are classified as microadenomas and macroadenomas by an arbitrary cutoff size of 10 mm, whereas tumors exceeding 40 mm in size are defined giant adenomas. Most of these tumors are noninvasive and benign in nature, and remain either within the sella or exhibit slow expansive growth onto surrounding tissues. A significant number of pituitary tumors, 25–55% depending on the criteria used, can show signs of invasion of dura, bone and/or surrounding anatomical structures (7, 44). However, these so-called “invasive” pituitary adenomas display benign behavior even in the presence of marked dural invasion and are not considered malignant by current definition. Truly malignant pituitary tumors (i.e., pituitary carcinomas) are only defined by the presence of cerebrospinal or systemic metastases and are exceedingly rare, with an incidence of <1% of symptomatic pituitary tumors (11, 12). The so-called “aggressive” adenomas lie between benign adenomas and malignant pituitary carcinomas and display a distinct clinical behavior with marked/gross invasion of nearby

anatomical structures, tendency towards resistance to conventional treatments and early postoperative recurrence.

In 2004, the WHO published a classification system for pituitary tumors based upon immunohistochemistry distinguishing them according to the presence or absence of secretory products along with other ultrastructural features (*Table 1*) (10). Apart from benign typical adenomas and pituitary carcinomas, this classification also identified “atypical” adenomas as tumors with atypical morphological features suggestive of an aggressive behavior, substantiated further by the presence of invasive growth, high mitotic index, Ki-67 labelling index >3%, as well as extensive nuclear staining for p53. This was the first attempt to identify pituitary tumors that have the potential to exhibit a distinctive course compared to benign adenomas, characterized by extensive growth and potentially malignant transformation (45, 46). However, this classification based on histopathological markers does not closely correlate with clinical behavior, as typical adenomas may occasionally exhibit early recurrence and resistance to therapy, whereas atypical adenomas are not always invasive, and they do not always exhibit recurrence. It is also acknowledged that atypical adenomas may share morphological and histological features with carcinomas, which are

distinctively characterized by cerebrospinal or distant metastases, poor prognosis and an overall fatal outcome. Therefore, the validity of the term “atypical adenoma” proposed by the 2004 WHO pituitary tumor classification system is now debatable, and tumors with a potential to display an aggressive clinical course need to be properly identified, introducing a new classification system incorporating novel molecular and genetic biomarkers that have recently been evaluated (47).

2.2 Definition of pituitary tumor aggressiveness

In contrast to the term “atypical adenomas” which was based on well-established proliferative and histological markers, the term “aggressive” pituitary tumor is not well-defined and is differently interpreted by individual clinicians. One aspect of aggressiveness is the invasive expansion into surrounding anatomical structures. The terms “aggressive” and “invasive” are often interchangeably and synonymously used in the literature; however, this is not always the case and creates considerable confusion as microscopic dura and cavernous sinus invasion and suprasellar expansion are commonly encountered in apparently benign adenomas (48). There is also great variation in the literature regarding the definition of

invasiveness based on imaging features, histological proof of sphenoid sinus mucosal invasion and/or intraoperative findings (49). Furthermore, the precise anatomical structure infiltrated is of importance since invasion of the clivus or sphenoid bone, as opposed to cavernous sinus invasion, is a more indicative feature of aggressive behavior (50). According to the Hardy's classification, for example, only grade III (focal bone erosion) and grade IV (extensive bone erosion including skull base) tumors are considered invasive (*Fig. 1*) (51). Moreover, as far as parasellar invasion of the cavernous sinuses is concerned, only grade III and IV adenomas are considered truly invasive according to Knosp's classification (*Fig. 1*) (52).

Another feature of aggressiveness characterizing the behavior of such tumors is recurrence. Patients with apparently cured benign typical adenomas may develop recurrence of their tumors after 5–10 years; however, early recurrence, within 6–12 months postoperatively, and the speed of tumor growth are more in favor of a tumor with aggressive behavior, although a definite time to tumor progression cutoff is yet to be established to distinguish these tumors from truly benign adenomas.

Additionally, patients with aggressive tumors usually exhibit resistance to conventional therapies, although early or late resistance to treatment may also occasionally occur in benign tumors, reflecting specific tumor receptor heterogeneity, tachyphylaxis and/or other unknown factors affecting drug efficacy.

Aggressive pituitary tumors are thought to have a greater chance of giving rise to pituitary carcinomas with cerebrospinal or systemic metastases. Pituitary carcinomas develop with equal frequency in both sexes at a mean age of 44 years, with a latency period of 7 years after the diagnosis of a pituitary tumor depending on tumor subtype (11, 12). Although *de novo* development of a malignant pituitary tumor cannot be excluded, in most case series pituitary carcinomas evolve from macroadenomas that exhibit invasive and proliferative features (53-55). This supports the view that pituitary carcinomas mainly arise from the transformation of initially benign adenomas that accumulate genetic aberrations over time exhibiting an aggressive behavior and eventually metastasizing (11, 12, 54, 55). However, as not all aggressive tumors transform into carcinomas, it is important to develop tools to identify the subset of tumors at higher risk and to apply close clinical and radiological

surveillance along with all available treatments early in the course of the disease in an attempt to minimize their morbidity.

2.3 Epidemiology of aggressive pituitary tumors and carcinomas

Epidemiological characteristics of aggressive pituitary tumors have been poorly investigated. In fact, based on the WHO definition of atypical adenomas, only four independent retrospective studies have reported on the prevalence of such tumors (45, 56-58). Particularly, Saeger et al. (56) reported 12 atypical tumors out of 451 total pituitary adenomas (2.7%) in the German Pituitary Tumor Registry. Scheithauer et al. (45) reported 6 atypical cases out of 78 total pituitary adenomas (14.7%), with the prevalence of atypical cases being similar to that of 14.8% reported by Zada et al. (57). In a more recent single-center study, 13 out of 146 pituitary adenomas (8.9%) were atypical, and 38.4% of them developed recurrence (58). Overall, by combining the findings of these studies, aggressive tumors account for approximately 6% of all pituitary adenomas. There are no further studies describing similar epidemiological data on aggressive pituitary tumors. This is mainly ascribable to the lack of a standardized definition of aggressive tumors based not only on

histological or proliferative markers, but also on the clinical course
and behavior.

3. MOLECULAR BASIS OF PITUITARY TUMOR AGGRESSIVENESS

A cross-talk between fine deregulation of intracellular pathways and complex micro-environmental factors have been hypothesized to be implicated in pituitary tumor pathogenesis. The signaling pathways of growth, angiogenesis and hormone secretion are intricate, and alterations upon node molecules can lead to aberrant proliferation.

3.1 Genetics

Most pituitary tumors are sporadic, but in approximately 5% of cases they arise in a familial setting as a component of genetic syndromes such as the McCune–Albright syndrome (59), the multiple endocrine neoplasia type 1 (MEN 1) (60), the Carney Complex (61), the familial isolated pituitary tumor (FIPA) (62) and, more recently described, the MEN1-like phenotype, namely MEN 4 (63). Specific genes have been identified to predispose to pituitary tumorigenesis, including *GNAS* (59), *MEN1* (60), *PRKAR1A* (61), *AIP* (64) and *CDKN1B* (63), but these are rarely involved in the pathogenesis of sporadic tumors. Very recently, a new genomic disorder, the X-linked acrogigantism (X-LAG), has been described (65) as

characterized by early childhood-onset gigantism resulting from GH excess and caused by microduplication on X chromosome, including the *GPR101* gene, that can be transmitted as a dominant trait (65).

Such genetic alterations may predispose pituitary tumors to display an “aggressive” behavior. Particularly, in the context of MEN 1 syndrome prolactinomas have been shown to be more aggressive than their sporadic counterparts (66, 67), although in a recent retrospective multicentre study (68) prolactinomas in patients with MEN1 have been found to respond well to medical treatment, and microadenomas to grow only occasionally and after many years without clinical consequences (68). *AIP*-mutated GH-secreting tumors have been demonstrated to occur at younger age, to be more invasive, to require more surgical interventions and to have lower decreases in GH and IGF-I levels and less tumor shrinkage while on SA (i.e., resistance to treatment with SA) as compared to *AIP*-non mutated somatotropinomas (69). Similarly, *AIP*-mutated prolactinomas have been found to occur generally in young males and to frequently require surgery or radiotherapy, as they are poor responsive or resistant to dopamine-agonists (DA) (69).

Several other genetic alterations have been implicated in pituitary tumorigenesis, including the increased expression of pituitary tumor

transforming gene (PTTG). Changes in PTTG expression may relate to pituitary tumor angiogenesis, invasiveness and aggressiveness (70-72). PTTG expression has been found correlated with Ki-67 expression in pituitary tumors (72). In addition, in hormone-secreting tumors, over-expression of PTTG has been reported to correlate with tumor invasiveness, since higher PTTG expression was observed in tumors that had invaded the sphenoid bone (stages III and IV) as compared with tumors that were confined to the pituitary fossa (stages I and II) (70).

Other well-known tumor suppressor genes in other neoplasms, such as *P53* and *RB* or common oncogenes, including those of the *Ras*-family, are only rarely involved in the development of pituitary tumors (73-78). Particularly, a mutation of the *H-Ras* gene at codon 12, Gly to Val, has been found in recurrent, highly invasive prolactinomas (74). A recent study showed the presence of *P53* gene mutations in pituitary carcinomas and confirmed their absence in pituitary adenomas (79). In carcinomas, a *P53* gene mutation was additionally related to p53 protein over-expression in tumor cells, which may be diagnostically helpful (79).

3.2 Cell cycle regulators

p21^{Cip1}, p57^{Kip2}, and p27^{Kip1}, the Cip/Kip proteins members of the cyclin-kinase inhibitor family of proteins, directly inhibit the action of the cyclin E/ cdk2 complex in inducing progression from G1 into S phase in the cell cycle (80), and are therefore defined as cyclin-dependent kinases inhibitors (CDKI). Epigenetic modulation of these genes, usually by promoter hypermethylation, result in CDKI under-expression, that in turn may predispose to pituitary tumorigenesis (81-84). Particularly, in rat GH3 cell line p27^{Kip1} has been found under-expressed by promoter hypermethylation (81, 82). In humans, both p21^{Cip1} and p27^{Kip1} have been reported to be under-expressed at protein level in all types of pituitary tumors (83, 84). Importantly, p27^{Kip1} expression has been found inversely related to the mitotic index Ki-67, resulting much lower in pituitary invasive adenomas and carcinomas (85).

Inappropriate methylation of CpG islands of other key cell cycle control and growth regulatory genes has been demonstrated. Such genes include the growth arrest and DNA damage-inducible protein gamma (GADD45G, 86), and death-associated protein kinase (DAPK, 87). GADD45G negatively regulates cell growth and is significantly under-expressed in GH-secreting and PRL-secreting pituitary tumors (88). The DAPK gene encodes for a calmodulin-

dependent serine/threonine kinase, which positively mediates programmed cell death: loss of DAPK expression, in association with either CpG island methylation or homozygous deletion, preferentially segregates with pituitary tumors that show an invasive phenotype (87).

3.3 Growth factors

Fibroblast growth factors (FGF) and fibroblast growth factor receptors (FGFR) are known to be important for a variety of biological processes, including mitogenesis, differentiation, development, angiogenesis and tumorigenesis (89). FGF-2 has been shown to be over-expressed in pituitary tumor cells, with higher levels in more aggressive tumors (90). The expression of the pituitary tumor-derived FGFR-4 isoform (ptd-FGFR4), a constitutively phosphorylated protein with transforming properties *in vitro* and *in vivo* (91), has been found stronger in macroadenomas as compared to microadenomas, and correlated with cell proliferation assessed by Ki-67 (92).

Angiogenesis is another essential process of solid tumors allowing their growth and determining tumor behaviour. Increased angiogenesis has been shown to be associated with the

development of metastases, poor prognosis, and reduced survival in several human tumors (93). However, the role of angiogenesis in the pituitary gland is yet to be completely clarified, since few studies have shown lower vascularisation in pituitary tumors compared with the normal gland, with discordant results (94-97). Moreover, the expression of VEGF and its receptor has been recently reported to differ between pituitary histological subtypes (98). VEGF expression has been found related to suprasellar extension, being more expressed on tumors with extrasellar growth than intrasellar ones (98), so suggesting the expression of VEGF and its receptor (VEGF-R) as marker for poor outcome after partial tumor resection.

3.4 Receptor modulation

SSTR and dopamine receptors (DR) are abundantly expressed in pituitary normal and tumoral cells and have been highlighted as two critical regulators involved in the negative control of hormonal secretion and tumor shrinkage (99-105). SSTR and DR are $G_{\alpha i}$ -protein coupled that inhibit adenylate cyclase activity and cAMP production and reduce intracellular calcium concentration and calcium flux oscillations. Upon receptor stimulation, somatostatin and the SA octreotide LAR (LAR), lanreotide (LAN), and PAS on

one hand, and dopamine and the DA bromocriptine and cabergoline on the other hand, suppress hormonal secretion from pituitary tumors (99-102). Moreover, SA and DA are known to induce tumor shrinkage of pituitary adenomas (103-105).

The SSTR subtypes 1-5 are encoded by genes localized on different chromosomes (106-110). However, two forms of the SSTR2 receptor, SSTR2A and SSTR2B, are generated via alternative splicing; these two isoforms only differ in the length of the cytoplasmic tail of the receptors (110).

Several functional genetic aberrations associated with GH and IGF1 changes have been described for SSTR5. LAR-resistant acromegaly has been described in a patient with a single germline mutation at Arg240Trp that attenuated somatostatin 28-inhibition of cAMP accumulation and MAPK pathway activation, as well as increased cell proliferation (111). SSTR5 single nucleotide polymorphisms (SNPs) at C1004T and T461C have been associated with GH and IGF-I levels (i.e., disease severity) in patients with acromegaly (112). SSTR5 SNP at the 663T allele has been reported associated with a younger age at diagnosis of acromegaly, increased body mass index, more frequent adenoma resection, and a lack of tumor shrinkage after SA therapy (113).

SSTR5 mRNA splice variant isoforms, namely sst5TMD5 and sst5TMD4, are truncated at the 5th or 4th transmembrane domain in a variety of pituitary tumors, but mostly in somatotroph adenomas (85% of tumors) (28). Particularly, sst5TMD4 expression has been shown to negatively correlate with ability of OCT or SST5- selective SA therapy to reduce GH levels (29), suggesting sst5TMD4 is a marker of resistance to SA (28, 29). sst5TMD4 mRNA and protein levels positively correlated with pituitary tumor invasiveness, and inversely with age or LAR inhibition of GH and IGF-I, so to confer aggressive features to somatotroph adenomas (114). Genetic SSTR5 aberration in somatotroph adenomas may contribute to tumor responsiveness to SA therapy and tumor growth, but the extent of this effect remains unclear.

Beta-arrestins 1 and 2 and the G protein-coupled receptor kinase (GRK) 2, intracellular molecules involved in membrane receptor phosphorylation, desensitization, and trafficking, have been recently pointed out as a possible modulator of ligand activated-receptor response (30). Particularly, lower beta-arrestin 1 and higher GRK2 mRNA expression have been shown to correlate with a greater GH suppression after treatment with OCT either in primary cultures of GH-secreting adenomas and *in vivo* (30). Similarly, beta-arrestin 1

and 2 mRNA have been found significantly lower in adenoma tissues from acromegalic patients who achieved IGF-I normalization and complete biochemical control after long-term treatment with SA (115). These findings suggest that beta-arrestins 1 GRK2 may play a role in modulating responsiveness to SA treatment.

Five DR subtypes are encoded by five separate genes, D1DR to D5DR. However, as for SSTR, alternative splicing of dopamine receptor subtype 2 (D2DR) generates two variants: long (D2DRL) and short (D2DRS) (116). The coding sequences of D2DRS and DRD2L are similar, but the former lacks exon 5 (116).

Filamin A (FLNA), a widely expressed large cytoskeleton protein, has been demonstrated to modulate responsiveness to medical treatment with DA in prolactinomas, as it plays a key role in D2DR signaling and cell surface expression (117). In primary cultures of PRL-secreting tumors, FLNA silencing in DA-responsive prolactinomas resulted in 60% reduction of D2DR expression and abrogation of DA-induced inhibition of prolactin release and antiproliferative signals, these results being replicated also in the MMQ cell line which endogenously express FLNA and D2R (117). On the other hand, FLNA overexpression in DA-resistant prolactinomas restored D2DR expression and prolactin

responsiveness to DA (117). These findings suggested that in prolactinomas resistance to DA may be related to the reduction of FLNA expression (117). More recently, FLNA has been demonstrated to be involved also in SSTR2 stabilization and signaling in both primary cultures of GH-secreting tumors and GH3 cell lines, playing both a structural and scaffold functional role (118).

3.5 Cell signaling pathways

Abnormalities in cell signalling pathways are frequently seen in pituitary adenomas. Clarifying the role of the particular component involved in regulation of these pathways may represent potential selective targets for therapy, identifying the locus or loci of the initiating abnormalities. The serine–threonine kinases, including key mediators of tumorigenesis such as Raf, mitogen activated protein kinase (MAPK) cascades and Akt/protein kinase B, appear to be of interest.

The PI3K/Akt/mTOR pathway is altered in many tumors (119), including pituitary adenomas (120). Phosphatidylinositol 3-kinase (PI3K) is activated as a result of the ligand-dependent activation of tyrosine kinase receptors, G-protein-coupled receptors or integrins. Receptor-independent activation of PI3K can also occur in cells

expressing a constitutively active Ras protein (121-123). The best-characterised phosphorylation target of PI3K is Akt, also known as protein kinase B, resulting in the phosphorylation of a host of other proteins that affect cell growth, cell cycle entry and cell survival (124). Akt phosphorylation activates a serine–threonine kinase mTOR (mammalian target of rapamycin), which activates 40S ribosomal protein S6 kinase (p70S6K) and inactivates 4E-binding protein (4EBP1) (124). The tuberous sclerosis complex (TSC), which includes TSC1 and TSC2 and mediates between PI3K/Akt and mTOR, inhibits mTOR (125). Mitogenic stimuli activating Akt can directly phosphorylate TSC2, causing destabilisation of TSC2 and inhibiting the formation of the TSC1/2 complex, leading to an increase of mTOR activity (125). 4E-BP1 inhibits the initiation of translation of mRNA for many factors, including c-myc and cyclin D1, through its association with eIF-4E (126, 127), and thus loss of the binding protein in response to mTOR activation will lead to enhanced proliferation. Akt is over-expressed (at both mRNA and protein levels) and over-activated (through phosphorylation) in all pituitary tumors, mainly non-functioning pituitary adenomas (NFA) (128). This up-regulation of Akt will increase the phosphorylation of p27^{Kip1}, preventing its nuclear import and causing changes in the cell

cycle (128). Therefore, changes in the cell cycle occurring in pituitary adenomas may be secondary to activation of the Akt pathway (128). Noteworthy, constitutive activation of the TSC1/2 complex, as occurs in tuberous sclerosis, appears to be associated with a risk of neuroendocrine tumorigenesis, especially insulinomas and ACTH-secreting pituitary tumors (129).

The Raf/MEK/ERK pathway is a hierarchical cascade originating at the cell membrane with receptors for mitogens or growth factors, which recruit, via adapter proteins and exchange factors, the small guanosine triphosphatase Ras (119). Activated Ras in turn activates the serine–threonine kinase Raf (MAPKKK). Raf activates the mitogen-activated protein kinase kinase (MAPKK) MEK, which in turn phosphorylates and activates the mitogen-activated protein kinase (MAPK, or ERK1 and ERK2), which translocates to the nucleus and trans-activates transcription factors, changing gene expression to promote growth and mitosis (130). This MAPK pathway activation causes phosphorylation and activation of ribosomal S6 kinase and transcription factors such as c-myc, Elk1, c-Fos and cyclin D1 (131, 132), similar to the Akt/mTOR cascade, and resulting in the activation of genes associated with proliferation (133) and leading to cell transformation (134). Over-activation of Akt

may also lead to activation of the b-catenin pathway, which has been implicated in pituitary tumorigenesis (135).

The most sensitive Raf, B-Raf, which is frequently mutated at the V600E position in melanomas and papillary thyroid cancer leading to constitutive activity, is not similarly mutated in sporadic pituitary adenomas, although it has been found over-expressed in pituitary adenomas, particularly NFA (136). MEK1/2 and its down-stream regulator ERK1/2 are also over-phosphorylated and hence over-activated in all types of pituitary adenomas, compared to normal pituitary (137). Therefore, in pituitary adenomas both the Raf/MEK/ERK and PI3K/Akt/mTOR pathways are up-regulated in their initial cascade, implicating a pro-proliferative signal derangement upstream to their point of convergence (137). Raf/MEK/ERK and PI3K/Akt/mTOR pathways have been also shown to play an important role either in malignant transformation and in drug resistance in endocrine cancer cells, such as breast and prostate cancer cells (138).

4. TREATMENT FOR PITUITARY AGGRESSIVE TUMORS AND CARCINOMAS.

Pituitary aggressive tumors and carcinomas are reportedly difficult to manage due to their size, invasiveness, rapid growth and high recurrence rate. Since clear-cut definition and reliable prognostic markers are lacking, such tumors are difficult to be identified at initial presentation, and therefore primary therapeutic approach is not different compared to other pituitary tumors, depending on the type of adenoma. Current therapeutic options include surgery, radiotherapy, and medical treatment. However, both aggressive tumors and carcinomas commonly relapse after radical surgical excision with a scarce responsiveness to radiotherapy or chemotherapy (9-12). The increasing evidence of the involvement of many molecular mechanisms in the pathogenesis of pituitary tumor aggressiveness or malignant transformation has raised the question of whether such pituitary tumors, similarly to other cancer types, may benefit from specific target therapies, which are drugs able to interfere with specific molecules involved in tumor cell growth and survival.

4.1 Surgery

Surgery represents the primary treatment for pituitary adenomas, also including aggressive tumors and carcinomas (19). In fact, medical treatments are often ineffective in controlling hormonal hypersecretion and/or tumor growth in such tumors. Hence, (re-) surgery appears a feasible treatment option for aggressive and/or recurrent tumors, although remission rates after repeated transsphenoidal surgery are much lower (139-141). In cases where tumors extend significantly into the suprasellar region, the transcranial approach may be advisable but the trans-sphenoidal or endoscopic approaches are also valid and can be used depending on the surgeon experience (50). Near-total surgical resection with no apparent remnant at postoperative imaging can be rarely achieved, as aggressive pituitary tumors tend to be infiltrative and recur over a relatively short time (27). Repeated pituitary tumor debulking surgeries can be performed to remove further emerging tumor tissue (142-144), albeit with less success, and increasing rate of complications such as worsened visual field, optic nerve palsy, meningitis, anterior pituitary deficiencies and diabetes insipidus (9), and can be combined with other therapeutic modalities such as systemic and/or radiological therapies to achieve tumor control (19).

4.2. Radiotherapy

Radiotherapy is usually reserved as a third-line therapy (after surgery and medical therapy) or for a residual tumor that is not surgically resectable. Therefore, radiotherapy is a valuable adjuvant therapy for aggressive tumors that cannot be controlled by other treatment modalities, mainly to prevent tumor regrowth in incompletely excised adenomas. Conventional external radiotherapy (CER) is advised when the tumor size exceeds 30 mm or when histological examination reveals heavy infiltration into surrounding tissues, whereas stereotactic radiosurgery (SR) is the preferred type of postoperative radiation therapy when the lesion is well demarcated and does not impinge the optic chiasm (145).

CER has been used in adjuvant settings to prevent tumor regrowth in large or partially removed pituitary tumors and for local control of expanding tumors, some of which were later proven to be aggressive pituitary tumors. CER efficacy ranges from 67 to 100% in several studies (145-147). CER has been shown to reduce recurrence of NFA remnants, particularly if administered immediately during the postoperative period (146), but its efficacy is often limited in aggressive tumors. However, after CER the most

common outcome is local tumor growth control, and only rarely tumor shrinkage has been reported (147).

SR with delivery of high-dose radiation in a single visit or fractionated radiotherapy (smaller fractions of radiation given over a period of 4–6 weeks) can also be applied if the tumor is adjacent to radiation-sensitive normal tissues. Techniques such as Gamma-Knife surgery, linear accelerator or Cyber-Knife can provide more precise targeting of the adenoma, offering better control of the dose of radiation received by adjacent structures, such as the pituitary stalk, pituitary gland, optic chiasm and cranial nerves in the cavernous sinus. Retrospective series with new SR methods have shown a similar efficacy as compared to CER (148, 149), with a tendency to achieve their effect slightly faster and with less frequent side effects, mainly pituitary deficiency (149).

Regardless from the type of radiotherapy, the amount of radiations that can be administered is limited by the risk of optic neuropathy, necrosis in the temporal lobe and other brain areas and the rare possibility of developing a secondary brain tumor. There has been also concern about the possible role of radiotherapy in the transformation or progression of pituitary adenomas to carcinomas following the report of the sarcomatous change induced by

radiotherapy on a pituitary adenoma (150). However, this is unlikely to be a common consequence in view of the large number of irradiated pituitary tumors and the small number of pituitary carcinomas (151).

4.3 Chemotherapy

Aggressive pituitary adenomas have relatively low proliferation indices and seem to display certain aspects of well-differentiated tumors, thus poorly responding to standard chemotherapy (152). The same rule applies to pituitary carcinomas despite their relatively higher proliferation indices; however, due to the rarity of these tumors, no randomized prospective studies of systemic chemotherapy have been conducted. Different cytotoxic chemotherapy protocols including procarbazine-etoposide-lomustine (153) and lomustine-doxorubicin (154) have been used in patients with aggressive pituitary tumors, with no clinically relevant effects in terms of control of tumor growth and hormone secretion. In a small series of 7 patients, including 3 with aggressive pituitary tumors and 4 with carcinomas, combination therapy with lomustine and 5-fluorouracil showed an overall poor response rate in terms of tumor

shrinkage, although temporary clinical responses were noticed in some patients (152). Noteworthy, chemotherapy regimens only partly change survival rate in such patients. In fact, only a few patients have survived for longer than 1 year after chemotherapy (152, 155). However, most patients with pituitary carcinomas and distant metastases who were still alive at last follow-up had received some form of chemotherapy (152, 155-157). This observation, together with the apparent response to chemotherapy of some patients with aggressive tumors with either regression or stabilization of the disease, may justify the early use of chemotherapy in patients with recurrent highly aggressive and potentially malignant tumors who have already received maximum therapy with surgery and radiotherapy (152). However, the lack of randomized studies makes chemotherapy poorly defined in pituitary aggressive tumors and carcinomas.

4.4 Medical treatment: role and perspectives of target therapies

4.4.1 Temozolomide

Since 2006, temozolomide (TMZ), originally approved for use in refractory glioblastoma multiforme, has been successfully used to

treat pituitary aggressive adenomas and carcinomas (13, 158-168). TMZ is an orally administered second generation alkylating agent, which exerts its action by attaching a methyl group to the O6 position of guanine bases causing mispair with thymine bases, DNA damage, proliferation arrest and cellular apoptosis. O6-methylguanine-DNA methyltransferase (MGMT) is a DNA repair enzyme that counteracts the effects of TMZ by removing alkylating adducts from DNA. TMZ can readily cross the blood-brain barrier, and its action is not cell cycle specific, meaning that it inhibits all stages of tumor cell growth, even in slow-growing tumors, such as pituitary tumors. Initial experience on the use of TMZ in pituitary aggressive tumors and carcinomas, mainly based on case reports or very small patient series, has documented an overall hormonal and tumoral response rate of approximately 69% in carcinomas and 60% in aggressive adenomas (13, 14, 17, 20). To date, eight independent studies have investigated the effects of TMZ in series including at least 5 patients with pituitary aggressive tumors or carcinomas (21, 23, 161-166). As shown in *Table 2*, combining data from these studies including overall 100 patients receiving 9-12 cycles of therapy, TMZ induced a complete or partial response in 42%, stabilization in 31% and progression in 31% (21, 23, 161-166).

Based on findings from re-operated patients, changes in histopathological and morphological features of tumors have been reported after TMZ treatment: tumor softening and friability have been noticed, making easier the resection at re-operation, and TMZ-treated tumors exhibited fewer mitoses, lower Ki-67, hemorrhage, necrosis, and focal fibrosis (167, 168). The DNA repair enzyme MGMT reverses the methylation caused by TMZ, being the major mechanism of resistance to TMZ treatment. A significant inverse correlation has found between the response to TMZ and MGMT expression, evaluated by immunohistochemistry (9, 23, 161, 163); however, the absence of MGMT expression was not always predictive of tumor response (23, 161). Conversely, MGMT promoter methylation in pituitary tumors has been shown to have poor prognostic value since methylated MGMT promoter was found in a similar proportion of TMZ-sensitive tumors and TMZ-resistant tumors (9). A clinically relevant suggestion proposed by Raverot et al. (23) is that 3 cycles of TMZ identify treatment-responsive patients, whereas after 3 cycles of TMZ non-responders do not benefit from additional cycles. It is currently unclear which regimen offers the best efficacy and which is associated with a reduced risk of secondary malignancy, such leukemia or lymphoma (18), and

there are scant data to support whether TMZ can be used alone or in combination with other medications such as PAS or capecitabine (14, 169, 170).

4.4.2 Pasireotide

SA are the mainstay of medical treatment for pituitary adenomas. The second-generation SA PAS exhibits a high binding affinity for 4 out of 5 SSTR, mainly for SSTR2, SSTR3 and SSTR5 (31, 32), and has been shown to exert antisecretory and antiproliferative effects on metastatic neuroendocrine tumors (NET) and pituitary adenomas (31-35, 171-180). Results of preclinical studies in NET have indicated PAS to reduce NET secretion and growth both *in vitro* and *in vivo* (173, 174), displaying an anti-proliferative activity higher than the first-generation SA OCT (175). In primary cultures of pituitary tumors PAS has been shown to potently suppress GH, PRL and ACTH secretion (31, 32), and cell viability (171). Recent phase III clinical trials have demonstrated PAS effectiveness in terms of hormonal excess control and tumor shrinkage in patients with acromegaly and Cushing's disease (33-35). Responsiveness to PAS has been found to persist over time both in GH-secreting and ACTH-secreting pituitary tumors (176-180). Moreover, in patients with

inadequately controlled acromegaly (35) PAS has been demonstrated to induce the achievement of complete disease control (i.e., GH and IGF-I normalization) in approximately 18% of cases after 24 weeks, as compared to none of the patients continuing treatment with first-generation SA LAR and LAN, suggesting that PAS provides superior efficacy compared with continued treatment with LAR or LAN, and could become the new standard pituitary-directed treatment in patients with acromegaly who are inadequately controlled by first generation SA (35). Such results, mainly in view of the effectiveness of PAS in resistant or poorly controlled acromegaly, have raised the question of whether it may represent a promising therapy also for pituitary aggressive tumors and carcinomas. A few reports have documented the efficacy of PAS in patients with pituitary aggressive tumors (165, 181-183) in terms of control of both hormonal hypersecretion and tumor growth, whereas the escape to treatment following an initial excellent response to PAS has been reported in a patient with an ACTH-secreting pituitary carcinoma metastatic to bone (183).

Some evidence also suggests the successful use of PAS in association to TMZ (170). Particularly, in a patient with ACTH-secreting pituitary carcinoma and widespread intracranial, spinal and

systemic metastases, PAS addition to TMZ induced the improvement of patient clinical status, and a reduction of ACTH levels (170). After 12 months of combination therapy a sustained tumor control was achieved and persisted upon monotherapy with PAS for more than 9 months thereafter (170), suggesting that combined treatment with TMZ and PAS might be promising in patients with metastatic pituitary carcinomas.

4.4.3 Everolimus

The mTOR inhibitor EVE, originally approved for the treatment of breast and renal cell cancers, has been shown to exert an antineoplastic activity in several human neuroendocrine tumors, particularly when combined with SA (36-40). As for many tumor types, the PI3K/Akt/mTOR pathway has been demonstrated to be overexpressed and activated also in human pituitary adenomas (128, 184). Thus, pituitary tumors may be sensitive to the anti-proliferative effects of mTOR inhibitors. *In vitro* studies on both pituitary cell lines (41) and primary cultures of pituitary tumors (42, 43) showed that EVE potently inhibits cell proliferation, reducing cell viability and promoting apoptosis, thus suggesting that EVE might represent a promising alternative anti-proliferative therapeutic option

for pituitary aggressive tumors and carcinomas. However, the experience with the clinical use of EVE in patients harbouring such tumors is controversial, and the impact on patient survival appears to be scant. In fact, two reports have described the anti-tumoral effects of EVE in two patients with metastatic ACTH-secreting pituitary carcinomas (185, 186), including one resistant to TMZ (185). In this latter patient, EVE has been associated with LAR, but combined therapy failed to control pituitary tumor growth and ACTH secretion, and the patient died 3 months after treatment discontinuation (185). Conversely, the former patient received RT and EVE, leading to clinical improvement and stability on MRI and PET for >6 months (186). However, the patient expired from widely metastatic disease (186).

5. AIM

To date, scant data are available about the epidemiological, clinical, radiological, and pathological characteristics, as well as about the molecular predictors of responsiveness to medical treatments, including the more recent target therapies, in patients with pituitary aggressive tumors and carcinomas.

Therefore, the main objectives of the current study were:

1. To investigate *in vitro* responsiveness to PAS and EVE, used as monotherapy or as combined treatment, in primary cultures of pituitary aggressive tumors.
2. To assess the clinical, hormonal, radiological, and pathological characteristics in patients with pituitary aggressive tumors and carcinomas, evaluated both during the active disease and/or after the disease remission.
3. To evaluate the incidence rates, tumor subtype, pathophysiological mechanisms, clinical characteristics, and the therapeutic approaches performed.
4. To allow a better standardization of the diagnosis and therapy of pituitary aggressive tumors and carcinomas.

6. PATIENTS AND METHODS

6.1 *In vitro* study

The *in vitro* study has included somatotroph tumors from patients undergoing trans-sphenoidal surgery at the Division of Neurosurgery at University “Federico II”, Naples. This study has been approved by the Ethics Committee of the University of “Federico II” of Naples, Italy, and informed consent has been obtained from each patient. A careful classification of patients on the basis of sex, age, histotype and tumor grade has been performed before pituitary samples collection. Experiments of the present study have been performed in primary cultures developed from surgically removed fresh tissue. Tissue samples have been placed in Hanks' balanced salt solution, supplemented with human serum albumin 5%, penicillin and streptomycin and fungizone, immediately after resection. The specimens have been first mechanically minced and then enzymatically dissociated with collagenase or dispase. Cells have been plated in multiwell plates in the appropriate growth medium and incubated at 37°C in a 5% CO₂ humidified atmosphere.

Twenty-one consecutive pituitary somatotroph tumors have been collected for the current study, including 5 aggressive somatotroph

tumors as defined on the basis of histopathological characteristics (4 atypical tumors) or drug resistance (1 tumor), and 16 non-aggressive tumors. Pathology study in all pituitary tumors has confirmed the GH phenotype by immunohistochemistry. Out of the total 21 tumors, 5 have been collected from patients who had received presurgical treatment with SA, DA or with the GH receptor antagonist pegvisomant (PEG). SSTR and mTOR pathway components in all 21 somatotroph tumors have been assessed in basal condition, whereas in 9 somatotroph tumors the effects of the SA OCT and PAS and of EVE on the modulation of receptor expression profile has been investigated. Drug effects on cell proliferation have been assessed by DNA assay in 9 non-aggressive somatotroph tumors and in all 5 aggressive somatotroph tumors. Drug effects on cell hormonal secretion have been assessed by CLIA assay in 5 non-aggressive somatotroph tumors and in all 5 aggressive somatotroph tumors.

6.1.1 Pharmacological compounds

PAS has been kindly gifted by Novartis, whereas OCT, EVE and TMZ have been purchased by Selleck Chemicals. PAS and OCT

have been re-suspended in sterile water at concentration of 10^{-3} M. EVE and TMZ have been re-suspended in DMSO 100% at 10^{-3} M and 10^{-1} M respectively. All drug stocks were stored at -80°C until using. Fresh serial dilutions in PBS 1X were made for PAS and OCT and in DMSO 10% for EVE and TMZ before starting each experiment.

6.1.2 RNA isolation and RT-qPCR

RT-qPCR was performed to quantify the messenger expression level of SSTRs, the most important mTOR pathway components (mTOR, 4eBP1 and p70S6K) and of IGF1R and IR (isoforms A and B). The cells were lysed on ice in a lysis binding buffer containing 100 mM Tris-HCl (pH 8.0), 500 mM LiCl, 10 mM EDTA (pH 8.0), 1% LiDS, 5 mM DTT, and 5 Ltd., Cambridge, UK). The mRNA was isolated from total RNA with the use of prewashed Dynabeads Oligo beads were collected with a magnet and washed three times with 10 mM Tris HCl (pH 8.0), 0.15 M LiCl, 1 mM EDTA, 0.1% LiDS, and once with a similar buffer from which LiDS was omitted. The poly (A+) mRNA was eluted twice, for 2' each time, in H_2O (65°C) and $20\mu\text{l}$ were used for cDNA synthesis in a Tris Buffer (50 mM Tris-HCl

(pH 8.3), 100 mM KCl, 4 mM DTT and 10 mM MgCl₂) with 10 units RNase inhibitor, 2 units avian myeloblastosis virus Super Reverse Transcriptase, oligo dT (5 ng/μl) and 1 mM of each dNTPs in a final volume of 40 μl. This mix was incubated for 1 h at 42°C and the resulting cDNA was diluted fivefold in 160 μl sterile H₂O. The cDNA was used for quantification of mRNA levels of all investigated genes. The total reaction volume (12 μl) consisted in 5 μl of cDNA, 0.5 μl of primers (1 μM) and 6.5 μl 1X Sybr Green Mix (Maxima SYBR Green qPCR Master Mixes, Thermo Fisher Scientific Inc. Waltham MA). Primers sequences and concentrations are shown in *Table 3*. All primers and probes were purchased from Sigma-Aldrich. RT-qPCR was performed with iCycler IQ5 (Bio-Rad Laboratories, CA, USA) and the reaction conditions were as follows: 95°C for 5 min, 40 cycles at 95°C for 1 min, 60°C for 2 min, and 72° C for 1 min. Specific products were detected as clear single peaks at their melting curves. Values were normalized against the expression of the housekeeping gene β-actin. All samples were assayed in duplicate. The relative expression of target genes was calculated using the comparative threshold method, $2^{-\Delta C_t}$ with efficiency correction of target and reference gene transcripts. To exclude genomic DNA contamination in RNA extracts, cDNA reactions were

also performed without reverse transcriptase and amplified with each primer pair. To exclude contamination of the PCR mixtures, reactions were also performed in the absence of cDNA template, in parallel with cDNA samples.

6.1.3 Pharmacological study

Tumoral somatotroph cells have been incubated in serum medium, containing D-valine to inhibit fibroblast growth while allowing selective growth of epithelial cells, with or without PAS 10^{-8} M, OCT 10^{-8} M, EVE 10^{-7} M, and TMZ 10^{-4} M for 4 days. Tumoral somatotroph cells have been also incubated with drug combinations of PAS plus EVE and OCT plus EVE in order to evaluate a potential drug additive effect. Each experimental condition has been assayed at least in triplicate wells. After 4 days, measurement of total DNA content, representative for the number of cells, has been performed using the bisbenzimidazole fluorescent dye (Hoechst 33258). Supernatants have been collected and frozen before measuring hormonal levels. Endogenous GH has been assayed using the Liaison hGH assay kit, based on a chemiluminescent method (CLIA) that uses monoclonal antibodies directed against the 22 kDa form of the GH peptide. The kit is calibrated against the NIBSC 98/574

International Standard (IS).

6.2 In vivo study

6.2.1 Study design

This was an international, multicentre, retrospective, observational study. The study was officially endorsed by the European Neuroendocrine Association (Enea). A dedicated database platform, called “Aggressive pituitary tumors: a Multicentre, Observational, Retrospective study of Enea (A.M.O.R.E)”, was specifically created to collect retrospectively the data of patients with diagnosis of pituitary aggressive tumors and carcinomas, based on pathological (atypical and malignant tumors), clinical (tumor growth despite adequate treatment, disease recurrence, tumor invasiveness, resistance to conventional therapy) and/or radiological (giant tumors, distant metastasis) characteristics. The A.M.O.R.E platform was accessible online from across the world on the Enea official website (<http://www.eneassoc.org>). All referral centers for pituitary aggressive tumors and carcinomas were invited to access the A.M.O.R.E platform to fill in data about clinical, hormonal, radiological, and pathological characteristics, as well as diagnostic and therapeutic approaches of patients with such tumors. Queries

for data clarifications were generated and sent to all participants starting from 24 months after the beginning of the study. Nowadays, the online A.M.O.R.E platform is still available and open for data collection, however for the purpose of the current study data collected until June the 30th 2016 were considered.

6.2.2 Inclusion and exclusion criteria

The study included patients with a diagnosis of pituitary aggressive tumors and pituitary carcinomas. Inclusion criteria were:

- Patients with all type of pituitary tumors, including NFA, secreting pituitary adenomas (ACTH, GH, PRL, FSH, LH, TSH), and craniopharyngiomas
- Age >18 yrs
- Atypical pituitary adenoma (Ki-67 >3%, extensive p53 immunoreactivity, increased mitotic activity)
- Pituitary carcinoma
- Disease recurrence
- Tumor growth >20% in the last year despite medical therapy
- Invasion of the surrounding structures
- Deterioration of visual field or sudden visual loss
- Resistance to conventional therapy

- Maximal tumor diameter >4 cm in adult (giant tumors)/ 2 cm in children/ 1 cm in ACTH secreting
- Silent adenoma

Exclusion Criteria were:

- Responsiveness to conventional treatment
- Meningiomas
- Unavailability of clinical, biochemical, hormonal or radiological data

6.2.3 Patients

A total of 697 patients from 13 different countries (Italy no=185 patients, Russia no= 138 patients, Bulgaria no=121 patients, Brazil no= 120 patients, Turkey no= 75 patients, Israel no= 33 patients, Austria no= 8 patients, Argentina no= 6 patients, Belgium no= 3 patients, India no= 3 patients, Spain no=2 patients, Mexico no= 2 patients, Canada no= 1 patient) received a diagnosis of pituitary aggressive tumors or carcinomas between 1979 and 2013. Sixty-four patients were excluded from the study because of unavailability of clinical (no= 13 patients), hormonal (no= 8 patients), radiological (no=11 patients), pathological (no= 16 patients), diagnostic (no= 12 patients) or therapeutic (no= 4 patients) data. Therefore, for the

purpose of the study 633 patients (237 females, 396 males, age at diagnosis 40.3 ± 15.7 yrs) were considered for the final analysis. Patient profile at study entry is shown in *Table 4*. According to the classification system based upon histopathological markers proposed by WHO (10) and to the presence of distant metastases (11, 12), tumors were classified as atypical, carcinomas, and non-atypical non-malignant.

6.3 Statistical Analysis

Data have been analyzed using SPSS Software for Windows, version 24.0 (SPSS, Inc., Cary, NC package). The comparison between the numerical data before and after treatment has been made by non parametric Wilcoxon test for two related samples, and by non parametric *U* Mann-Whitney or Student t test for not related samples with non normal and normal distribution, respectively. . The comparison between the numerical data among different groups of patients has been made by OnewayAnova for multiple comparisons corrected by Bonferroni exact test when necessary. The comparison between prevalence has been performed by χ^2 test corrected by Fisher exact test when necessary. Significance has been set at 5%.

7. RESULTS

7.1 In vitro study

7.1.1 Characterization of SSTR, IGF1R, IRA, IRB and mTOR pathway components in human somatotroph tumors

RT-qPCR analysis revealed that non-aggressive somatotroph tumor cells expressed slightly but not significantly higher levels of SSTRs and IGF1R compared with aggressive somatotroph tumor cells (*Fig.2*). No significant difference in mTOR components expression has been found between the two groups of somatotroph tumors. SSTRs, IGF1R, IRA, IRB and mTOR pathway components expression has been also evaluated in 9 somatotroph tumors, including 7 non-aggressive and 2 aggressive somatotroph tumors, after drug treatment. As shown in *Fig. 3*, PAS and EVE treatment did not induce gene transcription regulation even when combined after 1h of treatment, although a trend in increasing SSTR expression has been observed in non-aggressive somatotroph tumors after combined treatment.

7.1.2 Functional study: DNA assay

Fig. 4 shows the effects of different treatments on cell proliferation. In 14 out of 21 somatotroph tumors, including 5 aggressive and 9 non-aggressive tumors, cell proliferation has been tested after 4 days of treatment. Incubation of cells from 9 non-aggressive somatotroph tumors with PAS 10^{-8} M+EVE 10^{-7} M in DMEM containing 10% FCS and D-Valine has significantly reduced cell proliferation by 30%. The same drugs, used alone, did not significantly change cell proliferation at tested doses. OCT, both used alone and in combination with EVE, has been tested on 5 non-aggressive somatotroph tumors, with no significant effect on cell proliferation. In 5 aggressive somatotroph tumors, neither PAS, EVE, nor PAS+EVE have significantly inhibited cell proliferation at tested doses. In 2 non-aggressive somatotroph tumors and in 1 aggressive somatotroph tumor TMZ did not significantly change cell proliferation at tested doses.

7.1.3 Functional study: Hormonal assay

Fig. 5 shows the effects of different treatment on GH secretion. In 5 non-aggressive somatostroph tumors, as compared to the control PAS, EVE and PAS+EVE significantly reduced GH secretion by

23,73% ($p < 0.01$), 21% ($p < 0.05$) and 28,96 % ($p < 0.001$), respectively. In 2 non-aggressive somatotroph tumors OCT alone or combined with EVE did not significantly reduce GH secretion. In 5 aggressive somatotroph tumors, PAS induced the significant GH secretion inhibition when used alone (27,28%, $p < 0.01$) and combined with EVE (37%, $p < 0.0001$ vs control, $p < 0.001$ vs EVE alone). In non-aggressive somatotroph tumors TMZ did not significantly reduce GH secretion, and in aggressive somatotroph tumors it increased GH secretion ($p < 0.01$) probably due GH excretion most likely because of its cytotoxic effect.

7.2 In vivo study

Clinical, hormonal and radiological characteristics of the whole cohort of patients with pituitary aggressive tumors and carcinomas are shown in *Table 5*.

7.2.1 Whole patient cohort

In the whole cohort, most patients (68.7%) were Caucasian. According to disease status, 50.1% of patients had active disease whereas 46.4% had achieved disease remission. Death had occurred in 22 patients (3.5%): causes of death included tumor

progression in 10 (45.4%), cerebrovascular accidents in 8 (36.4%), heart stroke in 3 (13.6%) and other malignancy in 1 (4.5%) (Fig. 6). Genetics had been assessed in 25% of patients and revealed isolated pituitary tumors in 85.5%, FIPA with *AIP* mutation in 4.4 %, FIPA with no *AIP* mutation in 8.8%, MEN1 syndrome in 0.6% and McCune Albright syndrome in 0.6%. Based on histopathological findings, 101 out of 633 patients (15.9%) had atypical pituitary tumors, whereas pituitary carcinomas were reported in 6 patients (0.9%). Non-atypical non-malignant tumors were described in 526 patients (83.2%). In the whole cohort of 633 patients, distribution of pituitary tumor histotypes was as follows (Fig. 7): NFA= 27.6%; GH-secreting tumors= 21.3%; GH and PRL-cosecreting tumors= 7.7%; PRL-secreting tumors= 20.8%; ACTH-secreting pituitary tumors= 9%; craniopharyngiomas= 7.4%; FSH/LH-secreting pituitary tumors= 5.8%. Approximately 5% of patients had a silent pituitary tumor. Overall, secreting and non-secreting tumors were found in 68.9% 31.1% of patients, respectively. Microadenomas were reported in 18.3% of cases, whereas the vast majority of patients (81.7%) harboured pituitary macroadenomas, including giant tumors in 33.2%, tumors with maximal diameter > 2 cm in children in 3.3%, and ACTH-secreting tumors with maximal diameter > 1 cm in 5%. In

the whole patient cohort, maximal tumor diameter was 3.6 ± 1.98 cm. Approximately 31% of patients had experienced tumor growth $>20\%$ in the last year despite medical therapy, whereas recurrence was reported in 15.3% of cases. Tumor invasiveness was the most commonly used criterion for tumor aggressiveness: bilateral or monolateral invasion of cavernous sinus was found in 35.2% and 44.7% of patients, respectively; tumors grew up to the third ventricle or to the sellar floor in 25.9% and 34.3% of cases, respectively. Laterosellar extension was described in 67.3% of patients, whereas in 66.8% of cases suprasellar extension was reported. Overall, 3 or more clinical criteria for tumor aggressiveness (invasiveness, resistance to medical therapy, giant size and visual field defects) were found in 79% of patients. As a result of tumor invasiveness and extension, patients had headache in 46.3%, deterioration of visual field in 40.9%, sudden visual loss in 16.4%, intracranial hypertension in 10.4% and cerebrospinal fluid (CSF) leak in 4.6% of cases. The most frequent pituitary deficiency was hypogonadism (46.3%), followed by hypothyroidism (30.5%), GH deficiency (20.2%), hypocortisolism (19.3%), and diabetes insipidus (5%). Panhypopituitarism was described in 12.9% of cases. Resistance to conventional therapy was reported in 56.7% of patients, including

37.6% with resistance to DA bromocriptine and cabergoline, and 19.1% with resistance to SA LAN, LAR and PAS. In the whole patient cohort, out of 767 total required surgical interventions 79.4% were performed with trans-sphenoidal approach, and 20.6% with transcranial technique. RT was required in 21.5% of patients, and was administered as CER in 61% and RS in 39% of cases, respectively. A second course of medical therapy was required in 41.7% of patients, with 49.5% of patients receiving DA, 35.6% SA, 7.5% the GH receptor antagonist pegvisomant, 4.3% the adrenal directed drug ketoconazole, and 0.3% TMZ. However, such treatment was unsuccessful in 81.6% of cases, as only 18.4% of patients achieved disease control.

7.2.2 Atypical tumors

Based on histopathological findings, 101 out of 633 total patients (15.9%, 48 females and 53 males, age at diagnosis 40.4 ± 12.6 yrs) harboured an atypical pituitary tumor. According to disease status, 52.5% of patients had active disease whereas 45.5% had achieved disease remission. Death had occurred in 2 patients (2%). Distribution of pituitary tumor histotypes was as follows: PRL-secreting tumors= 34.6%; NFA= 30.7%; ACTH-secreting tumors=

14.8%; GH-secreting tumors= 14.8%; GH and PRL-cosecreting tumors= 2.9%; FSH/LH-secreting tumors= 1.9%. Approximately 5% of patients had a silent pituitary tumor. The vast majority of patients had macroadenomas (91%), including 23 giant adenomas (25%) and 9 ACTH-secreting tumors with maximal tumor diameter > 1 cm (9.8%). Maximal tumor diameter was 3.56 ± 1.7 cm. Approximately 20% of patients had experienced tumor growth >20% in the last year despite medical therapy, whereas recurrence was reported in 19% of cases. As far as tumor invasiveness is concerned, bilateral or monolateral invasion of cavernous sinus was found in 26.7% and 38.6% of patients, respectively; tumors grew up to the third ventricle or to the sellar floor in 37.6% and 17.8% of cases, respectively. Laterosellar and suprasellar extension were both described in 47.5% of patients. Overall, 3 or more clinical criteria for tumor aggressiveness (invasiveness, resistance to medical therapy, giant size and visual field defects) were found in 89% of patients. As a result of tumor invasiveness and extension, patients had headache in 47.5%, deterioration of visual field in 41.6%, sudden visual loss in 16.8%, intracranial hypertension in 9.9% and CSF leak in 2% of cases. The most frequent pituitary deficiency was hypogonadism (33.6%), followed by hypothyroidism (24.7%), hypocortisolism

(22.7%), GH deficiency (12.9%), and diabetes insipidus (2%). Panhypopituitarism was described in 12.9% of cases. Resistance to conventional therapy was reported in 60.4% of patients, including 44.5% with resistance to DA bromocriptine and cabergoline, and 15.8% with resistance to SA LAN, LAR and PAS. In the cohort of patients with atypical adenomas, out of 80 total required surgical interventions 76.3% were performed with trans-sphenoidal approach, and 23.7% with transcranial technique. RT was required in 32.7% of patients, and was administered as CER in 75.8% and RS in 24.2% of cases, respectively. A second course of medical therapy was required in 60.7% of patients, with 49.1% of patients receiving DA, 40% SA, 9.9% the GH receptor antagonist pegvisomant, 6.3% the adrenal directed drug ketoconazole, and 1% TMZ. However, such treatment was unsuccessful in 86.3% of cases, as only 13.7% of patients achieved disease control.

7.2.3 Carcinomas

Six out of 633 total patients (0.9%, 1 female and 5 males, age at diagnosis 46 ± 15.7 yrs) harboured a pituitary carcinoma. According to disease status, 50% of patients had active disease, and 50% had

died because of tumor progression and distant metastases. Distribution of pituitary tumor histotypes was as follows: ACTH-secreting tumors= 66.6%; PRL-secreting tumors= 16.7%; NFA= 16.7%. All patients had a pituitary macroadenoma (91%), including 1 giant NFA (16.7%), 1 PRL-secreting tumors with maximal diameter > 2 cm in a child (16.7%) and 4 ACTH-secreting tumors with maximal diameter > 1 cm (66.6%). Maximal tumor diameter was 3.5 ± 1.5 cm. Tumor growth >20% in the last year despite medical therapy was reported in 33.3% of patients, and recurrence was found in 66.6%. As far as tumor invasiveness is concerned, bilateral or monolateral invasion of cavernous sinus was found in 33.3% and 16.7% of patients, respectively; tumors grew up to the third ventricle or to the sellar floor in 66.6% and 33.3% of cases, respectively. Laterosellar and suprasellar extension were described in 66.6% and 83.3% of patients, respectively. Overall, 3 or more clinical criteria for tumor aggressiveness (invasiveness, resistance to medical therapy, giant size and visual field defects) were found in 100% of patients. As a result of tumor invasiveness and extension, patients had headache in 83.3%, deterioration of visual field in 100%, sudden visual loss in 83.3%, intracranial hypertension in 33.3% and CSF leak in 16.7% of cases. The most frequent pituitary deficiency was

hypogonadism (83.3%), followed by GH deficiency (50%), hypothyroidism (33.3%), hypocortisolism (33.3%), and diabetes insipidus (33.3%). Panhypopituitarism was described in one third of cases. Resistance to conventional therapy was reported in 83.3% of patients, including 33.3% with resistance to DA bromocriptine and cabergoline, 33.3% with resistance to SA LAN, LAR and PAS, and 16.7% with resistance to TMZ. In the cohort of patients with pituitary carcinomas, out of 7 total required surgical interventions 71.4% were performed with trans-sphenoidal approach, and 28.6% with transcranial technique. RT was required in two thirds of patients, and was administered as CER in 75% and RS in 25% of cases, respectively. A second course of medical therapy was required in all patients, with 83.3% of patients receiving DA and ketoconazole, and 16.7% SA. However, such treatment was unsuccessful in 100% of cases, and no patient achieved disease control.

7.2.4 Non-atypical non-malignant vs atypical and malignant tumors: comparison study

Comparison between non-atypical non-malignant vs atypical tumors and carcinomas is shown in *Table 5*.

Active disease and disease remission were similarly described in both groups of patients, and no significant difference was found in mortality rate between patients with non-atypical non-malignant and those with atypical tumors and carcinomas. Histopathological distribution of pituitary tumors was different between the two groups, as PRL-secreting ($p < 0.001$) and ACTH-secreting ($p = 0.002$) tumors were significantly more prevalent in patients with atypical tumors and carcinomas as compared to those with non-atypical non-malignant tumors. Prevalence of macroadenomas was significantly higher ($p = 0.021$), and of microadenomas significantly lower ($p = 0.022$) in patients with atypical tumors and carcinomas as compared to those with non-atypical non-malignant tumors. Similarly, prevalence of giant tumors ($p = 0.013$) and of ACTH-secreting tumor > 1 cm in size ($p < 0.001$) was significantly greater in patients with atypical tumors and carcinomas as compared to those with non-atypical non-malignant tumors, whereas no significant difference was found in the rate of giant tumors in children between the two groups. Overall, maximal tumor diameter was significantly higher ($p = 0.001$) in patients with atypical tumors and carcinomas as compared to those with non-atypical non-malignant tumors. As shown in *Fig. 8*, tumor growth ($p = 0.003$) and disease recurrence

($p=0.05$) were significantly more frequent in patients with atypical tumors and carcinomas as compared to those with non-atypical non-malignant tumors; conversely, no significant difference was found between the two groups of patients in terms of tumor invasiveness, as bilateral or monolateral cavernous sinus invasion, and invasion of the third ventricle or of the sellar floor were similarly reported in both groups of patients. However, atypical tumors and carcinomas displayed a higher rate of laterosellar extension ($p=0.05$) compared to non-atypical non-malignant tumors, and a slight but not significant difference was found in the rate of suprasellar extension between the two groups of patients (*Fig. 8*). Thus, deterioration of visual field was significantly more prevalent in patients with atypical tumors and carcinomas as compared to those with non-atypical non-malignant tumors, whereas no significant difference was found in the prevalence of sudden visual loss, headache, intracranial hypertension and CSF leak. Such large and invasive tumors resulted in a similar prevalence of multiple or isolated pituitary hormone deficiency, including hypothyroidism, hypocortisolism, GH deficiency and diabetes insipidus, between the two groups of patients, with the only exception of hypogonadotropic hypogonadism that was significantly more frequent in patients with non-atypical

non-malignant tumors as compared to those with atypical tumors and carcinomas. Both groups of patients were similarly resistant to medical therapy with SA, whereas the resistance rate to DA was found significantly higher in patients with atypical tumors and carcinomas as compared to those with non-atypical non-malignant tumors. As far as surgical therapy is concerned, the trans-sphenoidal and the trans-cranial approaches were used in a similar proportion in both groups of patients. Conversely, radiotherapy was required in a significantly higher ($p < 0.001$) proportion of patients with atypical tumors and carcinomas compared to those with non-atypical non-malignant tumors; CER was administered more frequently ($p < 0.001$) and RS more rarely ($p < 0.001$) in presence of atypical tumors and carcinomas as compared to non-atypical non-malignant tumors. Patients with atypical tumors and carcinomas required also more frequently ($p < 0.001$) a second course of medical therapy, including either DA ($p < 0.001$) and SA ($p < 0.001$), as compared to patients with non-atypical non-malignant tumors. Disease control was achieved in a minority of patients in both groups, however unsuccessful treatment was more frequently reported in patients with atypical tumors and carcinomas as

compared to patients with non-atypical non-malignant tumors
($p=0.042$).

8. DISCUSSION

The current *in vitro* study has first demonstrated that combined treatment with PAS and EVE is able to significantly inhibit cell proliferation and GH secretion in primary cultures of aggressive GH-secreting pituitary tumors, thus suggesting the potential use of this therapeutic strategy as valid alternative treatment in patients with aggressive pituitary tumors poorly responsive to conventional medical treatments. Moreover, the current *in vivo* study has first demonstrated in a large cohort of patients with pituitary aggressive tumors that atypical tumors and carcinomas are larger, more recurrent and less responsive to medical treatment than non-atypical non-malignant pituitary adenomas, thus suggesting a greater biological and clinical aggressiveness of atypical tumors and carcinomas.

In line with previous studies investigating *in vitro* the effects of the second generation SA PAS in patients with aggressive pituitary tumors (32, 171), the results of the current *in vitro* study have confirmed PAS to potently suppress GH secretion and to inhibit cell proliferation. Worth of note, this study has also highlighted the potential beneficial effects, mainly in terms of GH secretion, deriving

from the addition of EVE to PAS in patients with aggressive GH-secreting tumors, besides the anti-proliferative effects induced by EVE in pituitary tumors already demonstrated in previous *in vitro* studies (41-43). Conversely, in the present study OCT and TMZ, nowadays considered the standard medical treatment for acromegaly and aggressive tumors, respectively, did not induce significant change in cell proliferation and GH secretion. However, such results may be explained, at least partly, considering that most experiments have been performed in few tumor samples, due to the rarity of pituitary aggressive tumors and carcinomas.

Indeed, the current retrospective study has confirmed carcinomas to account for less than 1% of all pituitary tumors, in line with previous data (11, 12). Conversely, in the present patient cohort pituitary atypical tumors have been found in a slightly higher percentage of patients than previously reported, as they have been seen to account for approximately 16% of cases. Previous studies (45, 56-58) have reported atypical pituitary tumors in 2.7%-14.8% of patients. However, these studies included much smaller patient series, as the largest included 146 patients (58), as compared to the present cohort. In fact, the current study is the first specifically investigating pituitary aggressive tumors, including atypical and

malignant ones, in a very large cohort of patients. Moreover, as the vast majority of patients of the current series have received the diagnosis of pituitary tumor between 1979 and 2009, before the availability of the classification system based on histopathological markers proposed by the WHO (10), we cannot exclude that the true prevalence of atypical tumors is still underestimated, and further investigations are needed to rule out definitive conclusions about the epidemiology of pituitary atypical tumors.

In line with previous data (7, 44), the current study confirmed macroadenomas to represent the more prevalent tumor size in patients with aggressive tumors, either atypical, malignant and non-atypical non-malignant. However, in the present cohort maximal tumor diameter was significantly larger in patients with atypical tumors and carcinomas as compared to those with non-atypical non-malignant adenomas. Similarly, laterosellar extension was found to be more frequent in the former as compared to the latter. These findings were also confirmed by a higher prevalence of giant tumors, mainly those associated with ACTH-secretion, in patients with atypical tumors and carcinomas as compared to those with non-atypical non-malignant tumors. However, characteristics of tumor invasiveness have been found to be similar in both groups of

patients, regardless from histopathological markers of aggressiveness. Indeed, no significant difference has been found in the prevalence of invasion of the cavernous sinus, third ventricle and sellar floor in the two groups of patients, whereas visual field defects were more frequent in patients with atypical tumors and carcinomas as compared to those with non-atypical non-malignant adenomas. These findings confirmed that invasive pituitary tumors are not always aggressive, and that in turn tumor aggressiveness is not always synonymous of invasiveness. Indeed, invasive pituitary adenomas often display benign behavior even in presence of marked dural invasion and are not considered malignant by current definition (187). Moreover, microscopic dura and cavernous sinus invasion, together with suprasellar expansion, are commonly encountered in non-atypical non-malignant (i.e., apparently benign) pituitary adenomas (48), and the invasion of the clivus or the sphenoidal bone is generally considered more indicative of aggressive behavior as opposed to the invasion of cavernous sinus (50). The current study first has shown laterosellar extension to be more prevalent in atypical tumors and carcinomas as compared to non-atypical non-malignant adenomas, suggesting that it might be

considered a distinctive radiological characteristic for atypical tumors and carcinomas.

Other features of aggressiveness characterizing atypical tumors and carcinomas are speed of growth and recurrence. Even considering that typical and benign tumors can develop recurrence after a long latency (up to 10 years) postoperatively, early recurrence and fast tumor regrowth are more in favor of an aggressive behavior in atypical or malignant tumors (187). In line with this evidence, in the present study tumor growth and recurrence have been found to occur more frequently in atypical tumors and carcinomas as compared to non-atypical non-malignant adenomas.

In line with previous literature (10, 18, 23, 158-170), the present study has confirmed that aggressive tumors, regardless from histopathological markers of aggressiveness, are generally associated with hormonal hypersecretion, mainly PRL and ACTH, as they have been found in nearly 70% of patients of the whole series. However, in both secreting and non-secreting tumors, responsiveness to medical treatment has been found scant. Indeed, in the whole patient cohort of the current study resistance to conventional medical treatments has been demonstrated in approximately 57% of patients, and in nearly 62% of those with

atypical tumors and carcinomas. Generally, in pituitary tumors resistance to conventional medical treatment is not a common finding, as pituitary adenomas usually display a good responsiveness to pituitary-directed drugs, mainly DA and SA. Particularly, resistance to DA has been reported to occur in 10% of microadenomas and 18% of macroadenomas in patients with prolactinomas (188), and escape to treatment is known to occur in up to 25% of patients with Cushing's disease (104). In acromegaly, resistance to first-generation SA LAR and LAN has been demonstrated in approximately 25% of patients (189). No data are nowadays available about the resistance to the second-generation SA PAS, as it has been commercialized very recently for the treatment of patients with Cushing's disease and acromegaly. In typical and benign pituitary adenomas, early or late resistance to medical treatments may occasionally occur, mainly because of specific tumor receptor heterogeneity, tachyphylaxis or other factors influencing drug effectiveness, such as the expression of receptor isoforms (110, 116) or truncated variants (28, 29, 114), functional aberrations (111-113), and/or receptor interaction with specific receptor modulators (30, 115, 117, 118). In the present study resistance to DA and SA, used either before and/or after surgery

and radiotherapy, has been shown to occur more frequently in patients with atypical tumors and carcinomas as compared to those with non-atypical non-malignant tumors. As for the limitations of a retrospective study, no data were available about DR and SSTR expression in the current patient series, however alterations in receptor expression or function cannot be excluded. Indeed, the *in vitro* study has shown that in aggressive somatotroph tumors SSTR expression was lower, although not significantly, than that found in non-aggressive tumors.

Among patients resistant to conventional medical treatments, only two received TMZ (one with atypical tumor and one with non-atypical non-malignant adenoma) and only 4 were treated with PAS (all with non-atypical non-malignant tumors). This can be explained taking into account that both compounds have been officially approved only very recently for the treatment of aggressive pituitary tumors (TMZ), and for Cushing's disease and acromegaly refractory to first-generation SA (PAS). However, in previous studies TMZ has been successfully used to treat pituitary aggressive adenomas and carcinomas (13, 21, 23, 158-168), inducing complete or partial response in 42%, stabilization in 31% and progression in 31% of patients (21, 23, 161-166). Similarly, a few studies have

documented the efficacy of PAS in patients with pituitary aggressive tumors (165, 181-183) in terms of control of both hormonal hypersecretion and tumor growth, although the escape to treatment following an initial excellent response to PAS has been reported in a patient (183). Noteworthy, none of the patients of the current series received EVE. This finding is not surprising, as EVE is officially approved for the treatment of gastroenteropancreatic NET, besides breast and renal cell cancers, but not for pituitary tumors. However, the *in vitro* study has shown that EVE addition to PAS significantly reduced GH secretion in patients with aggressive GH-secreting tumors, besides the anti-proliferative effects already documented in previous *in vitro* studies (41-43). These findings can be explained taking into account that SA inhibit PI3K/Akt signalling upstream of mTOR, suggesting that the combination of a SA and a mTOR inhibitor, such as PAS and EVE, may have greater efficacy than either as single agents (190). Clinical trial experience has provided some encouraging findings and prompted the design of additional studies of this dual-targeted approach to treating advanced NET (36-39).

As a result of such poor responsiveness to conventional medical treatment and the unavailability of new target therapies, most

patients have received more than one surgery followed by radiation therapy. Particularly, patients with atypical tumors and carcinomas required RT more frequently than those with non-atypical non-malignant tumors. Worth of note, in the former CER was more commonly used as compared to RS, most likely because of the large tumor size (145).

However, despite this multimodal therapeutic approach, disease control has been shown to be rarely achieved in patients with aggressive tumors of the current cohort. Control has been found to occur in approximately 18% of patients in the whole series, in nearly 14% of atypical tumors and in none of patients with pituitary carcinomas. In the vast majority of patients, the multimodal treatment has failed to induce disease control, and persistent disease has been found in 82% of patients in the whole cohort, 86% of those with atypical tumors and 100% of those with pituitary carcinomas.

Altogether, the results of the current study appear to suggest that the early identification of patients with aggressive tumors, either atypical, malignant or non-atypical non-malignant, is mandatory to apply close clinical and radiological surveillance along with all

available treatments early in the course of the disease in an attempt to increase the cure rate and to minimize their morbidity.

9. CONCLUSIONS

Knowledge about epidemiological, clinical, molecular and pathological characteristics of pituitary aggressive tumors and carcinomas is still scant, and strong evidence about the best therapeutic approach is yet to be achieved. The current study has confirmed pituitary carcinomas to be exceptionally rare, but highlighted that atypical tumors might be more common than previously thought. Apart from the clear cut definition of atypical and malignant pituitary tumors, based on WHO criteria and on the presence of distant metastases, respectively, nowadays tumors size, recurrence, laterosellar extension and responsiveness to conventional medical treatments appear to be the best clinical and radiological criteria to discriminate pituitary tumors with a true aggressive behavior. Conversely, tumor invasiveness is not a good predictor of tumor aggressiveness and cannot discriminate pituitary atypical and malignant tumors from typical and benign adenomas. Radiotherapy and medical treatments remain the most commonly used therapeutic approaches for pituitary aggressive tumors, but fail to induce the achievement of disease control in most patients. *In vivo* experience with new target therapies, such as PAS and EVE, is still scant, however *in vitro* data support the use of combined

treatment with PAS and EVE as potential valid alternative treatment in patients with aggressive pituitary tumors poorly responsive to conventional medical treatments. Drug responsiveness can be, however, influenced by specific tumor receptor heterogeneity, tachyphylaxis or other factors influencing drug effectiveness, such as SSTR and mTOR components expression profile, and in turn early identification of molecular markers able to predict responsiveness to treatment might drive endocrinologists through the choice of the best individualized adjuvant therapy in patients with pituitary aggressive tumors and carcinomas. Further studies are needed to better elucidate the burden and the role of new target therapeutic strategies, such as PAS and EVE, on the tumor growth and hormonal hypersecretion in patients with pituitary aggressive tumors and carcinomas.

10. REFERENCES

1. Kovacs K, Horvath E. Pathology of pituitary tumors. *Endocrinol Metab Clin North Am* 1987, 16: 529–51.
2. Central Brain Tumor Registry of the United States 2007-2008. Central Brain Tumor Registry of the United States Statistical Report, 2008.
3. Clayton, RN. Sporadic pituitary adenomas: from epidemiology to use of databases. *Baillière's Best Practice and Research Clinical Endocrinology and Metabolism* 1999, 13,:451-460.
4. Ambrosi B, Faglia G. Epidemiology of pituitary tumors. In Faglia G., Beck-Peccoz P. & Ambrosi B. *Pituitary adenomas: new trends in basic and clinical research* 1991, Elsevier, Amsterdam.
5. Ezzat S, Asa SL, Couldwell WT, Barr CE, Dodge WE, Vance ML, McCutcheon IE. The prevalence of pituitary adenomas: a systematic review. *Cancer* 2004, 101: 613–619.
6. Daly AF, Rixhon M, Adam C, Dempegioti A, Tichomirowa MA, Beckers A. High prevalence of pituitary adenomas: a cross-sectional study in the province of Liège, Belgium. *The Journal of Clinical Endocrinology and Metabolism* 2006, 91: 4769-4775.
7. Selman WR, Laws ER, Scheithauer BW, et al. The occurrence of dural invasion in pituitary adenomas. *J Neurosurg* 1986; 64:402-7
8. Trouillas J, Raverot G, Jouanneau E. et al.(2010) Chapter 23: Tumeurs de l'hypophyse p441 in Droz Jean-Pierre , Ray-Coquard Isabelle, Peix, Jean-Louis (eds.). *Tumeurs malignes rares*. 1st Edition., Lyon 2010, XXII, 632.
9. Raverot G, Castinetti F, Jouanneau E, Morange I, Figarella-Branger D, Dufour H, Trouillas J, Brue T. Pituitary carcinomas and aggressive pituitary tumours: merits and pitfalls of temozolomide treatment. *Clin Endocrinol (Oxf)*. 2012, 76(6):769-75.

10. De Lellis RA, Lloyd RV, Heitz PU, Eng C (eds). World Health Organization Classification of Tumours. Pathology and Genetics of Tumours of Endocrine Organs. IARC Press: Lyon 2004.
11. Kaltsas GA, Nomikos P, Kontogeorgos G, Buchfelder M, Grossman AB. Clinical review: Diagnosis and management of pituitary carcinomas. *J Clin Endocrinol Metab.* 2005, 90(5):3089-99.
12. Colao A, Ochoa AS, Auriemma RS, Faggiano A, Pivonello R, Lombardi G. Pituitary carcinomas. *Front Horm Res.* 2010, 38:94-108.
13. Lim S, Shahinian H, Maya MM, Yong W, Heaney AP. Temozolomide: a novel treatment for pituitary carcinoma. *Lancet Oncol* 2006, 7(6): 518-520.
14. Zacharia BE, Gulati AP, Bruce JN, Carminucci AS, Wardlaw SL, Siegelin M, Remotti H, Lignelli A, Fine RL. High Response Rates and Prolonged Survival in Patients With Corticotroph Pituitary Tumors and Refractory Cushing's Disease From Capecitabine and Temozolomide (CAPTEM): A Case Series. *Neurosurgery.* 2013 Nov 12. [Epub ahead of print] PubMed PMID: 24226425.
15. Tatar Z, Thivat E, Planchat E, Gimbergues P, Gadea E, Abrial C, Durando X. Temozolomide and unusual indications: review of literature. *Cancer Treat Rev.* 2013 Apr;39(2):125-35.
16. Ortiz LD, Syro LV, Scheithauer BW, Rotondo F, Uribe H, Fadul CE, Horvath E, Kovacs K. Temozolomide in aggressive pituitary adenomas and carcinomas. *Clinics (Sao Paulo).* 2012;67 Suppl 1:119-23.
17. Whitelaw BC, Dworakowska D, Thomas NW, Barazi S, Riordan-Eva P, King AP, Hampton T, Landau DB, Lipscomb D, Buchanan CR, Gilbert JA, Aylwin SJ. Temozolomide in the management of dopamine agonist-resistant prolactinomas. *Clin Endocrinol (Oxf).* 2012 Jun;76(6):877-86.
18. McCormack AI, Wass JA, Grossman AB. Aggressive pituitary tumours: the role of temozolomide and the assessment of MGMT status. *Eur J Clin Invest.* 2011 Oct;41(10):1133-48.
19. Colao A, Grasso LF, Pivonello R, Lombardi G. Therapy of aggressive pituitary tumors. *Expert Opin Pharmacother.* 2011 Jul;12(10):1561-70.

20. Dillard TH, Gultekin SH, Delashaw JB Jr, Yedinak CG, Neuwelt EA, Fleseriu M. Temozolomide for corticotroph pituitary adenomas refractory to standard therapy. *Pituitary*. 2011 Mar;14(1):80-91.
21. Losa M, Mazza E, Terreni MR, McCormack A, Gill AJ, Motta M, Cangini MG, Talarico A, Mortini P, Reni M. Salvage therapy with temozolomide in patients with aggressive or metastatic pituitary adenomas: experience in six cases. *Eur J Endocrinol*. 2010 Dec;163(6):843-51.
22. Syro LV, Ortiz LD, Scheithauer BW, Lloyd R, Lau Q, Gonzalez R, Uribe H, Cusimano M, Kovacs K, Horvath E. Treatment of pituitary neoplasms with temozolomide: a review. *Cancer*. 2011 Feb 1;117(3):454-62.
23. Raverot G, Sturm N, de Fraipont F, Muller M, Salenave S, Caron P, Chabre O, Chanson P, Cortet-Rudelli C, Assaker R, Dufour H, Gaillard S, François P, Jouanneau E, Passagia JG, Bernier M, Cornélius A, Figarella-Branger D, Trouillas J, Borson-Chazot F, Brue T. Temozolomide treatment in aggressive pituitary tumors and pituitary carcinomas: a French multicenter experience. *J Clin Endocrinol Metab*. 2010 Oct;95(10):4592-9.
24. Maïza JC, Caron P. Pituitary carcinomas and aggressive adenomas: an overview and new therapeutic options. *Ann Endocrinol (Paris)*. 2009 Sep;70 Suppl 1:S12-9.
25. Hagen C, Schroeder HD, Hansen S, Hagen C, Andersen M. Temozolomide treatment of a pituitary carcinoma and two pituitary macroadenomas resistant to conventional therapy. *Eur J Endocrinol*. 2009 Oct;161(4):631-7.
26. Widhalm G, Wolfsberger S, Preusser M, Woehrer A, Kotter MR, Czech T, Marosi C, Knosp E. O(6)-methylguanine DNA methyltransferase immunoexpression in nonfunctioning pituitary adenomas: are progressive tumors potential candidates for temozolomide treatment? *Cancer*. 2009 Mar 1;115(5):1070-80.
27. Buchfelder M. Management of aggressive pituitary adenomas: current treatment strategies. *Pituitary*. 2009;12(3):256-60.
28. Durán-Prado M, Saveanu A, Luque RM, Gahete MD, Gracia-Navarro F, Jaquet P, Dufour H, Malagón MM, Culler MD, Barlier A, Castaño JP. A potential

- inhibitory role for the new truncated variant of somatostatin receptor 5, sst5TMD4, in pituitary adenomas poorly responsive to somatostatin analogs. *J Clin Endocrinol Metab.* 2010 May;95(5):2497-502.
29. Durán-Prado M, Gahete MD, Martínez-Fuentes AJ, Luque RM, Quintero A, Webb SM, Benito-López P, Leal A, Schulz S, Gracia-Navarro F, Malagón MM, Castaño JP. Identification and characterization of two novel truncated but functional isoforms of the somatostatin receptor subtype 5 differentially present in pituitary tumors. *J Clin Endocrinol Metab.* 2009 Jul;94(7):2634-43
30. Gatto F, Feelders R, van der Pas R, Kros JM, Dogan F, van Koetsveld PM, van der Lelij AJ, Neggers SJ, Minuto F, de Herder W, Lamberts SW, Ferone D, Hofland LJ. β -Arrestin 1 and 2 and G protein-coupled receptor kinase 2 expression in pituitary adenomas: role in the regulation of response to somatostatin analogue treatment in patients with acromegaly. *Endocrinology.* 2013 Dec;154(12):4715-25.
31. Hofland LJ, van der Hoek J, Feelders R, van Aken MO, van Koetsveld PM, Waaijers M, Sprij-Mooij D, Bruns C, Weckbecker G, de Herder WW, Beckers A, Lamberts SW. The multi-ligand somatostatin analogue SOM230 inhibits ACTH secretion by cultured human corticotroph adenomas via somatostatin receptor type Eur *J Endocrinol.* 2005 Apr;152(4):645-54.
32. Hofland LJ, van der Hoek J, van Koetsveld PM, de Herder WW, Waaijers M, Sprij-Mooij D, Bruns C, Weckbecker G, Feelders R, van der Lely AJ, Beckers A, Lamberts SW. The novel somatostatin analog SOM230 is a potent inhibitor of hormone release by growth hormone- and prolactin-secreting pituitary adenomas in vitro. *J Clin Endocrinol Metab.* 2004 Apr;89(4):1577-85.
33. Colao A, Bronstein M, Freda P, Gu F, Shen CC, Gadelha M, Fleseriu M, van der Lely A, Farrall A, Hermosillo Reséndiz K, Ruffin M, Chen Y, Sheppard M; on behalf of the Pasireotide C2305 Study Group. Pasireotide versus octreotide in acromegaly: a head-to-head superiority study. *J Clin Endocrinol Metab.* 2014 Jan 13:jc20132480. [Epub ahead of print] PubMed PMID: 24423324.
34. Gadelha MR, Bronstein MD, Brue T, Coculescu M, Fleseriu M, Guitelman M, Pronin V, Raverot G, Shimon I, Lievre KK, Fleck J, Aout M, Pedroncelli AM, Colao A; PasireotideC2402 Study Group. Pasireotide versus continued

- treatment with octreotide or lanreotide in patients with inadequately controlled acromegaly (PAOLA): a randomised, phase 3 trial. *Lancet Diabetes Endocrinol.* 2014 Nov;2(11):875-84.
35. Colao A, Petersenn S, Newell-Price J, Findling JW, Gu F, Maldonado M, Schoenherr U, Mills D, Salgado LR, Biller BM; Pasireotide B2305 Study Group. A 12-month phase 3 study of pasireotide in Cushing's disease. *N Engl J Med.* 2012 Mar 8; 366(10):914-24.
36. Castellano D, Bajetta E, Panneerselvam A, Saletan S, Kocha W, O'Dorisio T, Anthony LB, Hobday T; RADIANT-2 Study Group. Everolimus plus octreotide long-acting repeatable in patients with colorectal neuroendocrine tumors: a subgroup analysis of the phase III RADIANT-2 study. *Oncologist.* 2013;18(1):46-53.
37. Chan JA, Ryan DP, Zhu AX, Abrams TA, Wolpin BM, Malinowski P, Regan EM, Fuchs CS, Kulke MH. Phase I study of pasireotide (SOM 230) and everolimus (RAD001) in advanced neuroendocrine tumors. *Endocr Relat Cancer.* 2012 Sep 14;19(5):615-23.
38. Pavel ME, Hainsworth JD, Baudin E, Peeters M, Hörsch D, Winkler RE, Klimovsky J, Lebwohl D, Jehl V, Wolin EM, Oberg K, Van Cutsem E, Yao JC; RADIANT-2 Study Group. Everolimus plus octreotide long-acting repeatable for the treatment of advanced neuroendocrine tumours associated with carcinoid syndrome (RADIANT-2): a randomised, placebo-controlled, phase 3 study. *Lancet.* 2011 Dec 10;378(9808):2005-12.
39. Yao JC, Phan AT, Chang DZ, Wolff RA, Hess K, Gupta S, Jacobs C, Mares JE, Landgraf AN, Rashid A, Meric-Bernstam F. Efficacy of RAD001 (everolimus) and octreotide LAR in advanced low- to intermediate-grade neuroendocrine tumors: results of a phase II study. *J Clin Oncol.* 2008 Sep 10;26(26):4311-8.
40. Grozinsky-Glasberg S, Franchi G, Teng M, Leontiou CA, Ribeiro de Oliveira A Jr, Dalino P, Salahuddin N, Korbonits M, Grossman AB. Octreotide and the mTOR inhibitor RAD001 (everolimus) block proliferation and interact with the Akt-mTOR-p70S6K pathway in a neuro-endocrine tumour cell Line. *Neuroendocrinology.* 2008;87(3):168-81.

41. Sukumari-Ramesh S, Singh N, Dhandapani KM, Vender JR. mTOR inhibition reduces cellular proliferation and sensitizes pituitary adenoma cells to ionizing radiation. *Surg Neurol Int.* 2011 Feb 23;2:22.
42. Zatelli MC, Minoia M, Filieri C, Tagliati F, Buratto M, Ambrosio MR, Lapparelli M, Scanarini M, Degli Uberti EC. Effect of everolimus on cell viability in nonfunctioning pituitary adenomas. *J Clin Endocrinol Metab.* 2010 Feb;95(2):968-76.
43. Gorshtein A, Rubinfeld H, Kendler E, Theodoropoulou M, Cerovac V, Stalla GK, Cohen ZR, Hadani M, Shimon I. Mammalian target of rapamycin inhibitors rapamycin and RAD001 (everolimus) induce anti-proliferative effects in GH-secreting pituitary tumor cells in vitro. *Endocr Relat Cancer.* 2009 Sep;16(3):1017-27.
44. Thapar K, Kovacs K, Scheithauer BW, Stefaneanu L, Horvath E, Pernicone PJ, Murray D, Laws ER Jr. Proliferative activity and invasiveness among pituitary adenomas and carcinomas: an analysis using the MIB-1 antibody. *Neurosurgery* 1996; 38:99–106; discussion 106–107.
45. Scheithauer BW, Kurtkaya-Yapicier O, Kovacs KT, Young WF Jr, Lloyd RV. Pituitary carcinoma: a clinicopathological review. *Neurosurgery* 2005; 56:1066–1074.
46. Thapar K, Scheithauer BW, Kovacs K, Pernicone PJ, Laws ER Jr. P53 expression in pituitary adenomas and carcinomas: correlation with invasiveness and tumor growth fractions. *Neurosurgery* 1996; 38:765–770.
47. Raverot G, Jouanneau E, Trouillas J. Management of endocrine disease: clinicopathological classification and molecular markers of pituitary tumours for personalized therapeutic strategies. *Eur J Endocrinol* 2014;170: R121–R132.
48. Meij BP, Lopes MB, Ellegala DB, Alden TD, Laws ER Jr. The long-term significance of microscopic dural invasion in 354 patients with pituitary adenomas treated with transsphenoidal surgery. *J Neurosurg* 2002;96:195–208.
49. Salehi F, Agur A, Scheithauer BW, Kovacs K, Lloyd RV, Cusimano M. Ki-67 in pituitary neoplasms: a review – part I. *Neurosurgery* 2009;65:429–437;

discussion 437.

50. Heaney A. Management of aggressive pituitary adenomas and pituitary carcinomas. *J Neurooncol* 2014;117:459–468.
51. Hardy J. Transphenoidal microsurgery of the normal and pathological pituitary. *Clin Neurosurg* 1969;16:185–217.
52. Knosp E, Steiner E, Kitz K, Matula C. Pituitary adenomas with invasion of the cavernous sinus space: a magnetic resonance imaging classification compared with surgical findings. *Neuro- surgery* 1993;33:610–617.
53. Trouillas J, Roy P, Sturm N, Dantony E, Cortet-Rudelli C, Viennet G, Bonneville JF, Assaker R, Auger C, Brue T, Cornelius A, Dufour H, Jouanneau E, François P, Galland F, Mougel F, Chapuis F, Villeneuve L, Maurage CA, Figarella-Branger D, Raverot G; members of HYPOPRONOS., Barlier A, Bernier M, Bonnet F, Borson-Chazot F, Brassier G, Caulet-Maugendre S, Chabre O, Chanson P, Cottier JF, Delemer B, Delgrange E, Di Tommaso L, Eimer S, Gaillard S, Jan M, Girard JJ, Lapras V, Loiseau H, Passagia JG, Patey M, Penfornis A, Poirier JY, Perrin G, Tabarin A. A new prognostic clinicopathological classification of pituitary adenomas: a multicentric case-control study of 410 patients with 8 years post-operative follow-up. *Acta Neuropathol* 2013;126:123–135.
54. Phillips J, East HE, French SE, Melcescu E, Hamilton RD, Nicholas WC, Fratkin JF, Parent AD, Luzardo G, Koch CA: What causes a prolactinoma to be aggressive or to become a pituitary carcinoma? *Hormones* 2012;11: 477–482.
55. Mamelak AN, Carmichael JD, Park P, Bannykh S, Fan X, Bonert HV. Atypical pituitary adenoma with malignant features. *Pituitary* 2011;14:92–97.
56. Saeger W, Ludecke DK, Buchfelder M, Fahlbusch R, Quabbe HJ, Petersenn S. Pathohistological classification of pituitary tumors: 10 years of experience with the German Pituitary Tumor Registry. *Eur J Endocrinol* 2007;156: 203–216.
57. Zada G, Woodmansee WW, Ramkissoon S, Amadio J, Nose V, Laws ER Jr. Atypical pituitary adenomas: incidence, clinical characteristics, and implications.

J Neurosurg 2011; 114:336–344.

58. Yildirim AE, Divanlioglu D, Nacar OA, Dursun E, Sahinoglu M, Unal T, Belen AD. Incidence, hormonal distribution and postoperative follow up of atypical pituitary adenomas. Turk Neurosurg 2013;23:226–231.
59. Dumitrescu CE, Collins MT. McCune-Albright syndrome. Orphanet J Rare Dis. 2008 May 19;3:12.
60. Chandrasekharappa SC, Guru SC, Manickam P, Olufemi SE, Collins FS, Emmert-Buck MR, Debelenko LV, Zhuang Z, Lubensky IA, Liotta LA, Crabtree JS, Wang Y, Roe BA, Weisemann J, Boguski MS, Agarwal SK, Kester MB, Kim YS, Heppner C, Dong Q, Spiegel AM, Burns AL, Marx SJ. Positional cloning of the gene for multiple endocrine neoplasia-type 1. Science. 1997 Apr 18;276(5311):404-7.
61. Stratakis CA, Carney JA, Lin JP, Papanicolaou DA, Karl M, Kastner DL, Pras E, Chrousos GP. Carney complex, a familial multiple neoplasia and lentiginosis syndrome. Analysis of 11 kindreds and linkage to the short arm of chromosome 2. J Clin Invest. 1996 Feb 1;97(3):699-705.
62. Daly AF, Jaffrain-Rea ML, Ciccarelli A, Valdes-Socin H, Rohmer V, Tamburrano G, Borson-Chazot C, Estour B, Ciccarelli E, Brue T, Ferolla P, Emy P, Colao A, De Menis E, Lecomte P, Penfornis F, Delemer B, Bertherat J, Wémeau JL, De Herder W, Archambeaud F, Stevenaert A, Calender A, Murat A, Cavagnini F, Beckers A. Clinical characterization of familial isolated pituitary adenomas. J Clin Endocrinol Metab. 2006 Sep;91(9):3316-23.
63. Pellegata NS, Quintanilla-Martinez L, Siggelkow H, Samson E, Bink K, Höfler H, Fend F, Graw J, Atkinson MJ. Germ-line mutations in p27Kip1 cause a multiple endocrine neoplasia syndrome in rats and humans. Proc Natl Acad Sci U S A. 2006 Oct 17;103(42):15558-63.
64. Vierimaa O, Georgitsi M, Lehtonen R, Vahteristo P, Kokko A, Raitila A, Tuppurainen K, Ebeling TM, Salmela PI, Paschke R, Gündogdu S, De Menis E, Mäkinen MJ, Launonen V, Karhu A, Aaltonen LA. Pituitary adenoma predisposition caused by germline mutations in the AIP gene. Science. 2006 May 26;312(5777):1228-30.

65. Trivellin G, Daly AF, Faucz FR, Yuan B, Rostomyan L, Larco DO, Scherthaner-Reiter MH, Szarek E, Leal LF, Caberg JH, Castermans E, Villa C, Dimopoulos A, Chittiboina P, Xekouki P, Shah N, Metzger D, Lysy PA, Ferrante E, Strebkova N, Mazerkina N, Zatelli MC, Lodish M, Horvath A, de Alexandre RB, Manning AD, Levy I, Keil MF, Sierra Mde L, Palmeira L, Coppieters W, Georges M, Naves LA, Jamar M, Bours V, Wu TJ, Choong CS, Bertherat J, Chanson P, Kamenický P, Farrell WE, Barlier A, Quezado M, Bjelobaba I, Stojilkovic SS, Wess J, Costanzi S, Liu P, Lupski JR, Beckers A, Stratakis CA. Gigantism and acromegaly due to Xq26 microduplications and GPR101 mutation. *N Engl J Med*. 2014 Dec 18;371(25):2363-74.
66. Burgess JR, Shepherd JJ, Parameswaran V, Hoffman L, Greenaway TM. Prolactinomas in a large kindred with multiple endocrine neoplasia type 1: clinical features and inheritance pattern. *J Clin Endocrinol Metab* 1996; 81: 1841–1845.
67. Vergès B, Boureille F, Goudet P, Murat A, Beckers A, Sassolas G, Cougard P, Chambe B, Montvernay C, Calender A. Pituitary disease in MEN type 1 [MEN1]: data from the France-Belgium MEN1 multicenter study. *J Clin Endocrinol Metab* 2002; 87: 457–465.
68. de Laat JM, Dekkers OM, Pieterman CR, Kluijfhout WP, Hermus AR, Pereira AM, van der Horst-Schrivers AN, Drent ML, Bisschop PH, Havekes B, de Herder WW, Valk GD. Long-Term Natural Course of Pituitary Tumors in Patients With MEN1: Results From the DutchMEN1 Study Group (DMSG). *J Clin Endocrinol Metab*. 2015 Sep;100(9):3288-96.
69. Daly AF, Tichomirowa MA, Petrossians P, Heliövaara E, Jaffrain-Rea ML, Barlier A, Naves LA, Ebeling T, Karhu A, Raappana A, Cazabat L, De Menis E, Montañana CF, Raverot G, Weil RJ, Sane T, Maiter D, Neggens S, Yaneva M, Tabarin A, Verrua E, Eloranta E, Murat A, Vierimaa O, Salmela PI, Emy P, Toledo RA, Sabaté MI, Villa C, Popelier M, Salvatori R, Jennings J, Longás AF, Labarta Aizpún JI, Georgitsi M, Paschke R, Ronchi C, Valimaki M, Saloranta C, De Herder W, Cozzi R, Guitelman M, Magri F, Lagonigro MS, Halaby G, Corman V, Hagelstein MT, Vanbellinghen JF, Barra GB, Gimenez-Roqueplo AP, Cameron FJ, Borson-Chazot F, Holdaway I, Toledo SP, Stalla GK, Spada A, Zacharieva S, Bertherat J, Brue T, Bours V, Chanson P, Aaltonen LA,

- Beckers A. Clinical characteristics and therapeutic responses in patients with germ-line AIP mutations and pituitary adenomas: an international collaborative study. *J Clin Endocrinol Metab.* 2010 Nov;95(11):E373-83.
70. Zhang X, Horwitz GA, Heaney AP, Nakashima M, Prezant TR, Bronstein MD, Melmed S.. Pituitary tumor transforming gene (PTTG) expression in pituitary adenomas. *J Clin Endocrinol Metab* 1999; 84: 761–767.
71. Salehi F, Kovacs K, Scheithauer BW, Lloyd RV, Cusimano M. Pituitary tumor-transforming gene in endocrine and other neoplasms: a review and update. *Endocr Rel Cancer* 2008; 15: 721–743.
72. Filippella M, Galland F, Kujas M, Young J, Faggiano A, Lombardi G, Colao A, Meduri G, Chanson P. Pituitary tumour transforming gene (PTTG) expression correlates with the proliferative activity and recurrence status of pituitary adenomas: a clinical and immunohistochemical study. *Clin Endocrinol* 2006; 65: 536–543.
73. Asa SL, Ezzat S. The pathogenesis of pituitary tumours. *Nature Reviews. Cancer* 2002; 2: 836–849.
74. Karga HJ, Alexander JM, Hedley-Whyte ET, Klibanski A, Jameson JL. Ras mutations in human pituitary tumors. *J Clin Endocrinol Metab* 1992; 74: 914–919.
75. Herman V, Drazin NZ, Gonsky R, Melmed S. Molecular screening of pituitary adenomas for gene mutations and rearrangements. *J Clin Endocrinol Metab* 1993; 77: 50–55.
76. Boggild MD, Jenkinson S, Pistorello M, Boscaro M, Scanarini M, McTernan P, Perrett CW, Thakker RV, Clayton RN. Molecular genetic studies of sporadic pituitary tumors. *J Clin Endocrinol Metab* 1994; 78: 387–392
77. Cryns VL, Alexander JM, Klibanski A, Arnold A. The retinoblastoma gene in human pituitary tumors. *J Clin Endocrinol Metab* 1993; 77: 644–646.
78. Pei L, Melmed S, Scheithauer B, Kovacs K, Benedict WF, Prager D. Frequent loss of heterozygosity at the retinoblastoma susceptibility gene (RB) locus in aggressive pituitary tumors: evidence for a chromosome 13 tumor suppressor

- gene other than RB. *Cancer Res* 1995; 55: 1613–1616.
79. Tanizaki Y, Jin L, Scheithauer BW, Kovacs K, Roncaroli F, Lloyd RV. P53 gene mutations in pituitary carcinomas. *Endocr Pathol* 2007; 18: 217–222.
80. Sherr CJ, Roberts JM. Inhibitors of mammalian G1 cyclin- dependent kinases, *Genes Dev.* 1995; 9:1149–1163.
81. Ogino A, Yoshino A, Katayama Y, Watanabe T, Ota T, Komine C, Yokoyama T, Fukushima T. The p15(INK4b)/p16(INK4a)/RB1 pathway is frequently deregulated in human pituitary adenomas. *J Neuropathol Exp Neurol* 2005; 64: 398–403.
82. Yoshino A, Katayama Y, Ogino A, Watanabe T, Yachi K, Ohta T, Komine C, Yokoyama T, Fukushima T.. Promoter hypermethylation profile of cell cycle regulator genes in pituitary adenomas. *J Neurooncol* 2007; 83: 153–162.
83. Lloyd RV, Jin L, Qian X, Kulig E. Aberrant p27kip1 expression in endocrine and other tumors. *The American Journal of Pathology* 1997; 150: 401–407.
84. Lidhar K, Korbonits M, Jordan S, Khalimova Z, Kaltsas G, Lu X, Clayton RN, Jenkins PJ, Monson JP, Besser GM, Lowe DG, Grossman AB. Low expression of the cell cycle inhibitor p27Kip1 in normal corticotroph cells, corticotroph tumors, and malignant pituitary tumors. *J Clin Endocrinol Metab.* 1999; 84: 3823–3830.
85. Korbonits M, Chahal HS, Kaltsas G, Jordan S, Urmanova Y, Khalimova Z, Harris PE, Farrell WE, Claret FX, Grossman AB. Expression of phosphorylated p27(Kip1) protein and Jun activation domain-binding protein 1 in human pituitary tumors. *J Clin Endocrinol Metab* 2002; 87: 2635–2643.
86. Bahar A, Bicknell JE, Simpson DJ, Clayton RN, Farrell WE. Loss of expression of the growth inhibitory gene GADD45gamma, in human pituitary adenomas, is associated with CpG island methylation. *Oncogene* 2004; 23: 936–944.
87. Simpson DJ, Clayton RN, Farrell WE. Preferential loss of Death Associated Protein kinase expression in invasive pituitary tumours is associated with either CpG island methylation or homozygous deletion. *Oncogene* 2002; 21: 1217–1224.

88. Zhang X, Sun H, Danila DC, Johnson SR, Zhou Y, Swearingen B, Klibanski A. Loss of expression of GADD45 gamma, a growth inhibitory gene, in human pituitary adenomas: implications for tumorigenesis. *J Clin Endocrinol Metab.* 2002; 87: 1262–1267.
89. Powers CJ, McLeskey SW, Wellstein A. Fibroblast growth factors, their receptors and signaling. *Endocr Rel Cancer* 2000; 7: 165–197.
90. Ezzat S, Smyth HS, Ramyar L, Asa SL. Heterogenous in vivo and in vitro expression of basic fibroblast growth factor by human pituitary adenomas. *J Clin Endocrinol Metab* 1995; 80: 878–884.
91. Ezzat S, Zheng L, Zhu XF, Wu GE, Asa SL. Targeted expression of a human pituitary tumor-derived isoform of FGF receptor-4 recapitulates pituitary tumorigenesis. *J Clin Invest* 2002; 109: 69–78.
92. Qian ZR1, Sano T, Asa SL, Yamada S, Horiguchi H, Tashiro T, Li CC, Hirokawa M, Kovacs K, Ezzat S. Cytoplasmic expression of fibroblast growth factor receptor-4 in human pituitary adenomas: relation to tumor type, size, proliferation, and invasiveness. *J Clin Endocrinol Metab* 2004; 89: 1904–1911.
93. Turner HE, Harris AL, Melmed S, Wass JA (2003) Angiogenesis in endocrine tumors. *Endocr Rev* 24(5):600–632.
94. McCabe CJ, Boelaert K, Tannahill LA, Heaney AP, Stratford AL, Khaira JS, Hussain S, Sheppard MC, Franklyn JA, Gittoes NJ (2002) Vascular endothelial growth factor, its receptor KDR/Fik-1, and pituitary tumor transforming gene in pituitary tumors. *J Clin Endocrinol Metab* 87(9):4238–4244.
95. Niveiro M, Aranda FI, Peiro G, Alenda C, Pico A (2005) Immunohistochemical analysis of tumor angiogenic factors in human pituitary adenomas. *Hum Pathol* 36(10):1090–1095.
96. Kurosaki M, Saegert W, Abe T, Lüdecke DK. Expression of vascular endothelial growth factor in growth hormone-secreting pituitary adenomas: special reference to the octreotide treatment. *Neurol Res.* 2008 Jun;30(5):518-22.

97. Raica M, Coculescu M, Cimpean AM, Ribatti D. Endocrine gland derived-VEGF is down-regulated in human pituitary adenoma. *Anticancer Res.* 2010 Oct;30(10):3981-6.
98. Sánchez-Ortiga R, Sánchez-Tejada L, Moreno-Perez O, Riesgo P, Niveiro M, Picó Alfonso AM. Over-expression of vascular endothelial growth factor in pituitary adenomas is associated with extrasellar growth and recurrence. *Pituitary.* 2013 Sep;16(3):370-7.
99. Gatto F, Hofland LJ. The role of somatostatin and dopamine D2 receptors in endocrine tumors. *Endocr Relat Cancer.* 2011 Dec 1;18(6):R233-51.
100. Ben-Jonathan N, Hnasko R. Dopamine as a prolactin (PRL) inhibitor. *Endocr Rev* 2001; 22: 724–763.
101. Guillemin R. Hypothalamic hormones a.k.a. hypothalamic releasing factors. *J Endocrinol* 2005; 184: 11–28.
102. Ferone D, Gatto F, Arvigo M, Resmini E, Boschetti M, Teti C, Esposito D, Minuto F. The clinical–molecular interface of somatostatin, dopamine and their receptors in pituitary pathophysiology. *J Mol Endocrinol* 2009; 42: 361–370
103. Colao A, Auriemma RS, Pivonello R. The effects of somatostatin analogue therapy on pituitary tumor volume in patients with acromegaly. *Pituitary.* 2016 Apr;19(2):210-21.
104. Pivonello R, De Leo M, Cozzolino A, Colao A. The Treatment of Cushing's Disease. *Endocr Rev.* 2015 Aug;36(4):385-486.
105. Auriemma RS, Grasso LF, Pivonello R, Colao A. The safety of treatments for prolactinomas. *Expert Opin Drug Saf.* 2016;15(4):503-12.
106. Bruns C, Weckbecker G, Raulf F, Kaupmann K, Schoeffter P, Hoyer D, Lübbert H. Molecular pharmacology of somatostatin-receptor subtypes. *Ann NY Acad Sci* 1994; 733: 138 –146.
107. Reisine T, Bell GI. Molecular biology of somatostatin receptors. *Endocr Rev* 1995; 16:427– 442.
108. Patel YC. Molecular pharmacology of somatostatin receptor subtypes. *J Endocrinol Invest* 1997; 20:348 –367.
109. Patel YC. Somatostatin and its receptor family. *Front Neuroendocrinol* 1999; 20:157–198.

110. Patel YC, Greenwood M, Kent G, Panetta R, Srikant CB 1993 Multiple gene transcripts of the somatostatin receptor SSTR2: tissue selective distribution and cAMP regulation. *Biochem Biophys Res Commun* 192:288 – 294
111. Ballare E, Persani L, Lania AG, Filopanti M, Giammona E, Corbetta S, Mantovani S, Arosio M, Beck-Peccoz P, Faglia G, Spada A. Mutation of somatostatin receptor type 5 in an acromegalic patient resistant to somatostatin analog treatment. *J Clin Endocrinol Metab* 2001; 86:3809–3814.
112. Filopanti M, Ronchi C, Ballare E, Bondioni S, Lania AG, Losa M, Gelmini S, Peri A, Orlando C, Beck-Peccoz P, Spada. Analysis of somatostatin receptors 2 and 5 polymorphisms in patients with acromegaly. *J Clin Endocrinol Metab* 2005; 90:4824–4828.
113. Ciganoka D, Balcere I, Kapa I, Peculis R, Valtere A, Nikitina-Zake L, Lase I, Schioth HB, Pirags V, Klovins J (2011) Identification of somatostatin receptor type 5 gene polymorphisms associated with acromegaly. *Eur J Endocrinol* 165:517–525
114. Luque RM, Ibanez-Costa A, Neto LV, Taboada GF, Hormaechea-Agulla D, Kasuki L, Venegas-Moreno E, Moreno-Carazo A, Galvez MA, Soto-Moreno A, Kineman RD, Culler MD, Gahete MD, Gadelha MR, Castano JP Truncated somatostatin receptor variant sst5TMD4 confers aggressive features (proliferation, invasion and reduced octreotide response) to somatotropinomas. *Cancer Lett* 2015; 359:299–306.
115. Gatto F, Biermasz NR, Feelders RA, Kros JM, Dogan F, van der Lely AJ, Neggers SJ, Lamberts SW, Pereira AM, Ferone D, Hofland LJ. Low beta-arrestin expression correlates with the responsiveness to long-term somatostatin analog treatment in acromegaly. *Eur J Endocrinol*. 2016 May;174(5):651-62.
116. Missale C, Nash SR, Robinson SW, Jaber M, Caron MG. Dopamine receptors: from structure to function. *Physiol Rev* 1998, 78:189–225.
117. Peverelli E, Mantovani G, Vitali E, Elli FM, Olgiati L, Ferrero S, Laws ER, Della Mina P, Villa A, Beck-Peccoz P, Spada A, Lania AG. Filamin-A is essential for dopamine d2 receptor expression and signaling in tumorous lactotrophs. *J Clin Endocrinol Metab*. 2012 Mar;97(3):967-77.
118. Peverelli E, Giardino E, Treppiedi D, Vitali E, Cambiaghi V, Locatelli M, Lasio GB, Spada A, Lania AG, Mantovani G. Filamin A (FLNA) plays an

- essential role in somatostatin receptor 2 (SST2) signaling and stabilization after agonist stimulation in human and rat somatotroph tumor cells. *Endocrinology*. 2014 Aug;155(8):2932-41
119. Adjei AA, Hidalgo M. Intracellular signal transduction pathway proteins as targets for cancer therapy. *Journal of Clinical Oncology* 2005; 23: 5386–5403.
120. Dworakowska D, Wlodek E, Leontiou CA, Igreja S, Cakir M, Teng M, Prodromou N, Goth MI, Grozinsky-Glasberg S, Guerorguiev M, Kola B, Korbonits M, Grossman AB. Activation of Raf/MEK/ERK and PI3K/Akt/mTOR pathways in pituitary adenomas and their effects on downstream effectors. 2009; *Endocr Relat Cancer* 16(4):1329-1338
121. Fruman DA, Rommel C. PI3K and cancer: lessons, challenges and opportunities. *Nat Rev Drug Discov*. 2014 Jan 31;13(2):140-56.
122. Rodriguez-Viciano P, Warne PH, Khwaja A, Marte BM, Pappin D, Das P, Waterfield MD, Ridley A, Downward J. Role of phosphoinositide 3-OH kinase in cell transformation and control of the actin cytoskeleton by Ras. *Cell* 1997; 89: 457–467.
123. Kauffmann-Zeh A, Rodriguez-Viciano P, Ulrich E, Gilbert C, Coffey P, Downward J, Evan G. Suppression of c-Myc-induced apoptosis by Ras signalling through PI(3)K and PKB. *Nature* 1997; 385: 544–548.
124. De Martino MC, van Koetsveld PM, Pivonello R, Hofland LJ. Role of the mTOR pathway in normal and tumoral adrenal cells. *Neuroendocrinology*. 2010;92 Suppl 1:28-34.
125. Inoki K, Li Y, Zhu T, Wu J, Guan KL. TSC2 is phosphorylated and inhibited by Akt and suppresses mTOR signalling. *Nature Cell Biology* 2002; 4: 648–657.
126. Sonenberg N, Gingras AC. The mRNA 50 cap-binding protein eIF4E and control of cell growth. *Current Opinion in Cell Biology* 1998; 10: 268–275.
127. Rosenwald IB, Kaspar R, Rousseau D, Gehrke L, Le Boulch P, Chen JJ, Schmidt EV, Sonenberg N, London IM. Eukaryotic translation initiation factor 4E regulates expression of cyclin D1 at transcriptional and post-transcriptional levels. *The Journal of Biological Chemistry* 1995; 270: 21176–21180.
128. Musat M, Korbonits M, Kola B, Borboli N, Hanson MR, Nanzer AM, Grigson J, Jordan S, Morris DG, Gueorguiev M, Coculescu M, Basu S,

- Grossman AB. Enhanced protein kinase B/Akt signalling in pituitary tumours. *Endocrine-related Cancer* 2005; 12: 423–433.
129. Dworakowska D, Grossman A. Are neuroendocrine tumours a feature of tuberous sclerosis? *Endocrine-related Cancer* 2009; 16: 45–58.
130. Haystead TA, ent P, Wu J, Haystead CM, Sturgill TW. Ordered phosphorylation of p42mapk by MAP kinase kinase. *FEBS Letters* 1992; 306: 17–22.
131. Terada Y, Nakashima O, Inoshita S, Kuwahara M, Sasaki S, Marumo F. Mitogen-activated protein kinase cascade and transcription factors: the opposite role of MKK3/6-p38K and MKK1-MAPK. *Nephrology, Dialysis, Transplantation* 1999; 14(Suppl. 1): 45–47.
132. Terada Y, Inoshita S, Nakashima O, Kuwahara M, Sasaki S, Marumo F. Regulation of cyclin D1 expression and cell cycle progression by mitogen-activated protein kinase cascade. *Kidney Int.* 1999 Oct;56(4):1258-61.
133. Guan KL. The mitogen activated protein kinase signal transduction pathway: from the cell surface to the nucleus. *Cellular Signalling* 1994; 6: 581–589.
134. Joneson T, Bar-Sagi D. Ras effectors and their role in mitogenesis and oncogenesis. *Journal of Molecular Medicine* 1997; 75: 587–593.
135. Gueorguiev M, Grossman AB. Pituitary gland and beta-catenin signaling: from ontogeny to oncogenesis. *Pituitary* 2008.
136. Ewing I, Pedder-Smith S, Franchi G, Ruscica M, Emery M, Vax V, Garcia E, Czirják S, Hanzély Z, Kola B, Korbonits M, Grossman AB. A mutation and expression analysis of the oncogene BRAF in pituitary adenomas. *Clinical Endocrinology* 2007; 66: 348–352.
137. Dworakowska D, Wlodek E, Leontiou CA, Igreja S, Cakir M, Teng M, Prodromou N, Góth MI, Grozinsky-Glasberg S, Gueorguiev M, Kola B, Korbonits M, Grossman AB. Activation of RAF/MEK/ERK and PI3K/AKT/mTOR pathways in pituitary adenomas and their effects on downstream effectors. *Endocr Relat Cancer.* 2009 Dec;16(4):1329-38.
138. McCubrey JA, Steelman LS, Abrams SL, Lee JT, Chang F, Bertrand FE, Navolanic PM, Terrian DM, Franklin RA, D'Assoro AB, Salisbury JL, Mazzarino MC, Stivala F, Libra M. Roles of the RAF/MEK/ERK and PI3K/PTEN/AKT pathways in malignant transformation and drug resistance. *Advances in Enzyme Regulation* 2006; 46: 249–279.

139. Chang E, Sughrue M, Zada G, Wilson C, Blevins L Jr, Kunwar S. Long term outcome following repeat transsphenoidal surgery for recurrent endocrine-inactive pituitary adenomas. *Pituitary* 2010; 13: 223–229.
140. Benveniste RJ, King WA, Walsh J, Lee JS, Delman BN, Post KD. Repeated transsphenoidal surgery to treat recurrent or residual pituitary adenoma. *J Neurosurg* 2005; 102:1004–1012.
141. Patil CG, Veeravagu A, Prevedello DM, Katznelson L, Vance ML, Laws ER Jr. Outcomes after repeat transsphenoidal surgery for recurrent Cushing's disease. *Neurosurgery* 2008; 63: 266–270.
142. Karavitaki N, Turner HE, Adams CB, Cudlip S, Byrne JV, Fazal-Sanderson V, Rowles S, Trainer PJ, Wass JA. Surgical debulking of pituitary macroadenomas causing acromegaly improves control by lanreotide. *Clin Endocrinol (Oxf)*. 2008 Jun;68(6):970-5.
143. Petrossians P, Borges-Martins L, Espinoza C, Daly A, Betea D, Valdes-Socin H, Stevenaert A, Chanson P, Beckers A. Gross total resection or debulking of pituitary adenomas improves hormonal control of acromegaly by somatostatin analogs. *Eur J Endocrinol*. 2005 Jan;152(1):61-6.
144. Colao A, Attanasio R, Pivonello R, Cappabianca P, Cavallo LM, Lasio G, Lodrini A, Lombardi G, Cozzi R. Partial surgical removal of growth hormone-secreting pituitary tumors enhances the response to somatostatin analogs in acromegaly. *J Clin Endocrinol Metab*. 2006 Jan;91(1):85-92.
145. Prasad D. Clinical results of conformal radiotherapy and radiosurgery for pituitary adenoma. *Neurosurg Clin N Am* 2006; 17:129-41.
146. Gittoes NJ. Radiotherapy for non-functioning pituitary tumors – when and under what circumstances? *Pituitary* 2003; 6: 103–108.
147. Kopp C, Theodorou M, Poulos N, Jacob V, Astner ST, Molls M, Grosu AL. Tumor shrinkage assessed by volumetric MRI in long-term follow-up after fractionated stereotactic radiotherapy of nonfunctioning pituitary adenoma. *Int J Radiat Oncol Biol Physics* 2012; 82: 1262–1267.
148. Sheehan JP, Niranjan A, Sheehan JM, Jane JA Jr, Laws ER, Kondziolka D, Flickinger J, Landolt AM, Loeffler JS, Lunsford LD. Stereotactic radiosurgery for pituitary adenomas: an intermediate review of its safety, efficacy, and role in the neurosurgical treatment armamentarium. *J Neurosurg* 2005; 102: 678–691.

149. Castinetti F, Regis J, Dufour H, Brue T. Role of stereotactic radiosurgery in the management of pituitary adenomas. *Nat Rev Endocrinol* 2010; 6: 214–223
150. Mountcastle RB, Roof BS, Mayfield RK, Mordes DB, Sagel J, Biggs PJ, Rawe SE. Pituitary adenocarcinoma in an acromegalic patient: response to bromocriptine and pituitary testing: a review of the literature on 36 cases of pituitary carcinoma. *Am J Med Sci* 1989; 298: 109–118.
151. Rowe J, Grainger A, Walton L, Silcocks P, Radatz M, Kemeny A. Risk of malignancy after gamma knife stereotactic radiosurgery. *Neurosurgery* 2007; 60: 60–65.
152. Kaltsas GA, Mukherjee JJ, Plowman PN, Monson JP, Grossman AB, Besser GM. The role of cytotoxic chemotherapy in the management of aggressive and malignant pituitary tumors. *J Clin Endocrinol Metab* 1998; 83: 4233–4238
153. Vaughan NJ, Laroche CM, Goodman I, Davies MJ, Jenkins JS. Pituitary Cushing's disease arising from a previously non-functional corticotrophic chromophobe adenoma. *Clin Endocrinol* 1985; 22: 147–153.
154. Kasperlik-Zaluska AA, Wislawski J, Kaniewska J, Zborzil J, Frankiewicz E, Zgliczynski S: Cytostatics for acromegaly. Marked improvement in a patient with an invasive pituitary tumour. *Acta Endocrinol* 1987; 116: 347–349.
155. Asai A, Matsutani M, Funada N, Takakura K. Malignant growth hormone-secreting pituitary adenoma with haematogenous dural metastasis: case report. *Neurosurgery* 1988; 22:1091-4.
156. Kaiser FE, Orth DN, Mukai K, Oppenheimer JH. A pituitary parasellar tumour with extracranial metastases and high, partially suppressible levels of adrenocorticotropin and related peptides. *J Clin Endocrinol Metab* 1983;57:649-53.
157. Gollard R, Kosty M, Cheney C, Copeland B, Bordin G. Prolactin secreting pituitary carcinoma with implants in the cheek pouch and metastases to the ovaries. *Cancer* 1995;76:1814-20
158. Syro LV, Uribe H, Penagos LC, Ortiz LD, Fadul CE, Horvath E, Kovacs K. Antitumour effects of temozolomide in a man with a large, invasive prolactin-producing pituitary neoplasm. *Clin Endocrinol* 2006; 65: 552–553.

159. Neff LM, Weil M, Cole A, Hedges TR, Shucart W, Lawrence D, Zhu JJ, Tischler AS, Lechan RM. Temozolomide in the treatment of an invasive prolactinoma resistant to dopamine agonists. *Pituitary* 2007; 10: 81–86.
160. Fadul Fadul CE, Kominsky AL, Meyer LP, Kingman LS, Kinlaw WB, Rhodes CH, Eskey CJ, Simmons NE. Long-term response of pituitary carcinoma to temozolomide. Report of two cases. *J Neurosurg* 2006; 105: 621–626.
161. Bush ZM, Longtine JA, Cunningham T, Schiff D, Jane JA Jr, Vance ML, Thorner MO, Laws ER Jr, Lopes MB. Temozolomide treatment for aggressive pituitary tumors: correlation of clinical outcome with O(6)-methylguanine methyltransferase (MGMT) promoter methylation and expression. *J Clin Endocrinol Metab.* 2010 Nov;95(11):E280-90.
162. Hirohata T, Asano K, Ogawa Y, Takano S, Amano K, Isozaki O, Iwai Y, Sakata K, Fukuhara N, Nishioka H, Yamada S, Fujio S, Arita K, Takano K, Tominaga A, Hizuka N, Ikeda H, Osamura RY, Tahara S, Ishii Y, Kawamata T, Shimatsu A, Teramoto A, Matsuno A. DNA mismatch repair protein (MSH6) correlated with the responses of atypical pituitary adenomas and pituitary carcinomas to temozolomide: the national cooperative study by the Japan Society for Hypothalamic and Pituitary Tumors. *J Clin Endocrinol Metab.* 2013 Mar;98(3):1130-6
163. Bengtsson D, Schröder HD, Andersen M, Maiter D, Berinder K, Feldt Rasmussen U, Rasmussen ÅK, Johannsson G, Hoybye C, van der Lely AJ, Petersson M, Ragnarsson O, Burman P. Long-term outcome and MGMT as a predictive marker in 24 patients with atypical pituitary adenomas and pituitary carcinomas given treatment with temozolomide. *J Clin Endocrinol Metab.* 2015 Apr;100(4):1689-98.
164. Bruno OD, Juárez-Allen L, Christiansen SB, Manavela M, Danilowicz K, Vigovich C, Gómez RM. Temozolomide Therapy for Aggressive Pituitary Tumors: Results in a Small Series of Patients from Argentina. *Int J Endocrinol.* 2015;2015:587893.
165. Ceccato F, Lombardi G, Manara R, Emanuelli E, Denaro L, Milanese L, Gardiman MP, Bertorelle R, Scanarini M, D'Avella D, Occhi G, Boscaro M, Zagonel V, Scaroni C. Temozolomide and pasireotide treatment for aggressive pituitary adenoma: expertise at a tertiary care center. *J Neurooncol.* 2015 Mar;122(1):189-96.

166. Losa M, Bogazzi F, Cannavo S, Ceccato F, Curtò L, De Marinis L, Iacovazzo D, Lombardi G, Mantovani G, Mazza E, Minniti G, Nizzoli M, Reni M, Scaroni C. Temozolomide therapy in patients with aggressive pituitary adenomas or carcinomas. *J Neurooncol.* 2016 Feb;126(3):519-25.
167. Kovacs K, Horvath E, Syro LV, Uribe H, Penagos LC, Ortiz LD, Fadul CE. Temozolomide therapy in a man with an aggressive prolactin-secreting pituitary neoplasm: morphological findings. *Hum Pathol* 2007; 38: 185–189.
168. Syro LV, Scheithauer BW, Ortiz LD, Fadul CE, Horvath E, Rotondo F, Kovacs K. Effect of temozolomide in a patient with recurring oncocytic gonadotrophic pituitary adenoma. *Hormones* 2009; 8: 303–306.
169. Thearle MS, Freda PU, Bruce JN, Isaacson SR, Lee Y, Fine RL. Temozolomide (temodar(r)) and capecitabine (xeloda(r)) treatment of an aggressive corticotroph pituitary tumor. *Pituitary* 2011; 14: 418–424.
170. Bode H, Seiz M, Lammert A, Brockmann MA, Back W, Hammes HP, Thome C. Som230 (pasireotide) and temozolomide achieve sustained control of tumour progression and ACTH secretion in pituitary carcinoma with widespread metastases. *Exp Clin Endocrinol Diabetes* 2010; 118: 760– 763.
171. Ibáñez-Costa A, Rivero-Cortés E, Vázquez-Borrego MC, Gahete MD, Jiménez-Reina L, Venegas-Moreno E, de la Riva A, Arráez MÁ, González-Molero I, Schmid HA, Maraver-Selfa S, Gavilán-Villarejo I, García-Arnés JA, Japón MA, Soto-Moreno A, Gálvez MA, Luque RM, Castaño JP. Octreotide and pasireotide (dis)similarly inhibit pituitary tumor cells in vitro. *J Endocrinol.* 2016 Nov;231(2):135-145.
172. Cives M, Kunz PL, Morse B, Coppola D, Schell MJ, Campos T, Nguyen PT, Nandoskar P, Khandelwal V, Strosberg JR. Phase II clinical trial of pasireotide long-acting repeatable in patients with metastatic neuroendocrine tumors. *Endocr Relat Cancer.* 2015 Feb;22(1):1-9.
173. van Hoek M, Hofland LJ, de Rijke YB, van Nederveen FH, de Krijger RR, van Koetseveld PM, Lamberts SW, van der Lely AJ, de Herder WW, Feelders RA. Effects of somatostatin analogs on a growth hormone-releasing hormone secreting bronchial carcinoid, in vivo and in vitro studies. *J Clin Endocrinol Metab.* 2009; 94:428–433
174. Somnay Y, Chen H, Kunnimalaiyaan M. Synergistic effect of pasireotide and teriflunomide in carcinoids in vitro. *Neuroendocrinology.* 2013; 97:183–192.

175. Ono K, Suzuki T, Miki Y, Taniyama Y, Nakamura Y, Noda Y, Watanabe M, Sasano H. Somatostatin receptor subtypes in human nonfunctioning neuroendocrine tumors and effects of somatostatin analogue SOM230 on cell proliferation in cell line NCI-H727. *Anticancer Res.* 2007; 27:2231–2239.
176. Sheppard M, Bronstein MD, Freda P, Serri O, De Marinis L, Naves L, Rozhinskaya L, Hermosillo Reséndiz K, Ruffin M, Chen Y, Colao A. Pasireotide LAR maintains inhibition of GH and IGF-1 in patients with acromegaly for up to 25 months: results from the blinded extension phase of a randomized, double-blind, multicenter, Phase III study. *Pituitary.* 2015 Jun;18(3):385-94.
177. Bronstein MD, Fleseriu M, Negggers S, Colao A, Sheppard M, Gu F, Shen CC, Gadelha M, Farrall AJ, Hermosillo Reséndiz K, Ruffin M, Chen Y, Freda P; Pasireotide C2305 Study Group. *BMC Endocr Disord.* 2016 Apr 2;16:16.
178. Simeoli C, Auriemma RS, Tortora F, De Leo M, IacuanIELLO D, Cozzolino A, De Martino MC, Pivonello C, Mainolfi CG, Rossi R, Cirillo S, Colao A, Pivonello R. The treatment with pasireotide in Cushing's disease: effects of long-term treatment on tumor mass in the experience of a single center. *Endocrine.* 2015 Dec;50(3):725-40.
179. Trementino L, Cardinaletti M, Concettoni C, Marcelli G, Boscaro M, Arnaldi G. Up-to 5-year efficacy of pasireotide in a patient with Cushing's disease and pre-existing diabetes: literature review and clinical practice considerations. *Pituitary.* 2015 Jun;18(3):359-65.
180. Trementino L, Michetti G, Angeletti A, Marcelli G, Concettoni C, Cardinaletti C, Polenta B, Boscaro M, Arnaldi G. A Single-Center 10-Year Experience with Pasireotide in Cushing's Disease: Patients' Characteristics and Outcome. *Horm Metab Res.* 2016 May;48(5):290-8.
181. Katznelson L. Sustained improvements in plasma ACTH and clinical status in a patient with Nelson's syndrome treated with pasireotide LAR, a multireceptor somatostatin analog. *J Clin Endocrinol Metab.* 2013 May;98(5):1803-7.
182. Shimon I, Jallad RS, Fleseriu M, Yedinak CG, Greenman Y, Bronstein MD. Giant GH-secreting pituitary adenomas: management of rare and aggressive pituitary tumors. *Eur J Endocrinol.* 2015 Jun;172(6):707-13.

183. Greenman Y, Stern N. Paradoxical and atypical responses to pasireotide in aggressive ACTH-secreting pituitary tumors. *Pituitary*. 2016 Dec;19(6):605-611.
184. Lu C, Willingham MC, Furuya F, Cheng SY. Activation of phosphatidylinositol 3-kinase signaling promotes aberrant pituitary growth in a mouse model of thyroid-stimulating hormone-secreting pituitary tumors. *Endocrinology* 2008; 149: 3339–3345.
185. Jouanneau E, Wierinckx A, Ducray F, Favrel V, Borson-Chazot F, Honnorat J, Trouillas J, Raverot G. New targeted therapies in pituitary carcinoma resistant to temozolomide. *Pituitary*. 2012 Mar;15(1):37-43.
186. Donovan LE, Arnal AV, Wang SH, Oda Y. Widely metastatic atypical pituitary adenoma with mTOR pathway STK11(F298L) mutation treated with everolimus therapy. *CNS Oncol*. 2016 Oct;5(4):203-9
187. Chatzellis E, Alexandraki KI, Androulakis II, Kaltsas G. Aggressive pituitary tumors. *Neuroendocrinology*. 2015;101(2):87-104.
188. Di Sarno A, Landi ML, Cappabianca P, Di Salle F, Rossi FW, Pivonello R, Di Somma C, Faggiano A, Lombardi G, Colao A. Resistance to cabergoline as compared with bromocriptine in hyperprolactinemia: prevalence, clinical definition, and therapeutic strategy. *J Clin Endocrinol Metab*. 2001 Nov;86(11):5256-61.
189. Colao A, Auriemma RS, Lombardi G, Pivonello R. Resistance to somatostatin analogs in acromegaly. *Endocr Rev*. 2011 Apr;32(2):247-71.
190. Salazar R, Reidy-Lagunes D, Yao J. Potential synergies for combined targeted therapy in the treatment of neuroendocrine cancer. *Drugs*. 2011 May 7;71(7):841-52.

Table 1: Classification of pituitary tumors according to the WHO

PRL-secreting adenoma (lactotroph adenoma or prolactinoma)	
	Densely granulated
	Sparsely granulated
GH-secreting adenoma (somatotroph adenoma)	
<i>Monohormonal</i>	Densely granulated
	Sparsely granulated
<i>Plurihormonal</i>	Mixed GH-PRL
	Mammomatotroph
	Acidophilic stem cell
ACTH-secreting adenoma (corticotroph adenoma)	
	Densely granulated
	Sparsely granulated
	Silent corticotroph subtype 1 and 2
TSH-secreting adenoma (thyrotroph adenoma)	
	Densely granulated
	Sparsely granulated
FSH/LH adenoma (gonadotroph adenoma or non-functioning adenoma-NFA)	
Null-cell adenoma (oncocytoma)	
Various	Silent subtype 3 tumor
	Plurihormonal

Table 2: Response to temozolomide in patients with pituitary aggressive tumors and carcinomas

Reference	Author, yr	Patient No	Cycle No	Response	Stabilization	Progression
21	Losa, 2010	6	12	2/6	2/6	2/6
23	Raverot, 2010	8	9	3/8	-	5/8
161	Bush, 2010	7	9	2/7	4/7	1/7
162	Hiroata, 2013	13	12	9/13	2/13	2/13
163	Bengtsson, 2015	24	10	11/24	4/24	9/24
164	Bruno, 2015	6	9	2/6	-	4/6
165	Ceccato, 2015	5	11	2/5	1/5	2/5
166	Losa, 2016	31	Up to 12	11/31	14/31	6/31
TOTAL				42/100	27/86	31/100
				42%	31%	31%

Table 3: Primers sequences and concentrations used in the current study.

Gene	Primer	Efficiency
SSTR1	Forward: 5' – TGAGTCAGCTGTCCGGTCATC – 3'	1.81
	Reverse: 5' – AACTGTAGGCACGGCTCTT – 3'	
SSTR2	Forward: 5' – TCGGCCAAGTGGAGGAGAC – 3'	1.86
	Reverse: 5' – AGAAGACTCCCCACACAGCCA – 3'	
SSTR3	Forward: 5' – CTGGGTAACCTCGCTGGTCATCTA – 3'	1.9
	Reverse: 5' – AGCGCCAGGTTGAGGATGTA – 3'	
SSTR5	Forward: 5' - CATCCTCTCCTACGCCACACG – 3'	2
	Reverse: 5' – GGAAGCTCTGGCGGAAGTT – 3'	
DRD2	Forward: 5' - CAAGACCATGAGCCGTAGGAA – 3'	2
	Reverse: 5' – CGGGATGTTGCAGTCACAGT – 3'	
mTOR	Forward: 5' - TGCTGCGTGTCTTCATGCAT - 3'	2
	Reverse: 5' - GGATTGCAGCCAGTAACTTGATAG - 3'	
p70	Forward: 5' - TGGAAGACACTGCCTGCTTTT – 3'	2
	Reverse: 5' – TGATCCCCTTTTGATGTAAATGC - 3'	
4EBP1	Forward: 5' – GGCGGCACGCTCTTCA – 3'	1.8
	Reverse: 5' - TCAGGAATTTCCGGTCATAGATG – 3'	
IGF1R	Forward: 5' - CCAAACTGAAGCCGAGAAG – 3'	2
	Reverse: 5' – GGGTCGGTGATGTTGTAGGT – 3'	
IRA	Forward: 5' – CGTTTGAGGATTACCTGCACAA – 3'	2
	Reverse: 5' – GCCAAGGGACCTGCGTTT – 3'	
IRB	Forward: 5' – CCCAGAAAAACCTCTTCAGGC – 3'	2
	Reverse: 5' – GGACCTGCGTTTCCGAGA – 3'	
β-Actin	Forward: 5' – TCCTCCTGGGCATGGAG – 3'	1.7
	Reverse: 5' – AGGAGGAGCAATGATCTTGATCTT – 3'	

Table 4: Patient profile at study entry

Patient number	633
Male/Female	396/237
Age at diagnosis	40.3±15.7
Non-secreting tumors	197 (31.1%)
Secreting tumors	436 (68.9%)
PRL-secreting adenomas	218 (34.4%)
GH-secreting adenomas	118 (18.6%)
GH silent	4 (0.6%)
GH and PRL-cosecreting adenomas	34 (5.4%)
ACTH-secreting adenomas	40 (6.3%)
ACTH silent	5 (0.8%)
TSH-secreting adenomas	3 (0.5%)
FSH/LH-secreting adenomas	21 (3.3%)
NFA	152 (24%)
Craniopharyngiomas	32 (5%)
Carcinomas	6 (0.9%)

Abbreviations: NFA= non-functioning pituitary adenomas

Table 5: comparison of non-atypical non-malignant versus atypical tumors and carcinomas.

	Non-atypical Non-malignant	Atypical and malignant	P
Active disease (%)	56.3	52.3	0.51
Disease remission (%)	43.7	42.9	0.96
Deaths (%)	3.2	4.7	0.63
PRL-secreting (%)	16.1	33.6	<0.001
GH-secreting (%)	22.8	14	0.06
ACTH-secreting (%)	7.2	17.7	0.002
NFA (%)	27.2	29.9	0.42
Silent tumors (%)	5.1	4.7	0.94
Macroadenomas (%)	79.6	89.7	0.021
Microadenomas (%)	20.3	10.3	0.022
Giant tumors (%)	22.4	35.4	0.013
ACTH-secreting tumor > 1 cm (%)	3.4	12,1	<0.001
Tumor >2 cm in children (%)	3.8	1	
Maximal tumor diameter (cm)	2.97±1.68	3.7±2.0	0.0001
Tumor growth (%)	20.6	36.3	0.003
Disease recurrence (%)	14.1	21.5	0.05
Tumor invasiveness			
Cavernous sinus-bilateral (%)	36.9	38.3	0.07
Cavernous sinus-monolateral (%)	46.2	36.4	0.08
Third ventricle (%)	27	20.5	0.20
Sellar floor (%)	33.8	36.4	0.69
Extension-laterosellar (%)	38.2	48.6	0.04
Extension-suprasellar (%)	65.6	72.9	0.09
Headache (%)	45.6	49.5	0.53
Visual field deterioration (%)	39.9	45.8	0.03
Sudden visual loss (%)	15.6	20.5	0.27
Intracranial hypertension (%)	10.3	11.2	0.92

Pituitary aggressive tumors and carcinomas: epidemiological, molecular, clinical, radiological, pathological and therapeutic characterization

Renata S. Auriemma

CSF leak (%)	4.9	2.3	0.35
Hypopituitarism			
Hypogonadism (%)	48.3	36.5	0.03
Hypothyroidism (%)	31.5	25.2	0.24
Hypocortisolism (%)	18.4	23.4	0.29
GH deficiency (%)	21.3	15	0.18
Diabetes insipidus (%)	5.3	3.7	0.65
Panhypopituitarism (%)	12.7	14	0.84
Resistance to medical therapy (%)	55.7	61.7	0.30
DA (%)	36.5	69.7	<0.001
SA (%)	19.6	27.3	0.98
Surgery			
Trans-sphenoidal (%)	79.8	75.9	0.43
Trans-cranial (%)	20.1	24.1	0.44
Radiotherapy (%)	18.8	34.6	<0.001
CER (%)	55.5	75.7	<0.001
RS (%)	44.5	24.3	<0.001
Second course pharmacotherapy (%)	37.4	62.6	<0.001
DA (%)	48.7	83.6	<0.001
SA (%)	35.5	61.2	<0.001
Disease control (%)	21.5	13.1	0.05
No disease control (%)	78.5	86.9	0.04

Abbreviations: NFA= non-functioning pituitary adenomas; CSF= cerebrospinal fluid; DA= dopamine-agonists; SA= somatostatin analogs; CER= conventional external radiotherapy; RS= radiosurgery.

LEGEND TO FIGURES

Figure 1: Hardy's (left) and Knosp's (right) classification of pituitary tumor invasiveness. In Hardy's classification, upper panel shows the classification of sphenoid bone invasion: grade 0= intact with normal contour; grade I= intact with bulging floor; grade II= intact, with enlarged fossa; grade III= localized sellar destruction; grade IV: diffuse destruction. Only grade III and IV tumors are considered invasive. Lower panel depicts a classification of the suprasellar extension of an adenoma which may be symmetrical or asymmetrical: grade A= suprasellar cistern only; grade B= recess of the third ventricle; grade C= whole anterior third ventricle; grade D= intracranial extradural; grade E= extracranial extradural (cavernous sinus). According to Knosp's classification, Grade 0= the adenoma does not pass the tangent of the medial aspects of the internal carotid artery (ICA); grade I= the medial tangent is passed, but the extension does not go beyond the intercarotid line, which is the line drawn between the cross-sectional centers of the intra- and supracavernous ICA; Grade II= the tumor is extending beyond the intercarotid line, but not beyond or tangent to the lateral aspects of the intra- and supracavernous ICA; Grade III = the tumor is extending laterally to the lateral tangent of the intra- and

supracavernous ICA; Grade IV= total encasement of the intracavernous carotid artery. Adapted from references 51 and 52.

Figure 2: Characterization of SSTRs, IGF1R, IRA, IRB and mTOR pathway components in human somatotroph tumors. RT-qPCR analysis revealed that non-aggressive somatotroph tumor cells expressed slightly but non significantly higher levels of SSTRs (Panel A) and IGF1R (Panel B) compared with aggressive somatotroph tumor cells. No significant difference in mTOR components expression has been found between the two groups of somatotroph tumors (Panel C).

Figure 3: Effects of PAS, EVE and PAS+EVE on SSTR gene transcription regulation in non-aggressive (Panel A) and aggressive (Panel B) somatotroph tumors. PAS+EVE did not induce gene transcription regulation after 1h of treatment, although a trend in increasing SSTR expression has been observed in non-aggressive somatotroph tumors (Panel A).

Figure 4: Effects of different treatments on cell proliferation. In non-aggressive somatotroph tumors, only PAS 10⁻⁶

$^8\text{M}+\text{EVE}$ 10^{-7}M significantly reduced cell proliferation by 30%, whereas the same drugs used alone did not significantly change cell proliferation at tested doses (Panel A). OCT, both used alone and in combination with EVE, did not significantly change cell proliferation at tested doses (Panel B). In 5 aggressive somatotroph tumors, neither PAS, EVE, nor PAS+EVE significantly inhibited cell proliferation at tested doses (Panel C). In 2 non-aggressive somatotroph tumors and in 1 aggressive somatotroph tumor TMZ did not significantly change cell proliferation at tested doses (Panel D).

Figure 5: Effects of different treatments on GH secretion. In 5 non-aggressive somatotroph tumors, as compared to the control PAS, EVE and PAS+EVE significantly reduced GH secretion by 23,73% ($p<0.01$), 21% ($p<0.05$) and 28,96 % ($p<0.001$), respectively (Panel A). In 2 non-aggressive somatotroph tumors OCT alone or combined with EVE did not significantly reduce GH secretion (Panel B). In 5 aggressive somatotroph tumors, PAS induced the significant GH secretion inhibition when used alone (27,28%, $p<0.01$) and combined with EVE (37%, $p<0.0001$ vs control, $p<0.001$ vs EVE alone) (Panel C). In non-aggressive somatotroph tumors TMZ did

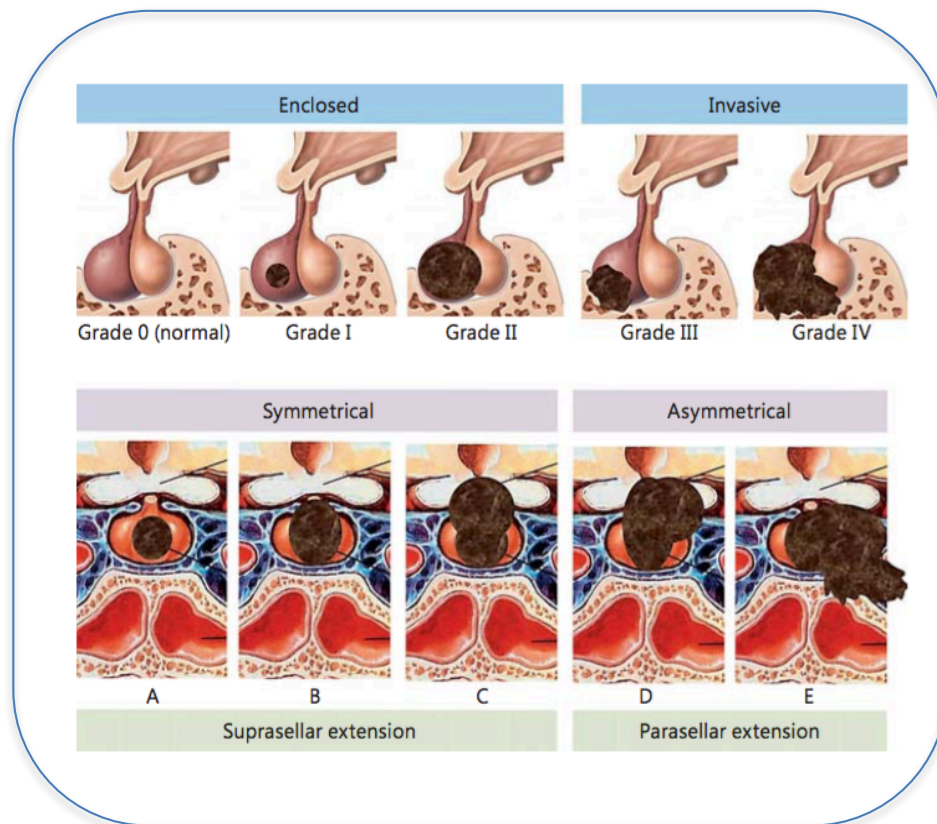
not significantly reduce GH secretion, and in aggressive somatotroph tumors it increased GH secretion ($p < 0.01$) probably due GH excretion most likely because of its cytotoxic effect (Panel D).

Figure 6: Mortality in the whole cohort of patients with pituitary aggressive tumors and carcinomas. Causes of death included tumor progression (TP) in 10 (45.4%), cerebrovascular accidents (CVA) in 8 (36.4%), heart stroke (HS) in 3 (13.6%) and other malignancy in 1 (4.5%).

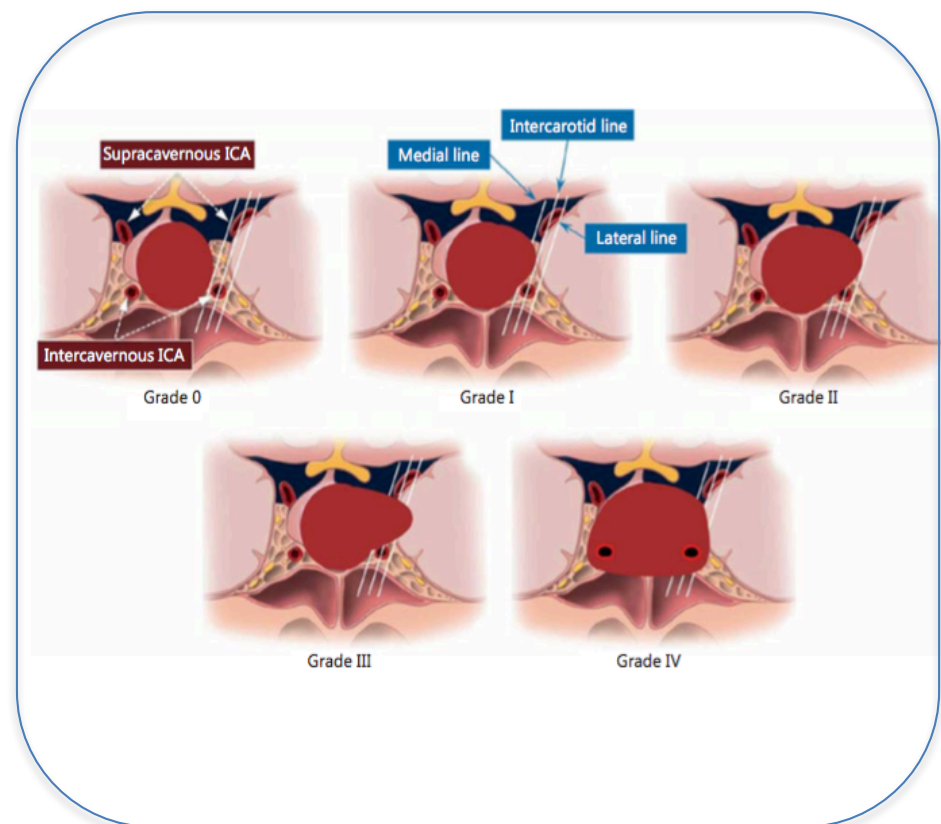
Figure 7: Distribution of pituitary tumor histotypes. NFA= 27.6%; GH-secreting tumors= 21.3%; GH and PRL-cosecreting tumors= 7.7%; PRL-secreting tumors= 20.8%; ACTH-secreting pituitary tumors= 9%; craniopharyngiomas (CP)= 7.4%; FSH/LH-secreting pituitary tumors= 5.8%.

Figure 8: Comparison of non-atypical non-malignant tumors *versus* atypical tumors and carcinomas. Rate of tumor growth ($p = 0.003$), disease recurrence ($p = 0.05$), and laterosellar extension was significantly higher in patients with atypical tumors and carcinomas

as compared to those with non-atypical non-malignant tumors. Invasion of cavernous sinus, third ventricle and sellar floor, and suprasellar extension were similarly reported in both groups of patients.



Hardy's classification



Knosp's classification

Figure 1: Hardy's (left) and Knosp's (right) classification of pituitary tumor invasiveness. In Hardy's classification, upper panel shows the classification of sphenoid bone invasion: grade 0= intact with normal contour; grade I= intact with bulging floor; grade II= intact, with enlarged fossa; grade III= localized sellar destruction; grade IV: diffuse destruction. Only grade III and IV tumors are considered invasive. Lower panel depicts a classification of the suprasellar extension of an adenoma which may be symmetrical or asymmetrical: grade A= suprasellar cistern only; grade B= recess of the third ventricle; grade C= whole anterior third ventricle; grade D= intracranial extradural; grade E= extracranial extradural (cavernous sinus). According to Knosp's classification, Grade 0= the adenoma does not pass the tangent of the medial aspects of the internal carotid artery (ICA); grade I= the medial tangent is passed, but the extension does not go beyond the intercarotid line, which is the line drawn between the cross-sectional centers of the intra- and supracavernous ICA; Grade II= the tumor is extending beyond the intercarotid line, but not beyond or tangent to the lateral aspects of the intra- and supracavernous ICA; Grade III = the tumor is extending laterally to the lateral tangent of the intra- and supracavernous ICA; Grade IV= total encasement of the intracavernous carotid artery. Adapted from references 50 and 51.

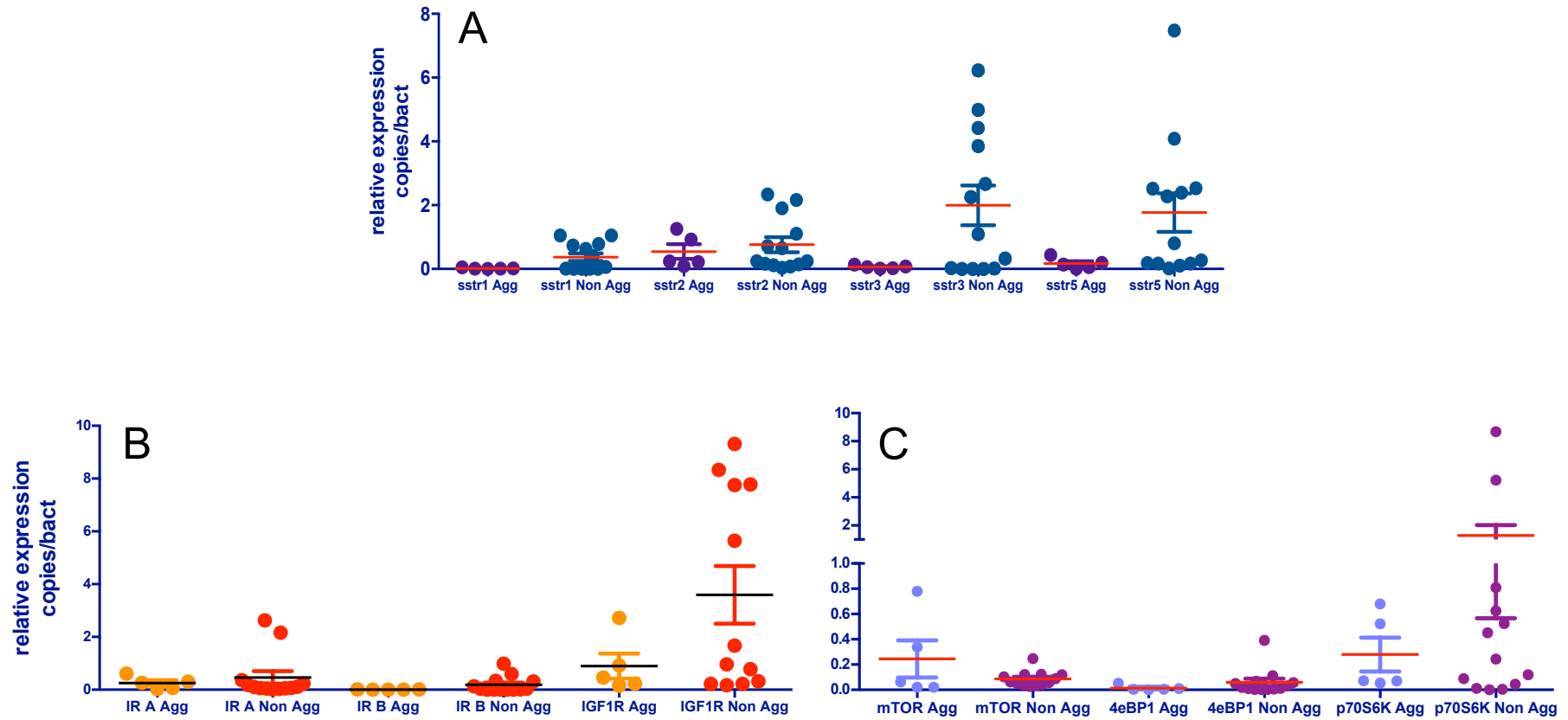


Figure 2: Characterization of SSTRs, IGF1R, IRA, IRB and mTOR pathway components in human somatotroph tumors. RT-qPCR analysis revealed that non-aggressive somatotroph tumor cells expressed slightly but non significantly higher levels of SSTRs (Panel A) and IGF1R (Panel B) compared with aggressive somatotroph tumor cells. No significant difference in mTOR components expression has been found between the two groups of somatotroph tumors (Panel C).

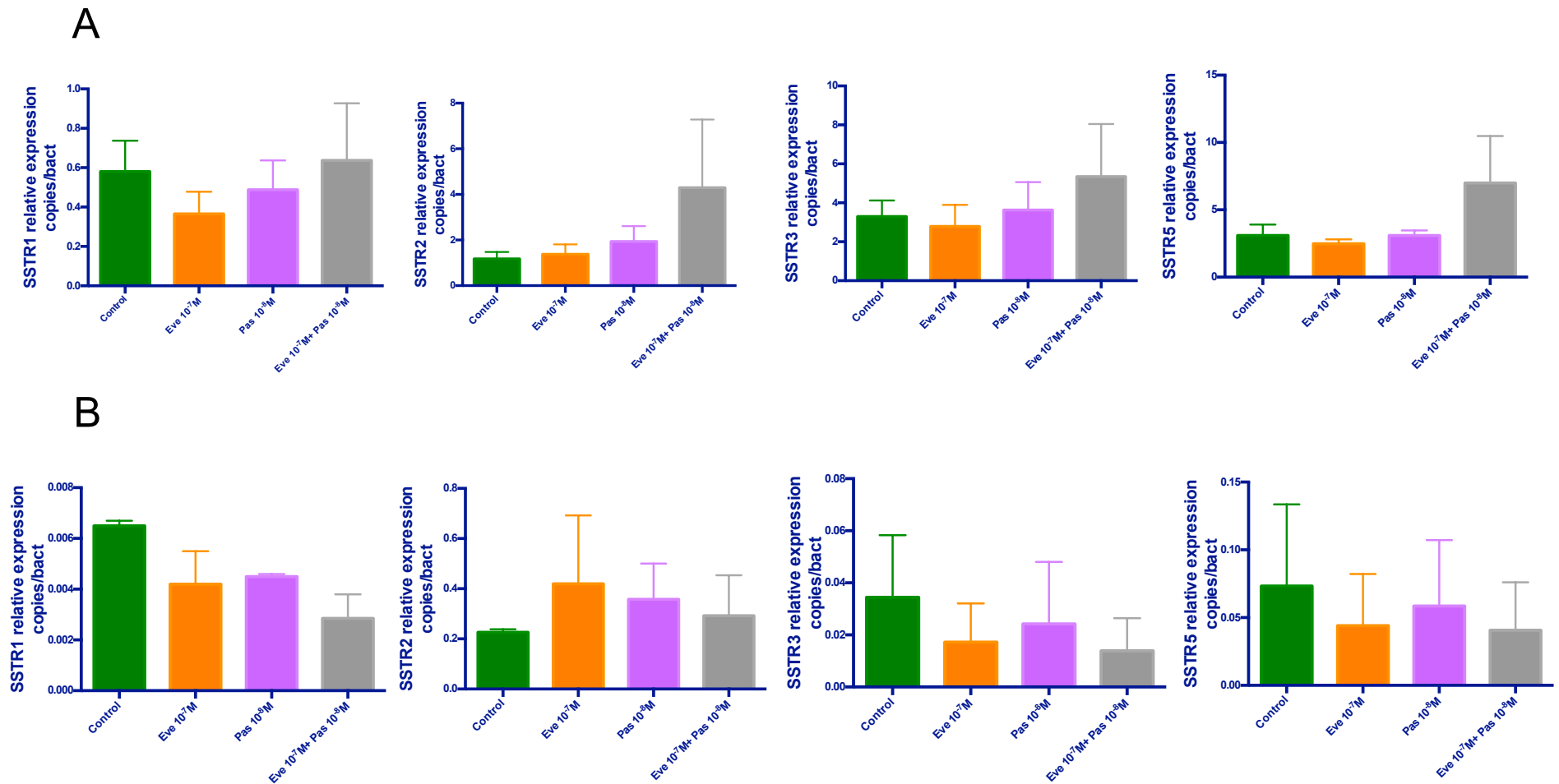


Figure 3: Effects of PAS, EVE and PAS+EVE on SSTR gene transcription regulation in non-aggressive (Panel A) and aggressive (Panel B) somatotroph tumors. PAS+EVE did not induce gene transcription regulation after 1h of treatment, although a trend in increasing SSTR expression has been observed in non-aggressive somatotroph tumors (Panel A).

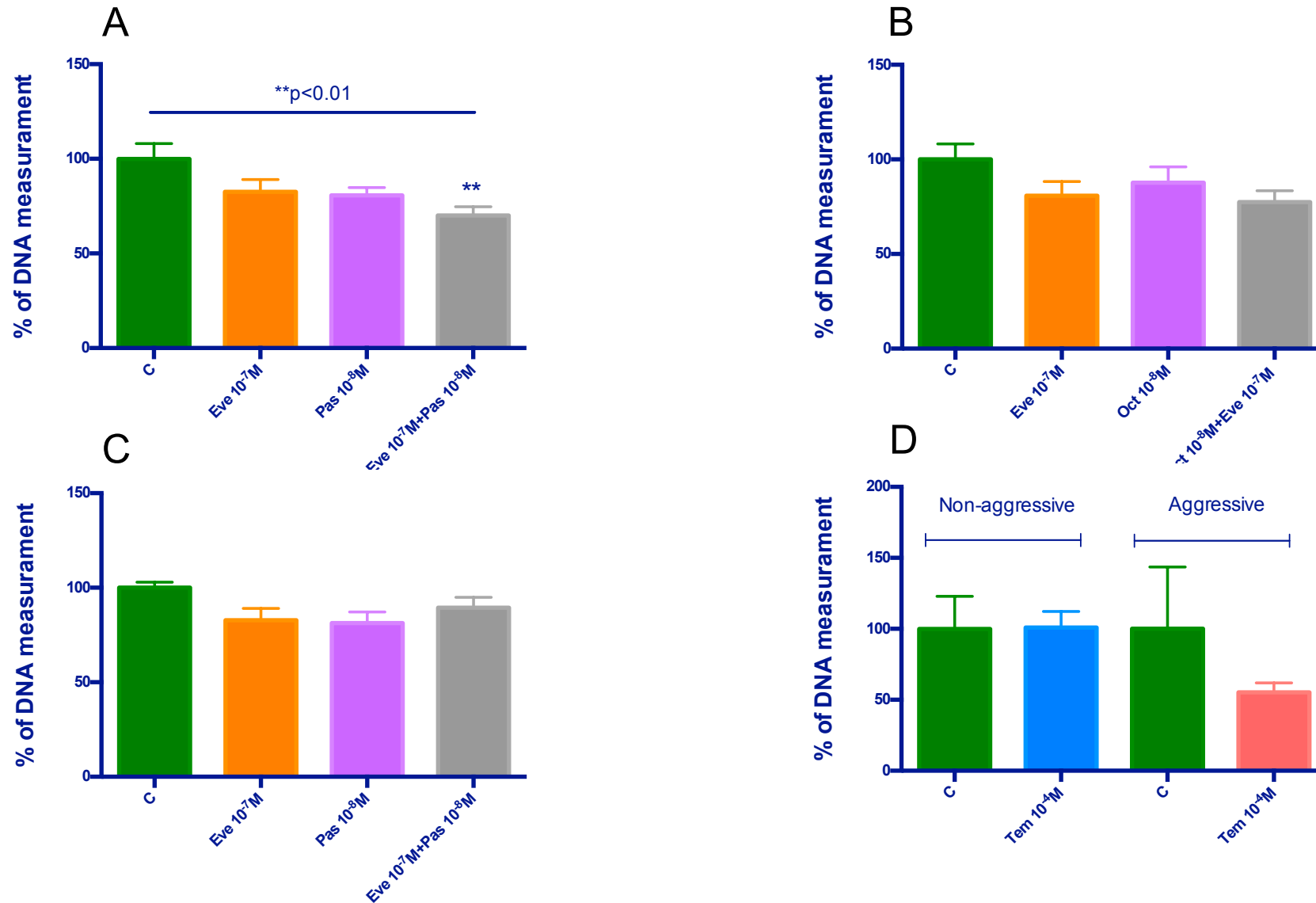


Figure 4: Effects of different treatments on cell proliferation. In non-aggressive somatotroph tumors, only PAS $10^{-8}M$ +EVE $10^{-7}M$ significantly reduced cell proliferation by 30%, whereas these same drugs used alone did not significantly change cell proliferation at tested doses (Panel A). OCT, both used alone and in combination with EVE, did not significantly change cell proliferation at tested doses (Panel B). In 5 aggressive somatotroph tumors, neither PAS, EVE, nor PAS+EVE significantly inhibited cell proliferation at tested doses (Panel C). In 2 non-aggressive somatotroph tumors and in 1 aggressive somatotroph tumor TMZ did not significantly change cell proliferation at tested doses (Panel D).

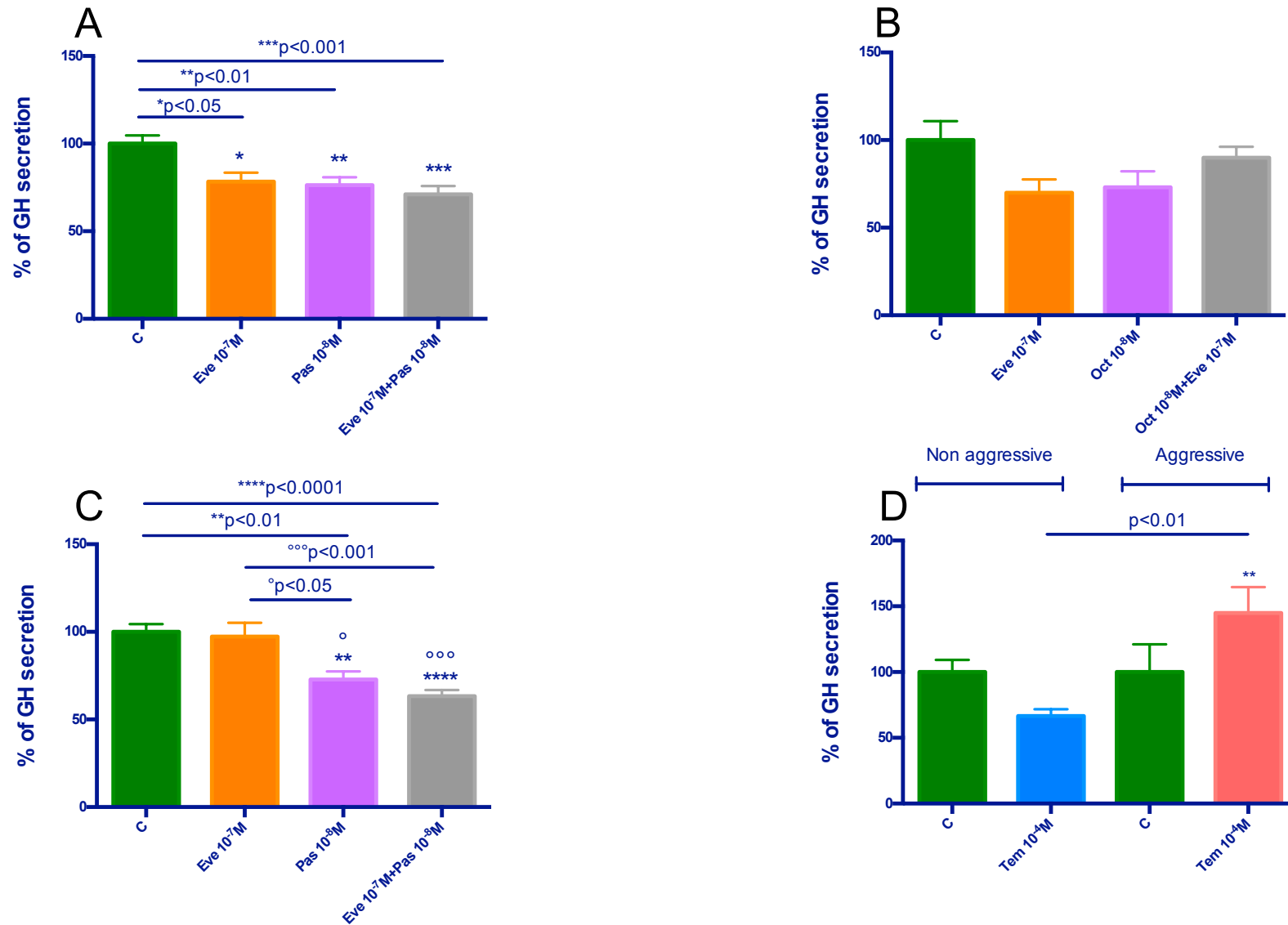


Figure 5: Effects of different treatments on GH secretion. In 5 non-aggressive somatostroph tumors, as compared to the control PAS, EVE and PAS+EVE significantly reduced GH secretion by 23,73% ($p<0.01$), 21% ($p<0.05$) and 28,96% ($p<0.001$), respectively (Panel A). In 2 non-aggressive somatotroph tumors OCT alone or combined with EVE did not significantly reduce GH secretion (Panel B). In 5 aggressive somatotroph tumors, PAS induced the significant GH secretion inhibition when used alone (27,28%, $p<0.01$) and combined with EVE (37%, $p<0.0001$ vs control, $p<0.001$ vs EVE alone) (Panel C). In non-aggressive somatotroph tumors TMZ did not significantly reduce GH secretion, and in aggressive somatotroph tumors it increased GH secretion ($p<0.01$) probably due GH excretion most likely because of its cytotoxic effect (Panel D).

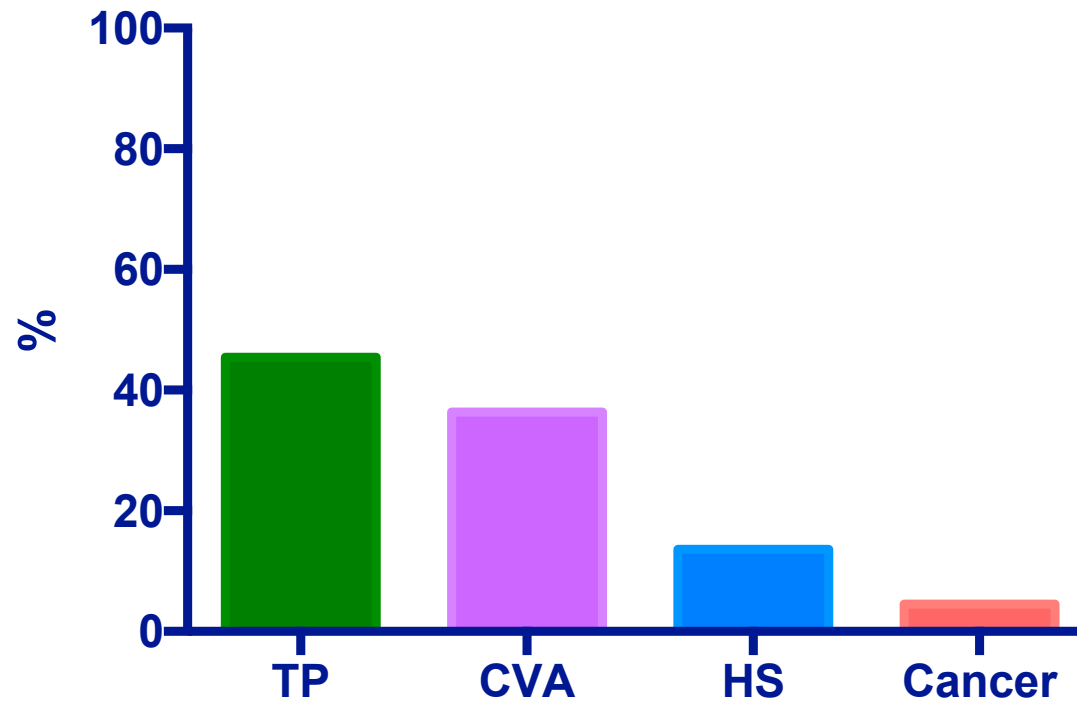


Figure 6: Mortality in the whole cohort of patients with pituitary aggressive tumors and carcinomas. Causes of death included tumor progression (TP) in 10 (45.4%), cerebrovascular accidents (CVA) in 8 (36.4%), heart stroke (HS) in 3 (13.6%) and other malignancy in 1 (4.5%).

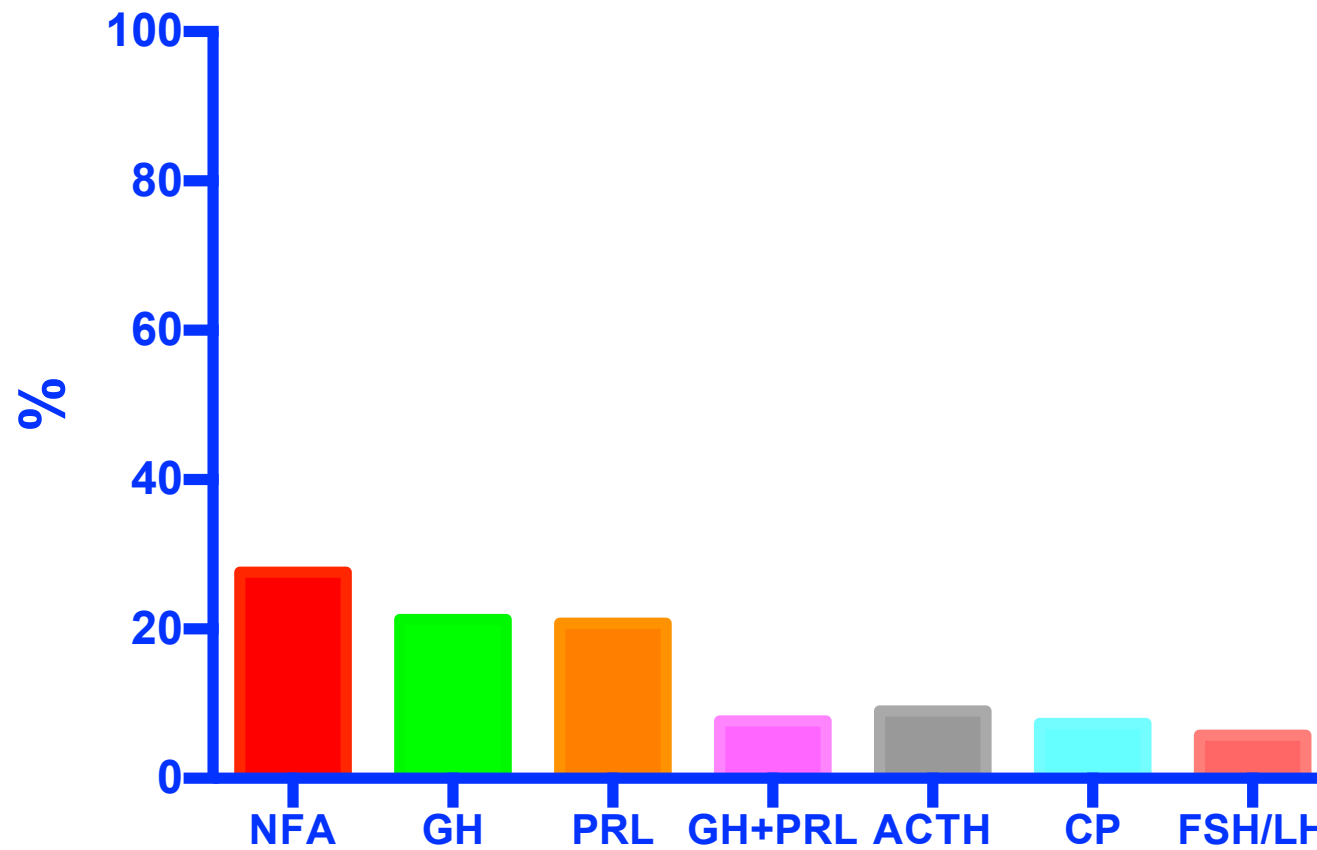


Figure 7: Distribution of pituitary tumor histotype. NFA= 27.6%; GH-secreting tumors= 21.3%; GH and PRL-cosecreting tumors= 7.7%; PRL-secreting tumors= 20.8%; ACTH-secreting pituitary tumors= 9%; craniopharyngiomas= 7.4%; FSH/LH-secreting pituitary tumors= 5.8%.

CP, craniopharyngiomas

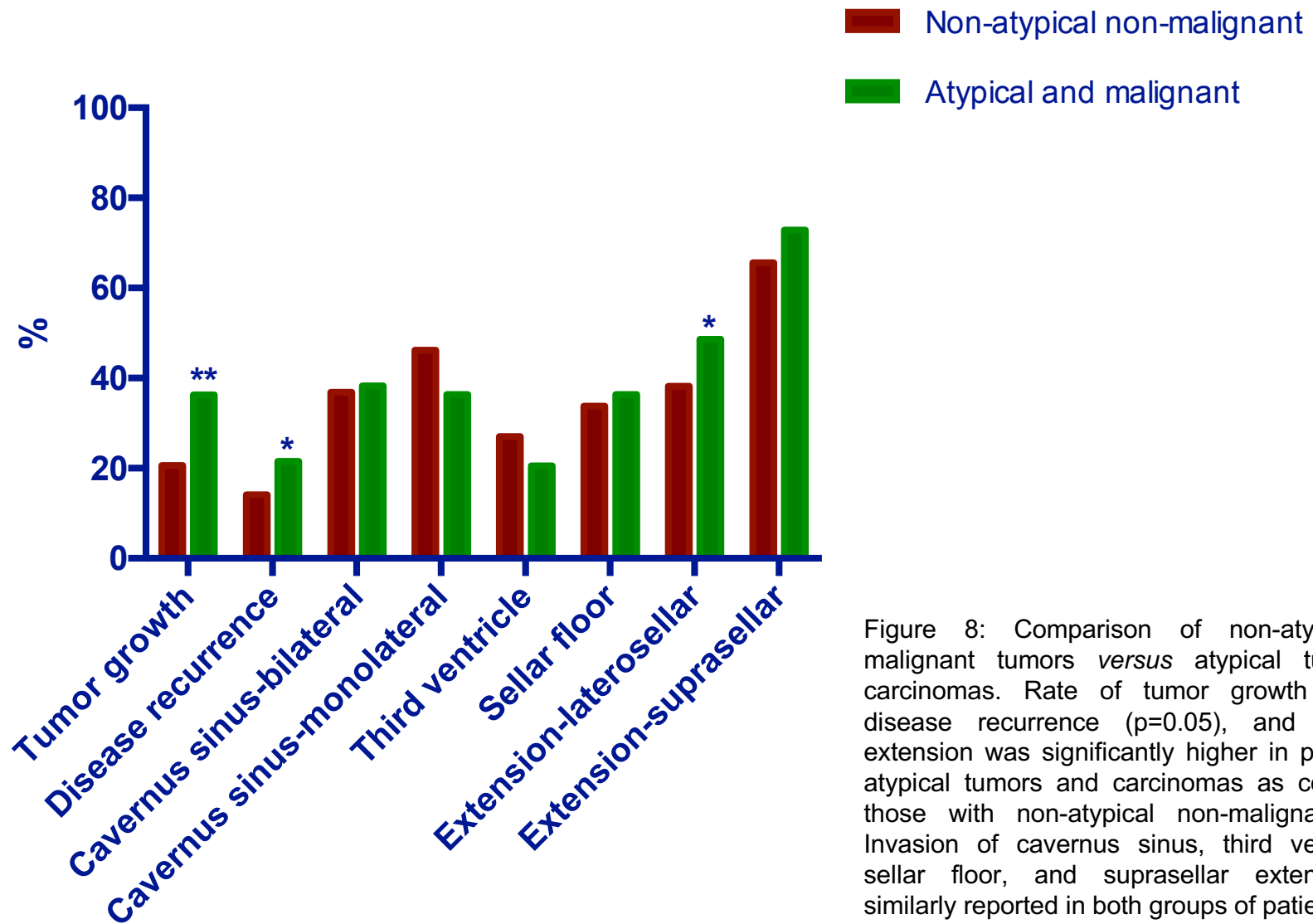


Figure 8: Comparison of non-atypical non-malignant tumors *versus* atypical tumors and carcinomas. Rate of tumor growth ($p=0.003$), disease recurrence ($p=0.05$), and laterosellar extension was significantly higher in patients with atypical tumors and carcinomas as compared to those with non-atypical non-malignant tumors. Invasion of cavernus sinus, third ventricle and sellar floor, and suprasellar extension were similarly reported in both groups of patients.