

Submitted: 18/02/2015

Accepted: 10/05/2015

Published: 20/05/2015

Haemangiosarcoma in a captive Asiatic lion (*Panthera leo persica*)

F. Vercammen^{1,*}, J. Brandt¹, L. Van Brantegem², L. Bosseler² and R. Ducatelle²¹Centre for Research and Conservation, Royal Zoological Society of Antwerp, K. Astridplein 26, B-2018 Antwerp, Belgium²Department of Pathology, Bacteriology and Avian Medicine, Faculty of Veterinary Medicine, University of Ghent, Salisburylaan 133, B-9820 Merelbeke, Belgium

Abstract

A 2.7-year-old male captive Asiatic lion (*Panthera leo persica*) died unexpectedly without preceding symptoms. Gross necropsy revealed liver and lung tumours, which proved to be haemangiosarcomas by histopathology. Some of the liver tumours were ruptured, leading to massive intra-abdominal haemorrhage and death. Haemangiosarcomas are rare in domestic and exotic felids, occurring in skin, thoracic-abdominal cavity and bones. Although these tumours mainly appear to be occurring in older cats, they are sometimes observed in younger animals, as in the present case. This is the first description of haemangiosarcoma in a young Asiatic lion.

Keywords: Asiatic lion, Haemangiosarcoma, Histopathology, Neoplasia, *Panthera leo persica*.

Introduction

Asiatic lions (*Panthera leo persica*) are large felids once found throughout most of southwest Asia and genetically distinct from African lions (*Panthera leo*). Now, they are confined to India and the International Union for the Conservation of Nature lists these animals as endangered, with an estimated population of only 250 animals inside and 100 animals outside the Gir Forest protected area in the State of Gujarat (Breitenmoser *et al.*, 2008). The major threats for this population are unpredictable events, such as epidemics or large forest fires, poaching and drowning incidents (Breitenmoser *et al.*, 2008). Today, the Zoological Information Management System (ZIMS) by the International Species Information System (ISIS) lists 325 captive animals in 57 institutions in Asia, Europe and the United States of America.

Searching the international literature, the authors could find few reports on infectious diseases (Ramanathan *et al.*, 2007; Pawar *et al.*, 2012) and only three reports on neoplasms in Asiatic lions, i.e. one case of ocular squamous cell carcinoma, one case of lymphocytic leukaemia, and one report describing two cases of visceral haemangiosarcoma (Hruban *et al.*, 1992; Kelawala *et al.*, 2001; Amaravathi *et al.*, 2012). There are two case reports of visceral haemangiosarcoma in other exotic felids: a cheetah (*Acinonyx jubatus*) and a Bengal tiger (*Panthera tigris*) (Ervin *et al.*, 1988; Kang *et al.*, 1996). Although haemangiosarcomas are also rarely observed in domestic cats, several such reports exist (Liu *et al.*, 1974; Quigley and Leedale, 1983; Scavelli *et al.*, 1985; Schultheiss, 2004; Johannes *et al.*, 2007; Wobeser *et al.*, 2007; Culp *et al.*, 2008).

The present report describes the gross necropsy and histopathology of a fatal haemangiosarcoma in a young captive Asiatic lion. This case is not only noteworthy because of the rarity of this tumour in large felids, but also the young age at which this animal developed the neoplasm is remarkable.

Case Details

At the Wild Animal Park Planckendaal of the Royal Zoological Society of Antwerp, an adult, male Asiatic lion, 2.7 years old, was found dead in his inside enclosure without preceding clinical abnormalities. Gross post-mortem examination revealed a normal body condition with a body weight of 140 kg and the following salient findings: anaemic mucosae; 10 litres of blood in the abdominal cavity; pale-coloured pancreas and spleen; multiple nodular lung masses (a few mm to 10 cm diameter, filled with blood clots) (Fig. 1); multiple (2 mm – 8 mm diameter) kidney cysts (filled with clear transparent liquid); multiple liver nodules (a few mm to 10 cm diameter, filled with blood clots, some with grapelike appearance, others were ruptured) (Fig. 2). An additional macroscopic finding, i.e. an extensive proximal diaphyseal new bone formation on the right humerus, was identified later after the preparation of the skeleton at the Royal Belgian Institute of Natural Sciences in Brussels. No anomalies were detected in any other organ.

A set of tissue samples (liver, lung, spleen, kidney, bronchial lymph node) was collected and fixed in 10% neutral buffered formalin, embedded in paraffin, sectioned at 4 µm, and stained with haematoxylin and eosin and Prussian blue for histologic examination. Immunohistochemistry was performed on 4-µm sections using Factor VIII-related antigen or von

*Corresponding Author: Dr. Francis Vercammen. Centre for Research and Conservation, Royal Zoological Society of Antwerp, K. Astridplein 26, B-2018 Antwerp, Belgium. Tel.: +3232024548. E-mail: francis.vercammen@kmda.org

Willebrand factor (vWf) (polyclonal rabbit antibody, reference A0082, Dako, Glostrup, Denmark) and the platelet-endothelial cell adhesion molecule or cluster of differentiation 31 (CD31) (monoclonal mouse antibody, Clone JC70A, reference M0823, Dako, Glostrup, Denmark). External positive controls for the immunohistochemical stainings were spleen from a pig for vWf and mesenteric blood vessels from a dog for CD31. Internal controls consisted of normal endothelial cells in the examined tissues. No non-specific staining was observed in any of the slides.

In the liver, there were multifocal areas where the normal architecture was lost and most of the parenchyma had been replaced by non-encapsulated, poorly demarcated, infiltrative and moderately cellular masses. The masses were composed of loosely arranged streams and poorly defined capillary-like channels, supported by a moderate amount of eosinophilic stroma and occasionally large vascular channels, filled with variable amounts of blood (Fig. 3a). Neoplastic cells were mainly polygonal to spindle shaped, with indistinct cell borders, moderate amounts of eosinophilic cytoplasm with a round to oval, centrally placed nucleus with a finely stippled chromatin pattern and 1 nucleolus. There was moderate anisokaryosis and anisocytosis. Mitotic figures ranged from 1 to 4 per high power field. There were larger areas of haemorrhage and necrosis. The neoplastic cells

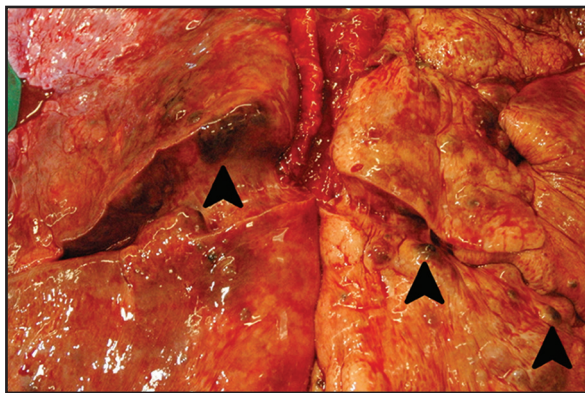


Fig. 1. Gross necropsy: lung tumours in an Asiatic lion with haemangiosarcoma.

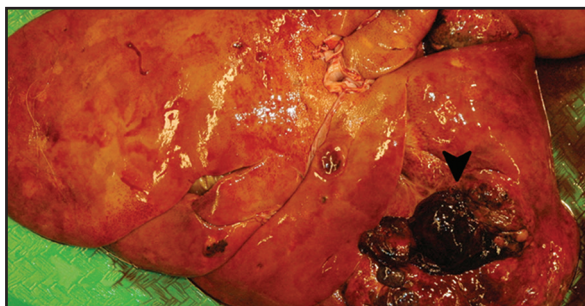

Fig. 2. Gross necropsy: liver tumours in an Asiatic lion with haemangiosarcoma.

labelled strongly positive for vWf and CD31 (Fig. 3b). In the lung similar neoplastic foci were observed, which also labelled positive for vWf and CD31. There was mild fibrosis of the renal capsule. There were no neoplastic lesions in the kidney. The capsule of the spleen showed focal mesothelial cell proliferation without signs of neoplastic masses in the spleen. In the bronchial lymph node, and especially in its subcapsular sinuses, there was a multifocal mild infiltration of macrophages. Many of those macrophages had an intracytoplasmic accumulation of a yellowish-brown granular pigment. Prussian blue staining confirmed the pigment as haemosiderin. Other macrophages showed erythrophagocytosis. The lesion in the humerus, detected during the preparation of the skeleton, was not examined histopathologically.

Tissue impression smears of bronchial lymph node, liver, lung and also of the abdominal blood were made for bacteriological examinations. Giemsa stain, Gram stain and Ziehl-Neelsen stain were all negative. Cultivation on tryptone-soya-agar and blood agar demonstrated no growth of bacteria.

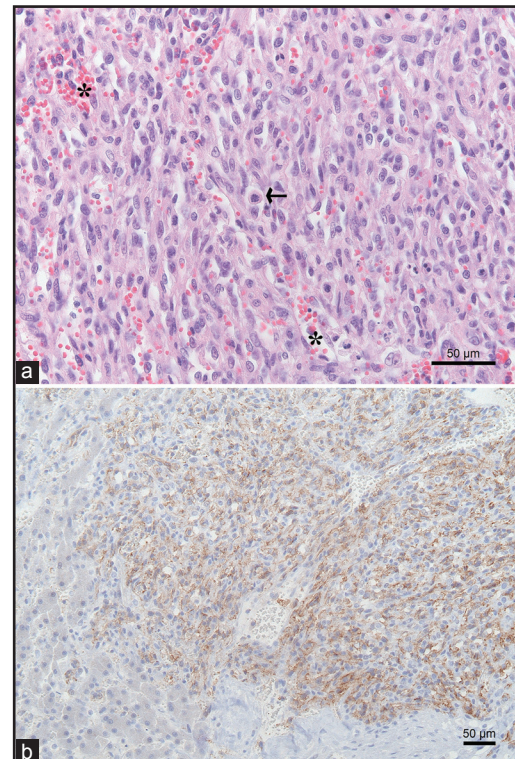


Fig. 3. Histopathology of liver haemangiosarcoma in an Asiatic lion. (a) The masses are composed of streams and capillary-like channels (asterisk) formed by polygonal to spindle shaped neoplastic cells. A mitotic figure is indicated (arrow). Mitoses range from 1 to 4 per high power field (Haematoxylin and eosin - H&E). (b) Cluster of differentiation 31 (CD31) positive immunohistochemistry. On the left side of the image CD31 negative hepatocytes are seen.

Discussion

Haemangiosarcomas are very rare in domestic cats as well as in large captive cats. In a retrospective study covering 6 years and 1912 domestic animals, only 72 cats (3-17 years old) were diagnosed with haemangiosarcoma, of which 59 involved the skin, 2 the bones and 11 the viscera (Schultheiss, 2004). Johannes *et al.* (2007) found 10 cats with visceral haemangiosarcoma out of 53 domestic cats with haemangiosarcoma over a period of 10 years. In a large survey totalling 3145 domestic cats, a haemangiosarcoma prevalence of 0.6% was observed (Patnaik and Liu, 1977). In a retrospective evaluation of surgical cases involving 31 domestic cats between 4 and 15 years old, 15 abdominal haemangiosarcomas, 2 thoracic, 13 subcutaneous and 1 haemangiosarcoma of the nasal cavity were found (Scavelli *et al.*, 1985). One report considered only amputated feline digits and found 5 domestic cats (2-13 years old) out of 63 with haemangiosarcomas (Wobeser *et al.*, 2007).

Visceral haemangiosarcoma involving the liver has been described only twice in the Asiatic lion and remains a very rare tumour in non-domestic felids (Amaravathi *et al.*, 2012). The prevalence of this tumour is very low even in domestic cats, where the mean age of occurrence is 9.5 years (range between 2-18 years) (Quigley and Leedale, 1983; Scavelli *et al.*, 1985; Schultheiss, 2004; Wobeser *et al.*, 2007). The age of the young Asiatic lion in the present case (2.7 years) falls within the age range reported for domestic cats, but deviates from the mean age (9.5 years) and is in very sharp contrast with the very old age of 22 and 24 years in the only two reported cases in Asiatic lions (Amaravathi *et al.*, 2012). Moreover, these two animals had been suffering from progressive weakness and debilitation for several months as opposed to our clinically healthy young animal (Amaravathi *et al.*, 2012). Probably these symptoms are the result of the progressive increase in abdominal serosanguinous fluid, contrary to the abrupt liver haemorrhages in the present case. Furthermore, the old lions presented with masses in their liver and spleen, whereas our lion had liver and lung tumours. Unfortunately, all our observations did not allow us to determine the primary neoplastic site. Clinicians should be aware that neoplasia is a potential differential diagnosis in a sick Asiatic lion and that pathological surveillance of all captive animals in all age categories is of great value to the breeding and conservation effort.

In domestic cats, bone involvement is rare, but two out of 58 bone neoplasms (one in the humerus and one in the tibia) were diagnosed as haemangiosarcoma, both in older animals, 17 and 18 years respectively (Quigley and Leedale, 1983). Another report described only one domestic cat with a soft tissue haemangiosarcoma with bone involvement out of 29 cats with soft

tissue tumours involving bone (Liu *et al.*, 1974). The extensive new bone formation on the humerus was not examined in histopathology because it was discovered after the preparation of the skeleton for the museum. Yet, this lesion is probably not a result of a metastasising haemangiosarcoma, which normally provokes extensive osteolysis rather than new bone formation (Quigley and Leedale, 1983).

In conclusion, this is the first description of haemangiosarcoma in a young captive Asiatic lion that died suddenly due to massive liver haemorrhages.

Acknowledgments

The authors wish to thank Mr. W. Wouters of the Royal Belgian Institute of Natural Sciences in Brussels for the preparation of the skeleton and the Flemish Government for structural support to the Centre for Research and Conservation.

References

- Amaravathi, P., Srilatha, C., Sujatha, K. and Sailaja, N. 2012. Histopathological and immunohistochemical study of hemangiosarcoma in lions. *Indian J. Vet. Pathol.* 36, 120-121.
- Breitenmoser, U., Mallon, D.P., Khan, J.A. and Driscoll, C. 2008. *Panthera leo ssp. persica*. IUCN 2013. IUCN Red List of Threatened Species. <http://www.iucnredlist.org>.
- Culp, W.T., Drobotz, K.J., Glassman, M.M., Baez, J.L. and Aronson, L.R. 2008. Feline visceral hemangiosarcoma. *J. Vet. Intern. Med.* 22, 148-152.
- Ervin, A.M., Junge, R.E., Miller, R.E. and Thornburg, L.P. 1988. Hemangiosarcoma in a cheetah (*Acinonyx jubatus*). *J. Zoo Wildl. Med.* 19, 143-145.
- Hruban, Z., Vardiman, J., Meehan, T., Frye, F. and Carter, W.E. 1992. Haematopoietic malignancies in zoo animals. *J. Comp. Pathol.* 106, 15-24.
- Johannes, C.M., Henry, C.J., Turnquist, S.E., Hamilton, T.A., Smith, A.N., Chun, R. and Tyler, J.W. 2007. Hemangiosarcoma in cats: 53 cases (1992-2002). *J. Am. Vet. Med. Assoc.* 231, 1851-1856.
- Kang, B., Kim, D., Shin, N. and Kwon, S. 1996. Spontaneous hemangiosarcoma in a Bengal tiger (*Panthera tigris*). *Korean J. Vet. Res.* 36, 143-150.
- Kelawala, N.H., Parsiana, R.R., Sabapara, R.H. and Prajapati, K.S. 2001. Ocular neoplasm in an Asiatic lion (*Panthera leo persica*) - a case report. *Intas Polivet* 2, 222-223.
- Liu, S.K., Dorfman, H.D. and Patnaik, A.K. 1974. Primary and secondary bone tumours in the cat. *J. Small Anim. Pract.* 15, 141-156.
- Patnaik, A.K. and Liu, S.K. 1977. Angiosarcoma in cats. *J. Small Anim. Pract.* 18, 191-198.
- Pawar, R.M., Lakshmikantan, U., Hasan, S., Poornachandar, A. and Shivaji, S. 2012. Detection and molecular characterization of ascarid nematode

- infection (*Toxascaris leonina* and *Toxocara cati*) in captive Asiatic lions (*Panthera leo persica*). Acta Parasitol. 57, 67-73.
- Quigley, P.J. and Leedale, A.H. 1983. Tumors involving bone in the domestic cat: a review of fifty-eight cases. Vet. Pathol. 20, 670-686.
- Ramanathan, A., Malik, P.K. and Prasad, G. 2007. Seroepizootiological survey for selected viral infections in captive Asiatic lions (*Panthera leo persica*) from western India. J. Zoo Wildl. Med. 38, 400-408.
- Scavelli, T.D., Patnaik, A.K., Mehlhaff, C.J. and Hayes, A.A. 1985. Hemangiosarcoma in the cat: retrospective evaluation of 31 surgical cases. J. Am. Vet. Med. Assoc. 187, 817-819.
- Schultheiss, P.C. 2004. A retrospective study of visceral and nonvisceral hemangiosarcoma and hemangiomas in domestic animals. J. Vet. Diagn. Invest. 16, 522-526.
- Wobeser, B.K., Kidney, B.A., Powers, B.E., Withrow, S.J., Mayer, M.N., Spinato, M.T. and Allen, A.L. 2007. Diagnoses and clinical outcomes associated with surgically amputated feline digits submitted to multiple veterinary diagnostic laboratories. Vet. Pathol. 44, 362-365.