

## Childhood primary large vessel CNS vasculitis: single centre experience and review of the literature

S. Walsh<sup>1</sup>, R. Knöfler<sup>2</sup>, G. Hahn<sup>3</sup>, J. Lohse<sup>2</sup>, R. Berner<sup>2</sup>, S. Brenner<sup>2</sup>, M. Smitka<sup>1</sup>, M. von der Hagen<sup>1</sup>, C.M. Hedrich<sup>2</sup>

<sup>1</sup>Abteilung Neuropädiatrie, Medizinische Fakultät Carl Gustav Carus, Technische Universität Dresden; <sup>2</sup>Klinik- und Poliklinik für Kinder- und Jugendmedizin, Medizinische Fakultät Carl Gustav Carus, Technische Universität Dresden; <sup>3</sup>Institut und Poliklinik für Radiologische Diagnostik, Medizinische Fakultät Carl Gustav Carus, Technische Universität Dresden, Germany.

S. Walsh, R. Knöfler, G. Hahn, J. Lohse, R. Berner, S. Brenner, M. Smitka, M. von der Hagen\*, C.M. Hedrich\*,



\*Both authors contributed equally to the presented work.

Please address correspondence to: PD Dr. med. Christian Hedrich, Pädiatrische Rheumatologie und Immunologie, Klinik und Poliklinik für Kinder- und Jugendmedizin, Technische Universität Dresden, Fetscherstr. 74, 01309 Dresden, Germany. E-mail: Christian.Hedrich@uniklinikum-dresden.de

Received on November 3, 2016; accepted in revised form on January 18, 2017.

© Copyright CLINICAL AND EXPERIMENTAL RHEUMATOLOGY 2017.

**Key words:** paediatric acute ischemic stroke, CNS vasculitis, therapy, anticoagulation, arteriopathy, primary angiitis

Competing interests: none declared.

### ABSTRACT

*Ischaemic brain injuries are rare conditions in the paediatric age group. Main causes include non-arteriosclerotic arteriopathies, which in childhood usually result from primary vasculitis of large or small vessels and lead to impaired perfusion and subsequent ischaemic brain lesions. In accordance with the nomenclature of systemic forms, CNS vasculitis is subdivided into groups, based on the size of affected vessels: angiography-positive primary angiitis of medium sized and large vessels (pPACNS), and angiography-negative angiitis of small vessels (svPACNS).*

*We report the clinical presentation, diagnostic approach, and therapy of four children with progressive pPACNS. Patients were treated with high-dose corticosteroids and anticoagulation with unfractionated heparin in the acute phase, followed by immune modulatory treatment with mycophenolate mofetil (MMF) and dual antiplatelet therapy with acetylsalicylic acid and clopidogrel. In this manuscript, we illustrate the experience gained in our hospital, resulting in significantly faster diagnosis and treatment initiation, and discuss the applied immune modulating treatment regimen in the context of the literature. Based on our observations, we conclude that immune modulating therapy with initial high-dose corticosteroids, followed by steroid-sparing maintenance treatment with MMF, may be safe and effective in childhood progressive pPACNS.*

### Introduction

Ischaemic brain injury is a rare but severe condition in the paediatric age group. According to epidemiologic data from the USA, the incidence of acute ischaemic stroke (AIS) in child-

hood exceeds 3.3/100 000 children per year (1). Recurrence rates vary between 5% and 25% (2, 3). Diagnosis and management can be challenging due to the rarity of pediatric AIS, differential diagnoses (“stroke mimics”), and the absence of uniformly accepted diagnostic and therapeutic guidelines. Though non-arteriosclerotic arteriopathies are the most common cause of childhood AIS after the neonatal period (4), their pathophysiology is poorly understood. As a result, nomenclature of underlying conditions is inconsistent and varies between the neuropediatric and the rheumatological literature. “Cerebral arteriopathy” is a descriptive diagnosis (5) that, after the exclusion of differential diagnoses (e.g. fibromuscular dysplasia), can be narrowed down to “inflammatory arteriopathies”, which can be subdivided into primary and secondary CNS vasculitis (6, 7). Criteria for the diagnosis of childhood primary angiitis of the central nervous system (PACNS) include i) an acquired neurological deficit, ii) angiographic or histological features of vasculitis, iii) the absence of an alternative explanation of the symptoms, and iv) new-onset psychiatric deficits (8).

Clinical presentations of PACNS are variable, and, among other factors, depend on the size and location of the affected vessels, individual host factors, and severity and duration of the inflammatory response. In accordance to primary systemic vasculitis, PACNS is stratified depending on the size of affected vessels (7, 9). Large and medium sized vessel primary CNS vasculitis is referred to as angiography-positive (pPACNS), small vessel disease as angiography-negative svPACNS (9). Angiography-positive PACNS is further divided into monophasic non-

progressive forms, also referred to as transient cerebral arteriopathy (TCA), and progressive forms (10). Patients with transient pPACNS/TCA typically present with focal neurological deficits, headaches and/or encephalopathy, depending on the vessel affected. Transient pPACNS/TCA is characterized by unilateral focal or segmental stenosis or occlusion involving the distal part of the internal carotid artery, and proximal segments of the anterior and/or middle cerebral artery (11). Historically, non-progressive pPACNS/TCA was defined by stable or regressing arterial changes in follow-up imaging studies 6 months after disease onset when compared to MRI angiograms at 3 months (12). Other patients develop chronically active CNS vasculitis, which can result in a series of ischemic strokes and even more severe sequelae. In such cases, the term progressive pPACNS is used. Recent reports suggest clinical features and vessel involvement on MR angiograms as early predictors of disease course, allowing timely and adequate treatment, preventing long-term disease activity (13). Clinical hallmarks of progressive pPACNS are focal and additional diffuse neurological deficits, with headaches, cognitive dysfunction, seizures, and encephalitis-like symptoms frequently preceding focal neurological deficits. Progressive pPACNS is characterized by uni- or bilateral focal or segmental stenosis or occlusion, involving the proximal and/or distal part of the internal carotid artery, and proximal and/or distal segments of the anterior and/or middle cerebral artery, as well as the posterior arteries (14). Provided timely diagnosis and treatment initiation, disease progression should be avoided and may not be seen in adequately treated patients with otherwise “progressive” disease (15). We present the clinical course and disease outcomes in four children with progressive pPACNS, some of whom were diagnosed and treated early during disease, others after prolonged symptoms and/or relapses. Focusing on clinical presentation, diagnostic and therapeutic approaches, as well as disease outcomes in the context of the available literature, this report emphasizes the

**Table I.** Patient characteristics.

Patient No.	1	2	3	4
Age at onset (years)	8	9	9	3,5
Gender	male	male	female	female
Clinical symptoms	headache, aphasia, ataxia, vertigo	progressive hemiparesis, aphasia, anisocoria, somnolence	hemiparesis, facial nerve palsy, vomiting	hemiparesis, ataxia, slurred speech
Time to admission (from first symptoms)	3 days	1 day	2 days	3 weeks
Time to anti-coagulation (from first symptoms)	3 days	1 day	2 days	3 weeks
Time to immune modulation with corticosteroids (from admission)	29 days	17 days	4 days	4 days, (approximately 25 days from first symptoms)
Number of ischemic events	3	3	1 (+ 1 TIA)	1

importance of PACNS treatment in experienced multi-professional teams as well as the establishment of consensus diagnostic and therapeutic regimens.

**Methods**

Medical charts of four pediatric patients with progressive pPACNS were reviewed to collect clinical and laboratory data at the time of diagnosis, applied treatment, and neurological outcomes after 18-42 months. Clinical presentation and response to treatment were evaluated in the context of available literature.

**Case reports**

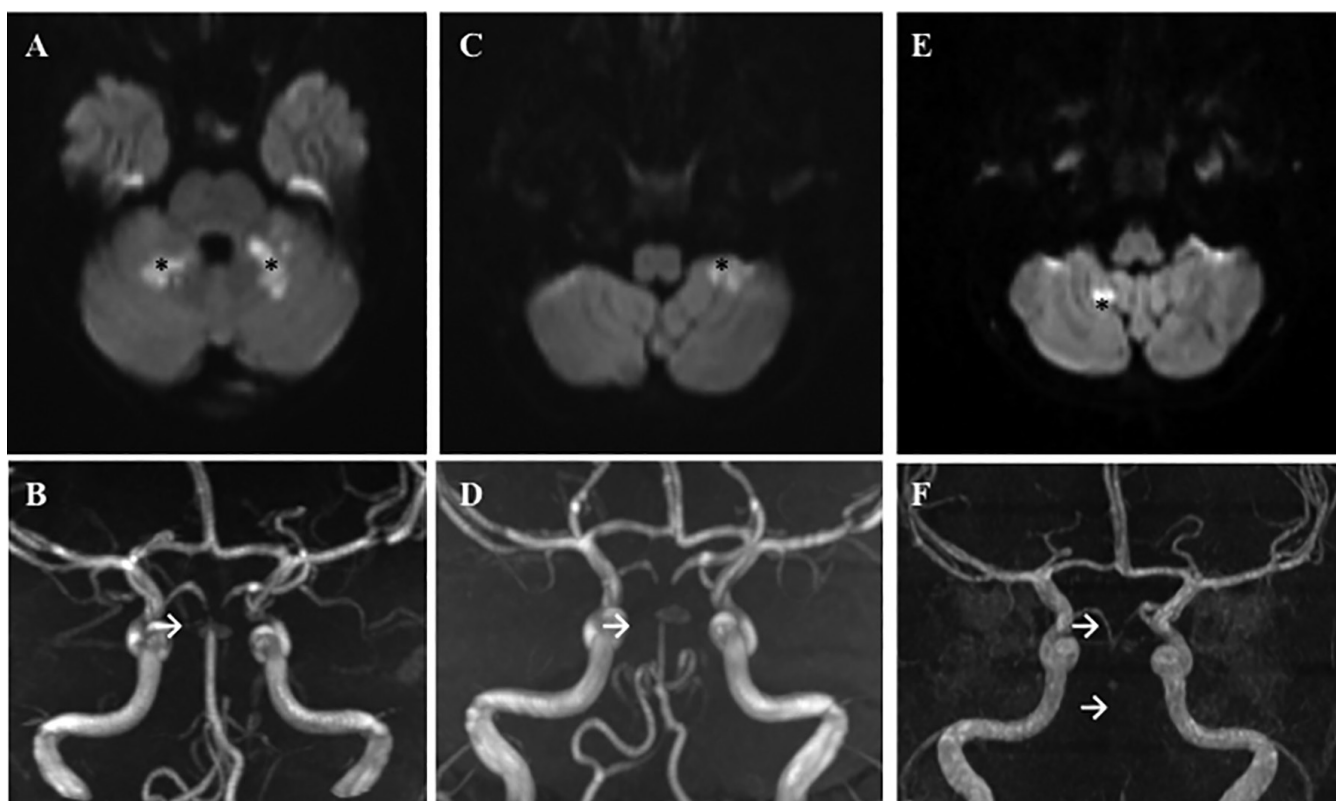
All four reported patients originate from non-consanguineous Caucasian families with no history of clotting disorders or stroke episodes in the family or personal history.

*Case 1*

An 8-year-old, previously healthy boy presented with headaches, fatigue, aphasia, ataxia, and progressive vertigo (Table I). Magnetic resonance imaging (MRI) three days after the onset of symptoms revealed a stenosis of the distal basilar artery with concomitant alterations in proton diffusion capacity in the cerebellum (Fig. 1A, C). Due to a suspected diagnosis of thromboembolic ischemic insult, the patient was started on therapeutic doses of unfractionated heparin (UFH). Neurological

deficits regressed over the course of 6 days, and treatment was switched to acetylsalicylic acid (ASA, 1.4 mg/kg/d). After 9 days, the patient relapsed with symptoms of double vision, nausea, and emesis. Magnetic resonance imaging revealed progressive stenosis of the proximal and distal basilar artery, with new areas of altered diffusion capacity in the left cerebellum (Fig. 1B, D); heparin was re-introduced. After another 18 days, the boy presented with new symptoms of ataxia and emesis; MRI unveiled an almost complete occlusion of the basilar artery and new parenchymal lesions with altered proton diffusion (Fig. 1E, F). Local thrombolysis was performed with recombinant tissue plasminogen activator (rt-PA), followed by temporary stenting and mechanical thrombectomy. After the intervention, the patient was started on a dual anti-platelet-therapy with ASA (2 mg/kg/d) and clopidogrel (0.5 mg/kg/d).

Because of the presence of general symptoms, the long segment involvement of proximal and distal cerebral vessels, together with the rapidly relapsing character, the diagnosis progressive pPACNS was made, and the patient was started on oral prednisolone (2 mg/kg/d) on day 29. Steroid-sparing mycophenolate mofetil (MMF) treatment was initiated (1000 mg/m<sup>2</sup>/d), and corticosteroids were slowly tapered over three months (Table II). After the



**Fig. 1.** MRI findings in an 8-year old boy with PACNS. Upper panel: Axial diffusion weighted imaging (DWI,  $b=1000\text{s/mm}^2$ ), showing bilateral cerebellar lesions with reduced diffusivity with high intensity (\*). Lower panel: Maximum intensity projection (MIP) of 3 dimensional time-of-flight (TOF) MR angiogram, showing progressive occlusion of the basilar artery (→). MRI imaging performed on A, C) day 6, B, D) day 9, and C, E) day 18 after the onset of symptoms.

**Table II.** Treatment and response.

Patient No.	1	2	3	4
Initial Anti-coagulation	UFH (550 IE/kg/d)	UFH (470 IE/kg/d)	UFH (360 IE/kg/d)	UFH (500IE/kg/d)
Antiplatelet therapy	ASA (2 mg/kg/d) clopidogrel (0.5 mg/kg/d) for 6 months	ASA (3 mg/kg/d) clopidogrel (0.5 mg/kg/d) for 6 months	ASA (2.7 mg/kg/d) clopidogrel (0.6 mg/kg/d) for 6 months	ASA (3 mg/kg/d) clopidogrel (1 mg/kg/d) for 6 months
Immune modulation	Prednisolone (2 mg/kg/d p.o.) for 2 months, followed by tapering over 4 weeks  MMF 900 mg/m <sup>2</sup> /d p.o. for 18 months	Methyl-prednisolone (20 mg/kg/d i.v. for 5 days)  MMF 1100 mg/m <sup>2</sup> /d p.o. for 18 months	Methyl-prednisolone (20 mg/kg/d i.v. for 5 days)  MMF 1000 mg/m <sup>2</sup> /d p.o. for 18 months	Methyl-prednisolone (20 mg/kg/d i.v. for 5 days) followed by Prednisolone (2 mg/kg/d p.o.) for 3 months  MMF 1000 mg/m <sup>2</sup> /d p.o. for 15 months (to date)
Follow-up	48 months	42 months	30 months	15 months
Clinical outcome	Minor impairment of fine motor skills on the upper limb, attention deficit	Incomplete hemiparesis on the right, attention deficit and reduced working memory	Mild paresis of the right hand, attention deficit, reduced retentiveness	Mild paresis of the right hand (mild pre-existing speech disorder)

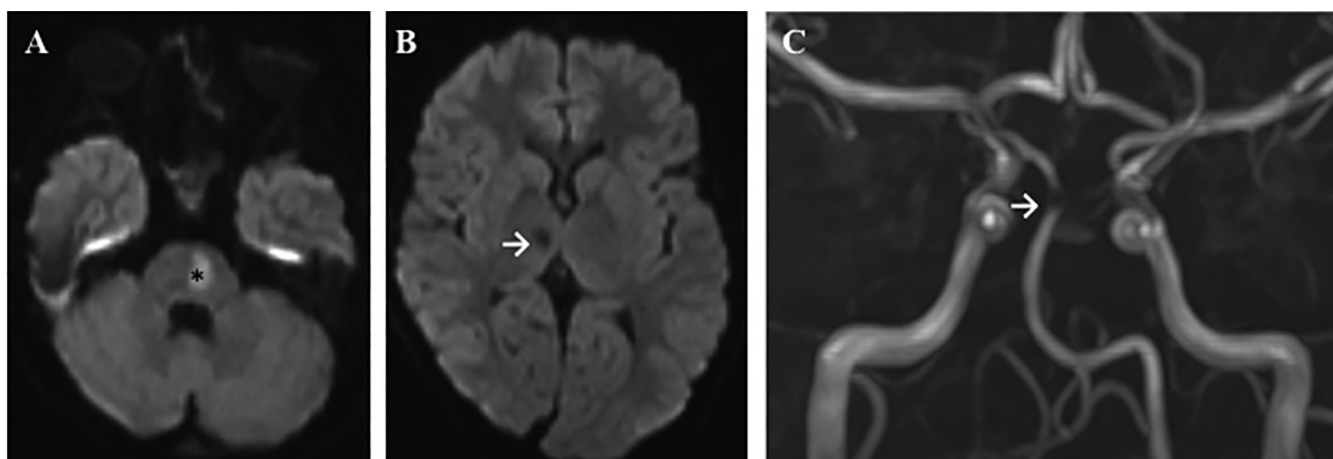
UFH: unfractionated heparin; LMWH (enoxaparin): low molecular weight heparin; ASA: acetyl salicylic acid; MMF: mycophenolate mofetil.

introduction of immune modulating treatment, no additional relapses occurred, and follow-up MR imaging, 12 months after the first ischemic attack revealed a normal configuration of the basilar artery. MMF treatment was dis-

continued after 18 months, while ASA treatment was continued because of persisting mild obstruction of the left vertebral artery. Minor impairment of fine motor skills of the upper limb and attention deficits remained.

#### Case 2

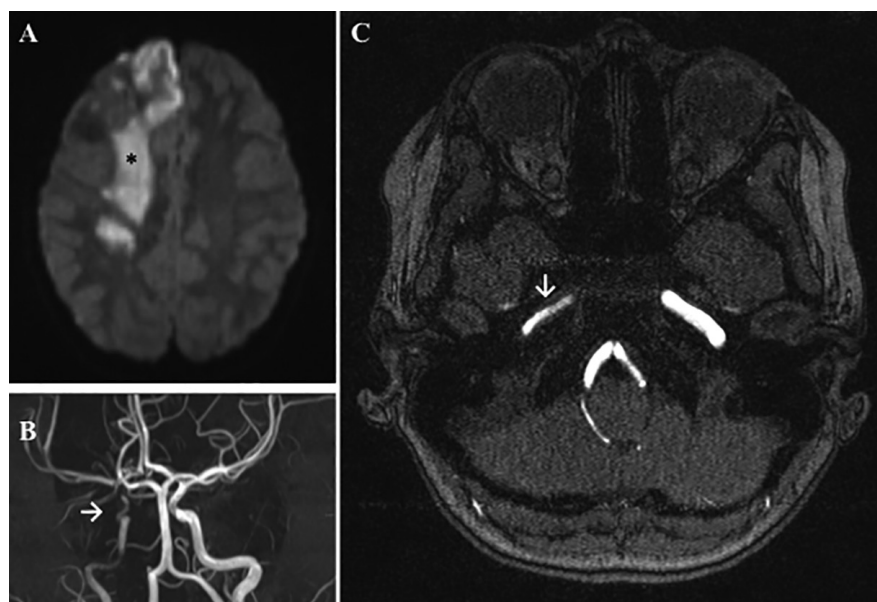
A nine-year-old, previously healthy boy presented with progressive hemiparesis on the right, anisocoria, hypoglossus and facial nerve palsy on the left, aphasia, somnolence, and emesis



**Fig. 2.** MRI findings in a 9-year old boy with PACNS, 1 day after the onset of symptoms. Axial diffusion weighted imaging (DWI,  $b=1000s/mm^2$ ), showing fresh lesions in the left pons region with reduced diffusion (\*) in A), and older lesions in the basal ganglia on the right (→) in B). C) Maximum intensity projection (MIP) of 3 dimensional time-of-flight (TOF) MR angiogram, unveiling an occlusion of the basilar artery (→).

(Table I). Brain MRI one day after the onset of symptoms revealed reduced proton diffusion capacity in the right thalamus region, in the pons cerebri, paramedian white matter, and cerebellum (Fig. 2A). In time of flight (TOF) angiography MRI sequences, almost complete occlusion of the basilar artery, and thinning of the right vertebral artery secondary to vessel wall edema were detected. The patient was started on UFH treatment. After six days, the boy developed clinical improvement of both the hemiparesis and the aphasia. Thus, heparin was replaced with ASA (3 mg/kg/d). However, three days later, neurological symptoms worsened, with the patient exhibiting progressive hemiparesis. MR imaging revealed new ischemic lesions in the left cerebellum. Thus, heparin treatment was re-established. Despite anticoagulation, the patient developed vertigo, nausea, vomiting, and spontaneous nystagmus. Magnetic resonance imaging revealed additional hypoperfusion areas in the pons cerebri.

Because of the presence of general symptoms, the long segment involvement of proximal and distal cerebral vessels with contrast enhancement in T1 sequences, together with the rapidly relapsing character, the diagnosis childhood progressive pPACNS was made on day 17 after the onset of first symptoms. Treatment with methylprednisolone i.v. pulses (20 mg/kg/d) was initiated over five days, and MMF



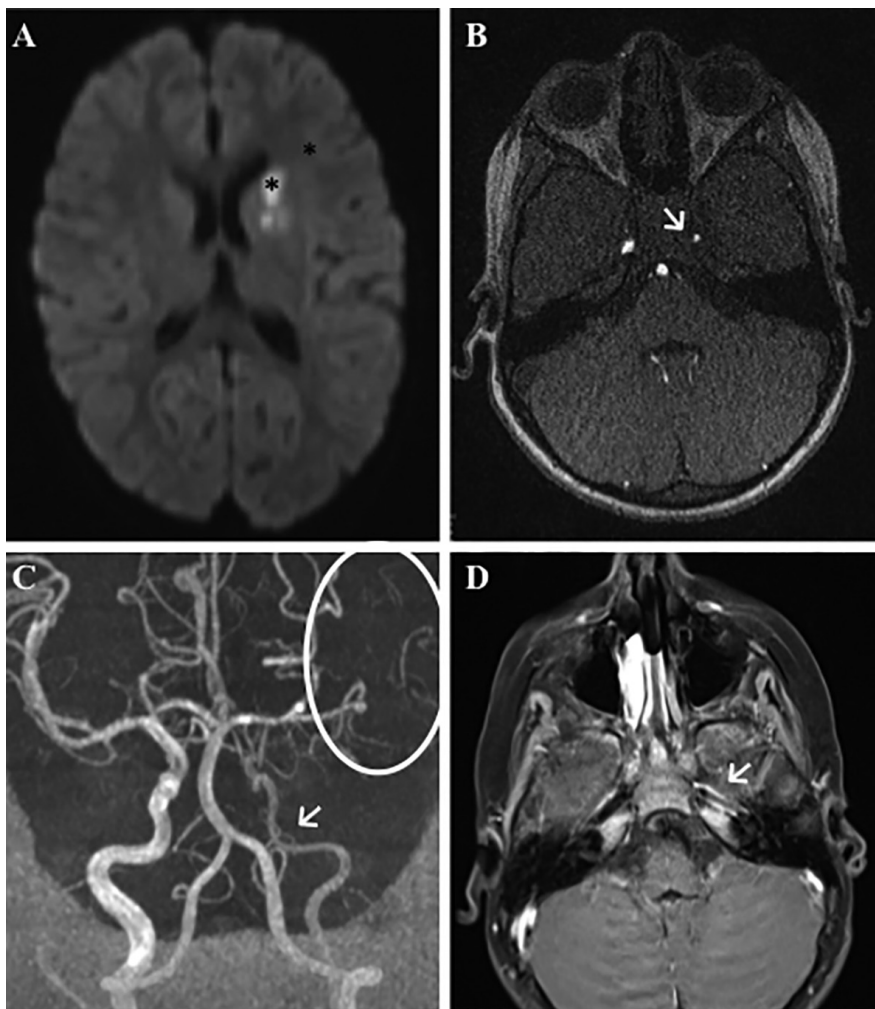
**Fig. 3.** MRI findings in a 9-year old girl with PACNS, 2 days after the onset of symptoms. A) Axial diffusion weighted imaging (DWI,  $b=1000s/mm^2$ ), showing fresh lesions in the right frontoparietal region with reduced diffusivity (\*). B) Single image from 3 dimensional time-of-flight (TOF) and C) Maximum intensity projection (MIP) of 3D time-of-flight (TOF) angiogram, unveiling an occlusion and stenosis of the right internal carotid artery (→). In C) arterial wall thickening of the right internal carotid artery with luminal obstruction can be seen (↓).

was started as steroid-sparing treatment (1000 mg/m<sup>2</sup>/d) (Table II). Seven days after the last relapse, antiplatelet-therapy was expanded with clopidogrel (0.5 mg/kg/d), and heparin treatment was tapered and finally discontinued. A follow-up MRI, six months after the initial manifestation, revealed a stable situation. Clopidogrel was discontinued after nine months, MMF was discontinued after 18 months, while ASA is still administered. To date, no further relapse occurred (in 42 months). While

the boy retained a mild hemiparesis on his right side as well as attention deficit and reduced working memory, he attends a regular school.

### Case 3

A nine-year-old, previously healthy girl presented with a two-day history of severe headaches, nausea, and emesis (Table I). Additionally, she exhibited acute dysphasia, facial nerve palsy, and hemiparesis of her left upper and lower extremities. Magnetic resonance imag-



**Fig. 4.** MRI findings in a 3.5-year old girl with PACNS, approximately three weeks after onset of first symptoms. A) Axial diffusion weighted imaging (DWI,  $b=1000s/mm^2$ ), showing fresh lesions in the left basal ganglia with reduced diffusivity (\*). B) Single image from 3D time-of-flight (TOF) angiogram and C) Maximum intensity projection (MIP) of 3D time-of-flight (TOF), unveiling an obstruction and stenosis of the left internal carotid artery (arrows). D) Transversal gadolinium enhanced T1 sequences with fat saturation unveiled contrast enhancement of the prominent arterial wall as a sign of vasculitis (arrow).

ing 2 days after the onset of symptoms revealed reduced proton diffusion capacity of the right cortical hemisphere, reflecting parenchymal damage due to an occlusion of the internal carotid artery distal to the posterior communicating artery, as seen on TOF angiography MRI (Fig. 3 B, C). The patient was started on therapeutic doses of UFH. On day 4, the girl developed clinical progression of hemiparesis, slurred speech, and a decline in vigilance. The subsequent brain MRI did not reveal new brain lesions, but signs of large vessel inflammation, including arterial wall thickening, and contrast enhancement. Provided general symptoms and the long segment involvement of the

arteria cerebri interna, the diagnosis progressive pPACNS was made.

Methylprednisolone *i.v.* pulses (20 mg/kg) were given over five days, and the patient was started on steroid-sparing immunomodulatory treatment with MMF (1000mg/m<sup>2</sup>/d) for 18 months (Table II). After twelve days, heparin treatment was tapered to a prophylactic dose for an additional five days, overlapping dual anti-platelet-therapy with clopidogrel (0.5 mg/kg/d) and ASA (2.7 mg/kg/d). To date, no further clinical relapse occurred (30 months). The patient has a mild paresis of the right hand as well as attention deficits and impaired memory. Follow-up MRIs revealed complete resolution of inflam-

mation, while arterial wall-thickening remained (Fig. 3).

#### Case 4

A three and a half year-old girl presented with progressive paresis of the right arm, ataxia, and slurred speech that had started approximately three weeks prior to admission (Table I). Patient's prior history included delayed speech development.

While all aforementioned patients had been vaccinated according to national recommendations, the child had suffered a wild-type varicella infection about six months prior to admission. Magnetic resonance imaging at admission indicated pre-existing and recent infarctions in the left hemisphere. Altered proton diffusion capacity (Fig. 4A), reduced vessel calibers on TOF angiography (Fig. 4B), and contrast enhancement in T1 sequences with fat saturation (Fig. 4C) suggested vasculitis of the left internal carotid artery, mid-cerebral artery, and anterior cerebral artery. Ultrasound examination unveiled pathological intima thickening of the common carotid and left internal carotid artery. Provided the rapidly progressing symptoms and long segment involvement of proximal and distal cerebral vessels, the diagnosis progressive pPACNS was made. The girl was started on therapeutic UFH treatment and ASA (3 mg/kg/d). Four days after initiation of heparin treatment, it was replaced with clopidogrel (1 mg/kg/d). Methylprednisolone *i.v.* pulses (20 mg/kg/d) were given for five days, followed by oral prednisolone (tapering over three months), and immunomodulatory treatment with MMF (1000 mg/m<sup>2</sup>/d) (Table II). Over the observation period of 15 months, no relapses occurred. In addition to the pre-existing mild speech disorder, a mild paresis of the right hand remained.

#### Discussion

In contrast to adults, acute ischaemic stroke (AIS) is a rare entity in childhood (1). Furthermore, the pathophysiology in paediatric AIS often differs from adults, with vasculitic lesions being the most frequent cause after the neonatal period. In concordance with

the nomenclature in systemic disease, primary angiitis of the CNS (PACNS) requires differentiation from secondary causes, which include infections, inflammatory and non-inflammatory collagen vascular diseases, and malignancies (16, 17). Here, we report four exemplary cases of progressive pPACNS in childhood; two in boys and two in girls. While our small cohort exhibits equal gender distribution, typically a male preponderance is observed in childhood pPACNS (f:m=2:3) (17).

Important differential diagnoses to childhood PACNS include inflammatory conditions secondary to other inflammatory and/or non-inflammatory CNS or systemic diseases (including infections), such as primary or secondary systemic vasculitis with CNS involvement (*e.g.* SLE, Takayasu arteritis, etc.), Moyamoya syndrome, fibromuscular dysplasia, arterial dissections, and others (17-19).

Of note, a significant subset of patients with transient pPACNS/TCA exhibit a history of varicella zoster virus (VZV) infections within 12 months prior to disease-onset (up to 50%), suggesting a pathophysiological link between VZV infections and pPACNS (15, 18). To our knowledge, reliable data on concurrent or recent VZV infection rates do not exist for progressive forms of pPACNS (case 4 in this report). Though the pathophysiological role of VZV in pPACNS has not been scientifically proven, high rates of recent infections suggest an involvement at least in non-progressive forms of pPACNS. Thus, in such cases, the term "primary angiitis" may be considered somewhat incorrect. In line with the existing literature, the pathophysiological role of a previous VZV infection 6 months prior to disease-onset in Case 4 remains unclear. In the presented patient, particularly since clinical presentation and MRI angiography were indicative for progressive pPACNS, VZV was not treated with acyclovir, and the patient responded to induction therapy with high-dose corticosteroids followed by maintenance treatment with MMF.

Transient pPACNS/TCA is generally considered a self-limiting condition, and some authors even argue that in-

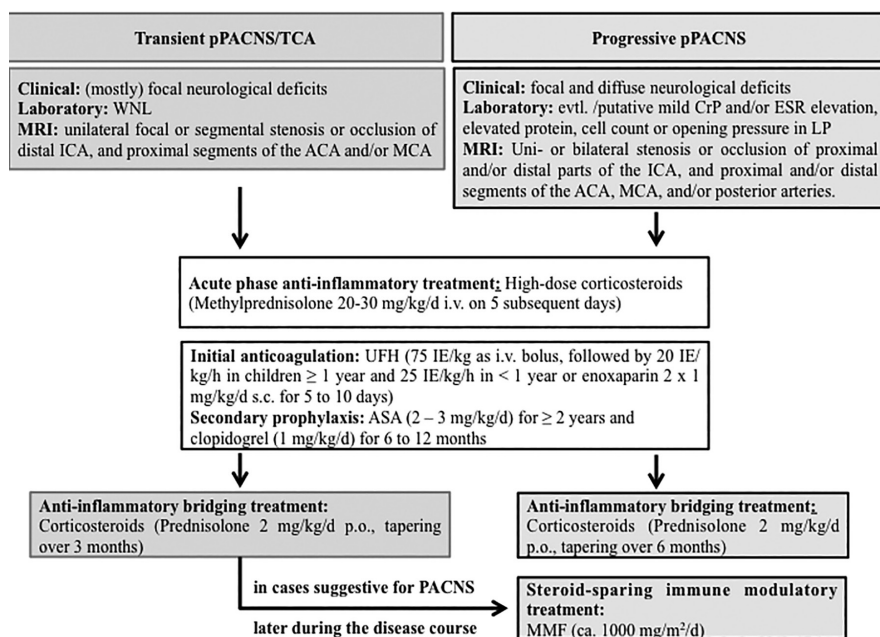
dividual patients may not require immune suppressive or modulating treatment at all. Though the inflammatory phase of non-progressive pPACNS/TCA is transient, almost 60% of children with AIS develop permanent neurological or neurocognitive deficits, and almost 80% retain residual arterial lesions (15). At the time of manifestation, differentiation between progressive and transient pPACNS can be difficult. However, depending on the pattern of affected vessels and resulting clinical symptoms, individuals with transient disease may be distinguished from such individuals at the beginning of a progressive disease course. Transient pPACNS is characterized by short segment involvement of a single artery. Thus, most patients with monophasic pPACNS/TCA present with focal neurological deficits, sometimes headaches, and/or encephalopathy depending on the area affected. Conversely, patients with progressive PCANS exhibit long segment involvement of proximal and distal cerebral vessels, more severe systemic symptoms, and sometimes elevated systemic inflammatory markers (in up to 50%) (6, 8, 9, 12, 13). Because of the rapidly progressive character in the presented cases, long segment involvement of proximal and distal segments of the affected vessels, the diagnosis progressive pPACNS was made, and all patients were treated accordingly.

As childhood AIS is rare, treatment approaches in childhood pPACNS vary significantly throughout the literature. Reported strategies include acute phase and maintenance treatment. In the acute phase, depending on the time-line and duration of symptoms, mechanical thrombectomy or thrombolysis may be discussed in individual cases. However, provided the lack of experience in the pediatric age group, neither approach is generally recommended outside of specific research protocols. In one of the here reported patients (case 1), mechanical thrombectomy and temporary stent implantation was performed, as the basilar artery was occluded (19). Anticoagulant treatment is based on the actual guidelines of the American College of Chest Physicians

and includes unfractionated heparin, low molecular weight heparin or ASA, followed by anti-platelet therapy with ASA or clopidogrel for a minimum of two years (19).

Controlling inflammation is central for preventing disease progression and improving disease outcomes. However, evidence-based and/or widely accepted protocols for anti-inflammatory or immune modulating treatment of transient or progressive pPACNS are lacking. Applied regimens for induction treatment include methylprednisolone *i.v.* pulses or oral corticosteroids, both followed by tapering strategies (usually over 3-6 months), and cyclophosphamide *i.v.* every 4 weeks for up to 6 months (8). For maintenance treatment, low-dose corticosteroids, MMF, or other purine- or pyrimidine antagonists are discussed (8). All of the here reported pPACNS patients were diagnosed with progressive disease, and treated with anticoagulatory agents, corticosteroids, and MMF. Three children suffered recurring brain ischemia under exclusive anticoagulation treatment prior to the initiation of immune modulation. In our institution, patients diagnosed with progressive pPACNS are usually treated with high-dose methylprednisolone *i.v.* pulses (20-30 mg/kg/d) to impede acute inflammatory responses, followed by oral corticosteroids for 3-6 months, and immune modulatory treatment with MMF in combination with dual antiplatelet therapy (with ASA and clopidogrel). All of the here reported patients remained relapse free after the initiation of immune modulatory treatment.

However, in two children (cases 1 and 2), the diagnosis progressive PACNS was only made after several relapses, and patients would potentially have benefitted from an earlier introduction of anti-inflammatory treatment. The reduced "time to correct diagnosis" and subsequent treatment initiation in the here presented cases, together with improved outcomes of pPACNS patients indicate a learning curve in our institution and the interdisciplinary approach. Thus, in our (and other authors') opinion, the diagnosis progressive pPACNS should not be solely based on the pro-



**Fig. 5.** Suggested therapeutic interventions in PACNS. Typical clinical, laboratory, and imaging findings are provided for transient (grey boxes) and progressive (black boxes) pPACNS. Therapeutic approaches for PACNS chosen in our institution are provided. Where identical, treatment suggestions are outlined in white boxes, where differential treatment is suggested, grey (for transient disease) or black (for progressive disease) boxes are displayed. In unclear cases, we suggest treatment following our empiric protocol for progressive pPACNS. Abbreviations: Internal carotid artery – ICA; arteria cerebri anterior – ACA; arteria cerebri media – ACM.

gression of inflammatory lesions over 6 months, but rather on clinical symptoms, laboratory tests, and vasculopathy patterns on MRI (6, 8, 9, 12, 13). Furthermore, high-dose corticosteroid treatment should at least be considered in all pPACNS patients to rapidly control inflammatory activity and prevent (progressive) vascular stenosis (Fig. 5). After the initiation of immune modulatory treatment with corticosteroids and MMF, all of our cases achieved stable remission without further relapses. Thus, it is worth discussing whether cyclophosphamide, which is suggested by some authors (6, 8), is necessary for the treatment of progressive pPACNS. Based on our (certainly limited) experience, high-dose corticosteroids for remission induction, followed by MMF as maintenance treatment may be sufficient at least in most cases. To finally answer the question of which treatment option may be the safest and most effective alternative in individual PACNS patients, randomized prospective multi-center studies are necessary to determine optimal treatment with minimal treatment-associated side-effects. However, it may prove difficult

to identify and recruit sufficient numbers of patients in this rare and variable entity.

A particular challenge in individual patients can be the prediction of clinical courses, distinguishing between transient or progressive PACNS. Since short-term corticosteroid treatment and immune modulation with MMF are usually tolerated without severe long-term sequelae, while ischemic stroke may affect an individual's further development, cognitive, and/or motor skills, we argue to initially treat all pPACNS patients, including those with both transient and progressive disease, with corticosteroids, and to include steroid-sparing agents, such as MMF, in cases suggestive of progressive disease (6, 8) (Fig. 5).

### Conclusions

Paediatric primary angiitis of the CNS (pPACNS) are rare disorders, but account for a large portion of ischemic brain injuries in childhood. Outcomes depend largely on a timely and correct diagnosis, ensuring sufficient treatment to prevent disease progression and/or relapses. Thus, patients should be di-

agnosed and treated in an experienced multi-professional team, including pediatric intensive care providers, pediatric radiologists, neuro-paediatricians, and pediatric rheumatologists/ immunologists. To date, treatment regimens are based on case reports, small case collections, and expert opinions. Studies are urgently warranted, comparing applied treatment regimens, in order to ensure optimal treatment outcomes. We conclude that initial anticoagulation with unfractionated heparin, followed anti-platelet therapy with ASA and/or clopidogrel, in combination with immune modulating treatment with high-dose corticosteroids in the acute phase, followed by steroid-sparing maintenance treatment with mycophenolate mofetil, may be effective and safe in childhood progressive pPACNS.

### Acknowledgements

The authors thank Prof. Dr. M Steinlin, Neuropediatrics, University Children's Hospital, Inselspital, Bern, Switzerland, for insightful discussion in one of the presented cases, and PD Dr. J. Gerber, Institut und Poliklinik für Neuro-radiologie, Medizinische Fakultät Carl Gustav Carus, Technische Universität Dresden, Germany, for helpful discussion and temporary stent implantation into the basilar artery in one patient. We thank Christine R. Hedrich for critically reading the manuscript and language editing.

### References

- LYNCH JK, HIRTZ DG, DEVEBER G, NELSON KB: Report of the National Institute of Neurological Disorders and Stroke workshop on perinatal and childhood stroke. *Pediatrics* 2002; 109: 116-123.
- STRATER R, BECKER S, VON ECKARDSTEIN A *et al.*: Prospective assessment of risk factors for recurrent stroke during childhood—a 5-year follow-up study. *Lancet* 2002; 360: 1540-1545.
- GANESAN V, PRENGLER M, WADE A, KIRKHAM FJ: Clinical and radiological recurrence after childhood arterial ischemic stroke. *Circulation* 2006; 114: 2170-7.
- AMLIE-LEFOND C, BERNARD TJ, SEBIRE G *et al.*: Predictors of cerebral arteriopathy in children with arterial ischemic stroke: results of the International Pediatric Stroke Study. *Circulation* 2009; 119: 1417-23.
- AMLIE-LEFOND C, SEBIRE G, FULLERTON HJ: Recent developments in childhood arterial ischaemic stroke. *Lancet Neurol* 2008; 7: 425-35.

6. TWILT M, BENSELER SM: The spectrum of CNS vasculitis in children and adults. *Nat Rev Rheumatol* 2012; 8: 97-107.
7. ELEFANTE E, TRIPOLI A, FERRO F, BALDINI C: One year in review: systemic vasculitis. *Clin Exp Rheumatol* 2016; 34 (Suppl. 97): S1-6.
8. TWILT M, BENSELER SM: Childhood inflammatory brain diseases: pathogenesis, diagnosis and therapy. *Rheumatology (Oxford)* 2014; 53: 1359-68.
9. TWILT M, BENSELER SM: Central nervous system vasculitis in adults and children. *Handb Clin Neurol* 2016; 133: 283-300.
10. SEBIRE G: Transient cerebral arteriopathy in childhood. *Lancet* 2006; 368: 8-10.
11. AVIV RI, BENSELER SM, SILVERMAN ED *et al.*: MR imaging and angiography of primary CNS vasculitis of childhood. *AJNR Am J Neuroradiol* 2006; 27: 192-9.
12. BENSELER SM: Central nervous system vasculitis in children. *Curr Rheumatol Rep* 2006; 8: 442-9.
13. BENSELER SM, SILVERMAN E, AVIV RI *et al.*: Primary central nervous system vasculitis in children. *Arthritis Rheum* 2006; 54: 1291-7.
14. SEBIRE G, FULLERTON H, RIOU E, DEVEBER G: Toward the definition of cerebral arteriopathies of childhood. *Curr Opin Pediatr* 2004; 16: 617-622.
15. BRAUN KP, BULDER MM, CHABRIER S *et al.*: The course and outcome of unilateral intracranial arteriopathy in 79 children with ischaemic stroke. *Brain* 2009; 132 (Pt 2): 544-57.
16. GOEGGEL SIMONETTI B, RITTER B, GAUTSCHI M *et al.*: Basilar artery stroke in childhood. *Dev Med Child Neurol* 2013; 55: 65-70.
17. GOLOMB MR, FULLERTON HJ, NOWAK-GOTTL U, DEVEBER G, INTERNATIONAL PEDIATRIC STROKE STUDY GROUP: Male predominance in childhood ischemic stroke: findings from the international pediatric stroke study. *Stroke* 2009; 40: 52-7.
18. ASKALAN R, LAUGHLIN S, MAYANK S *et al.*: Chickenpox and stroke in childhood: a study of frequency and causation. *Stroke* 2001; 32: 1257-62.
19. MONAGLE P, CHAN AK, GOLDENBERG NA *et al.*: Antithrombotic therapy in neonates and children: Antithrombotic Therapy and Prevention of Thrombosis, 9<sup>th</sup> ed: American College of Chest Physicians Evidence-Based Clinical Practice Guidelines. *Chest* 2012; 141 (Suppl.): e737S-801S.