

SHORT COMMUNICATION

The role of time-resolved imaging of contrast kinetics (TRICKS) magnetic resonance angiography (MRA) in the evaluation of head–neck vascular anomalies: a preliminary experience

¹A Romano, ²F Tavanti, ²M C Rossi Espagnet, ³V Terenzi, ³A Cassoni, ⁴G Suma, ²A Boellis, ⁵A Pierallini, ³V Valentini and ²A Bozzao

¹San Raffaele Foundation Rome, Rehabilitation Facility Ceglie Messapica, Rome, Italy; ²NESMOS, Department of Neuroradiology, Sant' Andrea Hospital, University Sapienza, Rome, Italy; ³Department of Odontostomatological Science and Maxillofacial Surgery, Sapienza University of Rome, Policlinico Umberto I, Rome, Italy; ⁴Department of Radiology, Madonna della Fiducia Institute, Rome, Italy; ⁵IRCSS San Raffaele Pisana, Department of Radiology, Rome, Italy

Objectives: In this preliminary report, we describe our experience with time-resolved imaging of contrast kinetics–MR angiography (TRICKS-MRA) in the assessment of head–neck vascular anomalies (HNVA).

Methods: We prospectively studied six consecutive patients with clinically suspected or diagnosed HNVA. All of them underwent TRICKS-MRA of the head and neck as part of the routine for treatment planning. A digital subtraction angiography (DSA) was also performed.

Results: TRICKS-MRA could be achieved in all cases. Three subjects were treated based on TRICKS-MRA imaging findings and subsequent DSA examination. In all of them, DSA confirmed the vascular architecture of HNVA shown by TRICKS-MRA. In the other three patients, a close follow up to assess the evolution of the suspected haemangioma was preferred.

Conclusions: TRICKS sequences add important diagnostic information in cases of HNVA, helpful for therapeutic decisions and post-treatment follow up. We recommend TRICKS-MRA use (if technically possible) as part of routine MRI protocol for HNVA, representing a possible alternative imaging tool to conventional DSA.

Dentomaxillofacial Radiology (2015) **44**, 20140302. doi: [10.1259/dmfr.20140302](https://doi.org/10.1259/dmfr.20140302)

Cite this article as: Romano A, Tavanti F, Rossi Espagnet MC, Terenzi V, Cassoni A, Suma G, et al. The role of time-resolved imaging of contrast kinetics (TRICKS) magnetic resonance angiography (MRA) in the evaluation of head–neck vascular anomalies: a preliminary experience. *Dentomaxillofac Radiol* 2015; **44**: 20140302.

Keywords: magnetic resonance angiography; head and neck; digital subtraction angiography

Introduction

Head–neck vascular anomalies (HNVA) are congenital aberrancies of vascular development; their clinical appearance depends on their depth and phase of growth.¹ The diagnosis of haemangiomas or vascular malformations is most often a clinical one; imaging plays

a pivotal role in the diagnosis of more challenging cases and in planning the therapeutic approach that may consist of pharmacological embolization, sclerotherapy or surgery.²

Doppler ultrasonography is the first imaging modality used to characterize maxillofacial superficial lesions and their haemodynamic conditions; despite this, Doppler ultrasonography is not able to depict the real extension and, most importantly, the vascular anatomy

of complex HNVAs.³ CT may provide further information by identifying calcifications and in demonstrating involvement of major vessels after contrast injection.⁴ Dynamic CT acquisition during contrast injection might also be acquired, but they use considerable X-ray dosages (avoidable especially in young patients).

MRI and MR angiography (MRA) represent the best diagnostic tools to demonstrate, respectively, soft-tissue components and relationships with nearby structures and to provide useful information on HNVA feeding vessels.⁵ Conventional non-contrast MRA techniques, such as time-of-flight and phase-contrast MRA, as well as contrast-enhanced MRA, may allow identification of lesions but they produce static images and cannot detect smallest vessels.^{5,6}

Time-resolved imaging of contrast kinetics (TRICKS) is a recently introduced keyhole technique that improves temporal resolution with respect to contrast-enhanced MRA technique; by this, one can obtain dynamic images during the arterial, capillary and venous phases.^{5–7} Using this sequence, it is possible to acquire three-dimensional volumes during the passage of gadolinium (GD), to detect the vascularization of the region of interest over time, similar to digital subtraction angiography (DSA).⁸ Previous investigations have demonstrated the advantages of applying this sequence to visualize vascular lesions, such as peripheral, intracranial, extracranial or head and neck arteriovenous malformations.^{5–10} All authors have stressed the clinical importance of TRICKS to verify the haemodynamic characteristics of lesions, its rapid acquisition and its role in their therapeutic management. Other studies assessed an excellent interobserver agreement when comparing TRICKS to DSA, evaluating extracranial arteriovenous malformations or arteriovenous malformations of head and neck, their feeding arteries, drainage veins and the extent of nidus.^{6,7} DSA is an invasive, relatively expensive, time consuming technique, with risk of vascular injury and exposure to ionization.^{6,7}

In this preliminary report, we describe our experience with TRICKS-MRA to verify its impact on diagnosis and perioperative management in the primary assessment of HNVAs.

Methods and materials

We prospectively evaluated by means of MRI six consecutive patients with clinically suspected or diagnosed HNVAs. All of them underwent TRICKS-MRA of the head and neck as part of the routine work for treatment planning. The institutional ethics committee of Sant' Andrea Hospital of Rome, Rome, Italy, approved this work, and informed consent was obtained from the patients.

Conventional MR examinations were performed by using a 1.5-T magnet (Signa Excite HD; GE Healthcare, Milwaukee, WI) equipped with surface coil (eight-

channel head array). The following sequences were acquired: axial fat saturation T_1 and T_2 weighted images and coronal T_2 weighted images. Standard contrast medium-based intravenous agents were used (Gadovist[®]; Bayer Healthcare Pharmaceuticals, Leverkusen, Germany), and axial, sagittal and coronal fat saturation T_1 weighted images post-GD were acquired.

The three-dimensional TRICKS parameters were as follows: repetition time/echo time, 5.4/1.8 ms; flip angle, 45°; field of view (FOV), 28 cm; matrix, 320 × 192 pixels; slice thickness, 1.2 mm; and bandwidth, 41.67 MHz. A slab of 36–42 partitions was oriented on the sagittal plane to cover the entire lesion. The temporal resolution was 3–4 s for each phase (depending on the number of partitions), and a total of 15 phases were acquired within 2 min.

A first phase of three-dimensional data were obtained prior to injecting the contrast agent and then the scanning of subsequent phases began simultaneously with the initiation of contrast injection (bolus of GD at a rate of 3 ml s⁻¹ followed by a saline flush of at least 15 ml on a power injector). Complex subtraction of the pre-contrast phase (mask) was performed automatically to maximally suppress signal from background tissues. Feeding arteries as well as the type of enhancement (either arterial or venous) were evaluated.

DSA was performed in all patients. To compare DSA to TRICKS-MRA, both feeding arteries and the type of enhancement were evaluated.

Results

All patients presented occasional swelling of the cheek, symptoms increased with Valsalva manoeuvre in Patient 3 and during mastication in Patient 5. MRI, TRICKS-MRA and DSA examinations were obtained in all patients. The site and the type of vascular component of HNVAs are reported in Table 1.

In Patient 1 (Figure 1), a deep haemangioma located between the temporal and masseter muscles on the right side was suspected; TRICKS and DSA examinations documented an early arterial enhancement of a small tissue component, while most of the lesion was characterized by a slower venous enhancement. Only DSA, in a selective study of maxillary artery, showed a small feeding artery that reached the vascular lesion. Embolization treatment was preferred; after 6 months, poor volumetric cytorreduction was appreciable. Sclerotherapy was planned.

In Patient 4 (Figure 2), MRI examination revealed a venous malformation involving the right platysma, close to the jaw border. After GD, only the deep portion of the lesion showed enhancement, whereas TRICKS documented a little area of late enhancement after contrast medium injection inside the lesion, it was absent in the early phase of DSA. For this reason, sclerotherapy was performed; after 10 months, a subtotal regression of lesion was obtained (confirmed by TRICKS).

Table 1 The location, vascular enhancement characteristics, treatment (only in three patients) and follow-up conditions of head–neck vascular anomalies in this study

<i>Patients</i>	<i>Location</i>	<i>TRICKS</i>	<i>Treatment</i>	<i>Follow-up</i>
1	Close to the anterior border of the right masseter	Small component with early arterial enhancement	Embolization	Unchanged
2	Close to the inferior border of the right masseter	Small component with early arterial enhancement	–	Unchanged
3	Right masseter	Late venous enhancement	–	Unchanged
4	Right platysma close to the border of the jaw	Late venous enhancement	Sclerotherapy	No recurrence after treatment
5	Left masseter	Small component with early arterial enhancement	Embolization + surgery	No recurrence after treatment
6	Right masseter	Small component with early arterial enhancement	–	Unchanged

TRICKS, time-resolved imaging of contrast kinetics.

In Patient 5 (Figure 3), MRI documented a suspected haemangioma with diffuse enhancement post-GD into the left masseter muscle. TRICKS images demonstrated an early arterial enhancement in the upper portion of the

lesion, while most of the vascular mass was characterized by a slow venous enhancement. DSA investigation demonstrated similar results, with a vascular enhancement located close to the facial artery. The patient underwent

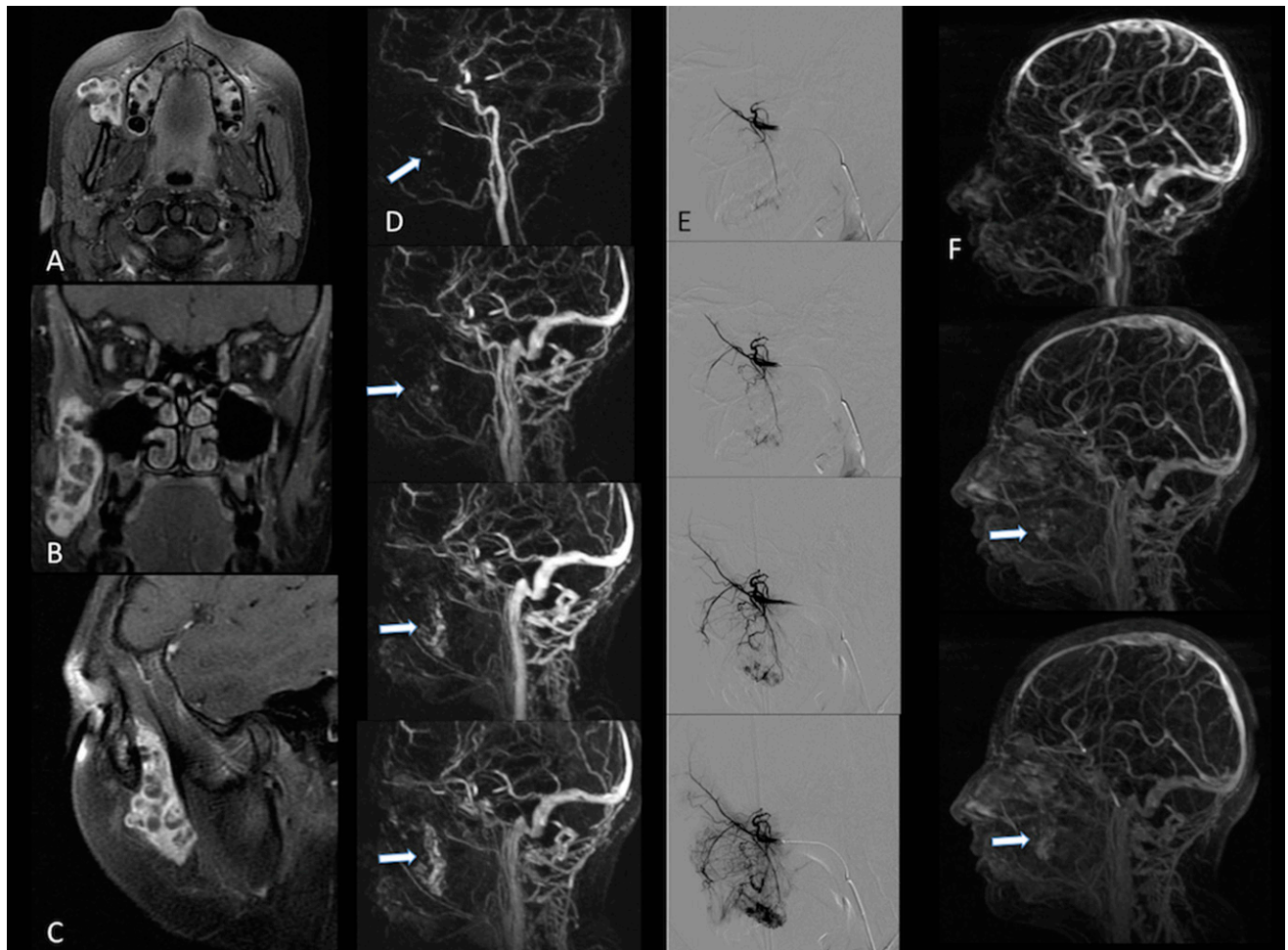


Figure 1 A 15-year-old girl (Patient 1) with tenderness and occasional swelling of the right cheek of about 1 month duration. MRI examination shows a mass lesion close to the anterior margin of the right masseter muscle (a–c). Time-resolved imaging of contrast kinetics (TRICKS) images (d) document a small tissue component with an early arterial enhancement, while the majority of the lesion is characterized by a slow venous enhancement (arrows). Digital subtraction radiography confirms these findings [selected angiogram of internal maxillary artery, (e)]. In TRICKS images after embolization (f), the residual component of haemangioma is evident (arrows).

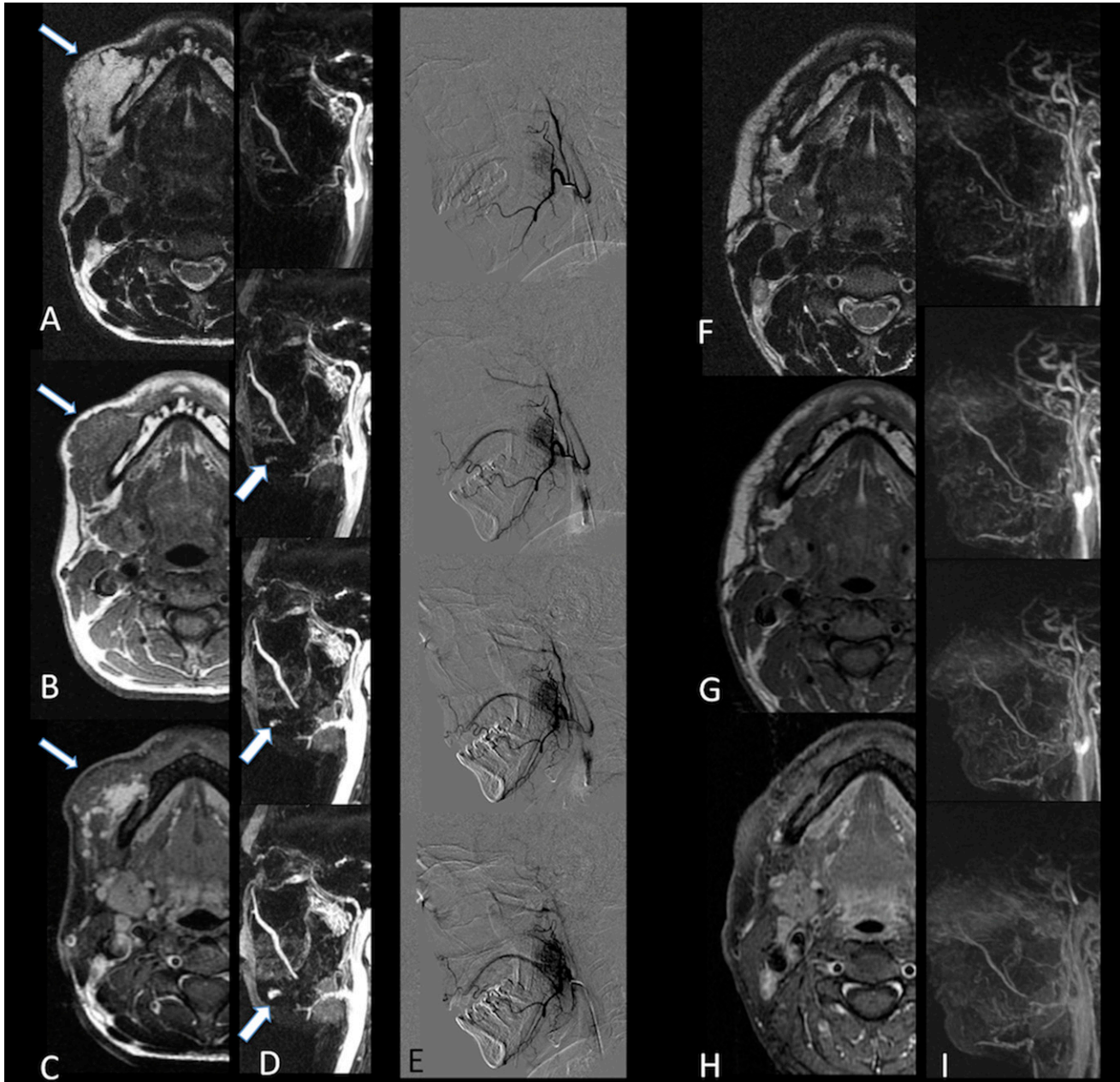


Figure 2 A 44-year-old female (Patient 4) with a right cheek swelling that grew slowly. MRI examination reveals a mass that involves right platysma, close to the jaw border (a–c, thin arrows). After gadolinium, the mass lesion shows enhancement only in its deepest portion (c, thin arrow). Time-resolved imaging of contrast kinetics documents a little area of late enhancement after contrast medium injection inside the lesion (d, thick arrows), absent in early phase of digital subtraction radiography (e). After sclerotherapy, a subtotal regression of lesion is appreciable (f–i).

embolization, but an aesthetic problem was still evident after embolization, and surgery was performed. Conventional MRI and TRICKS confirmed total removal of the lesion.

In the other three patients (Patients 2, 3 and 6), TRICKS showed only delayed, venous enhancement inside the lesions, all located close to the masseter muscles. DSA confirmed these data showing very small feeding arteries with delayed venous enhancement. Because of these results, a close follow-up to assess the evolution of the vascular malformations was preferred.

Discussion

In this preliminary report, we demonstrated that TRICKS-MRA can provide useful information in the management of patients with HNVAs. The identification of the vascular pattern by TRICKS-MRA was used, according to DSA, to plan treatment, considering both the haemodynamic and the feeding arteries of lesions.

TRICKS-MRA uses an algorithm that improves temporal resolution, although spatial resolution is

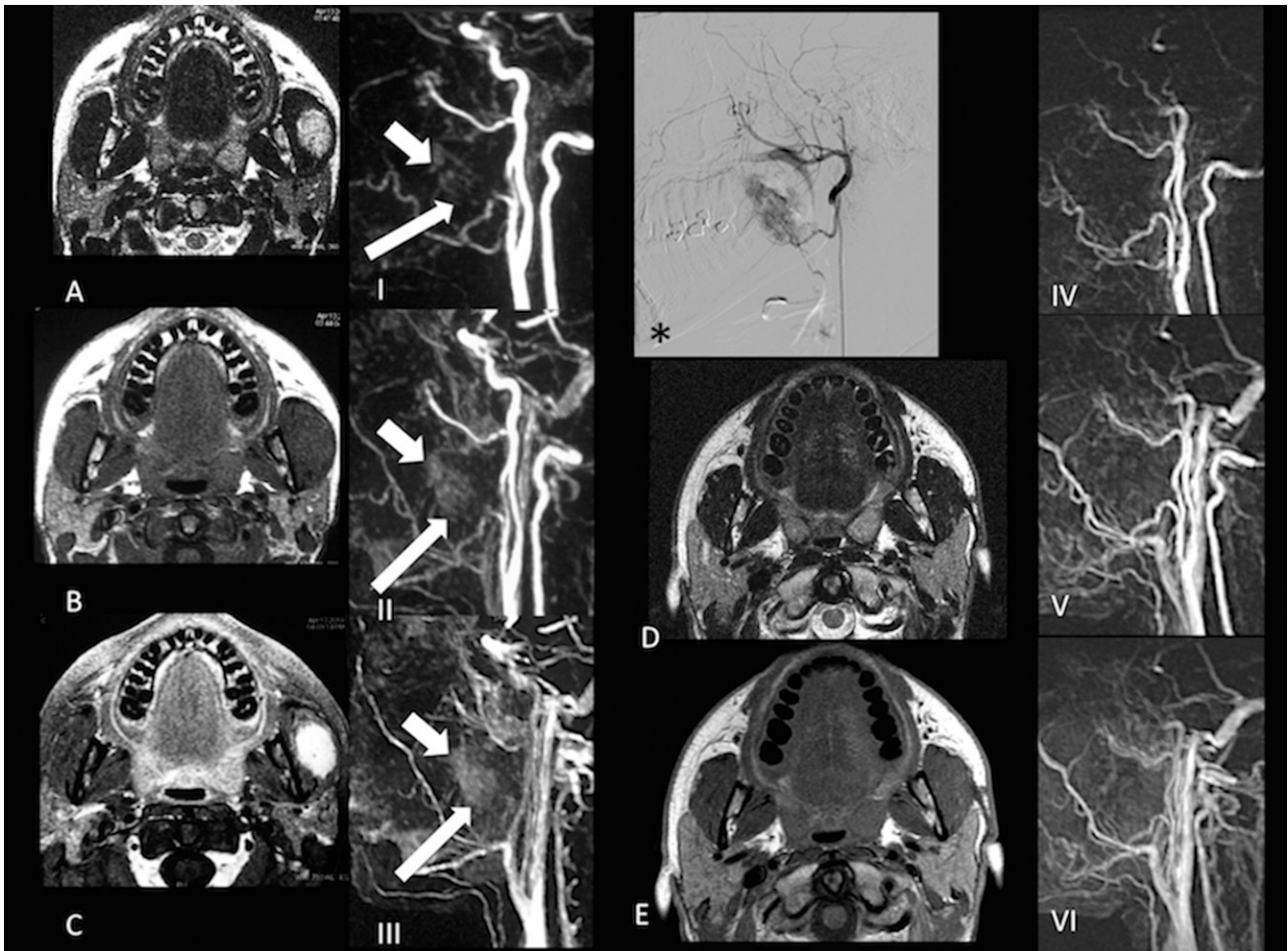


Figure 3 A 28-year-old girl (Patient 5) with painful mastication in the presence of a tumefaction on the left cheek. MRI shows an oval lesion with diffuse enhancement post-gadolinium (a–c). (I–III) Time-resolved imaging of contrast kinetics (TRICKS) images demonstrate an early arterial enhancement (thick arrows), while the majority of the lesion is characterized by a slow venous enhancement (thin arrows). These findings are confirmed by digital subtraction radiography (*). Post-operative imaging (d, e) shows total removal of the vascular lesion, confirmed by TRICKS images (IV–VI).

decreased. The improvement of temporal resolution enables clear separation of arterial inflow from venous drainage, allowing the possibility of acquiring information concerning contrast material arrival time and flow direction.⁶ This was confirmed in our study because arterial or venous phase of enhancement as assessed by TRICKS-MRA was in agreement with DSA.

Despite this, there is no evidence that TRICKS can replace DSA. DSA is still indicated for large lesions, such as arteriovenous malformations, as DSA is able to identify the arterial pedicles feeding the lesion for pre-operative embolization, which reduces the risk of perioperative bleeding.¹¹ This information is clearly underestimated by TRICKS-MRA.

Not surprisingly, previous investigations assessed a good interobserver agreement when comparing TRICKS to DSA.^{6,7} Higashihara *et al*⁷ reported comparable findings between TRICKS and DSA examinations in extracranial arteriovenous malformations;

similar results were obtained by Razek *et al*⁶ in a recent study about arteriovenous malformations of head and neck. The authors assessed that TRICKS-MRA may reduce the need for routine catheter angiography of diagnostic purpose especially in children and young adults.

Recently, some authors demonstrated the possibility of differentiating HNVAs by maximizing the temporal enhancement pattern of vessels that TRICKS imaging so nicely demonstrates.² The same authors constructed a “TRICKS enhancement pattern” useful to differentiate HNVAs. As reported, haemangiomas, different from venous malformations with late enhancement, showed early arterial enhancement without the evidence of a dilated draining vein.²

In our experience, a similar behaviour was appreciable in HNVAs studied with TRICKS and DSA examinations. The low spatial resolution of TRICKS did not allow demonstration of small feeding arteries, as

reported in Patient 1. Despite this, TRICKS was able to describe the different vascular enhancements in all cases; thus providing pivotal information for the treatment planning. In those cases in which follow up was preferred, DSA and TRICKS results were comparable, showing a similar pattern of enhancement. The same was true also in Patients 4 and 5. Based on these results, one could argue that DSA could be avoided when TRICKS shows slow filling of HNVA.

Many treatments of the HNVAs (cryotherapy, radiation therapy, sclerotizing agents, blood vessel ligation, embolization and surgical removal) should be individualized based on tumour location, size, depth of tissue invasion, accessibility, patient age and cosmetic appearance.¹¹

Although rarely performed, surgery may be necessary for patients with large HNVAs. Possible bleeding, neural injury or post-operative facial nerve dysfunction are factors limiting surgical approaches.¹² In cases of large lesions, surgical excision is usually performed after pre-operative embolization using an intraoral approach (if possible);^{13,14} administration of sclerotizing agents

alone can be used in cases of small lesions and can be eventually followed by surgery in lesions that do not show complete resolution.¹⁵ In these cases, the use of more invasive imaging modalities, such as DSA, could be avoided.

Another potential diagnostic contribution provided by TRICKS could be the follow-up evaluation of lesions after treatment. Although this was demonstrated only in three cases, and not being the aim of our study, it is likely that TRICKS could evaluate HNVAs after treatment better than post-GD images.

The small number of cases is the main limitation of our work. We hope that further studies could confirm our result, narrowing the indication of the more costly and invasive DSA to selected cases.

In conclusion, TRICKS-MRA adds important diagnostic information in cases of maxillofacial hemangiomas, helpful for therapeutic decisions and follow up. We think that TRICKS-MRA should be part of routine MRI protocol for HNVAs, before DSA acquisition, with the hope to avoid DSA when possible.

References

- Smith WP, Prince S, Phelan S. The role of imaging and surgery in the management of vascular tumors of the masseter muscle. *J Oral Maxillofac Surg* 2005; **63**: 1746–52.
- Kim JS, Chandler A, Borzykowski R, Thornhill B, Taragin BH. Maximizing time-resolved MRA for differentiation of hemangiomas, vascular malformations and vascularized tumors. *Pediatr Radiol* 2012; **42**: 775–84. doi: [10.1007/s00247-012-2359-5](https://doi.org/10.1007/s00247-012-2359-5)
- Gold L, Nazarian LN, Johar AS, Rao VM. Characterization of maxillofacial soft tissue vascular anomalies by ultrasound and color Doppler imaging: an adjuvant to computed tomography and magnetic resonance imaging. *J Oral Maxillofac Surg* 2003; **61**: 19–31.
- Lee SK, Kwon SY. Intramuscular cavernous hemangioma arising from masseter muscle: a diagnostic dilemma (2006: 12b). *Eur Radiol* 2007; **17**: 854–7.
- Tanaka T, Morimoto Y, Takano H, Tominaga K, Kito S, Okabe S, et al. Three-dimensional identification of hemangiomas and feeding arteries in the head and neck region using combined phase-contrast MR angiography and fast asymmetric spin-echo sequences. *Oral Surg Oral Med Oral Pathol Oral Radiol Endod* 2005; **100**: 609–13.
- Razek AA, Gaballa G, Megahed AS, Elmogy E. Time resolved imaging of contrast kinetics (TRICKS) MR angiography of arteriovenous malformations of head and neck. *Eur J Radiol* 2013; **82**: 1885–91. doi: [10.1016/j.ejrad.2013.07.007](https://doi.org/10.1016/j.ejrad.2013.07.007)
- Higashihara H, Osuga K, Ueguchi T, Onishi H, Tanaka H, Maeda N, et al. Usefulness of contrast-enhanced three-dimensional MR angiography using time-resolved imaging of contrast kinetics applied to description of extracranial arteriovenous malformations: initial experience. *Eur J Radiol* 2012; **81**: 1134–9. doi: [10.1016/j.ejrad.2011.03.040](https://doi.org/10.1016/j.ejrad.2011.03.040)
- Kahana A, Lucarelli MJ, Grayev AM, Van Buren JJ, Burkat CN, Gentry LR. Noninvasive dynamic magnetic resonance angiography with Time-Resolved Imaging of Contrast Kinetics (TRICKS) in the evaluation of orbital vascular lesions. *Arch Ophthalmol* 2007; **125**: 1635–42.
- Grist TM, Mistretta CA, Strother CM, Turski PA. Time-resolved angiography: past, present and future. *J Magn Reson Imaging* 2012; **36**: 1273–86. doi: [10.1002/jmri.23646](https://doi.org/10.1002/jmri.23646)
- Cassoni A, Romano A, Terenzi V, Bartoli D, Buonaccorsi S, Valentini V. Intramasseteric-infiltrating angiolioma: a challenging diagnosis. *J Craniofac Surg* 2012; **23**: e290–2. doi: [10.1097/SCS.0b013e31824e2514](https://doi.org/10.1097/SCS.0b013e31824e2514)
- Odabasi AO, Metin KK, Mutlu C, Başak S, Erpek G. Intramuscular hemangioma of the masseter muscle. *Eur Arch Otorhinolaryngol* 1999; **256**: 366–9.
- Ichimura K, Nibu K, Tanaka T. Essentials of surgical treatment for intramasseteric hemangioma. *Eur Arch Otorhinolaryngol* 1995; **252**: 125–9.
- Pompa V, Brauner E, Bresadola L, Di Carlo S, Valentini V, Pompa G. Treatment of facial vascular malformations with embolisation and surgical resection. *Eur Rev Med Pharmacol Sci* 2012; **16**: 407–13.
- Pompa V, Valentini V, Pompa G, Di Carlo S, Bresadola L. Treatment of high-flow arteriovenous malformations (AVMs) of the head and neck with embolization and surgical resection. *Ann Ital Chir* 2011; **82**: 253–9.
- Mariano FV, Vargas PA, Della Coletta R, Lopes MA. Sclerotherapy followed by surgery for the treatment of oral hemangioma: a report of two cases. *Gen Dent* 2011; **59**: e121–5.