




Available online at  
**ScienceDirect**  
[www.sciencedirect.com](http://www.sciencedirect.com)

Elsevier Masson France  
**EM|consulte**  
[www.em-consulte.com/en](http://www.em-consulte.com/en)



International consensus

## International consensus (ICON) on treatment of Ménière's disease



J. Nevoux<sup>a,b,\*</sup>, M. Barbara<sup>c</sup>, J. Dornhoffer<sup>d</sup>, W. Gibson<sup>e</sup>, T. Kitahara<sup>f</sup>, V. Darrouzet<sup>g</sup>

<sup>a</sup> Department of otology and neurotology, CHU de Bicêtre, AP-HP, 94270 Le Kremlin-Bicêtre, France

<sup>b</sup> Saclay university, Paris-Sud Medical School, 94270 Le Kremlin-Bicêtre, France

<sup>c</sup> Department of otology and neurotology, Sapienza university, Rome, Italy

<sup>d</sup> Department of otolaryngology, head and neck surgery, university of Arkansas for medical sciences and Arkansas Children's Hospital, Little Rock, Arkansas, USA

<sup>e</sup> Department of otolaryngology, head and neck surgery, university of Sydney, Australia

<sup>f</sup> Department of otolaryngology, Nara medical university, Japan

<sup>g</sup> Department of otolaryngology, Skull Base Surgery, CHU de Bordeaux, universit  de Bordeaux, 33000 Bordeaux, France

### ARTICLE INFO

**Keywords:**  
 International consensus  
 M ni re's disease  
 Treatment

### ABSTRACT

**Objective:** To present the international consensus for recommendations for M ni re's disease (MD) treatment.

**Methods:** Based on a literature review and report of 4 experts from 4 continents, the recommendations have been presented during the 21st IFOS congress in Paris, in June 2017 and are presented in this work.  
**Results:** The recommendation is to change the lifestyle, to use the vestibular rehabilitation in the inter-critic period and to propose psychotherapy. As a conservative medical treatment of first line, the authors recommend to use diuretics and Betahistine or local pressure therapy. When medical treatment fails, the recommendation is to use a second line treatment, which consists in the intratympanic injection of steroids. Then as a third line treatment, depending on the hearing function, could be either the endolymphatic sac surgery (when hearing is worth being preserved) or the intratympanic injection of gentamicin (with higher risks of hearing loss). The very last option is the destructive surgical treatment labyrinthectomy, associated or not to cochlear implantation or vestibular nerve section (when hearing is worth being preserved), which is the most frequent option.

  2018 Elsevier Masson SAS. All rights reserved.

### 1. Introduction

M ni re's disease (MD) treatment must be first based on a trustable diagnosis. To be confident with the diagnosis, it is recommended to use the consensual guidelines and classification of the AAO-HNS published in 1995 [1] and recently reviewed by the Equilibrium Committee in 2015 [2]. Although the diagnosis is primarily based on the clinical history, clinicians also utilize various tests to confirm the diagnosis before introduction of any treatment. The next step is to tailor the treatment for each patient based on an algorithm that seems frequently different from one center to another in the same country, even in the same country. During the last IFOS Congress in Paris in June 2017, an international consensus (ICON) Round Table joining six experts of MD from different continents (Asia, America, Europe, and Australia) was designed in trying to draw a minimal consensus, which could be summarized in an

algorithm. But this synthesis revealed highly challenging, as among the countries and/or continents of the participants of this ICON, only two have drawn a consensus or recommendation applicable in their countries, Japan in 2011 and France in 2016 [3]. Scientific literature was assessed using the Level of Evidence classification (1 to 5) and recommendations were given following the grading of recommendations assessment, development and evaluation (GRADE) scoring system.

In MD, the aim of the treatment is first to reduce the frequency, and secondarily the severity, of the vertigo crises, with a minimal impairment of hearing function, hoping this favorable result is associated with a hearing and tinnitus improvement [4]. The treatment is symptomatic and should always be related to the main complain of the patient. It must be conservative in the first place. The conservative treatments are used whatever the hearing function, as destructive ones are preferentially used in patients with hearing loss. Concerning bilateral MD, the difficulty is the unilateral presentation at the beginning and the delay of the contralateral involvement. That is why the treatment should always be conservative. Caregivers must remember the natural evolution of MD, especially the resolution of vertigo,

\* Corresponding author. Otolology and skull base, Bic tre university hospital, AP-HP, 78, rue du G n ral-Leclerc, 94270 Paris, France.  
 E-mail address: [jerome.nevoux@aphp.fr](mailto:jerome.nevoux@aphp.fr) (J. Nevoux).

and the major implication of the placebo effect in any kind of treatment.

Finally, the discussion before and during the congress between participants of ICON Round Table has led to propose a minimal intercontinental consensus on MD treatment, reported here. It reviews the different therapeutic options for the unilateral form, makes a focus on the bilateral form, and proposes a treatment algorithm based on a review of the literature and the authors experience.

## 2. First step: medical treatment of Ménière's disease

The authors recommend (Grade C), as the first care given to the patient, the modification of the lifestyle including well sleeping [5] (Level of proof 4), and a research of an obstructive sleep apnea syndrome [6] (Level of proof 2), decreasing stress, avoiding caffeine, alcohol and tobacco [7] (Level of proof 4) and adopt a low salt diet. Two treatment options should be considered to help the patient: vestibular rehabilitation and psychotherapy [8–10] (Level of proof 2). The vestibular rehabilitation should be avoided during crises and preferentially used in intercritical period. The authors recommend this rehabilitation (Grade B) even if a recent Cochrane review of the literature, using the risk of bias tool, cannot conclude on a positive effect of vestibular rehabilitation on balance and dizziness-related quality of life [8]. But this review studied the effects of vestibular rehabilitation in all unilateral peripheral vestibular dysfunctions, including MD. In this context, it reported moderate to strong evidence that vestibular rehabilitation was a safe and effective management [9] (Level of proof 2). Considering psychotherapy, especially the cognitive behavior therapy intervention, it produces significant improvements in dizziness-related symptoms, disability, and functional impairment among patients with chronic subjective dizziness [10] (Level of proof 2).

Diuretics represent the most commonly used first-line medical treatment. The drug chosen differs from one author to another but, according to the literature, hydrochlorothiazide, acetazolamide and chlorthalidone are used in decreasing order [11,12] (Level of proof 4). The authors recommend their use that may decrease vertigo spell frequency (Grade C). A special attention must be paid to their respective contraindications and side-effects.

Betahistine is very popular in France, Europe, Japan and with many surgeons in Australia but not FDA-approved in USA. The dosage varies from one center to another but the literature reports a better effect with a minimal dosage of 48 mg/d. It could be used up to 288 to 480 mg/d for patient with severe MD who does not sufficiently respond to lower dosages [1–17] (Level of proof 1 and 3). The authors recommend, depending on their country, using betahistine at a dose of 48 to 96 mg/d (Grade C). Even if the side effects for higher dosage seem rare and the efficacy better in some reports, the authors do not give recommendation for these dosages for security reason.

Another non-invasive option is the Meniett® system (Medtronic Cie, the USA), producing sequences of micro-pressure pulses susceptible to act on the endolymphatic hydrops [18]. This device is included of the algorithm treatment in Italy and Australia, even if a recent Cochrane review concludes there is no evidence this therapy is effective [19] (Level of proof 2). Because of the very low rate of side effects reported in the five studies of the Cochrane review, the authors recommend using this device as a first line treatment (professional agreement).

## 3. Second step: intratympanic corticosteroids

At that point, after using one or all of these therapeutic options, the authors confirm that 80% of patients are in remission of MD

symptoms, especially vertigo [20]. To manage conservatively the rest of the patients, intratympanic injection of steroids (ITS) is proposed as a second-line treatment. It is more and more popular [21]. Dexamethasone [22] is more used than methylprednisolone [23] (Level of proof 2 for both). Patel et al. recently reported that two injections of methylprednisolone (62.5 mg/mL) given 2 weeks apart was safe and as efficient as gentamicin (40 mg/mL) used with the same protocol to treat refractory MD. Most authors use daily injections of dexamethasone solution (4 mg/mL) for five consecutive days. For the authors, the use of one injection per week for 1 to 4 consecutive weeks is also efficient [24]. ITS significantly improves both frequency and severity of vertigo spells compared to placebo at 24 months after treatment (Level of proof 2). The authors recommend the use of ITS, whatever the drug, preferably with the protocol previously described to treat patients with MD in a non ablative manner (Grade B) since these drugs are not ototoxic [25] (Level of proof 1).

## 4. Third step: surgical conservative treatment

A literature review considering the studies published during the last decade confirms a decline of surgical treatment of MD in favor of intratympanic injections [20]. The most favored surgical technique remains endolymphatic sac surgery (ELSS). It represents for the authors one of the third-line treatments of MD, even if it has long been criticized and considered as a placebo surgery. Most critics referred on two placebo-controlled Danish studies analyzed in the Cochrane review in 2010 and 2013. Both studies concluded that ELSS has no evidence-based effect on natural course and vertigo of MD [26,27] (Level of proof 2). But a more recent meta-analysis came to the conclusion there was a low level of evidence in favor of an effect [28] (Level of proof 2). This controversy is due to the great difficulty to evaluate in a blinded way surgical treatments in MD, since the choice of a placebo or control reveals rather impossible. For most authors today, grommet insertion or mastoidectomy, respectively chosen in the Danish studies, cannot be considered as placebo treatments. Therefore the conclusion of these studies is not relevant. This is underlined in the Cochrane review. Even if solid proofs are lacking in the literature, the authors agree that it should be the first option after failure of the medical conservative treatment, if hearing function useful and MD in young subjects (Grade B). All the authors favour ELSS but the evolution of the practice is toward an increase number of ITS, especially in USA and in France, and a decrease number of ELSS surgeries.

## 5. Fourth step: medical destructive treatment of Ménière's disease

Intratympanic injection of gentamicin (ITG) is probably the most effective non-surgical treatment to eradicate vertigo in MD. But it is also an ablative method that carries a non-negligible risk of hearing loss [29] (Level of proof 2). Currently, ITG is favored in USA and most European countries. But it is about to change, as in France, Japan and Australia, ITS is preferred to ITG as a second-line treatment. Concerning ITG, no consensus has been reached so far on the dosage and treatment duration as Syed et al. has reported recently in a review of the literature [24]. The authors recommend using ITG as a destructive method preferentially when hearing function is impaired for patients with good contralateral vestibular function (Grade A). Based on Syed et al. meta-analysis, is advocated a "titration" protocol, ITG injections (40 mg/mL) being repeated until disappearance of vertigo spells. This "tailored" protocol is about to prevent hearing loss more than systematic weekly or monthly injection [24,30] (Level of proof 2 and 4). As a systematic genetic screening of MD patients is not currently done, hypersensitivity

## ICON algorithm for treatment of Ménière's disease

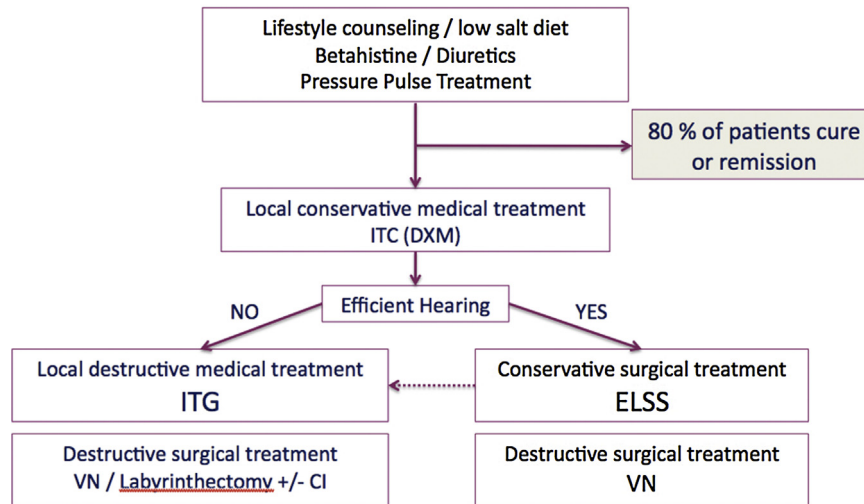


Fig. 1. Proposition of algorithm of treatment of Ménière's disease.

to the aminoglycosides in carriers of the mitochondrial mutation of the gene MTRNR1 is not screened. This mutation exposes to a complete and definitive deafness after a single injection of aminoglycosides [31]. ITG is now in transition between the third and the fourth line of treatment of the MD.

### 6. Fifth step: surgical destructive treatments

Evidence-based evaluations of totally ablative techniques, represented by surgical labyrinthectomy and vestibular neurectomy (VN) are scarce in the literature, compared to that of ELSS. No randomized controlled trials are available in the literature. Nevertheless, studies recommend their use after medical treatment failure and report a very good efficacy to control vertigo in MD patients. VN reveals more efficient than ITG [32,33]. The authors recommend indicating VN in patients suffering of intractable vertigo crises not influenced by medical treatment associated with poor but serviceable hearing function for patients with good contralateral vestibular function (Grade B). There is a trend to replace ELSS by VN in patients that do not respond to ITG or suffer of drop-attack crises. Surgical labyrinthectomy is less and less performed, even if the efficacy is close to the VN, since it totally destroys the remaining hearing function, at the difference with VN [34]. Most authors recommend to associate cochlear implantation to surgical labyrinthectomy in order to rehabilitate hearing in the same time. This practice is more common in Australia and USA than in Europe or Japan. It is not allowed in France.

### 7. Treatment of bilateral form of Ménière's disease

Specific data concerning occurrence of bilateral MD are not available and reports are from 2 to 47%. Bilateralization occurs secondarily after several years [35]. Obviously, bilateral MD should be treated in a conservative way to avoid bilateral deafferentation or ablative treatments. This occurrence has to be anticipated at the time of treating the first ear, especially when there are some arguments to forecast that the contralateral ear is not spared. This is the reason why the conservative treatment has always to be used for the first line, bringing more and more teams to switch from ITG to steroids ITS. Concerning the surgical treatment, the best option, even if controversial, is the ELSS in case of bilateral MD.

### 8. Proposition of algorithm of MD treatment

The Fig. 1 represents a proposal of an algorithm of MD treatment as an international consensus obtains for the IFOS meeting 2017. The first line of treatment includes the medical conservative treatment. After this line of treatment 80% of patients with MD are cured or in remission. Then the second line is the IT injections, mainly ITS as a conservative treatment and ITG in case of failure and preferentially in patients with hearing impairment. After this second line, 90 to 95% of the patients are cured or in remission [36]. The third line is the surgical, conservative or destructive, treatment. If indicated, ELSS must be indicated before ITG.

### Disclosure of interest

The authors declare that they have no competing interest.

### References

- [1] Committee on hearing equilibrium guidelines for the diagnosis evaluation on therapy in Ménière's disease. *Otolaryngol Head Neck Surg* 1995;113:181–5.
- [2] Lopez-Escamez JA, Carey J, Chung WH, Goebel JA, et al. Diagnostic criteria for Ménière's disease. *J Vest Res* 2015;25:1–7.
- [3] Nevoux J, Franco-Vidal V, Bouccara D, Parietti-Winkler C, et al. Groupe de travail de la SFORL. Diagnostic and therapeutic strategy in Ménière's disease. Guidelines of the French Otorhinolaryngology-Head and Neck Surgery Society (SFORL). *Eur Ann Otorhinolaryngol Head Neck Dis* 2017;16:30222–8.
- [4] van Esch BF, van der Zaag-Loonen HJ, Bruintjes TD, van Benthem PP. Interventions for Ménière's disease: protocol for an umbrella systematic review and a network meta-analysis. *BMJ Open* 2016;6:e010269.
- [5] Holgers K-M, Finizia C. Health profile for patients with Ménière's disease. *Noise Health* 2001;4:71–80.
- [6] Nakayama M, Masuda A, Ando KB, Arima S, et al. A pilot study on the efficacy of continuous positive airway pressure on the manifestations of Ménière's disease in patients with concomitant obstructive sleep apnea syndrome. *J Clin Sleep Med* 2015;11:1101–7.
- [7] Luxford E, Berliner KI, Lee J, Luxford WM. Dietary modification as adjunct treatment in Ménière's disease: patients willingness and ability to comply. *Otol Neurotol* 2013;34:1438–43.
- [8] van Esch BF, van der Scheer-Horst ES, van der Zaag-Loonen HJ, Bruintjes TD, et al. The effect of vestibular rehabilitation in patients with Ménière's disease. *Otolaryngol Head Neck Surg* 2017;156:426–34.
- [9] McDonnell MN, Hillier SL. Vestibular rehabilitation for unilateral peripheral vestibular dysfunction. *Cochrane Database Syst Rev* 2015;1:CD005397.
- [10] Edelman S, Mahoney AE, Cremer PD. Cognitive behavior therapy for chronic subjective dizziness: a randomized, controlled trial. *Am J Otolaryngol* 2012;33:395–401.
- [11] Thirlwall AS, Kundu S. Diuretics for Ménière's disease or syndrome. *Cochrane Database Syst Rev* 2006;3:CD003599.

[12] Crowson MG, Patki A, Tucci DL. A systematic review of diuretics in the medical management of Ménière's disease. *Otolaryngol Head Neck Surg* 2016;154:824–34.

[13] James AL, Burton MJ. Betahistine for Ménière's disease or syndrome. *Cochrane Database Syst Rev* 2001;1:CD001873.

[14] Strupp M, Zwergal A, Feil K, Bremova T, Brandt T. Pharmacotherapy of vestibular and cerebellar disorders and downbeat nystagmus: translational and back-translational research. *Ann N Y Acad Sci* 2015;1343:27–36.

[15] Lezius F, Adrion C, Mansmann U, Jahn K, Strupp M. High-dosage Betahistine dihydrochloride between 288 and 480 mg/day in patients with severe Ménière's disease: a case series. *Eur Arch Otorhinolaryngol* 2011;268:1237–40.

[16] Albu S, Chirtes F, Trombitas V, Nagy A, Marceanu L, Babighian G, et al. Intratympanic dexamethasone versus high dosage of betahistine in the treatment of intractable unilateral Ménière disease. *Am J Otolaryngol* 2015;36:205–9.

[17] Adrion C, Fischer CS, Wagner J, Gürkov R, et al. Efficacy and safety of betahistine treatment in patients with Ménière's disease: primary results of a long term, multicentre, double blind, randomised, placebo controlled, dose defining trial (BEMED trial). *BMJ* 2016;352:h6816.

[18] Covelli E, Volpini L, Atturo F, Benincasa AT, et al. Delayed effect of active pressure treatment on endolymphatic hydrops. *Audiol Neurootol* 2017;22(1):24–9.

[19] van Sonsbeek S, Pullens B, van Benthem PP. Positive pressure therapy for Ménière's disease or syndrome. *Cochrane Database Syst Rev* 2015;3:CD008419.

[20] Claes J, Van de Heyning PH. A review of medical treatment for Ménière's disease. *Acta Otolaryngol Suppl* 2000;544:34–9.

[21] Syed MI, Iian O, Leong AC, Pothier DD, et al. Ménière's syndrome or disease: tie trends in management and quality of evidence over the last two decades. *Otol Neurotol* 2015;36:1309–16.

[22] Garduno-Anaya MA, Couthino De Toledo H, Hinojosa-Gonzalez R, Pane-Pianese C, et al. Dexamethasone inner ear perfusion by intratympanic injection in unilateral Ménière's disease: a two-year prospective, placebo-controlled, double-blind, randomized trial. *Otolaryngol Head Neck Surg* 2005;133:285–94.

[23] Patel M, Agarwal K, Arshad Q, Hariri M, et al. Intratympanic methylprednisolone versus gentamicin in patients with unilateral Ménière's disease: a randomised, double-blind, comparative effectiveness trial. *Lancet* 2016;388:2753–62.

[24] Philips JS, Westerberg B. Intratympanic steroids for Ménière's disease or syndrome. *Cochrane Database Syst Rev* 2011;7:CD008514.

[25] Syed MI, Iilan O, Nassar J, Rutka JA. Intratympanic therapy in Ménière's syndrome or disease: up to date evidence for clinical practice. *Clin Otolaryngol* 2015;40:682–90.

[26] Pullens B, Giard JL, Verschuur HP, van Benthem PP. Surgery for Ménière's disease. *Cochrane Database Syst Rev* 2010;1:CD005395.

[27] Pullens B, Verschuur HP, van Benthem PP. Surgery for Ménière's disease. *Cochrane Database Syst Rev* 2013;2:CD005395.

[28] Lim MY, Zhang M, Yuen HW, Leong JL. Current evidence for endolymphatic sac surgery in the treatment of Ménière's disease: a systematic review. *Singapore Med J* 2015;56:593–8.

[29] Pullens B, van Benthem PP. Intratympanic gentamicin for Ménière's disease or syndrome. *Cochrane Database Syst Rev* 2011;3:CD008234.

[30] Quagliari S, Gatti O, Rebecchi E, Manfrin M, et al. Intratympanic gentamicin treatment "as needed" for Ménière's disease. Long-term analysis using the Kaplan-Meier method. *Eur Arch Otorhinolaryngol* 2014;271:1443–9.

[31] Prezant TR, Agopian JV, Bohlman MC, Bu X, et al. Mitochondrial ribosomal RNA mutation associated with both antibiotic-induced and non-syndromic deafness. *Nat Genet* 1993;4:289–94.

[32] Silverstein H, Wanamaker H, Flanzer J, Rosenberg S. Vestibular neurectomy in the United States 1990. *Am J Otol* 1992;13:23–30.

[33] Morel N, Dumas G, Nguyen DQ, Mohr E, et al. Vestibular neurotomy versus chemical labyrinthectomy for disabling Ménière disease. *Ann Otolaryngol Chir Cervicofac* 2005;122:271–80.

[34] De La Cruz A, Borne Teufert K, Berliner K. Transmastoid labyrinthectomy versus translabyrinthine vestibular nerve section: does cutting the vestibular nerve make a difference in outcome? *Otol Neurotol* 2007;28:801–8.

[35] House JW, Doherty JK, Fisher LM, Derebery MJ, et al. Ménière's disease: prevalence of contralateral ear involvement. *Otol Neurotol* 2006;27:355–61.

[36] Espinosa-Sanchez JM, Lopez-Escamez JA. Ménière's disease. *Handb Clin Neuro* 2016;137:257–77.