

**SUPERFICIAL VENOUS PATTERNS OF THE CUBITAL  
FOSSA AMONG VOLUNTEERS FROM HOSPITAL KUALA  
LUMPUR**

**BY**

**DR.SARAVANAN A/L RAMASAMY**

Dissertation Submitted In Partial Fulfilment of  
The Requirement for  
The Degree of Master of Medicine  
(General Surgery)



**UNIVERSITI SAINS MALAYSIA**

**2012**

# I. ACKNOWLEDGEMENTS

I am grateful to the God for giving me the opportunity and strength to complete this study.

My utmost gratitude goes to Mr.Kumaraguru VK Pillay for giving me advises and tireless guidance in which has inspired me to carry out this dissertation to its completion. I would like to express my gratitude to my co-supervisors, Mr.Mehboob Alam Pasha, Mr.Naresh and Mr. Saravana Kumar for the efficient way for further guiding me along the process of finishing this research. My sincere appreciation to Mr.Zainal Ariffin Azizi , Head of Department of Vascular and General Surgery , Hospital Kuala Lumpur (HKL) and Mr.Mohd Nor Gohar ,head of Department of Surgery ,University Sains Malaysia (USM) for continuous support and encouragement.

Furthermore, I am also thankful to my statistician, Puan Anis Kausar Ghazali for helping me when required. I hope that this study will evince greater interest among the readers for further clarification of the patterns of superficial veins at cubital fossa among Malaysians. Moreover, I am also indebted to all my teachers, colleagues and the staffs of Surgical Department from USM and HKL, for rendering generous support and willing assistance in contributing to this study.

Nevertheless, after saying all this, certainly I am thankful to my parents and my sister Sangeetha and brother-inlaw Kumar and not forgetting the rest of my family for their fullest love and unconditional support, understanding and co-operation throughout my postgraduate study.

Finally, I am thankful to all my volunteers for giving me their trusts and opportunity to conclude them in this work. In spite of that, I would like to dedicate this study to my entire teachers and volunteers. I hope this study will benefit the patients in future.

## II. TABLE OF CONTENT

I ACKNOWLEDGEMENTS .....	ii
II TABLE OF CONTENT.....	iii
III LIST OF FIGURES.....	vii
IV LIST OF TABLES.....	ix
V LIST OF ABBREVIATIONS.....	x
VI ABSTRAK.....	xi
VII ABSTRACT.....	xiv
CHAPTER 1 .....	1
INTRODUCTION .....	1
1. Background of Studies.....	1
1.1 Anatomy of Cubital Fossa.....	3
1.1.1 Boundaries of Cubital Fossa:.....	3
1.1.2 Content of Cubital Fossa .....	4
1.1.3 Superficial Content of Cubital Fossa.....	5
1.2 Anatomy and Physiology of Veins.....	6
1.3 Anatomy of Superficial Veins of Upper limb .....	7
1.4 Functions of Superficial Veins of Cubital Fossa.....	12
1.5 Patterns of superficial veins of Cubital Fossa.....	16

1.6 Duplex Ultrasound in Vascular Access .....	18
1.6.1 Duplex Ultrasound.....	18
1.6.2 Ultrasound in Vascular Access Planning.....	20
CHAPTER 2 .....	22
LITERATURE REVIEW .....	22
2.1 Overview.....	22
2.2 Superficial Venous Patterns at Cubital Fossa.....	22
CHAPTER 3.....	36
OBJECTIVES OF STUDY .....	36
3.1 Title of Study .....	36
3.2 General Objective .....	36
3.3 Specific Objective.....	36
3.4 Research Questions.....	37
CHAPTER 4 .....	38
METHODOLOGY .....	38
4.1 Research Strategy .....	38
4.2 Study Design.....	38
4.3 Reference Population and Source Population.....	38
4.4 Study Period and Place.....	38
4.5 Study Participants.....	39
4.5.1 Inclusion Criteria.....	39

4.5.2 Exclusion Criteria.....	39
4.6 Sample Size.....	39
4.6.1 Sample Size Calculation.....	40
4.7 Method of Sampling.....	41
4.8 Data Collection and Research Tool.....	41
4.9 Ethical Issues.....	42
4.10 Statistical Analysis.....	42
4.11 Study Variables.....	42
4.12 Flow Chart.....	44
CHAPTER 5.....	45
RESULTS .....	45
5.1 Analysis of Study.....	45
5.2 Sample Profile.....	45
5.3 Age Distribution.....	45
5.4 Gender Distribution.....	47
5.5 Ethnicities.....	48
5.6 Patterns of Superficial Veins of Cubital Fossa in Different Gender.....	48
5.7 Patterns of Superficial Veins of Cubital Fossa in Different Ethnicities.....	53
5.8 Combinations of Superficial Veins on both Cubital Fossa.....	57

CHAPTER 6.....	60
DISCUSSION.....	60
6 Background.....	60
6.1 Recapitulation of the Study.....	60
6.2 Discussion.....	60
CHAPTER 7 .....	65
CONCLUSION.....	65
7.1 Summary.....	65
7.2 Conclusion.....	65
CHAPTER 8.....	66
LIMITATIONS AND RECOMMENDATIONS.....	66
8.1 Limitations.....	66
8.2 Recommendations.....	66
REFERENCES .....	67
Appendix A.....	71
Appendix B.....	72
Appendix C.....	79
Appendix D.....	85

### III. LIST OF FIGURES

Figure 1.1: Surface anatomy of cubital fossa.....	3
Figure 1.2: Boundaries of cubital fossa.....	4
Figure 1.3: Contents of cubital fossa.....	5
Figure 1.4: Superficial content of cubital fossa.....	6
Figure 1.5: Superficial veins of the hand.....	9
Figure 1.6: Anatomy of superficial veins in the upper limb.....	11
Figure 1.7: Functions of superficial veins of cubital fossa.....	12
Figure 1.8: Cephalic vein used for forearm flap.....	15
Figure 1.9: Median cubital vein runs upward from cephalic to basilic vein .....	17
Figure 1.10: Median antebrachial vein joins the median cubital vein.....	17
Figure 1.11: Median antebrachial vein diverge to join the cephalic and basilic veins .....	17
Figure 1.12: Median antebrachial vein joins the basilic vein.....	18
Figure 1.13: Sagittal view of cephalic vein on duplex ultrasound.....	19
Figure 1.14: Duplex ultrasound used in venous mapping.....	21
Figure 2.1: Classical patterns of superficial vens of cubital fossa.....	23
Figure 2.2: Superficial venous patterns of cubital fossa in Indians.....	26
Figure 2.3: Patterns of superficial veins of cubital fossa in Nigerian.....	27

Figure 2.4: Patterns of superficial veins of cubital fossa in Iraqis.....	29
Figure 2.5: Patterns of superficial veins of cubital fossa in Colombian people.....	31
Figure 2.6: Superficial venous patterns in Mapuche ethnic group from Chile.....	33
Figure 2.7: Superficial venous patterns of cubital fossa in Malays.....	35
Figure 4.1: Duplex ultrasound machine in the vascular lab HKL.....	41
Figure 4.2: Types of anastomosis of superficial veins of cubital fossa.....	43
Figure 5.1: Age distribution.....	46
Figure 5.2: Superficial venous patterns of right cubital fossa in different gender.....	50
Figure 5.3: Superficial venous patterns of left cubital fossa in different gender.....	52
Figure 5.4: Patterns on the right cubital fossa among major ethnicities.....	54
Figure 5.5: Patterns on the right cubital fossa among major ethnicities.....	56
Figure 5.6: Combinations of anastomosis of both cubital fossa in Malays.....	58
Figure 5.7: Combinations of anastomosis of both cubital fossa in Chinese.....	58
Figure 5.8: Combinations of anastomosis of both cubital fossa in Indians.....	59



## V. LIST OF TABLES

Table 2.1: Comparison of the percentage incidences of the three basic types of venous patterns in the cubital region.....	24
Table 2.2: Superficial venous patterns in Colombian people.....	30
Table 2.3: Superficial venous patterns in right and left cubital fossa of Columbians..	31
Table 5.1: Mean of age.....	47
Table 5.2: Gender distribution among subjects.....	47
Table 5.3: Volunteers distribution among different ethnicities.....	48
Table 5.4: Patterns of superficial veins of right cubital fossa in different gender.....	49
Table 5.5: Patterns of superficial veins of left cubital fossa in different gender.....	51
Table 5.6: Patterns of superficial veins of right cubital fossa among different ethnicities.....	53
Table 5.7: Patterns of superficial veins of left cubital fossa among different ethnicities.....	55
Table 5.8: Combinations of superficial veins anastomosis on the right and left cubital fossa in different ethnicities.....	57

## **VI. LIST OF ABBREVIATIONS**

AC	Antecubital
AVF	Arteriovenous fistula
BV	Basilic vein
CF	Cubital fossa
CRF	Chronic renal failure
CV	Cephalic vein
CVPF	Cephalic Vein Pedicle Flap
DUS	Duplex Ultrasound
HKL	Hospital Kuala Lumpur
HUSM	Hospital University Sains Malaysia
IV	Intravenous
MAV	Median antebrachial vein
MCV	Median Cubital Vein
PICC	Peripherally Inserted Central Catheters
RAFFF	Radial Artery Forearm Free Flap
SVP	Superficial venous patterns

## **VII. ABSTRAK**

### **Pengenalan:**

Fosa kubital ('cubital fossa') adalah ruang yang terletak di hadapan siku yang mengandungi salur darah dan saraf yang penting di lengan. Salur darah vena luaran di fosa kubital biasanya digunakan untuk pengambilan darah, transfusi darah dan pemberian suntikan ubatan lebih-lebih lagi pada masa kecemasan. Ia juga dapat membantu dalam penyediaan untuk pembedahan fistula ('arteriovenous fistula') di mana salur darah vena dan arteri disambung untuk digunakan dalam dialisis. Ia juga penting di dalam pembedahan penampalan tisu di lengan ('forearm flaps'). Corak pengaliran salur darah vena luaran di fosa kubital berbeza di antara kaum dan ini telah diterjemahkan di dalam beberapa kajian yang dijalankan sebelum ini. Oleh sebab tu, saya memutuskan untuk membuat kajian mengenai salur darah vena luaran di antara pelbagai kaum di Malaysia dan berharap kajian saya dapat membantu memahami corak pengaliran salur darah vena luaran dan aplikasinya dalam bidang perubatan.

### **Objektif:**

Kajian ini bertujuan untuk menghuraikan corak pengaliran salur darah vena luaran di fosa kubital kedua-dua belah lengan di kalangan sukarelawan dari Hospital Kuala Lumpur yang terdiri daripada kaum Melayu, Cina dan India.

### **Metodologi dan reka bentuk kajian**

Kajian ini adalah satu analisis keratan rentas yang melibatkan tiga ratus sukarelawan dari Hospital Kuala Lumpur yang terdiri daripada tiga kaum utama di Malaysia iaitu Melayu, Cina dan India. Para sukarelawan yang berumur lapan belas tahun dan keatas telah dipilih dan corak salur darah vena di kubital fosa telah diperiksa menggunakan ultrasound dupleks

(‘duplex ultrasound’) dari makmal vaskular Hospital Kuala Lumpur. Saya sendiri telah melakukan ultrasound duplex dengan dibantu oleh penyelia saya. Corak tersebut dilukis diatas borang kaji selidik yang disediakan.

## **Keputusan**

Berdasarkan kajian yang dibuat corak salur darah vena jenis satu (type 1) dimana salur darah kefalik (cephalic vein) akan memberi satu cabang salur darah vena kubital median (median cubital vein) ke salur darah vena basilik ( basilic vein) merupakan corak yang paling tinggi di kalangan perempuan dan lelaki dimana 33.3% dan 34.0% di lengan kanan dan 32.0% dan 34.0% di lengan kiri masing-masing. Corak jenis satu (type 1) juga merupakan corak yang paling banyak dilihat di kalangan sukarelawan Melayu dan India. Sukarelawan Melayu mempunyai 40.0% di lengan kanan 37.0% di lengan kiri. Sukarelawan India pula mempunyai 36.0% di lengan kanan dan 41.0% di lengan kiri. Manakala sukarelawan Cina mempunyai corak jenis tiga (type 3) iaitu salur darah vena kubital median memberi dua cabang ke salur darah vena kefalik dan basilik masing-masing. Ia dilihat 38.0% di lengan kanan dan 40.0% di lengan kiri. Kombinasi salur darah vena jenis bercampur adalah paling banyak dilihat di kedua-dua fosa kubital di kalangan Melayu, Cina dan India. Corak salur darah vena luaran tidak mempunyai perbezaan yang signifikan di antara perempuan dan lelaki tetapi mempunyai perbezaan signifikan di antara kaum .

## **Kesimpulan**

Salur darah vena luaran di fosa kubital adalah penting dari segi klinikal. Pengetahuan mengenai corak salur darah vena di kalangan perempuan dan lelaki, juga di kalangan tiga etnik utama dan kombinasi corak di lengan kanan dan kiri akan membantu dalam prosedur-

prosedur klinikal. Ultrasound dupleks juga telah memberi peluang yang baik untuk kita mengetahui anatomi salur darah vena luaran di fosa kubital dengan lebih terperinci lagi.

*Kata kunci:* fosa kubital, salur darah vena luaran, ultrasound duplex

## **VII. ABSTRACT**

### **Introduction**

Cubital fossa is a space in anterior to the elbow which contains important vessels and nerves in the arm. Superficial veins of cubital fossa are commonly used for blood sampling, transfusions and for intravenous injections often under conditions of emergency. These veins are useful in arteriovenous fistula creation for hemodialysis. Besides that, they are used for creation of forearm flaps in plastic surgery. The arrangement of the superficial veins in the cubital fossa however is subjected to considerable variation. Different patterns of superficial cubital veins and their percentages of occurrence have been reported in various races. This prospective study among Malaysians from three races (Malays, Chinese and Indians) was planned since the superficial veins in the cubital fossa are important clinically and their arrangements are subject to racial variation.

### **Objectives**

The aim of the study is to observe and describe the distribution of anatomical variations of the superficial veins of the cubital fossa among Malay, Chinese and Indian volunteers from Hospital Kuala Lumpur.

### **Methodology and Study Design**

The study is designed as a descriptive cross-sectional survey involving a simple examination of the superficial veins of cubital fossa among volunteers from Hospital Kuala Lumpur. My sample is composed of three hundred volunteers from three major ethnicities Malays, Chinese and Indians aged from eighteen and above. I, myself performed the duplex

ultrasound assessment with the guidance from my supervisors in the vascular unit HKL. The patterns of the veins were drawn onto a survey form.

## **Results**

Based on my analysis, the commonest type of anastomosis seen was type 1 in both genders with female having 33.3% and male having 34.0% on the right cubital fossa and 32.0% in female and 34.0% in male on the left cubital fossa. Type 1 was the commonest among Malays and Indians. It was 40.0% and 37.0% of right and left cubital fossa in Malays. Indians meanwhile had 36.0% and 41.0% on the right and left cubital fossa. While in Chinese type 3 of anastomosis observed the most. It was 38.0% and 40.0% on right and left cubital fossa. The mixed type combination on both right and left cubital fossa was the highest prevalence in all 3 major ethnicities. There was no significant difference between gender and patterns but there was a significant difference in between ethnicities and patterns of cubital fossa.

## **Conclusion**

Superficial veins of cubital fossa have their clinical importance. The understanding of patterns in genders, ethnicities and combination patterns of both cubital fossas will assist in clinical procedures. Duplex ultrasound has provided a great understanding of the anatomy of superficial veins of cubital fossa.

*Key words:* cubital fossa, superficial veins, duplex ultrasound

Biodata Abstrak Penyelidikan.

SUPERFICIAL VENOUS PATTERNS OF THE CUBITAL FOSSA AMONG VOLUNTEERS  
FROM HOSPITAL KUALA LUMPUR

Dr. Saravanan A/L Ramasamy

MMed Surgery

Department of Surgery,  
School of Medical sciences,Universiti Sains Malaysia,  
Health Campus, 16150 Kelantan, Malaysia.

## **Introduction**

Superficial veins of cubital fossa are commonly used for blood sampling, transfusions and for intravenous injections often under conditions of emergency. Cubital veins are also used for the introduction of cardiac catheters to obtain blood samples from cardiac chambers and for cardioangiography.

The arrangement of the superficial veins in the cubital fossa however is subject to considerable variation. Different patterns of superficial cubital veins and their percentages of occurrence have been reported in various races. This prospective study among Malaysians from three races (Malay, Chinese and Indians) was planned since the superficial veins in the cubital fossa are important clinically and their arrangements is subject to racial variation.



## **Objectives**

The aim of the study is to observe and describe the distribution of anatomical variations of the superficial veins of the cubital fossa among Malay, Chinese and Indian volunteers from Hospital Kuala Lumpur.

## **Methodology and Study Design**

The study is designed as a descriptive cross-sectional survey involving a simple examination of the superficial veins of cubital fossa among volunteers from Hospital Kuala Lumpur. My sample is composed of 300 volunteers from 3 major ethnicities Malay, Chinese and Indians aged from 18 and above. Ultrasound assessment of venous patterns has been performed by a single researcher (myself) in the vascular unit HKL. The pattern of the veins has been drawn onto a survey form.

## **Results**

Based on our analysis, the commonest type of anastomosis seen is H type with 52.2% on the right cubital fossa and 50.6% on the left cubital fossa. Type 2 of anastomosis observed is 25% on the right and 20.6% on the left cubital fossa. No anastomosis was observed in 22.8% and 28.9% on the right and left cubital fossa respectively .

## **Conclusion**

In our study of variation of anastomosis of superficial veins of upper limb, we found that the majority of our subjects, from 50.6% to 52.2% have H type of anastomosis on both left and right cubital fossa respectively, followed by type 2 of anastomosis from 20.6% to 25.0% on both left and right cubital fossa respectively. No anastomosis was found in 22.8% to 28.9% on right and left cubital fossa respectively.

Dr kumaraguru V.K Pillay (Supervisor)

Dr Saravana Kumar Selvanathan (Co-Supervisor)

Dr.Mehboob Alam Pasha (Co-Supervisor)

# CHAPTER 1

## INTRODUCTION

### 1 Background of Studies

Anatomically venous drainage of the upper limb can be classified into superficial and deep vein systems. Superficial and deep venous system separated by the superficial fascia of arm. Superficial compartment of the upper limb contain the superficial veins of the upper limb. Cephalic vein and basilic vein are the main superficial veins. The cephalic vein lies on the lateral side of biceps brachii and drains into axillary vein. The basilic vein lies on the medial side of biceps brachii, drains into axillary vein together with venae comitantes in the deep fascia. There are some variations of the superficial veins in the cubital fossa (Snell, 2012).

The pattern of anastomosis of superficial veins in the cubital fossa is extremely variable. The main variations of superficial veins depend on presence of median cubital vein and median antebrachial vein and their type of anastomosis (Basmajian *et al.*, 1971). It has been described that in a small percentage there may be no anastomosis. Besides the pattern in different ethnics and gender, the combinations of anastomosis of superficial veins on both right and left cubital fossa observed in the same person in this study.

Venepuncture of superficial veins used for blood collection and blood transfusion. Blood taken used for blood donation, health screening and testing. Besides that,

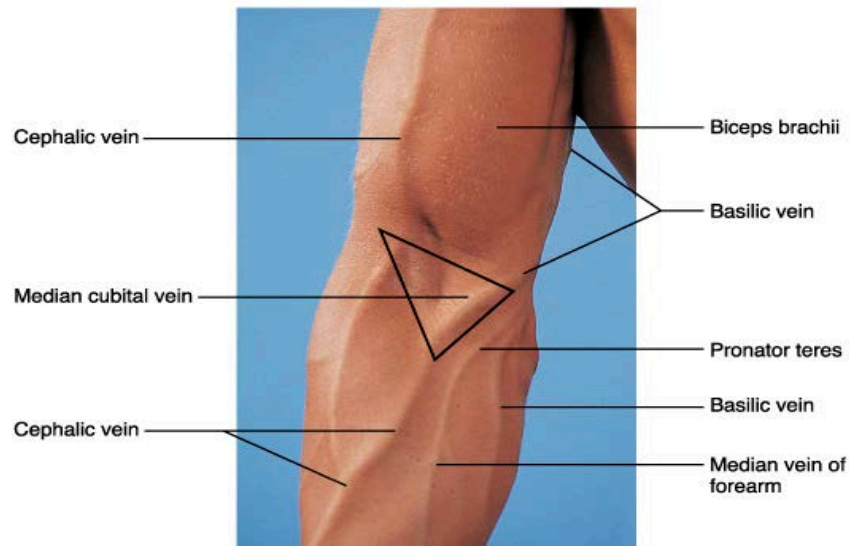
intravenous blood transfusion and intravenous medications can be given via superficial veins especially during the emergency treatment of hypovolemic shock. Central venous catheters usually get inserted mainly into median basilic vein or basilic vein. The basilic vein and cephalic vein can be used for arteriovenous fistula creation (brachio-basilic or brachio-cephalic fistula) for the purpose of hemodialysis. The arteriovenous fistula between superficial veins and brachial artery is recommended conduit bypass of the upper limb to increase the diameter and strengthen the venous wall, in another word “arterializing the vein’ (Dagher *et al.*, 1976).

There is much clinical relevance associated with the superficial veins of the cubital fossa but very limited literature is found on the anatomical variations of superficial veins of the upper limb especially among the Malaysian population. Thus, this study attempts to examine and describe the pattern of the superficial veins of both cubital fossa among volunteers from major ethnics in Malaysia.

The patterns of the superficial veins at the cubital fossa can be looked into by various methods. The first method is by using a blood pressure cuff or tourniquet which applied at the upper arm to distend the veins. Dissecting cadavers at autopsy and observing the pattern of the superficial veins of upper limb will be the second method. These two techniques had been used in previous studies. The third method is by using a duplex ultrasound. Since conducting this research project in a short period of time and without access to the required number of cadavers to dissect, I have chosen this method. The evaluation of the anatomy using a duplex ultrasound (DUS) probe is an extremely useful technique to map the peripheral arteries and veins (Beathard, 2001).

## 1.1 Anatomy of Cubital Fossa

Antecubital fossa is a space anterior to the elbow through which the principal vascular and nervous trunks pass into the forearm (Miyasaka, 1999).

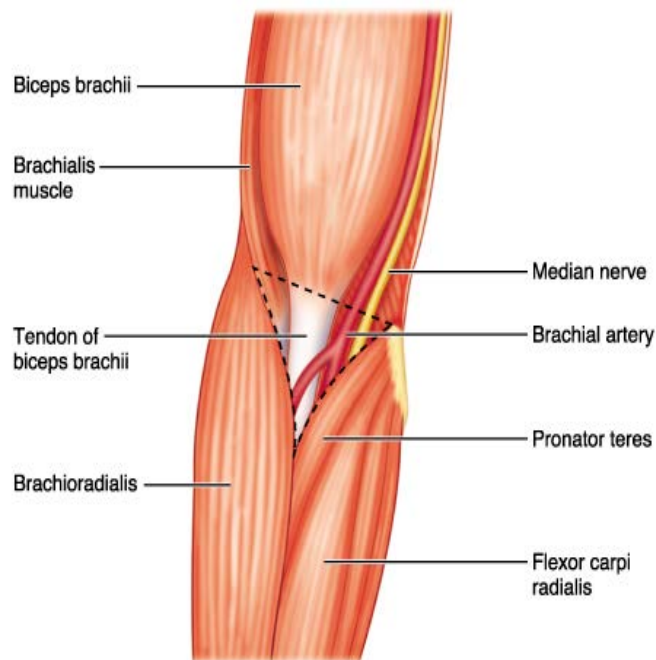


**Figure 1.1 Surface anatomy of cubital fossa (adapted from [dentistryandmedicine.blogspot.com](http://dentistryandmedicine.blogspot.com))**

### 1.1.1 Boundaries of Cubital Fossa:

- superior (proximal) boundary — an imaginary horizontal line connecting the medial epicondyle of the humerus to the lateral epicondyle of the humerus
- Medial (ulnar) boundary — lateral border of pronator teres muscle originating from the medial epicondyle of the humerus.
- Lateral (radial) boundary — medial border of brachioradialis muscle originating from the lateral supraepicondylar ridge of the humerus.

- Apex — it is directed inferiorly, and is formed by the meeting point of the lateral and medial boundaries.
- Superficial boundary (roof) — skin, superficial fascia containing the median cubital vein, cephalic vein and basilica vein, the lateral cutaneous nerve of the forearm and the medial cutaneous nerve of the forearm, deep fascia reinforced by the bicipital aponeurosis (a sheet of tendon-like material that arises from the tendon of the biceps brachii)
- Deep boundary (floor) – brachialis and supinator muscles



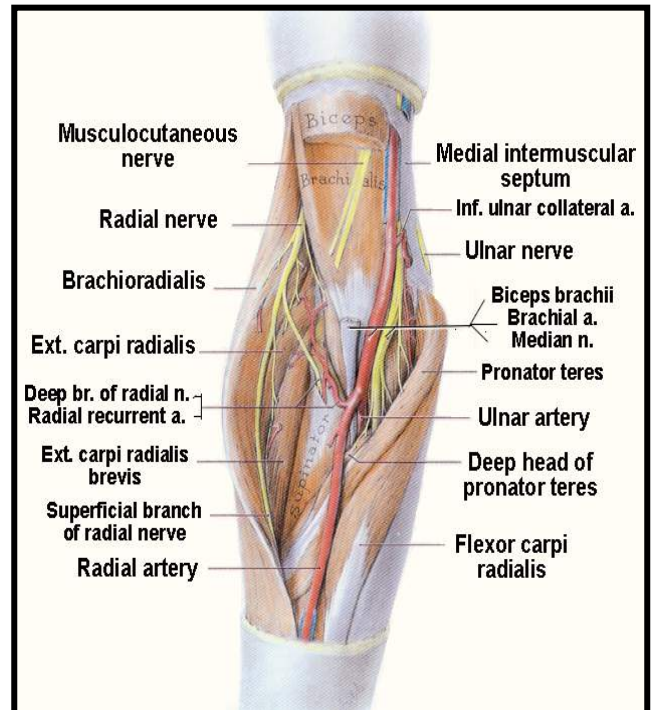
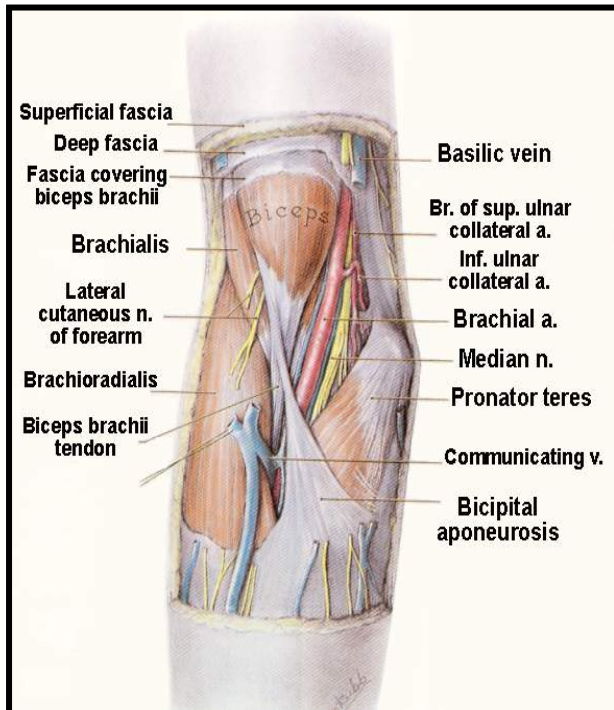
**Figure 1.2 Contents of cubital fossa**

### 1.1.2 Content of Cubital Fossa

The contents of the fossa from medial to lateral deep to superficial fascia are:

- Median nerve
- Brachial artery and its terminal branches, the radial and ulnar arteries

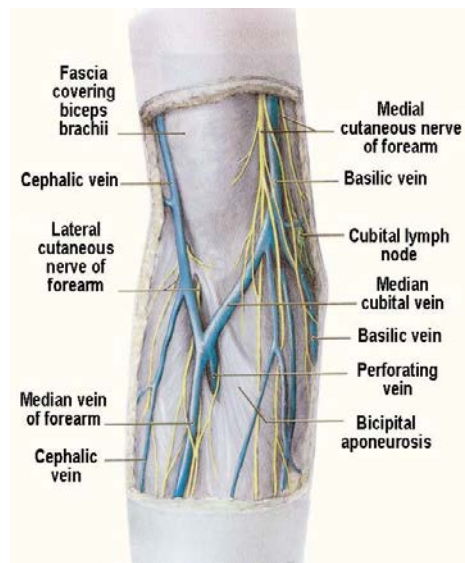
- Biceps tendon and bicipital aponeurosis (which separates the median cubital vein from the brachial artery)
- Radial and posterior interosseous nerves,



**Fig 1.3 Contents of cubital fossa**

### 1.1.3 Superficial Content of Cubital Fossa

There is a superficial fascia separating deep and superficial contents. The anterior branches of the medial and lateral cutaneous nerves of the forearm and the median cubital vein, which joins the cephalic and basilic veins lies on the roof of superficial fascia (Drake *et al.*, 2005) .



**Fig 1.4 Superficial content of cubital fossa**

## 1.2 Anatomy and Physiology of Veins

Veins contain 3 layers like arteries:

**Intima:** A thin layer of elastic tissue surrounds the endothelium. To promote the smooth laminar flows of blood, the endothelial cells are made flat.

**Media:** Composed of smooth muscle cells and elastic fibers. This layer is thinner than an artery. There is less muscle in the media which means it is much more easily distended or collapsed by pressure.

**Adventitia:** A tough fibrous layer. It merges in with the surrounding connective tissue and protects the vein.



There are three distinct sets of veins; the systemic, pulmonary and portal. The systemic veins receive the venous blood from the body and carry it to the heart. The pulmonary veins, unlike other veins, contain arterial blood, which they return from the lungs to the left atrium of the heart. Portal vein drains blood from the gastrointestinal tract between the gastro-oesophageal junction and the recto-anal junction and carries it to the liver (Moore and Dalley, 1999).

The systemic veins are subdivided into three sets; superficial, deep and venous sinuses (Marieb and Hoehn, 2007). The superficial veins (cutaneous veins) that I'm focusing in this study are found between the skin and layer of the superficial fascia. They return the blood from the body and communicate with the deep veins by perforating the deep fascia.

The deep veins usually accompany the arteries and are enclosed in the same sheaths with those vessels. The smaller arteries such as the radial, ulna, brachial, tibial and peroneal have veins generally in pairs, one lying on each side of the artery, and are called *venae comitantes*. The larger arteries such as the axillary, subclavian, popliteal, and femoral have usually only one accompanying vein.

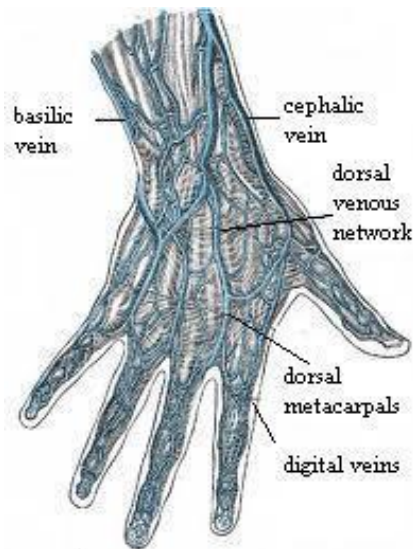
Venous Sinuses are found only in the interior of the skull, and consist of canals formed by a separation of the two layers of the dura mater; their outer coat consists of fibrous tissue and their inner composed of an endothelial layer continuous with the lining membrane of the veins.

### **1.3 Anatomy of Superficial Veins of Upper limb**

The veins of the upper limb are divided into two sets, superficial and deep (Scales, 2008). The two sets frequently anastomose with each other. The superficial veins lie above

superficial fascia while the deep veins lie below it. The deep veins accompany the arteries, and constitute the *venae comitantes* of those vessels. Both sets are provided with valves, which are more numerous in the deep than in the superficial veins.

The superficial veins of the upper extremity are the digital, metacarpal, cephalic, basilica and median cubital vein (Hallock, 2005). The dorsal digital veins which pass along the sides of the fingers are joined to one another by oblique communicating branches. Those digital veins from the adjacent sides of the fingers unite to form three dorsal metacarpal veins which end in a dorsal venous network opposite the middle of the metacarpus. The radial part of the network is joined by the dorsal digital vein from the radial side of the index finger and by the dorsal digital veins of the thumb, and is prolonged upward as the cephalic vein. The ulnar part of the network receives the dorsal digital vein of the ulnar side of the little finger and is continued upward as the basilic vein. A communicating branch frequently connects the dorsal venous network with the cephalic vein about the middle of the forearm. The volar digital veins on each finger are connected to the dorsal digital veins by oblique intercapitular veins. They drain into a venous plexus which is situated over the thenar and hypothenar eminences and across the front of the wrist (Moss *et al.*, 1985). Those digital veins from the adjacent sides of the fingers unite to form three dorsal metacarpal veins which end in a dorsal venous network opposite the middle of the metacarpus.

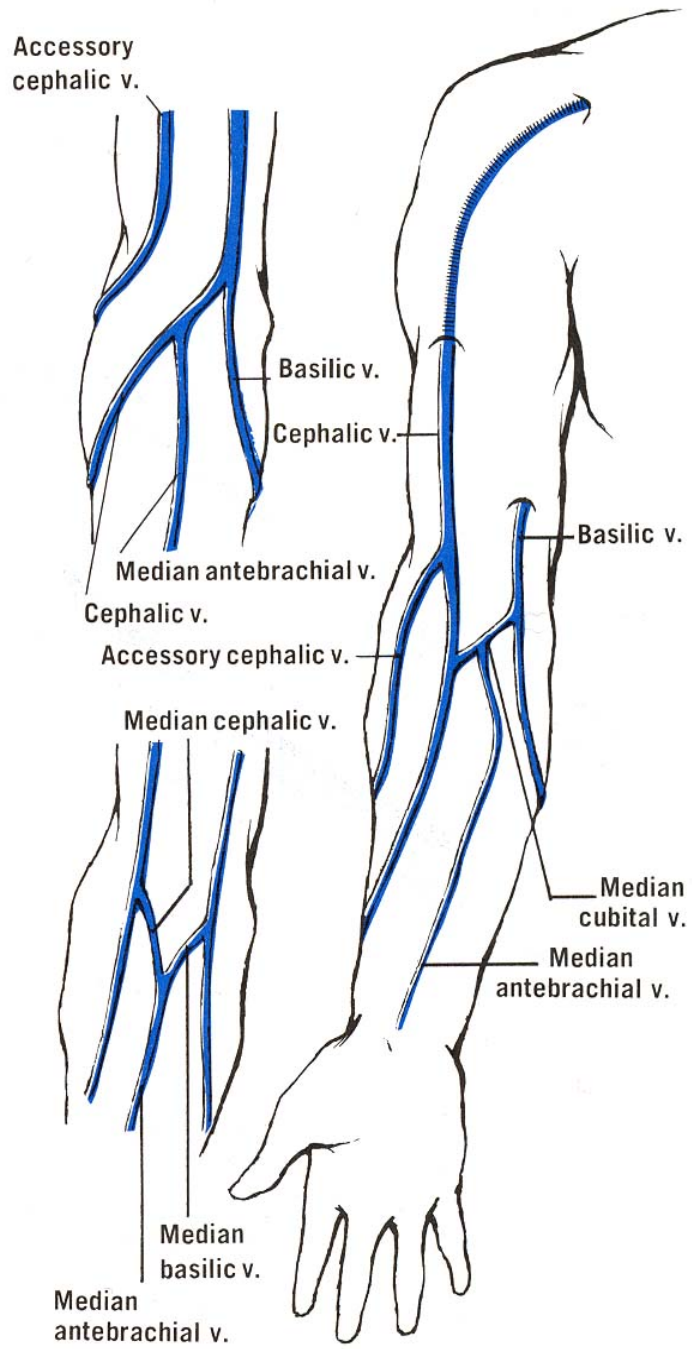


**Fig 1.5 Superficial veins of the hand**

From the dorsal venous network, the cephalic vein begins in the radial part and winds upward around the radial border of the forearm, receiving tributaries from both surfaces (Mozes and gloviczki, 2006) . Below the front of the elbow, it gives off the median cubital vein which receives a communicating branch from the deep veins of the forearm and passes across to join the basilic vein. In front of the elbow, the cephalic vein then ascends in the groove between the brachioradialis and the biceps brachii. It crosses superficial to the musculocutaneous nerve and ascends in the groove along the lateral border of the biceps brachii. It passes between the pectoralis major and deltoid (deltopectoral groove) in the upper third of the arm, where it is accompanied by the deltoid branch of the thoracoacromial artery. It pierces the clavipectoral fascia and, crossing the axillary artery, empties into third portion of the axillary vein just below the clavicle. Sometimes it communicates with the external jugular vein by a branch which ascends in front of the clavicle.

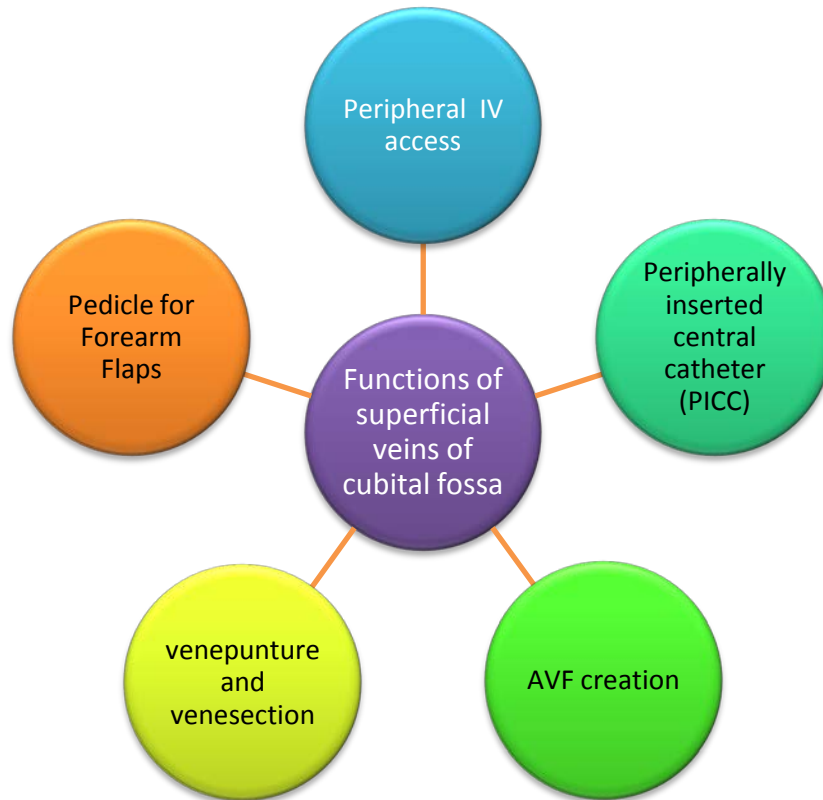
The basilic vein originates in the ulnar part of the dorsal venous network. It travels up the posterior surface of the ulnar side of the forearm and inclines forward to the anterior surface below the elbow, where it is joined by the median cubital vein. It ascends obliquely in the groove between the biceps brachii and pronator teres and crosses the brachial artery. It then runs upward along the medial border of the biceps brachii, perforates the deep fascia a little below the middle of the arm, and, ascending on the medial side of the brachial artery to the lower border of the teres major and joined by brachial veins to form the axillary vein (Richard *et al.*, 1992).

The median antibrachial vein drains the venous plexus on the palmar surface of the hand. It ascends on the ulnar side of the front of the forearm and ends in the basilic vein or in the median cubital vein. In a small proportion of cases, it divides into two branches, one of which joins the basilic, the other the cephalic, below the elbow to form median basilic vein and median cephalic vein respectively distal to the cubital fossa. The median antebrachial vein also has interconnections with the deep veins of the forearm.



**Fig. 1.6 Anatomy of superficial veins in the upper limb**

## 1.4 Functions of Superficial Veins of Cubital Fossa



**Figure 1.7: Function of superficial veins of cubital fossa**

Peripheral intravenous (IV) catheters permit for the safe infusion of medications, hydration fluids, blood products, and nutritional supplements. It can be a challenge even to experienced doctors to obtain peripheral IV access especially in infants, obese adults, intravenous drug abusers, edematous patients or patients who are frequently hospitalized. The problem may be due to thrombosis or scarring of normally visible veins in the hand and forearm or difficulty in palpation or visualization of veins as a result of subcutaneous fat or edema. Keyes and colleagues (Keyes *et al.*, 1999) used ultrasonography of the cubital fossa to catheterize the cephalic or basilic veins using a transverse image of these vessels (Sandhu and Sidhu, 2004).

These veins are often thrombosed in drug abusers, as the antecubital fossa is one of the most frequently used injection sites by the drug abusers. It offers an alternative site beneath the deep fascia in the mid-arm by longitudinally imaging the basilic vein. The cephalic vein is another possibility, as it has no adjacent artery or nerve. Real-time sonography can be used to locate and guide the needle into the veins. This also confers the advantage of preventing inadvertent arterial puncture, multiple vessel punctures, and nerve damage. The median and ulnar nerves are in close proximity to the basilic vein in the proximal part of the arm and advancing the needle blindly may lead to nerve injuries. Keyes and colleagues (Keyes *et al.*, 1999) and Kramer and colleagues (Kramer *et al.*, 1983) observed nerve injuries in 1% and 8% patients respectively, as a result of blind technique.

Venepuncture and venesection are methods of gaining access to superficial veins. Venepuncture is puncturing a vein with a needle for withdrawal of blood, blood donation or giving IV medications. (Klein and Anstee, 2005). Venesection is incision of a vein for the removal or withdrawal of blood; removes a quantity of venous circulating blood as a therapeutic treatment for patients with polycythemia, haemochromatosis or porphyria (Dutton, 1916). The veins at the cubital fossa are the preferred veins for drawing blood for a number of reasons. First, they are close to the skin and it is easier to access with minimal trauma and bruising. This vein is also in a place which lacks an abundance of nerve endings. In other words, while having blood drawn from the arm causes some degree of discomfort to almost everyone, there are many places where it would be much more painful.

A peripherally inserted central catheter (PICC) permits infusion of blood products, solutions containing medication or nutritional substances without causing the complications that may occur with a cannula, such as local tissue damage when a toxic drug leaks out of the vein.

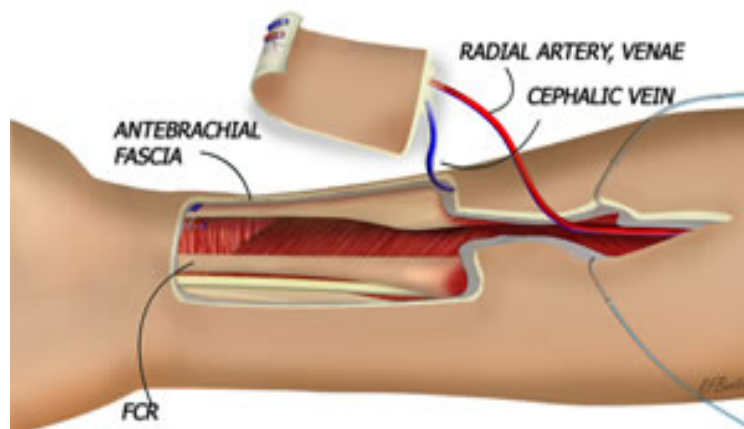
Ultrasound has been used for inserting central venous catheters in the antecubital region by Parkinson and colleagues (Parkinson *et al.*, 1998) by visualization of the vein and an advancing needle, catheter or guide wire in real-time. It is very easy and suitable to use ultrasound in this region for placement of central venous catheters especially when it is difficult to get venous access. The basilic vein and median basilic vein are commonly used in central venous catheterization. Identification of veins by the ultrasound spares the patient the discomfort and stress of repeated needle sticks. PICC is an extremely useful solution for patients who for any reason require repeated entry into the venous circulation over a long period. Placement of the vascular access device is a great solution for those requiring prolonged treatment such as chemotherapy (Matsuzaki *et al.*, 2006). It prevents from repeated IV line insertion for each treatment and scarring of the veins.

Surgeons need to become familiar with various anatomical variations of venous structures in the operating field in order to create an effective arteriovenous fistula (AVF) in patients with sustained chronic renal failure (CRF). In view of variety and different types of cubital venous patterns, there are more than a 90% possibility of creating suitable AVFs in the cubital fossa , but in the wrist and forearm, due to old injections and thrombophlebitis, there is less chance to do so (Alamshah, 2004). Grafting the antecubital veins to the brachial artery, because of anatomical variety and the number of veins in this region is more successful. Ultrasound duplex has capability in various facets of arteriovenous access planning and management (Wellen and Shenoy, 2009). The utility of this modality in preoperative vascular access planning is well established.

It is important in plastic surgery too when the veins commonly used when harvesting the free forearm flap or used as cephalic vein pedicle flap (CVPF) (Lamberty, 1983). The radial artery



forearm free flap (RAFFF) is a versatile and popular flap used in various reconstructive procedures. This flap contains two venous drainage systems: a superficial (cephalic) route, and a deep (venae comitantes) route. Most surgeons use either the deep venous system alone or in combination with a superficial vessel, hence requiring two venous anastomoses. The cephalic vein or a cutaneous vein can be taken with the flap. The cephalic vein can be identified by using the ultrasound. Later the vein is reversed and used for the reconstruction. It has many uses, ranging from reconstruction of skin and scalp defects to repair of composite intraoral defects.



**Fig 1.8 Cephalic vein used for forearm flap**

## **1.5 Patterns of Superficial Veins of Cubital Fossa**

The pattern of superficial veins in an arm which has been described in the classical textbook indicates the presence of a cephalic vein on the radial side of the forearm, beginning from the superficial veins of thumb and dorsal venous network of hand, running up lateral side of forearm and arm and ending in the axillary vein by piercing the clavipectoral fascia. The basilic vein is described, beginning in the dorsal venous network and running up, first the dorsum, and then the medial side of the forearm and arm to pierce deep fascia of arm and continue into axillary vein. These two venous lines are connected in cubital fossa by a median cubital vein running upwards from cephalic to basilic vein. This median cubital vein is connected to the deep veins of the forearm by a direct communicating vein (Grant, 1948; Basmajian, 1971; Williams, 1980).

Both Gray (Gray, 1967) and Cunningham (Cunningham, 1964) describe a median vein of the forearm or median antebrachial which, begins in the palmar venous network and ends in either basilic, or median cubital, or divides at its termination into two veins, the median cephalic vein to join cephalic and the median basilic vein to join basilic vein. Gray describes an accessory cephalic vein either arising from the ulnar side of the dorsal venous network and joining the cephalic vein below the elbow, or arising from the cephalic above the wrist and rejoining it above the elbow.

Others wrote that a large median vein ascends in the middle of the forearm and divides into median cephalic and median basilic veins which diverge from it to join the cephalic and basilic veins respectively (Hamilton, 1976; Romanes, 1981). Romanes mentioned that the median vein of the forearm if present runs to the elbow and may join the median cubital or

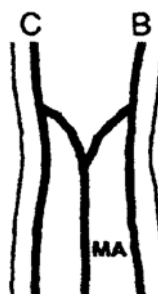basilic vein. The superficial veins of the forearm are extremely variable and any one of them may be absent.



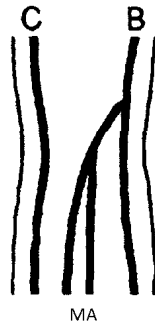**Figure1.9 Median cubital vein (MC) running upward from cephalic vein (C) to basilic vein (B)**



**Figure1.10 Median antebrachial vein (MA) joins the median cubital vein (MC).**



**Figure 1.11 Median antebrachial vein (MA) diverge to join cephalic and basilic respectively**



**Figure 1.12 Median antebrachial vein joins the basilic vein**

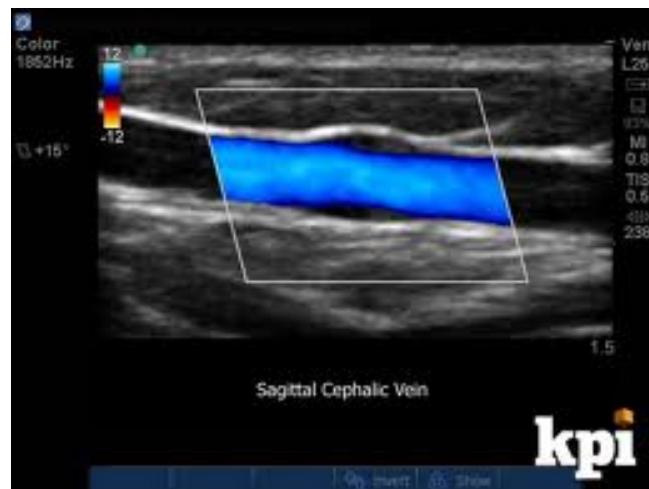## **1.6 Duplex ultrasound in Vascular Access**

### **1.6.1 Duplex Ultrasound**

Ultrasound uses sound waves with a frequency greater than that of audible sound. In medical applications, the range of frequency of sound waves used is from 2 to 20 megahertz (MHz). Ultrasound transducer probes used in vascular access in the present generation have multiple piezoelectric crystals capable of emitting ultrasound waves when stimulated by electrical energy and are called linear array transducers. Assuming that the sound waves travel through soft tissue at a constant speed, variable amounts of sound waves are reflected back (*echo*) at the interface between different soft tissues (e.g., subcutaneous tissue and muscle interface) and have different acoustic impedance (tissue density that affects sound wave propagation). Assuming that sound waves travel in a straight line, the crystals that emit these waves in the transducer also sense the reflected waves and convert the sound energy back to electrical energy. The handheld probes which cleverly engineered, utilize computer capabilities to process the information transduced, based on the distance traveled by the wave that was emitted before it was reflected and presents this information in a two-dimensional spatial manner on a television screen, thereby producing an image in grey scale (B mode). The speed

at which the sound pulses can be generated depends on the frequency of the ultrasound. Present transducer probes have the capacity to generate and gather return-wave information at rapid rates.

Duplex Doppler is the term used for a combination of the B mode for imaging and Doppler for flow evaluation. The B mode provides imaging for accurate focusing of the Doppler to assess flows in specific locations. This is the most useful imaging modality for the functional evaluation of a vascular access (Merritt, 2005). Most Duplex Doppler machines are capable of color flow that adds color to a two-dimensional image based on direction or volume of the blood flow.



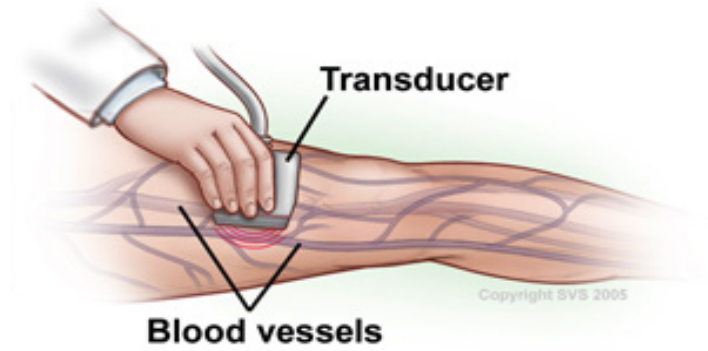
**Figure 1.13: Sagittal view of cephalic vein on duplex ultrasound (adapted from sciencedirect.com)**

### **1.6.2 Ultrasound in Vascular Access Planning**

A careful history and physical examination such as history of central and peripheral vein abuse, coagulation disorders, anatomy, and quality of available arteries and veins, continues to be the mainstay of vascular access evaluation. However, clinical examination is of limited value in patients who are overweight and obese. Clinical examination is also not very reliable in identifying the quality of the vessel wall and especially the amount of calcification and consequently the luminal diameter of the vessels. Ultrasound vessel mapping should always complement thorough clinical evaluation. Such an approach has shown to increase the incidence of AVF placement and maturation. The technique of vein mapping has been outlined in many publications, including the guidelines from the Fistula First Initiative (Sidawy *et al.*, 2008). During mapping, it is important to note the size and continuity of the outflow vein. It is also important to note the relation of the vein to the artery.

To create a successful arteriovenous anastomosis, such anatomic variations play a key role in planning incisions to identify, dissect, and mobilize veins. Ultrasound vein mapping to assess the diameter and quality of veins has shown to increase the success of fistula maturation (Ives *et al.*, 2009). The appreciation of vascular anatomy in a given individual and comprehension of the spatial relationships of the artery to the vein are very important components of vessel mapping. This becomes critical as there is often considerable variation in the normal anatomy in any given patient population forcing the surgeon to tailor an incision to achieve necessary dissection and mobilization for AVF creation. This becomes even more important during the evaluation of patients with variations in anatomy or those with multiple previous surgeries, a vascular surgeon with the operative and clinical background is often in a position to notice subtle nuances in the surgical anatomy in a given patient while viewing by real time ultrasound scanning. The surgeon is provided with a view of the vascular anatomy that lies

beneath the skin, thereby adding an entire new dimension to clinical evaluation while planning a vascular access procedure.



**Figure 1.14: Duplex ultrasound used in venous mapping.**

# **CHAPTER 2**

## **LITERATURE REVIEW**

### **2.1 Overview**

This chapter reviews literatures that related to superficial venous patterns of cubital fossa in various parts of the world. Knowledge of the superficial veins in the cubital region with variants is directly needed for the safety and survival of the patients in operative or emergency procedures.

### **2.2 Superficial Venous Patterns at Cubital Fossa**

Anatomist and surgeons have recognized the frequent variation in the arrangement of the superficial veins of the cubital fossa. The arrangement of these veins may be studied by dissection of cadavers or by placing a tourniquet around the arm of an individual and then observing the pattern resulting as the veins become engorged.

The latter method has been employed by Berry in British (Berry and Newton, 1908), by Lassila in Finns (Lassila, 1931), and by Okamoto in the Japanese (Okamoto, 1922). The patterns shown in the illustrations of these veins in the modern text books and atlases of human anatomy are by no means identical.

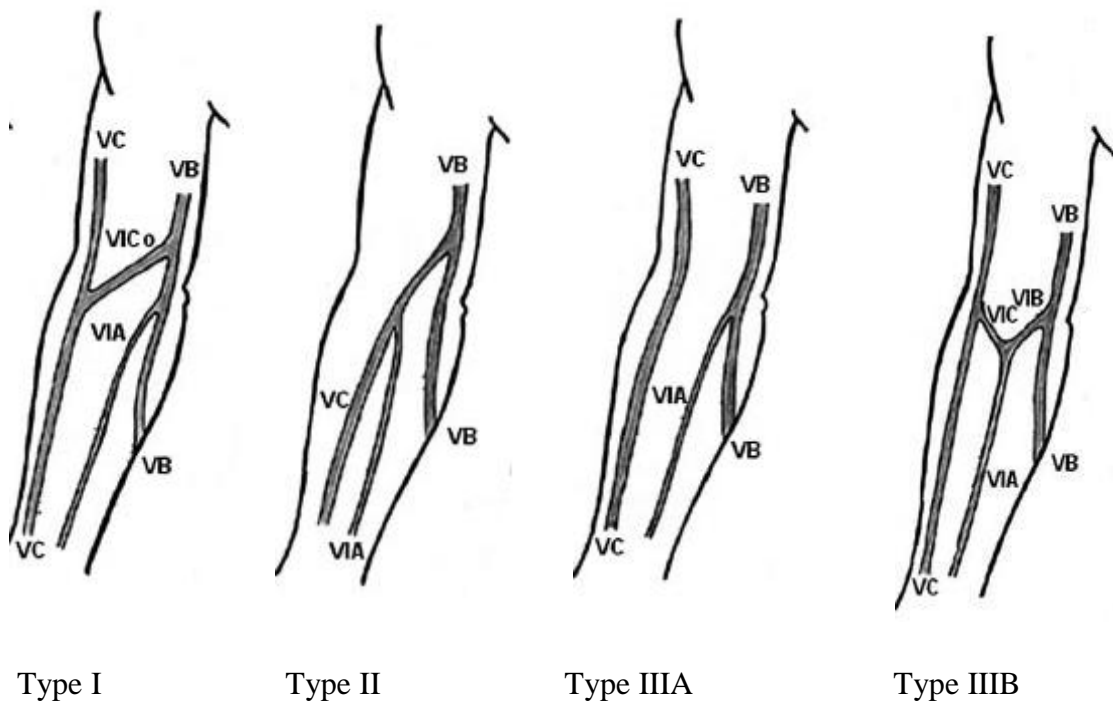


Out of the various patterns reported by the above workers the following three types of basic patterns can be worked out.

Type I: The cephalic vein communicating through the median cubital vein with the basilic vein in the elbow region.

Type II: The cephalic vein draining into the basilic vein in the elbow region.

Type III: The cephalic and the basilic veins without any direct communication in the elbow region, the median vein of the forearm joining either of the two (III A) or both (III B), after dividing into a median cephalic and a median basilica branches.



**Figure 2.1: Classical patterns of superficial veins of cubital fossa** (VC: cephalic vein VB: basilic vein, VIC0: median cubital vein, VIA: median vein of forearm, VIC: median cephalic vein, VIB: median basilic vein).

These basic patterns cover over 90% of the cases of each of the above sets of workers. The pattern most commonly encountered by each set of the workers conforms to the type I above except for Tewari (Tewari, 1971). According to them the pattern in the majority of Indians conforms to the type 111 B.

**Table 2.1 Comparison of the percentage incidences of the three basic types of venous patterns in the cubital region**

Names of the researchers	Total number of limbs studied	type1	type11	type111A	type111B
		%	%	%	%
Berry and Newton (1908)	600	83.0	0.3	0.7	16.0
Okamoto (1922)	200	84.5	0	14.5	1.0
Charles (1932)	244	70.5	1.6	8.2	19.7
Tewari(1971)	600	16.5	3	10.0	70.5

The table above will show that the most common pattern of the superficial veins in the cubital region conforms to the usual text book description, with a cephalic vein joined to the basilic vein by means of a median cubital vein (type I). This applies not only in the British, the Japanese and but also in the Americans. The reason for the much lower figure (16.5%) of Tewari for this type of pattern (their pattern 2) was not obscured. These researchers apparently confined their observations to the cubital region where a more medially located cephalic vein can be easily confused for the median vein of the forearm. Such a cephalic vein, having given off the median cubital vein, turns upwards and laterally and is usually joined by an accessory cephalic vein which can be mistaken for the cephalic vein itself.