



Contents lists available at ScienceDirect

Respiratory Medicine Case Reports

journal homepage: www.elsevier.com/locate/rmcr

Case report

Case report: Unusual cause of difficulty in intubation and ventilation with asthmatic-like presentation of Endobronchial Tuberculosis



S. Praveena Seevaunnamtum^{a,*}, Nazhan Afeef Mohd. Ariff @ Ghazali^a, Wan Mohd Nazaruddin^a, Alwi Muhd Besari^b, N.H. Nik Fariza^c, Sanihah Che Omar^a, Saedah Ali^a, M.Z. Rhendra Hardy^a, Mohd Erham Mat Hassan^a, N.M. Nik Abdullah^a

^a Department of Anaesthesiology & Intensive Care, School of Medical Science, Health Campus, Universiti Sains Malaysia, 16150 Kubang Kerian, Kelantan, Malaysia

^b Department of Internal Medicine, School of Medical Science, Health Campus, Universiti Sains Malaysia, 16150 Kubang Kerian, Kelantan, Malaysia

^c Department of Otorhinolaryngology-Head & Neck Surgery, School of Medical Science, Health Campus, Universiti Sains Malaysia, 16150 Kubang Kerian, Kelantan, Malaysia

ARTICLE INFO

Keywords:

Endobronchial tuberculosis
Bronchospasm
Subglottic stenosis
Bronchial asthma

ABSTRACT

Endobronchial Tuberculosis is hazardous in causing circumferential narrowing of tracheobronchial tree despite the eradication of tubercle bacilli in the initial insult from Pulmonary Tuberculosis. They may present as treatment resistant bronchial asthma and pose challenge to airway management in the acute setting. We present a 25 year-old lady who was newly diagnosed bronchial asthma with a past history of Pulmonary Tuberculosis that had completed treatment. She presented with sudden onset of difficulty breathing associated with noisy breathing for 3 days and hoarseness of voice for 6 months. Due to resistant bronchospasm, attempts were made to secure the airway which led to unanticipated difficult intubation and ventilation. Subsequent investigations confirmed the diagnosis of Endobronchial Tuberculosis and patient was managed successfully with anti TB medication, corticosteroids and multiple sessions of tracheal dilatation for tracheal stenosis. This case highlights the unusual cause of difficulty in intubation and ventilation due to Endobronchial Tuberculosis, which required medical and surgical intervention to improve the condition.

1. Introduction

Incidence of Endobronchial Tuberculosis (EBTB) has been reported in 6–50% of cases of Pulmonary Tuberculosis (PTB) [1,2]. True incidence is fairly unknown as it is not common practice to perform diagnostic bronchoscopy in all patients with PTB. Despite successful treatment PTB with eradication of tubercle bacilli, the advent of bronchial stenosis is still rampant [1].

EBTB often has non-specific clinical presentation with chronic cough as a major symptom [2]. However, with the onset of bronchial stenosis and stricture up to a critical diameter of approximately 6mm in an adult population, patients may also present with similarly with bronchospasm [1]. They are great mimickers of bronchial asthma at this stage. If these population of patients require intubation, clinicians may have unanticipated difficulty in intubation and ventilation while trying to secure the airway.

The aim of this report is to highlight dangers of diagnostic error as

bronchial asthma in acute presentation instead of EBTB and the challenges of intubation and ventilation with subsequent bronchoscopic interventions to maintain airway patency.

2. Case report

We present a 25 year old lady, recently diagnosed asthmatic who presented to Emergency Department (ED), with sudden onset of difficulty breathing associated with noisy breathing for 3 days and hoarseness of voice for 6 months. A year ago, she was treated as PTB and had completed treatment. Since then, she had multiple episodes of bronchospasm that required nebulization at a local clinic precipitating the diagnosis of bronchial asthma.

On presentation, she was in respiratory distress with silent chest and marked use of accessory respiratory muscles. An arterial blood gas revealed a severe respiratory acidemia. She received treatment including hydrocortisone, continuous nebulised beta-2 agonists, magnesium,

Abbreviation: EBTB, Endobronchial Tuberculosis; PTB, Pulmonary Tuberculosis; ED, Emergency Department; ETT, Endotracheal tube; FNPLS, Flexible Nasopharyngolaryngoscope; CT, Computed Tomography

* Corresponding author.

E-mail address: praveenaseeva@usm.my (S.P. Seevaunnamtum).

<http://dx.doi.org/10.1016/j.rmcr.2017.10.011>

Received 13 September 2017; Accepted 27 October 2017

2213-0071/ © 2017 The Authors. Published by Elsevier Ltd. This is an open access article under the CC BY-NC-ND license (<http://creativecommons.org/licenses/by-nc-nd/4.0/>).

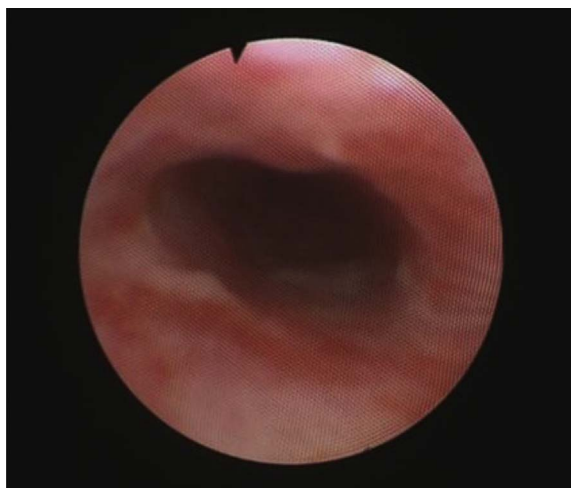

Fig. 1. Day 1- FNPLS showing evidence of subglottic stenosis.

antibiotics, and a salbutamol infusion. As her bronchospasm was not responding, ED team decided for intubation. Multiple attempts at intubation at ED before an alert to ICU was made, as although the larynx was visualized as Cormack-Lehane I, they were unable to advance the Endotracheal Tube (ETT) beyond more than 1 cm past the vocal cord. Finally, she was intubated with ETT size 6.0mm Internal Diameter where cuff was just after the vocal cord and anchored at 16 cm. We had difficulty ventilating her as her peak airway pressure's was persistently high with severe respiratory acidosis.

With the abnormal laryngoscopy and life-threatening bronchospasm and alternative diagnoses were explored. She underwent flexible nasopharyngolaryngoscope (FNPLS) that revealed subglottic stenosis (Fig. 1). CT Thorax/Neck showed features of tracheobronchial stenosis with post primary PTB changes (Fig. 2). Patient was subsequently treated successfully with anti TB medication and underwent multiple sessions of tracheal dilatation (Fig. 3a–c).

3. Discussion

We report a rare case of tracheobronchial stenosis secondary to

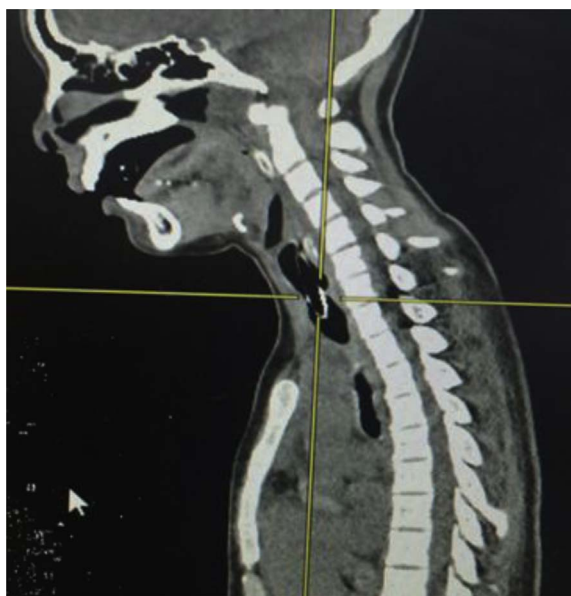

Fig. 2. CT Thorax pre intervention, Sagittal plane: Trachea narrowing 4.6 cm from hyoid bone, 0.8 cm length and 9.5 cm from hyoid bone, 8.7cm length. Right main bronchus narrowest diameter was 0.3 cm.

EBTB. Although rare, TB can present as EBTB with airway obstruction due to chronic inflammation causing circumferential narrowing [3]. EPTB is defined as a tuberculous infection of the tracheobronchial tree with microbial and histopathological evidence [4]. Bronchial stenosis and stricture secondary to PTB has been noted in up to 50% of cases of PTB [5].

The anatomy of the larynx and trachea are of great importance from a clinical stand point. In the larynx and trachea airflow is usually turbulent. The driving pressure for turbulent flow is proportional to the square of the flow rate and inversely related to the fifth power of the radius. Thus, a minor decrease in the circumference trachea results in a significant increase in the driving pressure necessary to achieve the same airflow [6]. Interestingly, EBTB is present in 10–40% of patients with active pulmonary tuberculosis, and more than 90% of the patients with EBTB have some degree of bronchial stenosis [7].

This case highlights the notion of how EBTB can present as treatment resistant asthma and the importance of recognising the diagnostic dilemma. Airway management in a patient with tracheobronchial stenosis will pose to be challenging as we have to ensure adequate ventilation despite the stenotic segment and the process of securing the airway as well [8]. Although fortunate, this case represents the nightmare of such patient being intubated by a team that neither anticipated nor prepared for a possibility of difficult intubation and ventilation. In the event intubation was not possible, subsequent life saving measures like surgical tracheostomy may also be difficult. Amongst possible airway manipulation that could be considered is trial of intubation with a smaller endotracheal tube to stent the stenosis and provides oxygenation.

Our case report also shows the difficulty in a clinician coming up with the diagnosis of an EBTB be it at the ED or local clinic due to the variability of the disease presentation. In this case the patient had multiple visits to the local clinic with signs and symptoms that could have been also explained by bronchospasm. It is not uncommon for EBTB to present with a localized low pitch wheeze or rhonchi. Reports show classical monophonic wheeze in 15% of patients [9].

Commonly, amongst the first investigations in a patient with a past history of PTB would have been smear examination. Despite being highly infective, the yield of sputum smear for AFB is not as high as in parenchymal involvement even in an optimal laboratory setup with meticulous sputum examination. In recent studies, sputum positivity in EBTB has been demonstrated only about 31.4% [10]. The other common investigation is a chest radiograph, which also does not help rule out the presence of EPTB as up to 40% of patients have a normal findings [11].

Hence, keeping in mind this diagnostic challenge towards EPTB, early bronchoscopy and computed tomography are the methods of choice for accurate diagnosis of bronchial involvement and assessment for surgical intervention. With the right early anti-tuberculous and corticosteroid treatment possible inflammation and oedema can be minimized for optimal tracheal dilatation.

Much of our current management especially in Bronchial Asthma is protocolised such as British Thoracic Guidelines [12] based on current evidence. While this is an excellent management in patients with the correct diagnosis, failure of response to protocol should be treated as a red flag by our trainees. This demonstrates the vulnerability of all doctors to this type of error. The process of making a diagnosis is always evolving and dynamic.

Hence although EBTB may be rare, it is worth considering in a wheezing patient who does not respond to conventional therapy. The adage “all that wheezes is not asthma”, first recognised by Chevallier Jackson about 100 years ago, still rings true today [13].

4. Conclusion

When apparent asthma is unresponsive to treatment present to clinical practice, clinicians should consider EBTB amongst their

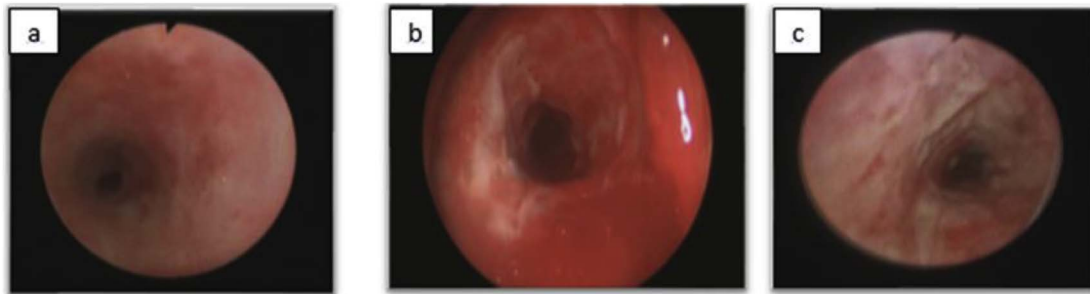


Fig. 3. Bronchoscopy findings (a) Day 3, pre dilatation of trachea: Cotton Meyer III, (b) Day 3, post dilatation: Cotton Meyer II (c) Day 9, trachea less inflamed with slough on mucosal surface.

differentials. If clinicians do anticipate EBTB as their differential diagnosis, it is wise to consider the perils of airway management during treatment of acute respiratory distress.

References

- [1] M. Faisal, H. Harun, T.M. Hassan, A.Y. Ban, S.H. Chotirmall, J.A.A. Rahaman, Treatment of multiple-level tracheobronchial stenosis secondary to endobronchial tuberculosis using bronchoscopic balloon dilatation with topical mitomycin-C, *BMC Pulm. Med.* 16 (1) (2016) 53.
- [2] S. Argun Baris, T. Onyilmaz, Tuğba Onyilmaz, I. Basyigit, H. Boyaci, Endobronchial tuberculosis mimicking asthma, *Tuberc. Res. Treat.* 2015 (2015) 3.
- [3] N.A. Bhatt, S. Parrish, R.F. Browning, A case of critical tracheal stenosis secondary to tuberculosis, *B48 CASE Rep. Tuberc. Am Thorac. Soc.* (2015) p. A3257-A.
- [4] G. Hoheisel, B. Chan, C. Chan, K. Chan, H. Teschler, U. Costabel, Endobronchial tuberculosis: diagnostic features and therapeutic outcome, *Respir. Med.* 88 (8) (1994) 593–597.
- [5] J.Y. An, J.E. Lee, S.A. Yang, S.S. Jung, J.O. Kim, S.Y. Kim, Clinical and bronchoscopic features in endobronchial tuberculosis, *Tuberc. Respir. Dis.* 60 (5) (2006) 532–539.
- [6] M.O. Al-Qadi, A.W. Arstenstein, S.S. Braman, The “forgotten zone”: acquired disorders of the trachea in adults, *Respir. Med.* 107 (9) (2013) 1301–1313.
- [7] J.K. Han, J. Im, J. Park, M. Han, Y.W. Kim, Y. Shim, Bronchial stenosis due to endobronchial tuberculosis: successful treatment with self-expanding metallic stent, *AJR Am. J. Roentgenol.* 159 (5) (1992) 971–972.
- [8] S. Arora, C.A. Bhargava, R. Singh, Airway management for tracheal stent insertion in a patient with difficult airway, *Indian J. Anaesth.* 57 (6) (2013) 617.
- [9] J.H. Lee, S.S. Turk, D.H. Lee, D.H. Shin, S.C. Yang, B.M. Yoo, Endobronchial tuberculosis: clinical and bronchoscopic features in 121 cases, *Chest* 102 (4) (1992) 990–994.
- [10] N. Samardžić, D. Jovanović, L. Marković-Denić, M. Roksandić-Milenković, S. Popević, V. Škodrić-Trifunović, Clinical features of endobronchial tuberculosis, *Vojnosanit. Pregl.* 71 (2) (2014) 156–160.
- [11] W. Yu, Z. Rong, Clinical analysis of 90 cases with endobronchial tuberculosis, *Zhonghua jie he hu xi za zhi = Zhonghua jiehe hu xuzhi = Chin. J. Tuberc. Respir. Dis.* 22 (7) (1999) 396–398.
- [12] B. Higgins, J. Douglas, The new BTS/SIGN asthma guidelines: where evidence leads the way, *BMJ Publ. Group Ltd.*, 2003.
- [13] T. Broom, C. Okereke, All that wheezes is not asthma, *Emerg. Med. J.* 25 (5) (2008) 311.