

Boon Chye Gan<sup>1</sup>, Wan Nor Najmiyah Wan Abdul Wahab<sup>2</sup>, Sharifah Emilia Tuan Sharif<sup>2</sup>,  
Norhafiza Mat Lazim<sup>1</sup>, Irfan Mohamad<sup>1</sup>

Received: 13.04.2017  
Accepted: 14.06.2017  
Published: 29.09.2017

## Bilateral tonsillar lymphangiomatous polyps in a snoring child

### Obustronne polipy migdałka o charakterze naczyniaka chłonnego u dziecka z problemem chrapania

<sup>1</sup> Department of Otorhinolaryngology – Head & Neck Surgery, School of Medical Sciences, Universiti Sains Malaysia, Health Campus, 16150 Kota Bharu, Kelantan, Malaysia

<sup>2</sup> Department of Pathology, School of Medical Sciences, Universiti Sains Malaysia, Kubang Kerian, Kelantan, Malaysia

Correspondence: Boon Chye Gan, Department of Otorhinolaryngology – Head & Neck Surgery, School of Medical Sciences, Universiti Sains Malaysia, Health Campus, 16150 Kota Bharu, Kelantan, Malaysia, tel.: +60105665008, e-mail: gbchye@gmail.com

#### Abstract

Lymphangiomatous polyps of the palatine tonsil are a rare clinical entity with only about 30 odd cases ever reported. All the cases in the literature were described as unilateral tonsillar diseases, except for one paediatric case which had bilateral tonsillar involvement. Due to its unilateral presentation and suspicious appearance similar to tonsillar malignancy, lymphangiomatous polyps may cause heightened anxiety to both patients and doctors alike on a routine oropharyngeal examination. Owing to its rarity and a variety of complex nomenclatures, this condition may also be confusing to the treating otolaryngologist as well as junior pathologist. We report an extremely rare case of bilateral tonsillar lymphangiomatous polyps in a snoring child that was successfully treated surgically via tonsillectomy.

**Key words:** tonsil, tonsillectomy, polyp, hamartoma, tumour

#### Streszczenie

Polipy o charakterze naczyniaka chłonnego migdałka podniebiennego są w praktyce klinicznej odnotowywane bardzo rzadko – dotychczas opisano jedynie około 30 przypadków. Zazwyczaj stwierdzano jednostronne zmiany w obrębie migdałka podniebiennego, tylko u jednego dziecka migdałki były zajęte obustronnie. Polipy o charakterze naczyniaka chłonnego mogą budzić zaniepokojenie pacjenta oraz lekarza ze względu na umiejscowienie po jednej stronie oraz wygląd przypominający nowotwór migdałka. Zważywszy na rzadkość występowania oraz różnorodność nazewnictwa jednostka ta może być również trudna do rozpoznania zarówno dla otolaryngologa, jak i niedoświadczonego patologa. Przedstawiamy niezwykle rzadki przypadek obustronnych polipów migdałka o charakterze naczyniaka chłonnego u dziecka z problemem chrapania, u którego skuteczny okazał się zabieg tonsillektomii.

**Słowa kluczowe:** migdałek, tonsillektomia, polip, hamartoma, guz

## INTRODUCTION

Lymphangiomatous polyps (LAP) are also known as angiomas, polypoid lymphangiomas, hamartomatous polyps, lymphoid polyps, and others<sup>(1-4)</sup>. Lymphangiomatous lesions are commonly found in the head and neck region, accounting for up to 90% of all lymphangiomas<sup>(1)</sup>. The sites are usually the skin or subcutaneous tissue, but may include areas such as the tongue, parotid gland and larynx<sup>(1)</sup>. Tonsillar occurrence is relatively rare. Common presentations include sore throat, dysphagia or the sensation of a lump in the throat, but snoring has never been the chief complaint<sup>(1)</sup>. Oropharyngeal examination commonly reveals a unilateral tonsillar enlargement with atypical appearance of a pedunculated mass extending from the tonsil<sup>(5)</sup>. The mainstay of treatment is tonsillectomy, but the difficulty lies in its preoperative diagnosis.

## CASE REPORT

A 12-year-old girl was referred by a primary care doctor due to snoring accompanied by a finding of unilateral left tonsillar hypertrophy suspicious for malignancy. She complained of snoring and mouth breathing. She denied any choking episodes, nocturia, morning headache, mood changes or daytime somnolence. There was no complaint of recurrent tonsillitis, neck swelling, or constitutional symptoms. Further history revealed she had been admitted to the gynaecology ward 6 months earlier, due to iron deficiency anaemia secondary to dysfunctional uterine bleeding. At that time, the treating gynaecologist had incidentally found multiple small lumps over her right breast. Fine needle aspiration cytology (FNAC) and ultrasonography of the right breast had been performed, with the lumps concluded to be benign findings, fibroadenoma category II, based on the breast imaging reporting and data system (BIRADS). She is an average primary school pupil with no history of smoking, alcohol intake, tuberculosis contact or any family history of malignancy. On oropharyngeal examination, the right tonsil was grade 2, while the left tonsil was grade 4 (Fig. 1). Both tonsils had polypoidal appearance with intact mucosa and mildly erythematous palatoglossal arches. There were few small and non-tender bilateral jugulodigastric lymph nodes. Other clinical examinations were unremarkable. Nasoendoscopy revealed a small amount of adenoid tissue.

Tonsillectomy was then performed under general anaesthesia, using dissection technique with cold instruments, while haemostasis was secured with bipolar diathermy. Both tonsils were sent for histopathological examination (HPE). The patient was discharged home with no more complaint of snoring, and recovered (Fig. 2).

Grossly, the specimen consisted of greyish tissue with multiple papillomatous nodules at the tonsillar surface, measuring 3 × 3 × 3 mm up to 10 × 5 × 3 mm. On microscopic

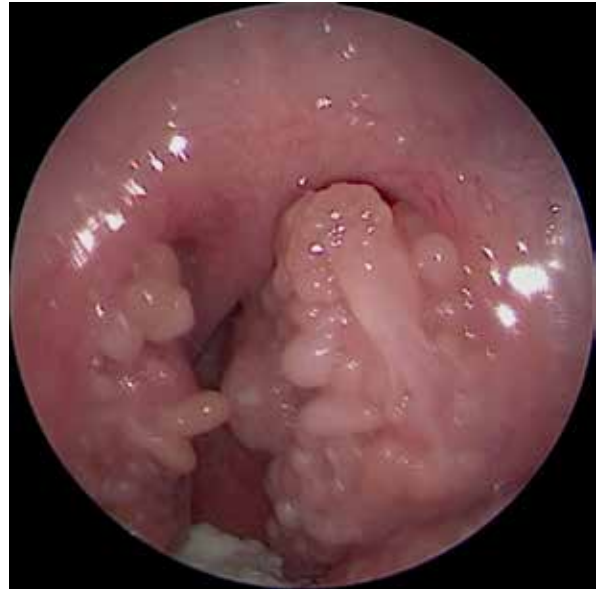

Fig. 1. Oropharyngeal examination revealed a substantially larger, grade 4 left tonsil in comparison to the right, grade 2 tonsil, with multiple pedunculated polypoidal structures

examinations, there were multiple pedunculated lymphoid polyps with stratified squamous epithelium covering (Fig. 3). In these polyps, there was proliferation of dilated lymphatic vascular channels within fibrous stroma with positive CD31 immunostaining (Fig. 4 A, C). These lymphatic vascular channels were filled with lymphocytes and positive for CD3 (Fig. 4 B, D). HPE found tonsillar LAP with a background of chronic tonsillitis, with no evidence of malignancy.

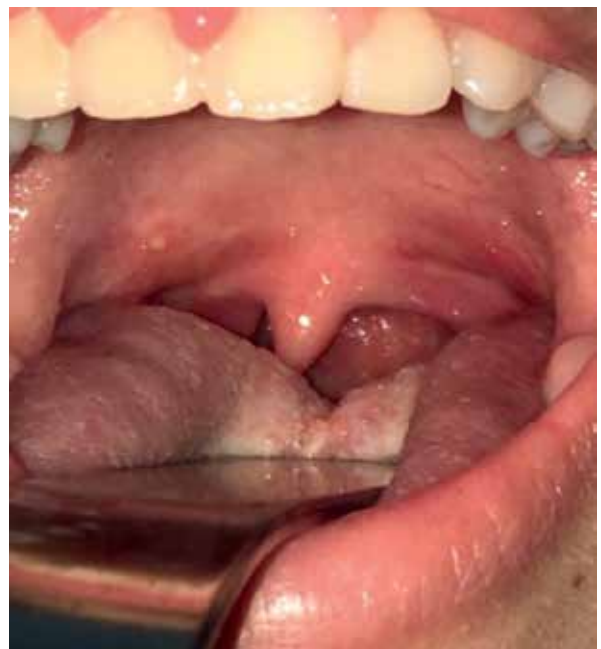

Fig. 2. Bilateral tonsillar fossae were already well healed at 2 weeks post tonsillectomy



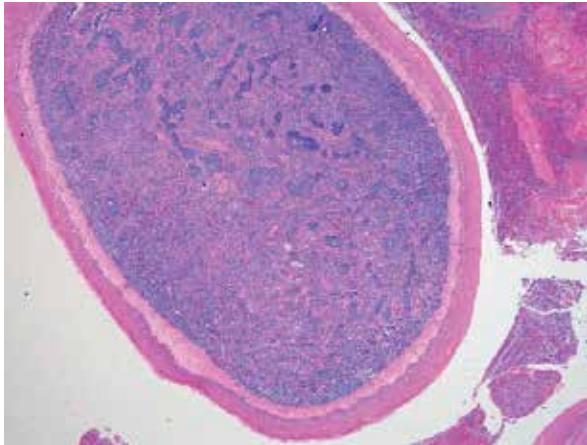


Fig. 3. The pedunculated lymphoid polyp arises from the tonsil covered by benign squamous epithelium ( $\times 40$  magnification)

### DISCUSSION

LAP may contribute to up to 8% of all benign tonsillar tumours<sup>(3)</sup>. The actual prevalence of LAP may be higher than reported because of confusing histological nomenclatures used for describing the lesion and the lack of awareness

among clinicians<sup>(1)</sup>. LAP often presents in adulthood, with a mean age of 25, with no sex predilection<sup>(1)</sup>. Most of the time, tonsillar LAP manifests as unilateral tonsillar hypertrophy with atypical appearance that may mimic a neoplasm. Unilateral tonsillar hypertrophy may be benign, such as chronic tonsillitis or squamous papilloma, but malignant differentials such as lymphoma, squamous cell carcinoma and metastatic disease must be ruled out first<sup>(6,7)</sup>. In this case, due to the asymmetrical tonsillar size and atypical, polypoidal appearance, diagnostic tonsillectomy was performed to rule out malignancy. A review of 30 tonsillectomies with unilateral tonsillar enlargement revealed 20% of the lesions were malignant<sup>(8)</sup>. These 20% of patients were found to have strong associative factors, such as suspicious appearance of the tonsil, cervical lymphadenopathy, constitutional symptoms and a strong family history of malignancy<sup>(8)</sup>. However, in the absence of sinister findings, unilateral tonsillar hypertrophy may just be an illusion created by the existing differences in the depth of the tonsillar beds, especially in paediatric patients<sup>(9)</sup>. Most patients with LAP will present with a sore throat, dysphagia, odynophagia or globus sensation<sup>(1)</sup>. This patient presented with snoring, which was atypical for tonsillar LAP. This may be attributed to the uniqueness of this case, possibly due to a higher degree of obstruction caused by bilateral

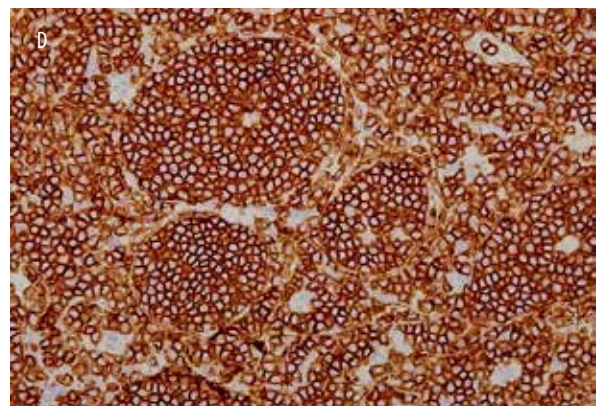
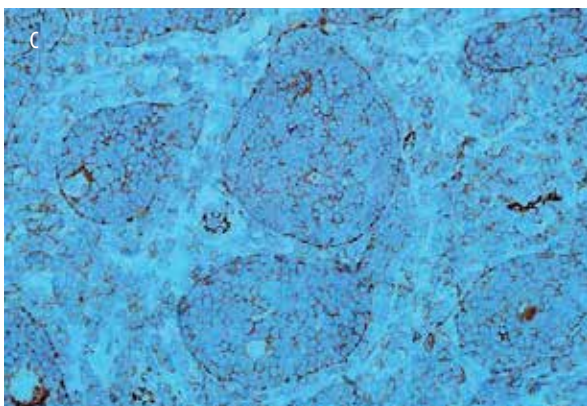
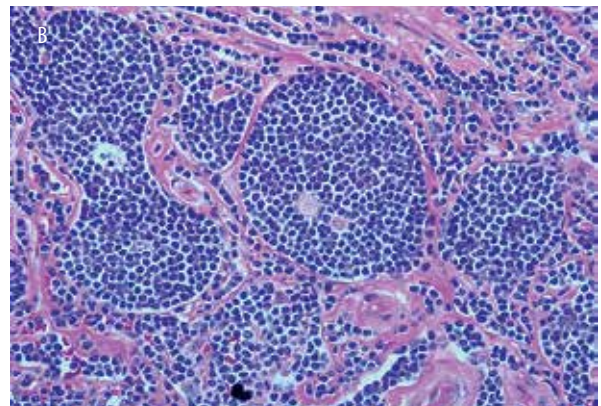
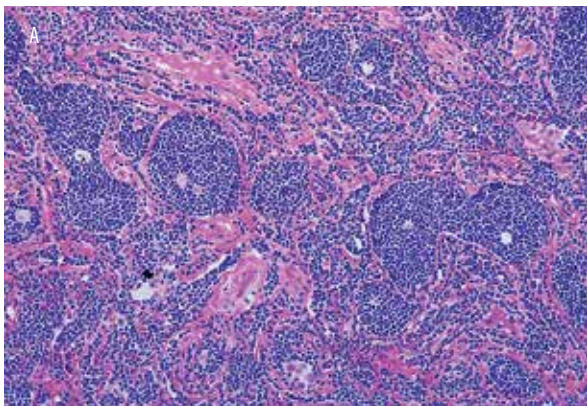


Fig. 4. **A.** The polyp composed of proliferation of lymphatic vascular channels within the fibrous stroma ( $\times 100$  magnification). **B.** The lymphatic vascular channels are stuffed with lymphocytes and thus more difficult to identify ( $\times 400$  magnification). **C.** CD31 highlights the endothelium of the lymphatic vascular channels ( $\times 400$  magnification). **D.** A predominantly T-cell (CD3) immunophenotype of the intralymphatic vascular lymphocytes ( $\times 400$  magnification)

disease rather than the more common unilateral tonsillar LAP. The exact aetiopathogenesis of LAP is debatable, but the presentation of this case may fit the theory of chronic inflammation and lymphatic channel obstruction leading to chronic tonsillitis<sup>(10,11)</sup>. This is due to the presence of mildly erythematous palatoglossal arches and jugular digastric lymph nodes and the histopathological confirmation. Microscopically, there were multiple lymphoid follicles and a prominent germinal centre covered with stratified squamous epithelium that showed features of chronic tonsillitis. LAP can be diagnosed with just routine microscopy and hematoxylin-eosin staining<sup>(2)</sup>. In microscopic examination, polyps are covered by stratified squamous epithelium with the presence of lymphatic vascular channel proliferation<sup>(1)</sup>. Immunohistochemical staining is not necessary for the diagnosis of LAP<sup>(2)</sup>. However, endothelial origin of the vascular proliferation can be highlighted using factor VIII related antigens, such as CD31<sup>(1)</sup>. Proper history taking and clinical examinations are important to diagnose tonsillar LAP, and the definitive diagnosis will be confirmed after the HPE report. To date, there are no reported cases of post-operative recurrence of tonsillar LAP, or malignant transformation. Therefore, a complete surgical excision via tonsillectomy in cases of tonsillar LAP can be regarded as both diagnostic and therapeutic.

## CONCLUSION

The true statistics of LAP are unavailable due to the lack of uniformity in terms of histologic nomenclatures and classification. Tonsillar LAP should be managed similarly to cases of unilateral tonsillar hypertrophy. Complete surgical excision via tonsillectomy should always be carried out whenever a suspicion of malignancy arises.

## Conflict of interest

*There is no financial support for our work or potential conflicts of interests.*

## References

1. Kardon DE, Wenig BM, Heffner DK et al.: Tonsillar lymphangiomas: a clinicopathologic series of 26 cases. *Mod Pathol* 2000; 13: 1128–1133.
2. Ryu HS, Jung SY, Koh JS et al.: Tonsillar lymphangiomas: report of two cases. *Korean J Pathol* 2006; 40: 381–384.
3. Barreto I, Juliano P, Chagas C et al.: Lymphoid polyps of the palatine tonsil. *Int J Surg Pathol* 2007; 15: 155–159.
4. Ormerod FC: Angioma of the tonsil. *J Laryngol Otol* 1926; 41: 797–800.
5. Chen HH, Lovell MA, Chan KH: Bilateral lymphangiomas of the palatine tonsils. *Int J Pediatr Otorhinolaryngol* 2010; 74: 87–88.
6. Hamid Z, Arul P, Madatang A et al.: Hamartomatous polyp of the palatine tonsil: a case report. *International Medical Journal* 2016; 23: 86–88.
7. Cortez EA, Mattox DE, Holt GR et al.: Unilateral tonsillar enlargement. *Otolaryngol Head Neck Surg* (1979) 1979; 87: 707–716.
8. Tobias Gómez S, Palomar Asenjo V, Borràs Perera M et al.: [Clinical significance of unilateral tonsillar enlargement]. *Acta Otorinolaringol Esp* 2009; 60: 194–198.
9. Harley EH: Asymmetric tonsil size in children. *Arch Otolaryngol Head Neck Surg* 2002; 128: 767–769.
10. Park E, Pransky SM, Malicki DM et al.: Unilateral lymphangiomas of the palatine tonsil in a very young child: a clinicopathologic case report. *Case Rep Pediatr* 2011; 2011: 451542.
11. Rahman WFWA, Jalil NAC, Mohamad I et al.: Hamartomatous polyp of the tonsil: a case report. *Arch Orolfac Sci* 2014; 9: 91–95.