

University of New Mexico  
**UNM Digital Repository**

---

Hand and Wrist

Orthopedics

---

4-16-2016

# A modified technique of partial trapeziectomy with capsular interposition as treatment for trapeziometacarpal osteoarthritis: a biomechanical study, short-term retrospective review, and medium-term follow-up

Deana Mercer

Christina Salas

Daniel Stewart

Gavin O'Mahoney

Dukens LaBaze

*See next page for additional authors*

Follow this and additional works at: [https://digitalrepository.unm.edu/hand\\_wrist](https://digitalrepository.unm.edu/hand_wrist)

---

## Recommended Citation

Deana Mercer, Christina Salas, Daniel Stewart, Gavin O'Mahoney, Dukens LaBaze, William McClellan, Moheb Moneim. A modified technique of partial trapeziectomy with capsular interposition as treatment for trapeziometacarpal osteoarthritis: a biomechanical study, short-term retrospective review, and medium-term follow-up. Poster presented at: 2013 New Mexico Shared Knowledge Conference; April 16-18 2013; Albuquerque, NM.

This Poster is brought to you for free and open access by the Orthopedics at UNM Digital Repository. It has been accepted for inclusion in Hand and Wrist by an authorized administrator of UNM Digital Repository. For more information, please contact [disc@unm.edu](mailto:disc@unm.edu).

---

**Authors**

Deana Mercer, Christina Salas, Daniel Stewart, Gavin O'Mahoney, Dukens LaBaze, William McClellan, and Moheb Moneim



# A Modified Technique of Partial Trapeziectomy with Capsular Interposition as Treatment for Trapeziometacarpal Osteoarthritis: A Biomechanical Study, Short-Term Retrospective Review, and Medium-Term Follow-Up

Deana Mercer, MD<sup>1</sup>; Christina Salas, MS<sup>1,2</sup>; Daniel Stewart, MD<sup>1</sup>; Gavin O'Mahoney, MD<sup>1</sup>; Dukens LaBaze, BS<sup>3</sup>; William McClellan, BS<sup>3</sup>; Moheb Moneim, MD<sup>1</sup>



1. Department of Orthopaedics and Rehabilitation  
2. Center for Biomedical Engineering  
3. School of Medicine  
The University of New Mexico, Albuquerque, USA



## INTRODUCTION

- Osteoarthritis (OA) of the trapeziometacarpal (TMC) joint is a common problem, affecting one in four people over the age of 45 with a 6:1 female predominance. (Fig. 1)
- Symptoms include pain at the base of the thumb, swelling and stiffness of the joint, and decreased pinch and grip strength – significantly affecting quality of life.
- Multiple surgical procedures are described for treating the symptoms of this disease, but none has been described which alleviates pain, preserves thumb length, stability, and strength.

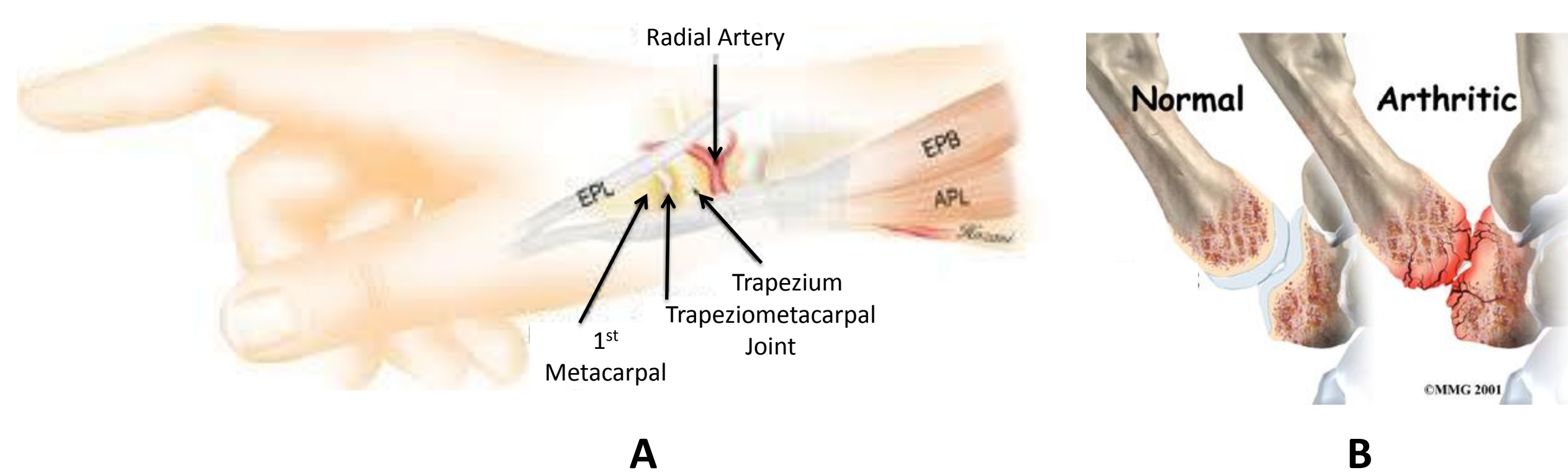


Figure 1: A. The trapeziometacarpal joint connects the trapezium bone of the wrist to the first thumb metacarpal. B. Representative images of normal and arthritic joints.

## PURPOSE

- We present a modified surgical technique of partial trapeziectomy with capsular interposition (PTCI) for treatment of TMC OA. In a matched-paired cadaveric study, short term retrospective review, and medium term follow-up of clinical cases, we demonstrate the possible advantages of this technique.

## METHODS

### Surgical Technique:

- The articular surface of the base of the 1<sup>st</sup> metacarpal (~2mm) is excised
- The distal articular surface of the trapezium (~2mm) is excised (Fig. 2A)
- Local soft tissue is utilized as interposition graft by capturing redundant capsular tissue with 1 or 2 figure-of-eight sutures (Fig. 2B)

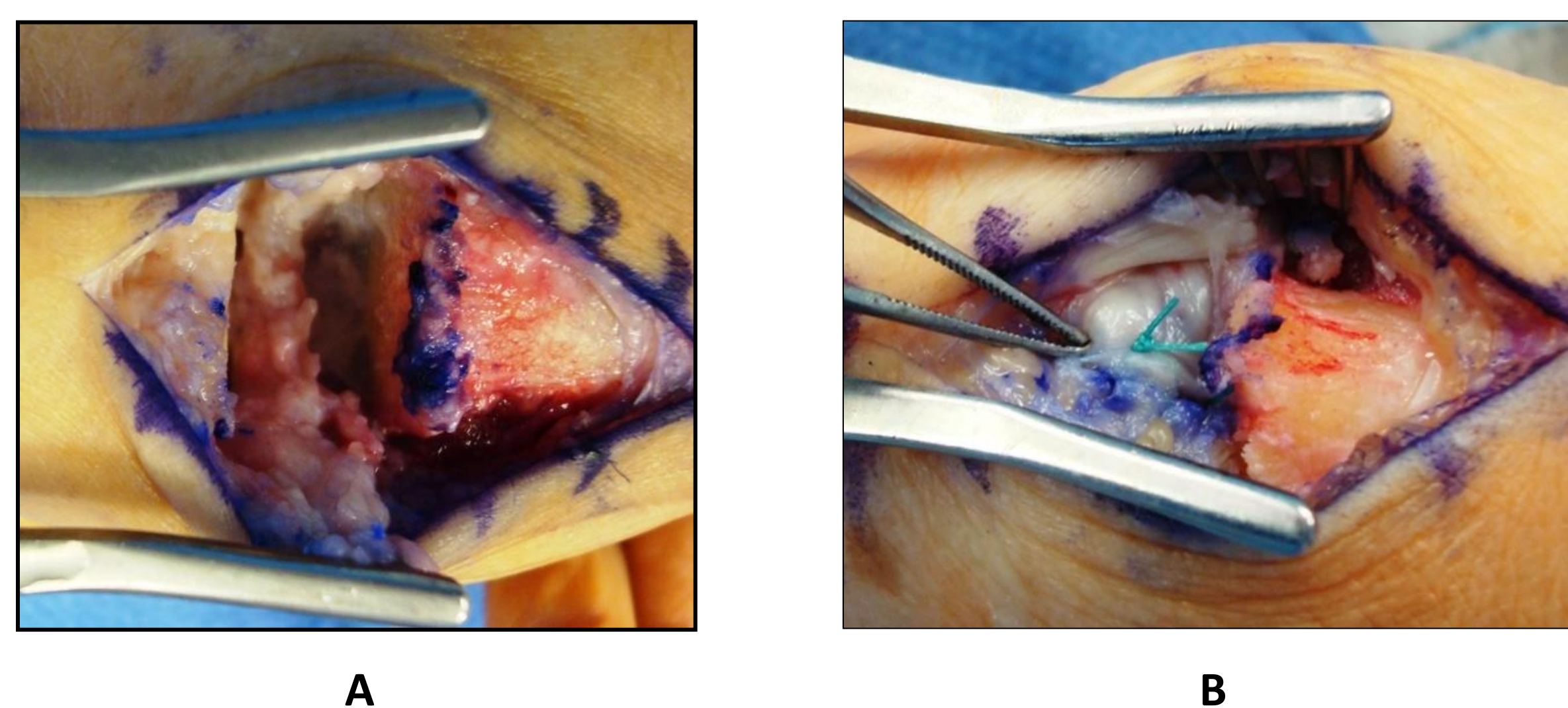


Figure 2: A. Modified partial trapeziectomy technique characterized by removal of ~2mm of the distal surface of the trapezium and ~2mm of the proximal surface of the first metacarpal. B. Interposition arthroplasty with local capsular tissue.

## METHODS

### Biomechanical Study:

- We quantified the metacarpal to scaphoid (M to S) distance from specimens treated with partial trapeziectomy (PTCI) and compare results with total trapezium resection (TRCI) in the contralateral limb
- Eight matched pairs of fresh frozen cadaveric hands were randomized into two groups:
  - Group 1: total trapeziectomy (TRCI)
  - Group 2: partial trapeziectomy (PTCI)
- Capsular interposition was utilized in both techniques
- K-wires were placed in the scaphoid and base of the metacarpal as reference points.
- Hands were stabilized in a custom jig and weighted sutures were attached to 6 tendons to allow lateral pinch thumb position. (Fig. 3)
- Calibrated antero-posterior images were taken using a mini-fluoroscopy unit to obtain native (untreated) joint measurements
- Specimens were treated with PTCI or TRCI and imaging was repeated
- M to S distance was measured with custom software
- A paired t-test was used to compare loss in thumb length determined by the relative M to S distance between native and treated joints

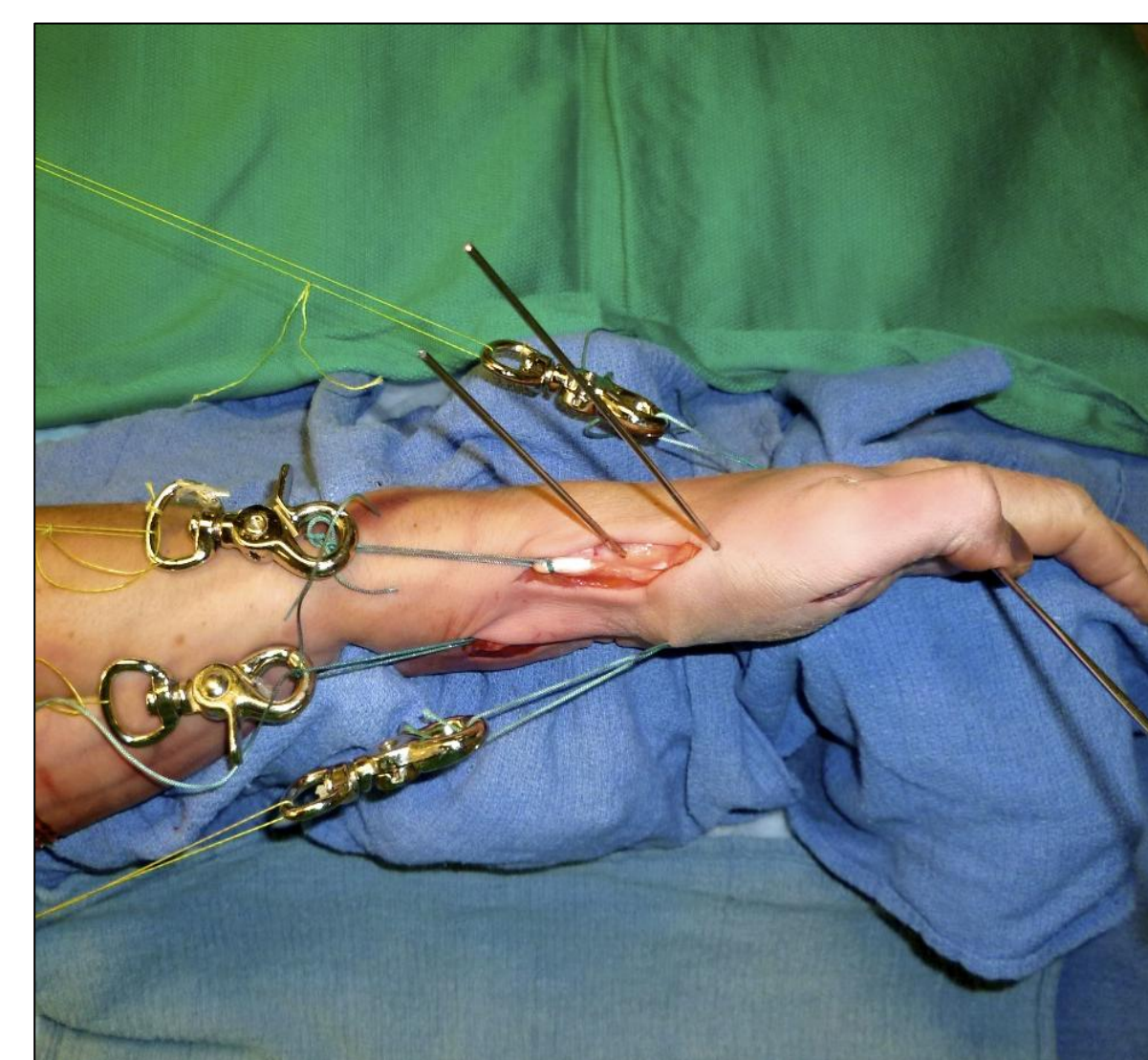

Figure 3: Experimental testing fixture showing trajectory of tendon loading and thumb lateral pinch motion.

### Short-term Retrospective Review:

- A retrospective review was completed of 71 consecutive surgeries in 67 patients (20 male/51 female; mean age 58.5+-7.0 y/o) performed over a 4 year period
- Inclusion criteria were all patients over 18 years of age who presented with TMC OA treated with PTCI by the senior surgeon
- Demographics, handedness, side of surgery, pre- and post-operative grip and pinch strength data were collected at 6 months to assess short-term outcomes

### Medium-term Follow-up:

- 22 patients (25 surgeries) returned (35%) to assess medium-term outcomes
- Grip and pinch strength, range of motion, first web space distance, and Disabilities of the Arm, Shoulder, and Hand (DASH) questionnaires were collected

## RESULTS

### Biomechanical Study:

- The relative M to S distance between native and treated joints was significantly different between the TRCI and PTCI groups ( $p=0.04$ ; 7.75+-3.09mm and 4.31+-3.25mm, respectively)

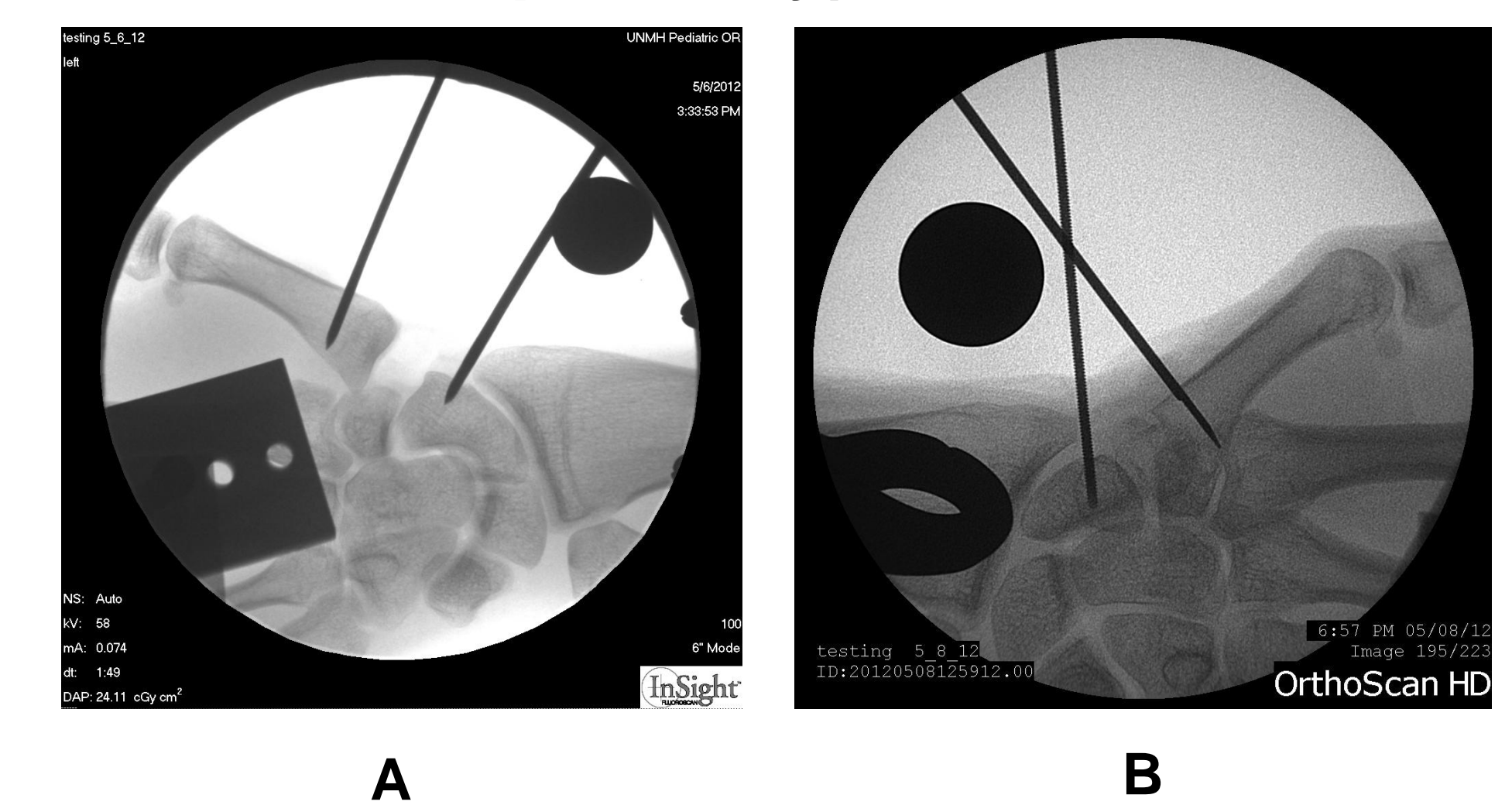


Figure 4: Antero-posterior radiographs showing K-wire placement in metacarpal and scaphoid bones plus spherical calibration marker after treatment with A. TRCI and B. PTCI.

### Short-term Retrospective Review:

- The difference in pre- and post-operative grip and pinch strength was not significant (0.4+-8.5kg and -0.8+-3.8kg, respectively)
- Complication rate was 2.86% (2 patients); 1 patient developing septic wrist with osteomyelitis of the distal ulna 3 months postoperatively; 1 patient developed proximal migration of 1<sup>st</sup> metacarpal with trapezium impingement

### Medium-term Follow-up:

- The difference in pre- and post-operative grip strength was significant (4.0+-4.3kg)
- There was no significant difference between the pre- and post-operative pinch strength (0.5+-2.0kg)

## CONCLUSIONS

- The biomechanical study showed PTCI minimized the loss in thumb length over the TRCI group by 3.44mm
- Medium-term clinical results show no loss in pinch strength and increased grip strength after PTCI

## CLINICAL RELEVANCE

- It has been shown that thumb shortening correlates with a reduction in thumb strength; PTCI maintains greater thumb length over common treatment for TMC OA (total trapeziectomy)
- Minimizing bone resection with less disruption of soft-tissue may lead to a more functional thumb

## ACKNOWLEDGEMENTS

- This project was supported in part by the National Center for Advancing Translational Sciences of the National Institutes of Health through grant number UL1 TR000041.