

5-19-2013

Clinical vignette: Ataxia and rash in a patient undergoing Hepatitis C treatment

Anthony Worsham

Follow this and additional works at: https://digitalrepository.unm.edu/hostpitalmed_pubs

Recommended Citation

Worsham Anthony; ATAXIA AND RASH IN A PATIENT UNDERGOING HEPATITIS C TREATMENT [abstract]. Journal of Hospital Medicine 8 Suppl 1 :735 [http://www.shmabstracts.com/abstract.asp?MeetingID=793&id=104328]

This Presentation is brought to you for free and open access by the Internal Medicine at UNM Digital Repository. It has been accepted for inclusion in Hospital Medicine by an authorized administrator of UNM Digital Repository. For more information, please contact disc@unm.edu.

ATAXIA AND RASH IN A PATIENT UNDERGOING HEPATITIS C TREATMENT

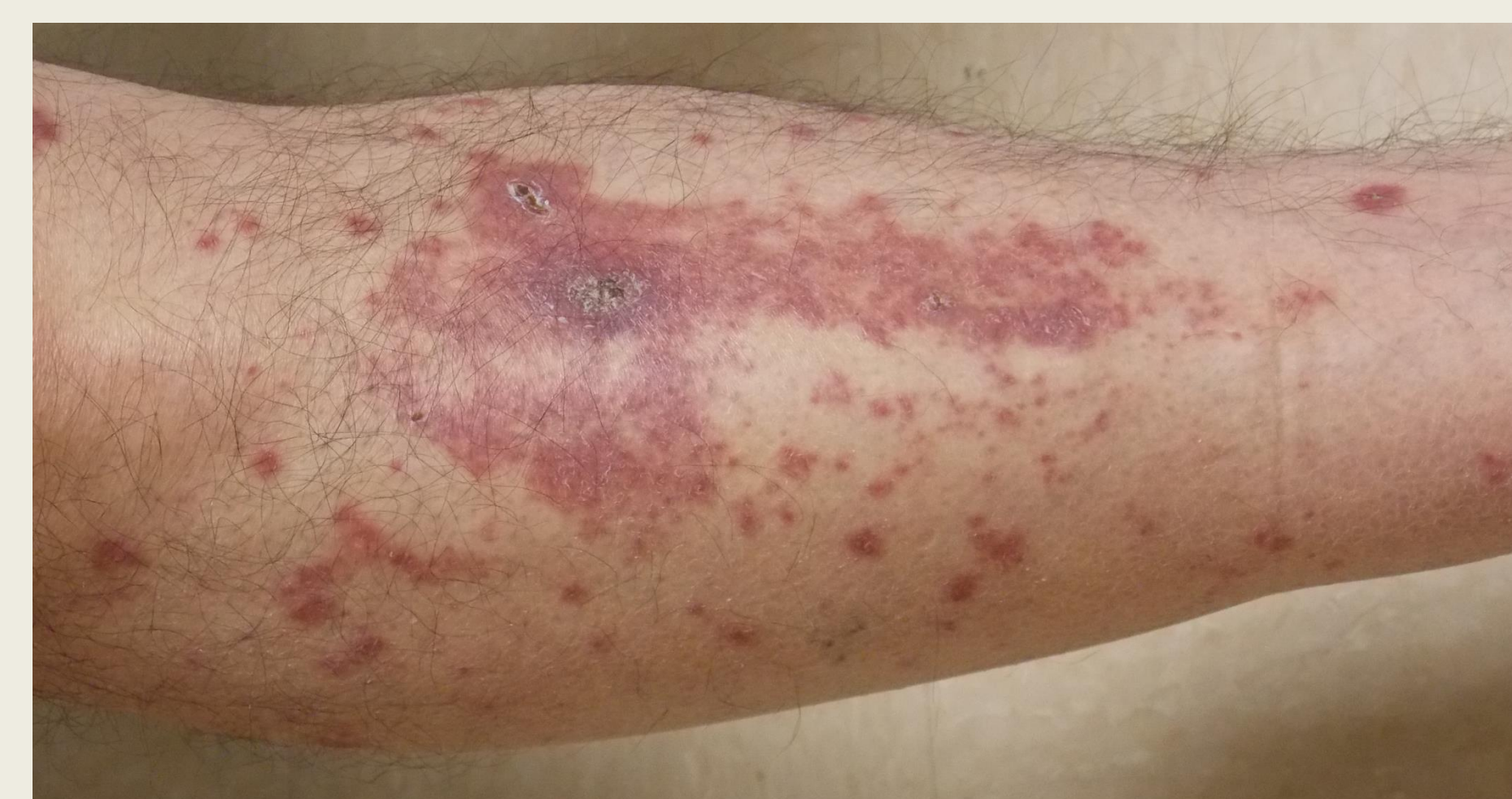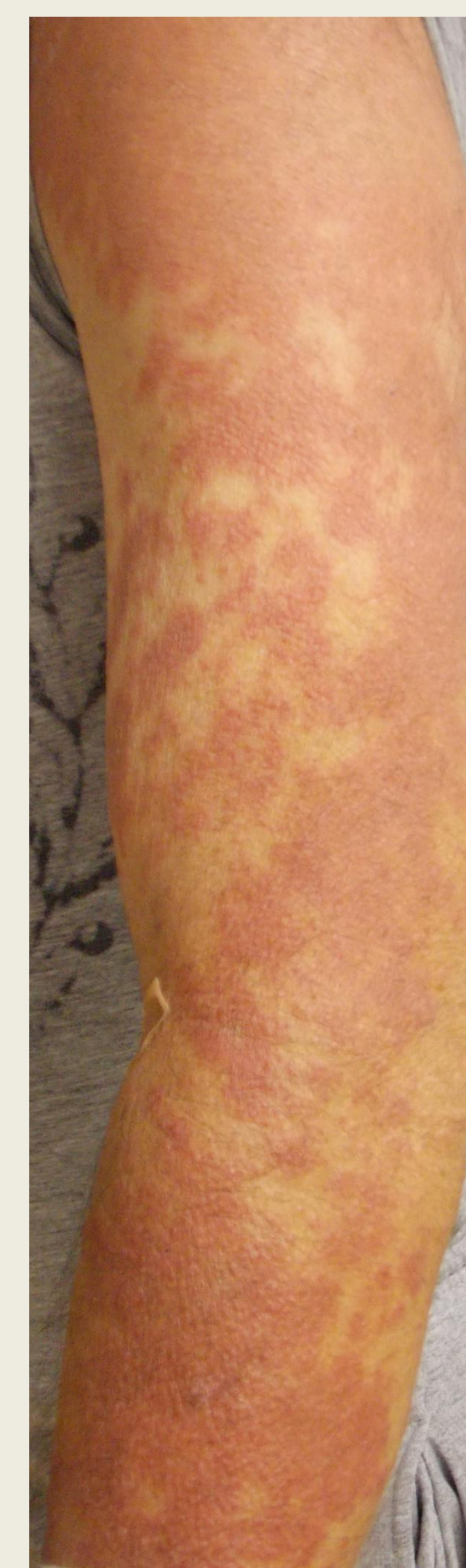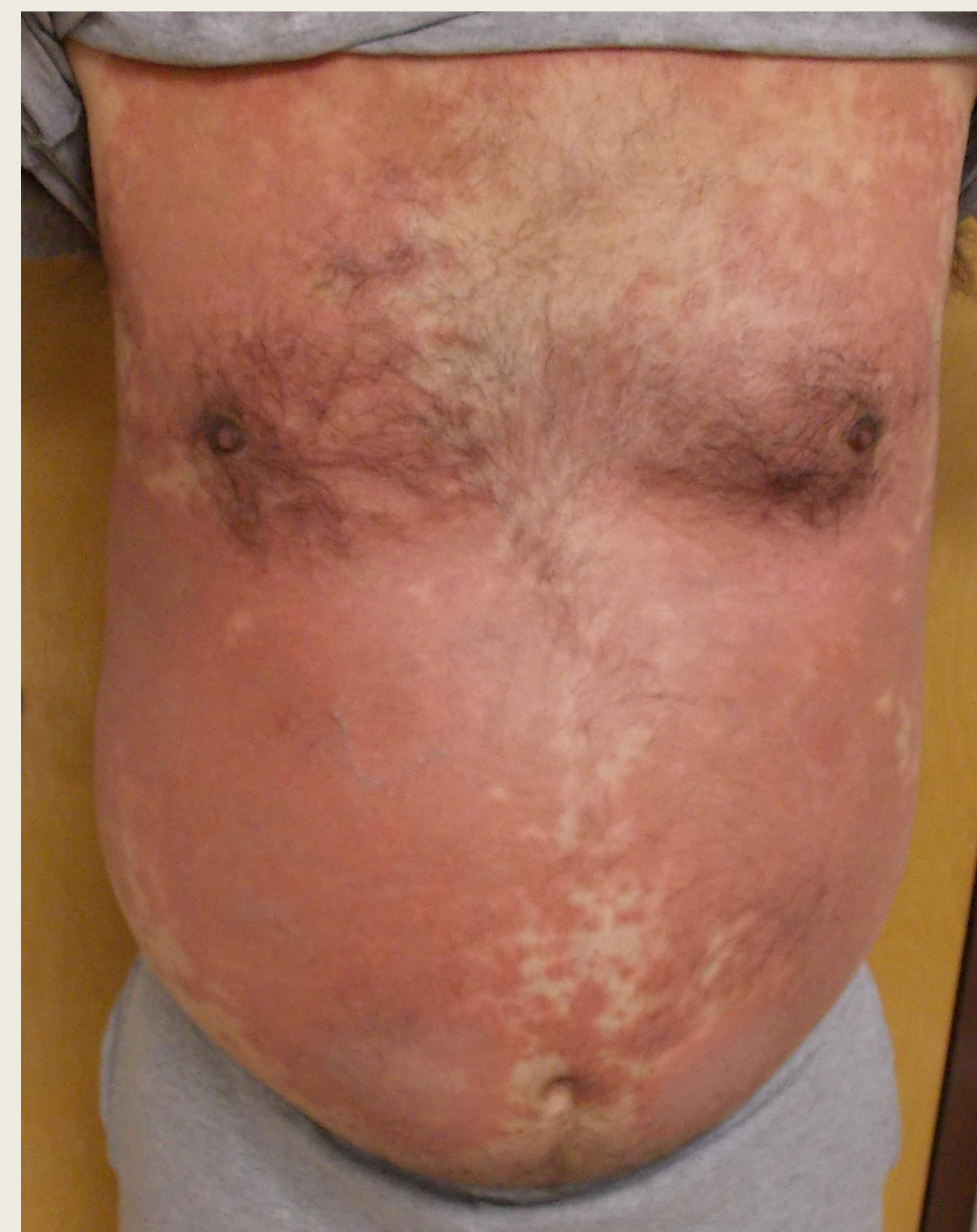
Anthony Worsham, MD

Division of Hospital Medicine, University of New Mexico School of Medicine, Albuquerque, NM

CASE PRESENTATION

HISTORY OF PRESENT ILLNESS:

- A 60-year-old man with a history of hepatitis C and gout presented to the Emergency Department with rash and ataxia.
- He was on week 10 of treatment for hepatitis C with peginterferon alfa-2a, ribavirin, and telaprevir when he presented to his primary care physician 1 week prior with a pruritic erythematous rash starting at his shins.
- He was told to discontinue all his hepatitis C treatment medications.
- In the interim the rash progressed superiorly and involved nearly his entire body, including the face and genitals.
- He also reported a fever.
- The family in addition notes that the patient was having altered mentation with confusion as well as difficulty walking with shaking of his right leg and arm.



WORKUP

PHYSICAL EXAMINATION:

- In the ED he was afebrile at triage but became febrile within hours to a temperature of 39.8°C and tachycardic to 102. He had normal blood pressure and respiration.
- Skin exam showed a diffuse erythematous rash with papules coalescing into plaques involving the forearms, back, abdomen, lower extremities, and face without vesicles. There was also superficial erosion of the hard palate.

LABORATORY VALUES:

- white count of $3.2 \times 10^3/\text{mm}^3$, left shift with 82% neutrophils without eosinophils or atypical lymphocytes
- hemoglobin 11.9 g/dL
- platelets $101 \times 10^3/\text{mm}^3$
- AST 88 U/L
- ALT 59 U/L
- alkaline phosphatase 144 U/L
- total bilirubin 2.1 mg/dL
- normal ESR but elevated CRP to 2.6 mg/dL

STUDIES:

- Blood and urine cultures were obtained on admission and remained negative.
- CT of the head did not show any acute intracranial abnormality.
- Drug screen was negative.
- Lumbar puncture was performed and was unremarkable for infection with negative screens for syphilis, coccidioides, varicella, and herpes.
- Viral serologies were negative for multiple organisms, including Epstein-Barr virus (EBV), HSV, several varieties of Coxsackie virus, adenovirus, RSV, and West Nile.

HOSPITAL COURSE:

- Dermatology was consulted and diagnosed erythema multiforme possibly secondary to a virus versus drug hypersensitivity pending the results of a punch biopsy.
- Gastroenterology was also consulted. They felt strongly that the rash was most consistent with telaprevir.
- He was started on empiric antibiotics and steroids with oral prednisone.
- The punch biopsy finally returned showing "acute spongiotic dermatitis with lymphohistiocytic infiltrate" most consistent with drug eruption.
- In this case, the presence of rash, fever, LFT abnormalities, and persistence of symptoms despite discontinuation of the suspected offending agent is most suggestive of DRESS, and the punch biopsy supported this conclusion.
- With the above treatment, the patient's rash stopped progressing and began to scale over inferiorly to superiorly.
- On follow-up, the patient still reported some residual trouble walking and was referred for outpatient physical therapy.

DISCUSSION

- The treatment of patients with hepatitis C genotype 1, which traditionally consisted of peginterferon and ribavirin, was revolutionized with the addition of the protease inhibitors boceprevir and telaprevir, which increased virologic response rates.
- The key side effects of peginterferon/ribavirin include anemia, thrombocytopenia, and neuropsychiatric symptoms like depression and fatigue.
- The level of cognitive dysfunction noted in the literature does not appear to capture this particular patient's ambulation difficulties. Although there was mention of seizures in the literature as a possible side effect, there was no evidence to support convulsions in this case.
- For telaprevir, skin reactions are common: nearly 56 percent of patients reported rash, 4 percent of them severe, less than 1 percent were DRESS or SJS, and nearly 6 percent of patients discontinuing the regimen due to rash.
- The range of skin reactions with telaprevir is broad and includes Stevens-Johnson syndrome, drug reaction with eosinophilia and systemic symptoms (DRESS), and toxic epidermal necrolysis (TEN).
- The recommended treatment for telaprevir-induced rash per a FDA black-box warning includes immediate discontinuation of telaprevir in addition to stopping pegylated interferon and ribavirin. Topical steroids may be used, although systemic corticosteroids are explicitly not recommended on the prescriber insert.

CONCLUSIONS

- Because community-based physicians are increasingly managing hepatitis C treatment regimens, it is important for hospitalists to be aware of the regimen.
- Telaprevir commonly causes a rash, which can be life-threatening in a small minority of cases and includes SJS, TEN, DRESS, and EM.
- Discontinuation of the offending agent and supportive care are the key treatment interventions, with systemic steroids not recommended by the manufacturer.
- It is important to recognize that symptoms including fever can persist for weeks after the drug is discontinued.

REFERENCES

- Stern RS, Exanthematous Drug Eruptions, *N Engl J Med* 2012; 366: 2492-501.
- INCIVEK™ (telaprevir) prescriber information, http://pi.vrtx.com/files/uspi_telaprevir.pdf