

3-1-2014

Clinical vignette: Acute esophageal necrosis

Aaron Price

Peggy Beeley

Follow this and additional works at: https://digitalrepository.unm.edu/hostpitalmed_pubs

Recommended Citation

Price, Aaron and Peggy Beeley. "Clinical vignette: Acute esophageal necrosis." (2014). https://digitalrepository.unm.edu/hostpitalmed_pubs/20

This Presentation is brought to you for free and open access by the Internal Medicine at UNM Digital Repository. It has been accepted for inclusion in Hospital Medicine by an authorized administrator of UNM Digital Repository. For more information, please contact disc@unm.edu.

Acute Esophageal Necrosis

Aaron J. Price, MD and Peggy Beeley, MD

Department of Medicine University of New Mexico School of Medicine

INTRODUCTION

Acute Esophageal Necrosis (AEN), also known as “Black Esophagus” is a condition which occurs after a sequence of physiologic challenges. The inciting event is diminished blood flow, followed by caustic exposure to gastric contents, ultimately leading to a compromise in the protective function of the esophageal architecture. Susceptible populations include immune compromised and elderly patients.

EPIDEMIOLOGY

Reported incidence of black esophagus is very low, ranging from 0.0125%–0.2%. [1]

DIFFERENTIAL DIAGNOSIS

Melanoma	Acanthosis nigricans
Pseudomelanosis	Melanosis
Coal dust deposition	Corrosive ingestion

MECHANISM / ETIOLOGY

Ischemic phenomenon is viewed by some as the major factor in rapid development of esophageal lesions. Low flow states or shock, atherosclerosis, thromboembolic disease, cardiac arrhythmias, and hypoperfusion as a result of severe lactic acidosis have been implied as possible etiologies.

CASE PRESENTATION

69-year-old male with HIV, Insulin Dependant Diabetes, Parkinsonism, who was recently discharged from the hospital to a skilled nursing facility after being treated for Clostridium Difficile presented to the emergency department with chest pain and nausea, which he attributed to heartburn and receiving an extra dose of HAART. Nitroglycerin SL was given at the skilled nursing facility without any appreciable relief. On evaluation patient revealed 7/10, non-radiating, epigastric pain exacerbated by oral intake. On physical exam patient was afebrile, tachycardic, hypotensive. He appeared pale, cachectic with temporal wasting. Stool guaiac was positive. Pertinent laboratory results included an elevated creatinine and BUN, Low Hgb/Hct, and negative cardiac biomarkers. EKG showed sinus rhythm with no S-T wave changes. Patient was started on pantoprazole drip. The morning after admission patient underwent EGD, which found circumferential pallor and blackening of the mucosa (see picture below) limited to the gastro-esophageal junction, suggestive of acute esophageal necrosis (AEN). Moreover, the patient continued to remain hypotensive in the absence of active hemorrhage or volume loss, this was later attributed to an underlying sepsis. Moving into day two of hospitalization patient reported “blood tinged diarrhea”. An infectious stool work-up found that patient had recurrence of C. Diff and patient was immediately started on high intensity oral Vancomycin, however the patient was not able to tolerate PO administration secondary to dysphagia. Medication delivery was discussed and NG delivery was considered, this was deemed unsafe due to the risk of esophageal perforation in the presence of AEN. IV metronidazole was substituted in the interim despite the presence extreme leukocytosis and sepsis. The patient appeared to have a positive response at which time a repeat EGD was performed which demonstrated near resolution of AEN, after which a complete course of PO vancomycin was started. The patient was discharged shortly after.

TREATMENT

Treatment is primarily supportive care, with intravenous fluids, proton pump inhibitors, nothing taken orally and instituting appropriate anti-microbials/virals/fungals as needed for underlying infections. Potential complications include stricture, perforation, and death. Surgical evaluation should be obtained for the aforementioned complications. Ideally treatment is to find/reverse the inciting event and prevent further physiologic insult.

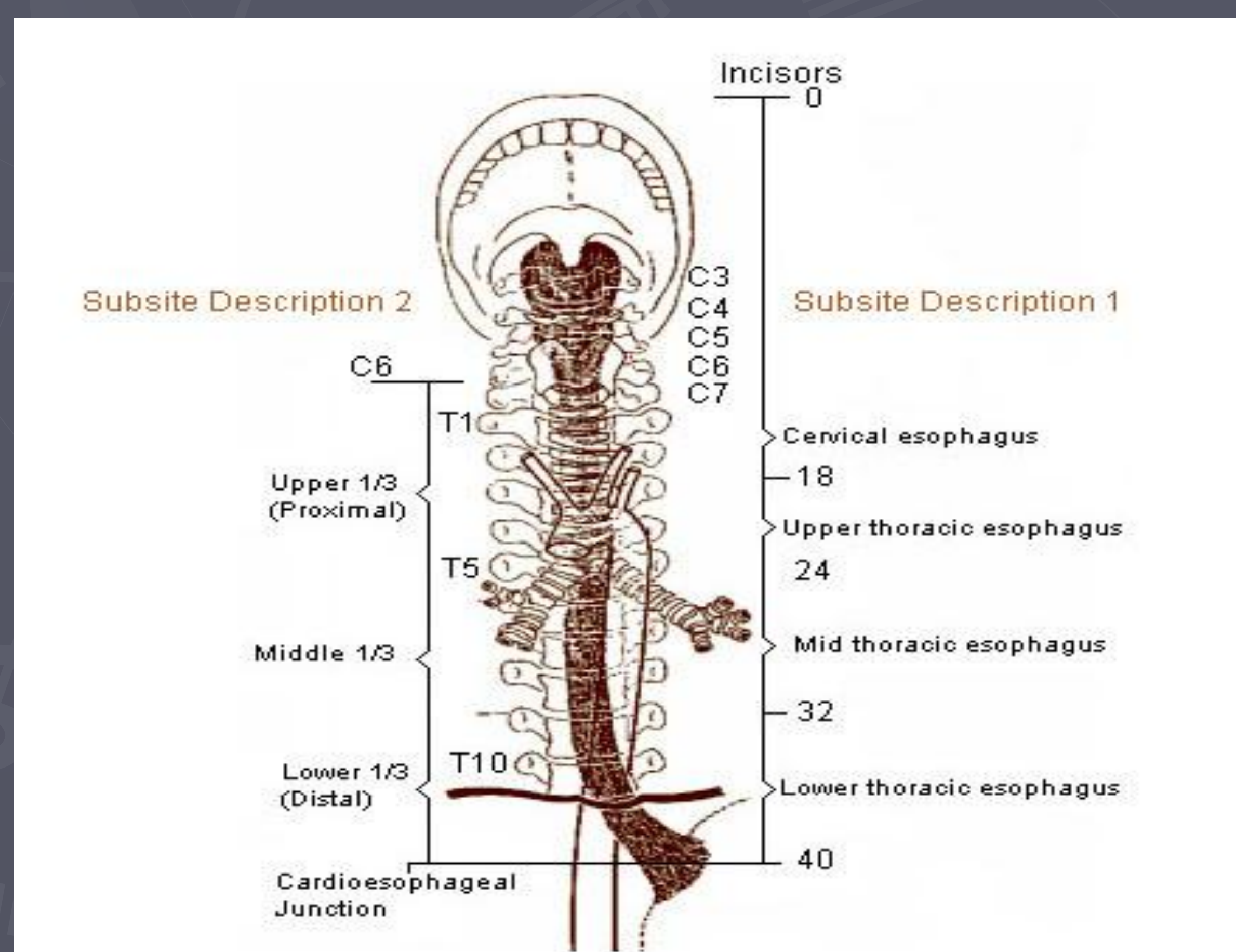
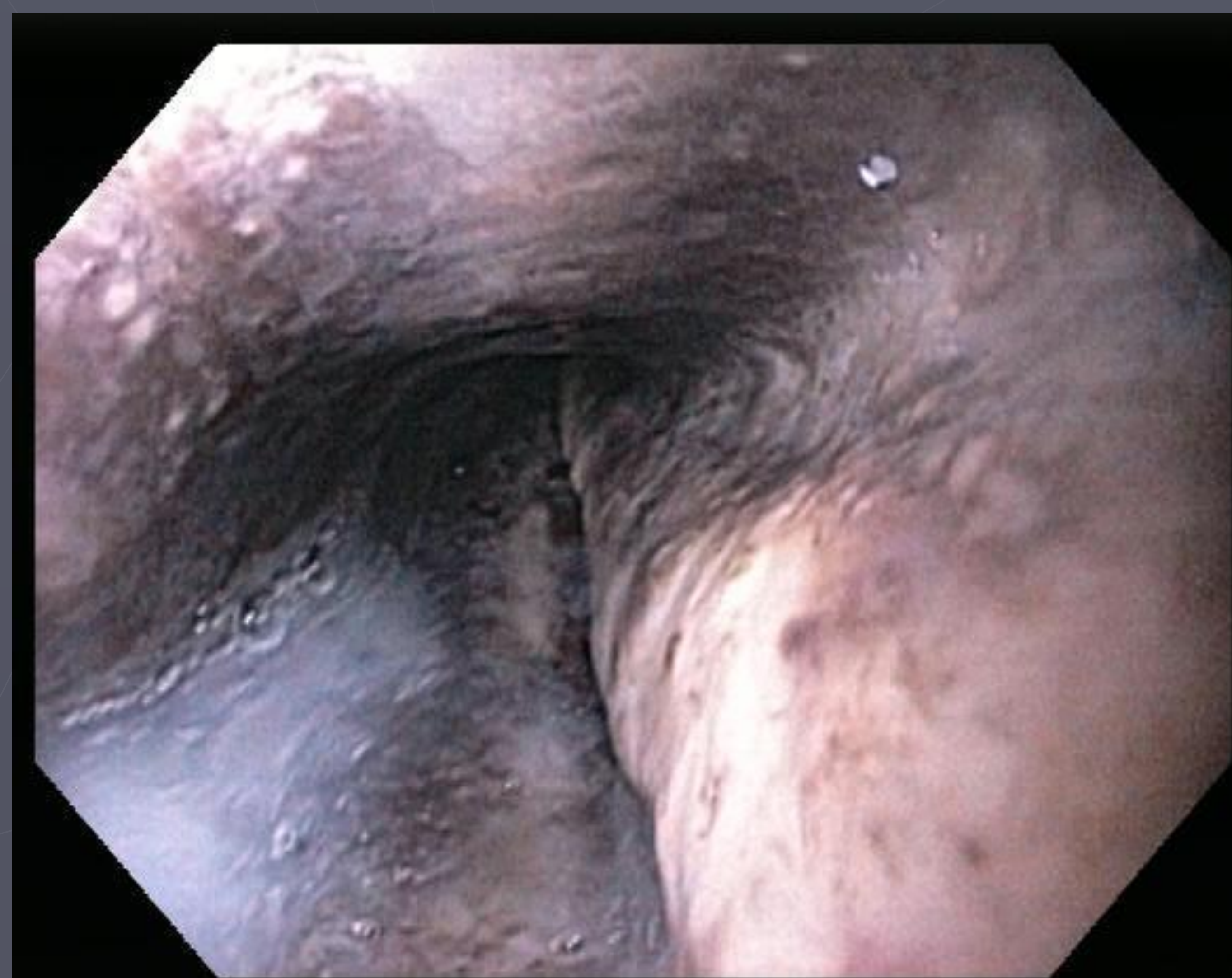PROGNOSIS

Death secondary to esophageal necrosis occurs in less than 6% of cases[3]. Prognosis of black esophagus is very poor, and its mortality reaches up to 31.8%-50%, although most of the deaths were caused by underlying illnesses[3-4].

DISCUSSION

Acute Esophageal Necrosis (AEN), also known as “Black Esophagus” is a condition which occurs after a period of ischemia of the esophagus. On initial evaluation one must identify risk factors, diagnosis, and pathogenesis of the acute esophageal necrosis. Risk factors include age, male sex, heart disease, hemodynamic instability, alcohol ingestion, diabetes, renal insufficiency, and hypercoagulable state. The physiologic insult is often multifactorial, ultimately leading up to ischemic compromise. Discovery of acute esophageal necrosis should be viewed as a poor prognostic factor, and may suggest eminent mortality from the underlying disease process.

Our Patient's Endoscopy



REFERENCE

1. Ben Soussan E, Savoye G, Hochain P, et al. Acute esophageal necrosis: 1-year prospective study. *Gastrointest Endosc* 2002;56:213–217.
2. Grudell AB, Mueller PS, Viggiano TR. Black esophagus: report of six cases and review of the literature, 1963-2003. *DisEsophagus* 2006; 19: 105-110
3. Gurvits GE, Shapsis A, Lau N, Gualtieri N, Robilotti JG. Acute esophageal necrosis: a rare syndrome. *J Gastroenterol* 2007; 42:29-38