

University of New Mexico  
**UNM Digital Repository**

---

Biomedical Sciences ETDs

Electronic Theses and Dissertations

---

5-1-2013

PARTIAL VERSUS COMPLETE  
TRAPEZIECTOMY FOR TREATMENT OF  
CARPOMETACARPAL JOINT ARTHRITIS: A  
CADAVERIC BIOMECHANICAL  
COMPARISON

Deana Mercer

Follow this and additional works at: [https://digitalrepository.unm.edu/biom\\_etds](https://digitalrepository.unm.edu/biom_etds)

---

**Recommended Citation**

Mercer, Deana. "PARTIAL VERSUS COMPLETE TRAPEZIECTOMY FOR TREATMENT OF CARPOMETACARPAL JOINT ARTHRITIS: A CADAVERIC BIOMECHANICAL COMPARISON." (2013). [https://digitalrepository.unm.edu/biom\\_etds/88](https://digitalrepository.unm.edu/biom_etds/88)

This Thesis is brought to you for free and open access by the Electronic Theses and Dissertations at UNM Digital Repository. It has been accepted for inclusion in Biomedical Sciences ETDs by an authorized administrator of UNM Digital Repository. For more information, please contact [disc@unm.edu](mailto:disc@unm.edu).

Deana Mercer, MD

*Candidate*

Department of Orthopaedics

*Department*

This thesis is approved, and it is acceptable in quality and form for publication:

*Approved by the Thesis Committee:*


Rebecca Rogers, MD , Chairperson




Thomas DeCoster , MD



Moheb Moneim, MD



Jonathan Eldredge, PhD



Ron Andrews, PhD



**PARTIAL VERSUS COMPLETE TRAPEZIECTOMY FOR TREATMENT OF  
CARPOMETACARPAL JOINT ARTHRITIS:  
A CADAVERIC BIOMECHANICAL COMPARISON**

**BY**

**DEANA MERCER**

**BACHELOR OF SCIENCE IN BIOCHEMISTRY/CHEMISTRY**

**DOCTOR OF MEDICINE**

**THESIS**

Submitted in Partial Fulfillment of the  
Requirements for the Degree of

**Master of Science**

**Biomedical Science**

The University of New Mexico

Albuquerque, New Mexico

**May, 2013**

## **DEDICATION**

I would like to dedicate this work to my family for their patience with me during the long evening hours spent working on course work and thesis preparation; my husband, James and my children: Allen, Ana, Heather and Thomas.

## ACKNOWLEDGEMENTS

I would like to acknowledge my support team that helped me through this process. This is not an all-inclusive list. I would like to thank my committee Rebecca Rogers, MD, Thomas DeCoster, MD, Moheb Moneim, MD, Jonathan Eldredge, PhD, and Ron Andrews, PhD for their time and dedication to this work.

I thank my chair, Robert Schenck, Jr., MD, Mary Jacintha, Department Administrator, and Kimberly Fields, Research Coordinator, for their time and support.

For my data analysis journey, I thank Clifford Qualls. He was very patient.

Last but not least, I acknowledge Christina Salas and Julie Bowers as without their help, I would not have succeeded.

This project was supported by the National Center for Research Resources and the National Center for Advancing Translational Sciences of the National Institutes of Health through Grant Number 8UL1TR000041.

**Partial Versus Complete Trapeziectomy for Treatment of Carpometacarpal Joint  
Arthritis: A Cadaveric Biomechanical Comparison**

Deana Mercer

Bachelor of Science in Biochemistry/Chemistry

Doctor of Medicine

Submitted in Partial Fulfillment of the  
Requirements for the Degree of

**Master of Science**

**Biomedical Science**

**ABSTRACT**

**Purpose:** We aimed to evaluate the stability of the thumb carpometacarpal joint following either complete removal of the trapezium (TR) or partial removal of the trapezium and of the base of the first metacarpal (PTR). We utilized local capsular tissue for interposition graft in both cases.

**Methods:** Right and left fresh frozen cadaveric hands from the same donor were randomized so that TR or PTR repair was performed randomly on the right or left hand of each pair. In the TR group we removed the entire trapezium. In the PTR group we removed 2mm of distal trapezium and 2mm of thumb metacarpal base. For both repairs, we interposed a capsular tissue graft. The cadaveric hands were stabilized in a jig designed to apply load across six thumb tendons. We measured gap closure distances

prior to and following surgery and examined the joints by radiograph. Distances were measured using the Hough Transform model for measurement of abstract shapes. In order to detect a difference in gap distances between groups of 2mm with an alpha error of 0.05 and a beta error of 0.20, 18 hands were required.

**Results:** The designated surgery was successfully performed on all hands. At baseline, mean gap differences did not vary between groups under load, while after surgery the TR group had greater mean gap closure when compared to the PTR group ( $4.44\text{mm}\pm 1.70$  vs  $2.42\text{mm}\pm 1.92$ ,  $P < .001$ ). No bone on bone contact was noted in any of the operated joints.

**Discussion:** We found that PTR of the thumb basal joint leads to less gap closure of the joint when placed under simulated physiological load when compared to the complete removal of the trapezium.

**Clinical Relevance:** Decreased gap closure under load may lead to preservation of thumb length and stability.

**Key words:** Arthroplasty; thumb; carpometacarpal joints; trapezium; bone osteoarthritis

## TABLE OF CONTENTS

LIST OF FIGURES.....	viii
LIST OF TABLES. ....	ix
INTRODUCTION. ....	1
MATERIALS AND METHODS.....	2
STATISTICAL ANALYSIS AND POWER ANALYSIS.....	6
RESULTS. ....	7
DISCUSSION. ....	11
REFERENCES. ....	14



## LIST OF FIGURES

- Figure 1. This image represents the specimen, loaded within the jig, with all tendons loaded. Note the k-wire markers placed in the first metacarpal and the scaphoid. ....3
- Figure 2. Anterior-posterior view of the thumb carpometacarpal joint after complete resection of the trapezium. Note the circular calibration marker in the image. ....7
- Figure 3. An example of the fluoroscan image after partial resection of the trapezium and partial resection of the metacarpal base.....8
- Figure 4. Hough Transform model to identify all spheres within the image. The sphere on the image denoted by the wide red circle is the sphere of interest. This sphere is a calibration marker of an exact diameter which was used to calculate the number of pixels within the known size of the marker. The number of pixels per known size was used to measure the distance between the two k-wires before and after loading of the joint denoted by the white bracket. The difference in gap before and after loading the thumb was used for the statistical analysis.....9

## LIST OF TABLES

Table 1.	Difference in gap TMC closures among the three reviewers. ....	10
Table 2.	Gap measurements before and after loading of native and treated (TR and PTR) groups.....	11

## **Introduction**

Arthritis of the thumb trapeziometacarpal (TMC) joint is a common, debilitating problem that affects one in four people over the age of 45 with a female predominance. Multiple surgical procedures are described for the treatment of this common problem with varied results. (1-10) These procedures include ligament reconstruction with tendon interposition in conjunction with complete removal of the trapezium, hematoma arthroplasty in conjunction with complete trapezium excision, trapezium or metacarpal osteotomy, partial removal of the trapezium with ligament reconstruction and interposition, implant arthroplasty utilizing varying materials including metal, silicone, sutures of different types and degradable polyurethane urea. Reported complications after trapezium excision for treatment of thumb TMC arthritis include thumb shortening, weakness and hyperextension at the metacarpal phalangeal joint. In addition, joint arthroplasties can be complicated by dislocation, biological reaction to the material, and implant or bone fracture. (11-19) While many procedures alleviate pain, many do not fully restore function and strength. (11, 20) The ideal procedure has not yet been described which alleviates pain and preserves thumb length, stability and strength.

A radiographic surrogate measure of thumb stability is TMC joint gap closure. (21-25) Gap closure is measured as the distance between the distal aspect of the trapezium or scaphoid in the case of trapezium excision, and the base of the first metacarpal. Clinically, a decreasing TMC joint gap distance after bone resection, also defined as proximal thumb migration or metacarpal subsidence, is associated with thumb weakness and instability. While other authors have described partial resection of the trapezium and the use of redundant capsular tissue for capsular interposition (7, 24, 26-28) none have

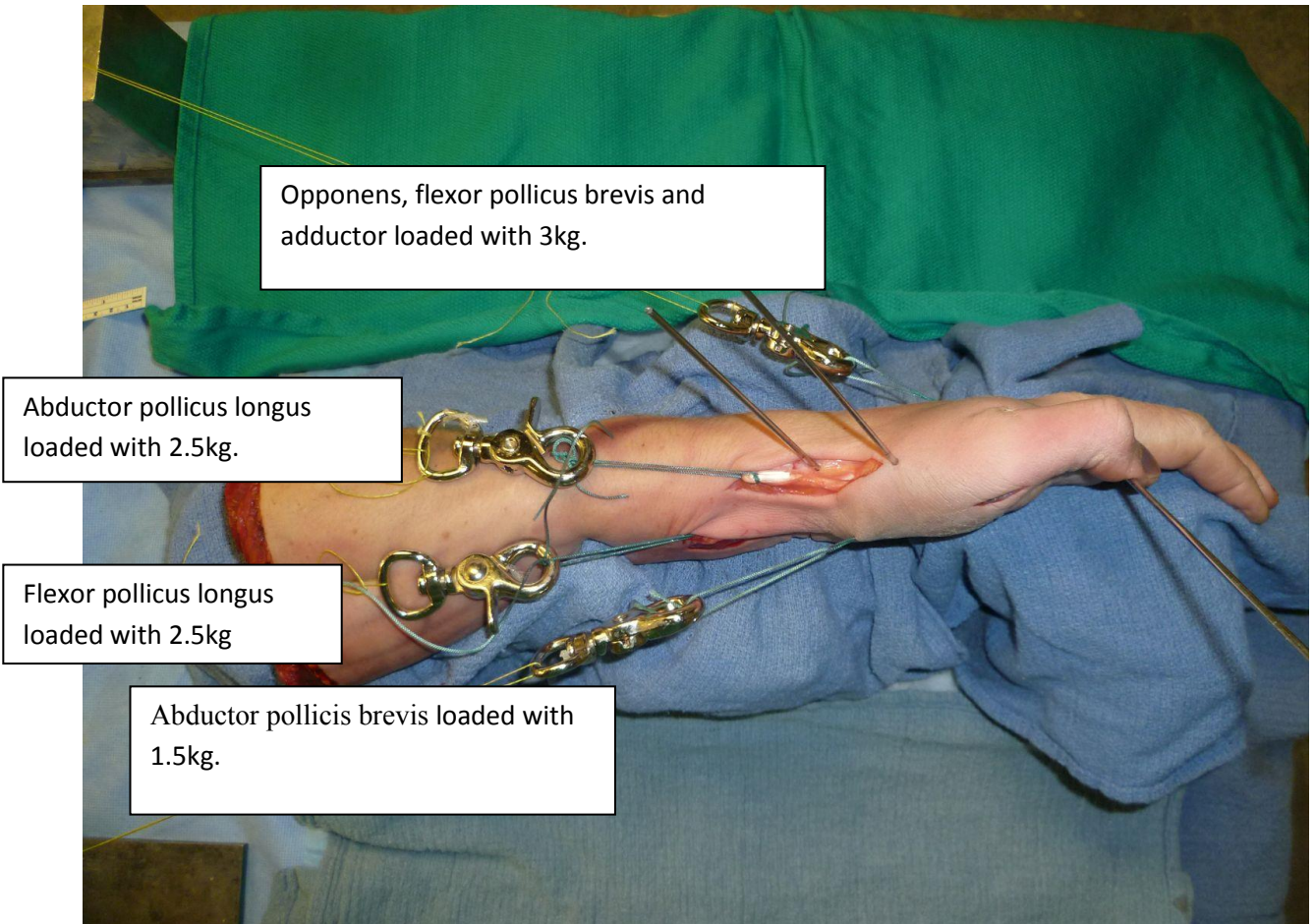
included in their technique resection of the base of the metacarpal. We hypothesize that removal of the irregular arthritic surface of the metacarpal base may lead to better outcomes with improved pain. In this study, we aimed to compare total trapezium resection (TR) to partial trapezium and partial metacarpal resection (PTR) under load in a cadaveric model to determine the differences between the two procedures in the gap closure of the TMC joint, as a surrogate measure of thumb stability. We hypothesize that the change in the gap width between the base of the metacarpal and the proximal carpal bone after PTR will be less than the amount of change in the gap width between the base of the metacarpal and the proximal carpal bone after TR.

### **Materials and methods**

This study was Institutional Review Board exempt (HRRC#12-106). Right and left fresh frozen cadaveric hands were obtained. Each pair was randomized to TR or PTR so that within each pair the right hand had one procedure and the left hand the other procedure performed, which controlled for inherent differences in strength and stability between hands in any given individual pair. Randomization assignment was performed utilizing a computer generated random number program. All TMC joints were imaged prior to commencing the study to ensure the joints were free of degenerative changes. The joints were grossly examined during the procedure to ensure no specimens had arthritic changes in the joint.

A custom built testing device was fabricated to stabilize the wrist and palm while allowing full motion of the thumb TMC joint. The hand was mounted in the testing device with the thumb in the position of lateral pinch. We dissected and tagged, utilizing

a braided suture locking stitch, the flexor pollicis longus (FPL), abductor pollicis longus (APL), abductor pollicis brevis (APB), adductor pollicis(AdP), opponens pollicis (Op) and flexor pollicis brevis (FPB). We loaded these six muscles in line with the direction of muscle fiber pull as described by Cooney and others.(25-27) The FPL was loaded with 2.5kg. The AdP/Op/APB group was loaded with 3kg. The APL, FPB, and EPB were each loaded with 1.5kg.(29-31) (Figure 1) We loaded each of the thumb TMC joints prior to performing the surgical procedures to ensure that there were no baseline differences between groups.



**Figure 1:** This image represents the specimen, loaded within the jig, with all tendons loaded. Note the k-wire markers placed in the first metacarpal and the scaphoid

All procedures were performed by a fellowship-trained hand surgeon. For the both groups, we used a dorsal approach to the thumb TMC joint between the abductor pollicis longus and extensor pollicis brevis. We elevated, in the subperiosteal plane, the soft tissues overlying the proximal third of the thumb metacarpal and trapezium and prepared the specimens for bone resection. Prior to cutting the bone, we measured and marked with a marking pen the amount of bone to be resected and the trajectory of the cut. This ensured accuracy of bone quantity resection and angle of bone cut. In the TR group, we removed the entire trapezium by sharply cutting soft tissue attachments to the trapezium and removing the entire trapezium bone. In the PTR group, we removed 2mm of distal trapezium and 2mm of thumb metacarpal base utilizing an oscillating saw and cutting the two bones parallel to the joint line. This created a 4mm gap in the TMC joint. After both the TR and PTR procedures, local capsular tissue was used for interposition graft by capturing the dorsal, radial and ulnar capsular tissue and interposing it into the TMC joint space with braided non-absorbable suture. We did not capture the flexor carpi radialis or the flexor pollicis longus in the interposition. After removal of the bone and interposition of the local capsular tissue, we repaired the dorsal periosteal sleeve overlying the base of the metacarpal and distal aspect of the trapezium which we carefully preserved during joint exposure. After performing each procedure, the hand was loaded into the testing device and the previously described loading technique was repeated.

As a reference for change in gap distance of the TMC joint, we utilized two K-wires which we securely embedded into the bone of the first metacarpal base and distal scaphoid. The K-wires were placed free of soft tissue tethers. A fluoroscan image was

taken before and after loading of the joint. Each specimen was loaded three times before and after surgery, with an image taken before and after each loading giving a total of twelve fluoroscan images per trial. To account for differences in magnification between images, a metal sphere of 19.05mm in diameter was used as a calibration marker. We utilized the Hough Transform model to calculate the gap distance change in the TMC joint. The Hough Transform model is a program that finds irregular shapes within images stored as pixels. (32) In our application, the Hough Transform model was programmed to find objects that formed circles or parts of circles within the image, so that the program could successfully identify the metal sphere with known diameter. The digital fluoroscan image of the hand was first imported in the program. The program was used to identify all of the circular objects within the image by a red outline and identifies the center of all circles with a cross hatch. We included in all of our images a sphere of known size, 19.05mm. This sphere of known size is converted, by the program, into a quantity of pixels giving us pixels per millimeter. The distance between any other two points in the image can then be measured utilizing this conversion factor when a reviewer identifies, using calipers, two points on the image. The program converts the number of pixels between two points of interest, in our case the two K-wires, into a distance in millimeters.

In order to evaluate inter-rater reader reliability, utilizing the Hough Transform measurement tool, three readers each identified the radius of the metal sphere in each fluoroscan image, which provided the conversion factor of pixels/mm. The second measurement obtained by each reader, and calculated by the program, was the distance

between the K-wires on the image. All measurements were obtained independently by each reader and blinded to the measurements taken by the other readers.

### **Statistical Analysis and Power analysis**

We performed a power analysis prior to conducting this trial utilizing 2 mm as the clinically significant difference in gap closure of the thumb trapeziometacarpal joint based on previously described functional analysis. (29, 30) A sample size of eighteen or nine matched pairs was adequate to detect a 2mm difference between surgical groups with an  $\alpha=0.05$  and Beta error of 0.20.

There were three joint loading trials per specimen before and after the procedure was performed on the TMC joint with a total of 648 comparisons. Three trials were performed and the average of these three trials was utilized for statistical analysis to control for possible measurement error. Three readers measured each image from each trial. The StataC/11.0 statistical program was utilized for the analysis. We first evaluated the data for systematic bias across readers and across trials using ANOVA. To determine if there was systematic error, ANOVA was utilized to evaluate for interactions between readers and between trials; significance was set at  $P \geq 0.05$ . If no bias was encountered, we planned to average measurements across trials and reviewers; if bias was encountered we planned to analyze the data for each individual reviewer and then compare this mean across the three reviewers. The TMC joint gap change in millimeters was averaged for each specimen across the three trials and between the three reviewers. This gap calculation was performed for the native specimens before the procedure was performed and after the PTR and TR procedure was performed. A t-test was utilized to compare the

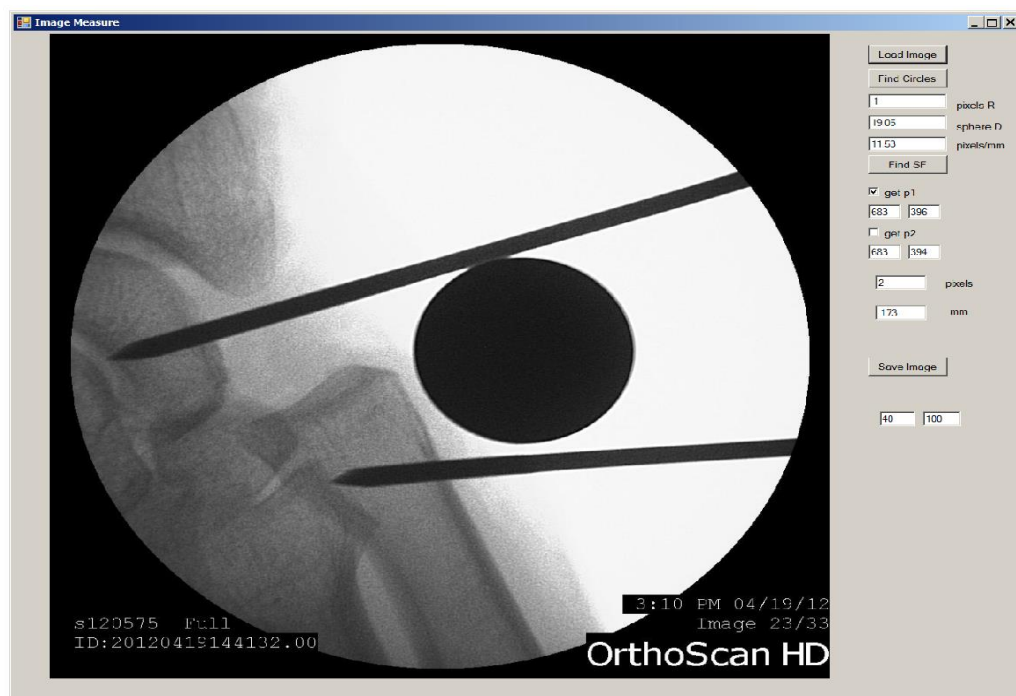


gap measurement means between the native specimens and between the TR and PTR group.

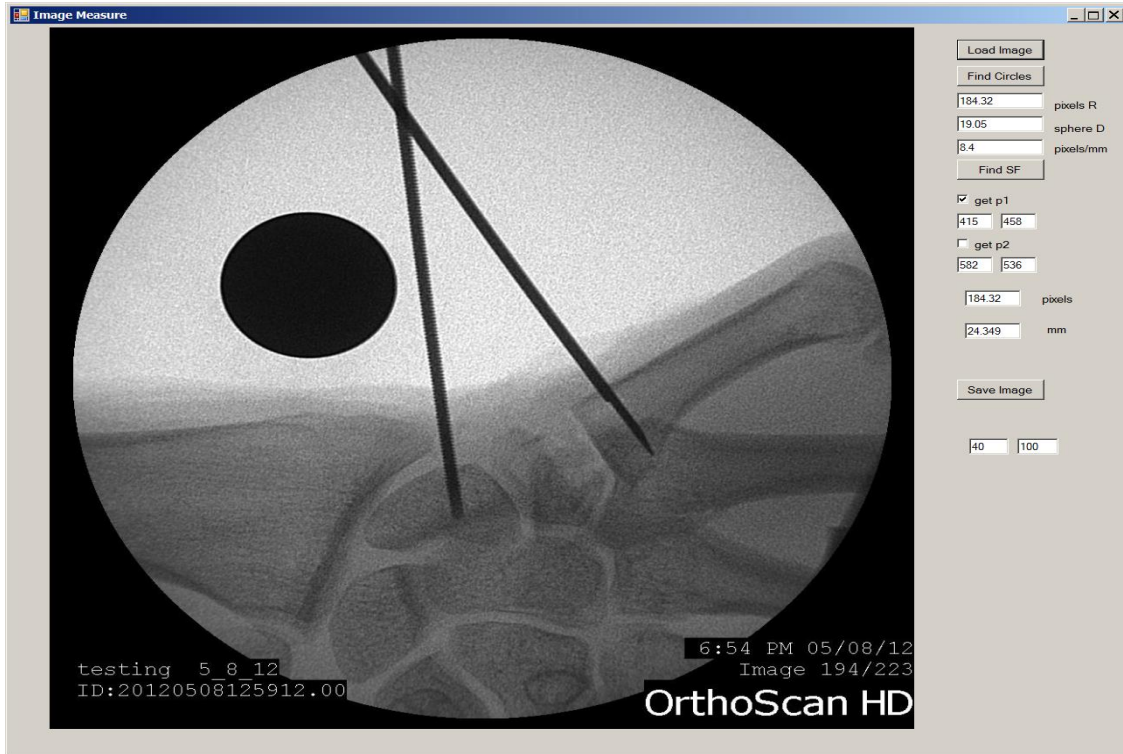
## Results

All TMC joints were found free of degenerative changes both on radiograph and on gross examination, and the assigned surgeries were successfully completed for all specimens.

Radiographs after complete resection of the trapezium and after partial resection of the first metacarpal base and distal aspect of the trapezium with the K-wires and circular calibration marker in place are illustrated in Figures 2 and 3. The Hough Transform model was able to successfully identify the reference sphere of known diameter in all the images.

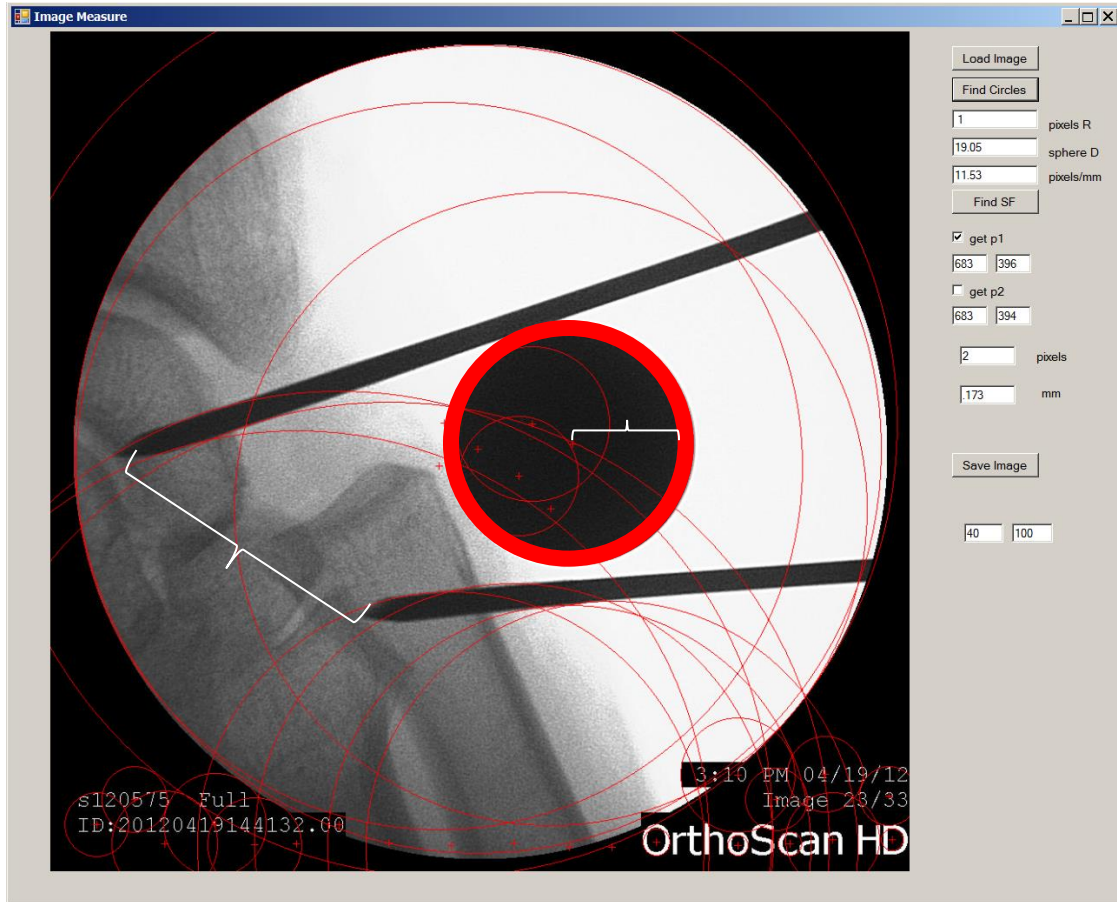


**Figure 2:** Anterior-posterior view of the thumb carpometacarpal joint after complete resection of the trapezium. Note the circular calibration marker in the image.



**Figure 3:** An example of the fluoroscan image after partial resection of the trapezium and partial resection of the metacarpal base.

Figure 4 is an example of the fluoroscan image after application of the model. The red circles within the image represent all circles found by the program within the image; the red circle of interest is the enhanced circle around the metal sphere. Readers were able to measure both the radius of the reference sphere and the distance between the tips of the K wires, in Figure 4 this is denoted by a white bracket.



**Figure 4:** Hough Transform model to identify all spheres within the image. The sphere on the image denoted by the wide red circle is the sphere of interest. This sphere is a calibration marker of an exact diameter which was used to calculate the number of pixels within the known size of the marker. The number of pixels per known size was used to measure the distance between the two k-wires before and after loading of the joint denoted by the white bracket. The difference in gap before and after loading the thumb was used for the statistical analysis.

We found no main effect or interaction between reviewers ( $p=0.98$ ) or between trials ( $p=0.90$ ). We averaged across trials to illustrate the lack of measured difference in gap TMC closures among the three reviewers. (Table 1) We found no difference between gap measurements obtained by each reviewer (t test all with  $p$  value  $\geq 0.88$ ). As there was no difference in measurements between reviewers or across trails, we were able to

average gap difference values across reviewers and trials to compare a single mean pre and post TMC joint loading for each specimen. Baseline gap measurements before and after loading of the native thumb TMC joints (before the procedure was performed on the specimens) was not different between the two arms of the study ( $0.82\pm 1.01$  mm vs  $0.64\pm 0.93$  mm mean gap differences;  $p=0.24$ ). (Table 2)

	<b>Reviewer 1</b>	<b>Reviewer 2</b>	<b>Reviewer 3</b>	<b>Anova p-value</b>
<b>Partial trapezium resection</b>				
<b>Before partial trapezium resection</b>	<b><math>0.9\pm 0.9</math> mm</b>	<b><math>0.7\pm 0.8</math> mm</b>	<b><math>0.9\pm 0.8</math> mm</b>	<b>0.92</b>
<b>After partial trapezium resection</b>	<b><math>2.3\pm 1.8</math> mm</b>	<b><math>2.4\pm 1.8</math> mm</b>	<b><math>2.6\pm 1.8</math> mm</b>	<b>0.96</b>
<b>Total Trapezium Resection</b>				
<b>Before total trapezium resection</b>	<b><math>0.6\pm 0.9</math> mm</b>	<b><math>0.7\pm 0.8</math> mm</b>	<b><math>0.6\pm 0.8</math> mm</b>	<b>0.98</b>
<b>After total trapezium resection</b>	<b><math>4.5\pm 1.6</math> mm</b>	<b><math>4.5\pm 1.7</math> mm</b>	<b><math>4.4\pm 1.7</math> mm</b>	<b>0.88</b>

**Table 1:** This table represents the average in gap closure for each reviewer and for each procedure. There was no difference in the measurements among the reviewers in the native specimens, in the partial resection group or in the total resection group.

Following surgery, gap closure differences between the TR and the PTR group were different after loading. There was greater gap closure in the TR group when compared to the PTR group. ( $4.44\pm 1.70$  mm vs  $2.42\pm 1.92$  mm;  $p=0.03$ ) The mean difference in gap closure between the total and partial resection group was 2 mm ( $\pm 1.82$ ). (Table 2)

	<b>Partial Resection; N=9</b>	<b>Total Resection; N=9</b>	<b>P-value</b>
<b>Before Procedure Native Joint</b>	<b>0.8±0.8 mm</b>	<b>0.6±0.8 mm</b>	<b>0.65</b>
<b>After Procedure</b>	<b>2.4±1.8mm</b>	<b>4.4 ±1.7 mm</b>	<b>0.03</b>

**Table 2:** This table represents the average in gap closure for each reviewer and for each procedure. There was greater gap closure after total resection of the trapezium when compared with partial resection of the trapezium and base of the first metacarpal.

## **Discussion**

We describe a technique of partial trapezium resection and first metacarpal base resection with utilization of local capsular tissue interposition for treatment of thumb TMC joint arthritis and have tested the gap closure distance of operated joints in comparison to total removal of the trapezium. We have demonstrated that in a cadaveric model this technique, when compared to complete trapezium excision, results in a smaller gap distance change under load. This decrease in gap distance in vitro may be important as it may be indicative of a more stable thumb in vivo.

Strengths of our study include randomization of specimens, the inclusion of a comparison group, and meticulous attention to inter-rater reliability of measurements. To control for inherent differences in specimens and that we were unable to attain clinical data for our specimens, we randomized each pair of hands to either TR or PTR. In addition, we compared baseline gap differences between groups in order to ensure that specimen groups were similar prior to surgery. Since measurement of gap differences relies on identification of points on an image by reviewers, we compared readings across

reviewers and across trials to control for these potential differences, and found that there were no significant differences between reviewers or trials, making this method of measuring gap differences reliable in a cadaveric model.

Utilizing a cadaveric model is an inherent limitation of this study. Cadaveric tissue can be variable in quality and we cannot control for the quality of the tissue between specimens. Cadaveric specimens do not have the biological healing which could change the behavior of the thumb TMC joint dynamics. Our model allowed for assessment of gap closure in the linear plane after axial load and did not assess displacement in the three dimensional plane. In vivo, the thumb TMC joint is subject to load in multiple planes by various muscle groups which is not easily reproduced in the laboratory setting. The biomechanics of thumb movement joint variable loading and interplay between bone stability and muscle stability is not well understood and is an area of further research.

The reason for less gap closure in the PTR group is unclear. A large contributor of thumb TMC joint stability is the soft tissue envelope which includes muscles, tendons and capsule. (33) We did not see bone on bone contact after loading of the joint in either the PTR group or in the TR group. However, the removal of the complete trapezium did require extensive soft tissue release to completely excise the bone. This may have disrupted the stabilizing soft tissue envelope surrounding the TMC joint leading to greater settling under load, which resulted in larger gap closure. The partial removal of the trapezium and metacarpal base required much less soft tissue release. Less disruption of this soft tissue envelope may have led to smaller gap closure distances under load. Finally, gap closure is a surrogate measure of thumb stability. While gap closure is found to be increased among individuals with thumb joint arthritis, it is not the

only measure of thumb function, and our proposed surgery needs to be evaluated more fully in operated patients.

Our described surgical technique may offer several advantages. Utilization of local capsular tissue for interposition does not require graft harvest which is required in many other described surgeries for thumb joint surgery. The capsular tissue after removal of 4mm of bone from the TMC joint becomes redundant and is adequate for utilization as an interposition graft into the created joint space. Others have shown that removal of the trapezium can lead to proximal thumb migration and thumb instability. (11, 20, 25, 28, 34) Avoiding removal of the entire trapezium may avoid this complication. The addition of metacarpal base resection may be beneficial in that the irregular, arthritic, eburnated bone, a potential pain generator in patients with TMC arthritis, is removed.

In conclusion, we found in a cadaveric model that partial resection of the distal trapezium and first metacarpal base with local capsular tissue interposition led to decreased gap closures of the thumb joint under load.

## REFERENCES

1. Kuhns CA, Emerson ET, Meals RA. Hematoma and distraction arthroplasty for thumb basal joint osteoarthritis: a prospective, single-surgeon study including outcomes measures. *The Journal of hand surgery*. 2003 May;28(3):381-9. PubMed PMID: 12772092. Epub 2003/05/29. eng.
2. Chang EY, Chung KC. Outcomes of trapeziectomy with a modified abductor pollicis longus suspension arthroplasty for the treatment of thumb carpometacarpal joint osteoarthritis. *Plastic and reconstructive surgery*. 2008 Aug;122(2):505-15. PubMed PMID: 18626369. Epub 2008/07/16. eng.
3. Parker WL, Linscheid RL, Amadio PC. Long-term outcomes of first metacarpal extension osteotomy in the treatment of carpal-metacarpal osteoarthritis. *The Journal of hand surgery*. 2008 Dec;33(10):1737-43. PubMed PMID: 19084172. Epub 2008/12/17. eng.
4. Jorheim M, Isaxon I, Flondell M, Kalen P, Atroshi I. Short-term outcomes of trapeziometacarpal artelon implant compared with tendon suspension interposition arthroplasty for osteoarthritis: a matched cohort study. *The Journal of hand surgery*. 2009 Oct;34(8):1381-7. PubMed PMID: 19683881. Epub 2009/08/18. eng.
5. Martinez de Aragon JS, Moran SL, Rizzo M, Reggin KB, Beckenbaugh RD. Early outcomes of pyrolytic carbon hemiarthroplasty for the treatment of trapezium-metacarpal arthritis. *The Journal of hand surgery*. 2009 Feb;34(2):205-12. PubMed PMID: 19181221. Epub 2009/02/03. eng.



6. Rizzo M, Moran SL, Shin AY. Long-term outcomes of trapeziometacarpal arthrodesis in the management of trapeziometacarpal arthritis. *The Journal of hand surgery*. 2009 Jan;34(1):20-6. PubMed PMID: 19121726.
7. Edwards SG, Ramsey PN. Prospective outcomes of stage III thumb carpometacarpal arthritis treated with arthroscopic hemitrapeziectomy and thermal capsular modification without interposition. *The Journal of hand surgery*. 2010 Apr;35(4):566-71. PubMed PMID: 20189321. Epub 2010/03/02. eng.
8. Sammer DM, Amadio PC. Description and outcomes of a new technique for thumb Basal joint arthroplasty. *The Journal of hand surgery*. 2010 Jul;35(7):1198-205. PubMed PMID: 20610065.
9. Jewell DP, Brewster MB, Arafa MA. Outcomes of silastic trapezium replacements. *Hand surgery : an international journal devoted to hand and upper limb surgery and related research : journal of the Asia-Pacific Federation of Societies for Surgery of the Hand*. 2011;16(3):301-5. PubMed PMID: 22072464. Epub 2011/11/11. eng.
10. Burke NG, Walsh J, Moran CJ, Cousins G, Molony D, Kelly EP. Patient-reported outcomes after Silastic replacement of the trapezium for osteoarthritis. *The Journal of hand surgery, European volume*. 2012 Mar;37(3):263-8. PubMed PMID: 21914695. Epub 2011/09/15. eng.
11. Conolly WB, Rath S. Revision procedures for complications of surgery for osteoarthritis of the carpometacarpal joint of the thumb. *Journal of hand surgery (Edinburgh, Scotland)*. 1993 Aug;18(4):533-9. PubMed PMID: 8409675. Epub 1993/08/01. eng.

12. Ardouin L, Mattelaer B, Villani F, Vaienti L, Merle M. Reconstruction for failed trapeziometacarpal implant. *Techniques in hand & upper extremity surgery*. 2011 Dec;15(4):225-9. PubMed PMID: 22105634. Epub 2011/11/23. eng.
13. McGovern RM, Shin AY, Beckenbaugh RD, Linscheid RL. Long-term results of cemented Steffee arthroplasty of the thumb metacarpophalangeal joint. *The Journal of hand surgery*. 2001 Jan;26(1):115-22. PubMed PMID: 11172377.
14. Hansen TB, Vainorius D. High loosening rate of the Moje Acamo prosthesis for treating osteoarthritis of the trapeziometacarpal joint. *The Journal of hand surgery, European volume*. 2008 Oct;33(5):571-4. PubMed PMID: 18694921.
15. Renfree KJ, Dell PC. Functional outcome following salvage of failed trapeziometacarpal joint arthroplasty. *Journal of hand surgery (Edinburgh, Scotland)*. 2002 Feb;27(1):96-100. PubMed PMID: 11895355.
16. Udeshi M, Bangash H, Gagliardi J. Foreign body giant cell reaction to polytetrafluoroethylene used as interposition material in scaphoid-trapezium arthroplasty. *Australasian radiology*. 2006 Jun;50(3):233-6. PubMed PMID: 16732820. Epub 2006/05/31. eng.
17. Regnard PJ. Electra trapezio metacarpal prosthesis: results of the first 100 cases. *Journal of hand surgery (Edinburgh, Scotland)*. 2006 Dec;31(6):621-8. PubMed PMID: 16928416. Epub 2006/08/25. eng.
18. Athwal GS, Chenkin J, King GJ, Pichora DR. Early failures with a spheric interposition arthroplasty of the thumb basal joint. *The Journal of hand surgery*. 2004 Nov;29(6):1080-4. PubMed PMID: 15576219.

19. Yuan BJ, Moran SL, Tay SC, Berger RA. Trapeziectomy and carpal collapse. *The Journal of hand surgery*. 2009 Feb;34(2):219-27. PubMed PMID: 19181222.
20. Zouzias IC, Doft MA, Uzumcugil A, Rosenwasser MP. Treatment of hyperextension deformity of the thumb metacarpophalangeal joint in basal joint arthritis: a novel technique based on an anatomic study. *Techniques in hand & upper extremity surgery*. 2011 Jun;15(2):119-24. PubMed PMID: 21606786. Epub 2011/05/25. eng.
21. Sakai N. Interposition arthroplasty using trapezium tendon ball for osteoarthritis of the carpometacarpal joint of the thumb. *Techniques in hand & upper extremity surgery*. 2006 Jun;10(2):68-72. PubMed PMID: 16783208. Epub 2006/06/20. eng.
22. Sirotakova M, Figus A, Elliot D. A new abductor pollicis longus suspension arthroplasty. *The Journal of hand surgery*. 2007 Jan;32(1):12-22. PubMed PMID: 17218171.
23. Saffar P, Goffin D, Galbiatti A. [Dynamics of the thumb in arthritis]. *Annales de chirurgie de la main et du membre superieur : organe officiel des societes de chirurgie de la main = Annals of hand and upper limb surgery*. 1990;9(3):212-8. PubMed PMID: 1698086. Epub 1990/01/01. La dynamique de la premiere colonne dans la rhizarthrose. fre.
24. Cox CA, Zlotolow DA, Yao J. Suture button suspensionplasty after arthroscopic hemitrapeziectomy for treatment of thumb carpometacarpal arthritis. *Arthroscopy : the journal of arthroscopic & related surgery : official publication of the Arthroscopy Association of North America and the International Arthroscopy Association*. 2010 Oct;26(10):1395-403. PubMed PMID: 20887938.

25. Belcher HJ, Nicholl JE. A comparison of trapeziectomy with and without ligament reconstruction and tendon interposition. *Journal of hand surgery (Edinburgh, Scotland)*. 2000 Aug;25(4):350-6. PubMed PMID: 11058002.
26. Rai JK, Singh P, Mendonca D, Porter M. Trapeziectomy with a capsular interposition flap. *Annals of the Royal College of Surgeons of England*. 2009 May;91(4):345-6. PubMed PMID: 19434773. Pubmed Central PMCID: PMC2749411. Epub 2009/05/13. eng.
27. Earp BE, Leung AC, Blazar PE, Simmons BP. Arthroscopic hemitrapeziectomy with tendon interposition for arthritis at the first carpometacarpal joint. *Techniques in hand & upper extremity surgery*. 2008 Mar;12(1):38-42. PubMed PMID: 18388753. Epub 2008/04/05. eng.
28. Barron OA, Eaton RG. Save the trapezium: double interposition arthroplasty for the treatment of stage IV disease of the basal joint. *The Journal of hand surgery*. 1998 Mar;23(2):196-204. PubMed PMID: 9556256. Epub 1998/04/29. eng.
29. Koff MF, Zhao KD, Mierisch CM, Chen MY, An KN, Cooney WP, 3rd. Joint kinematics after thumb carpometacarpal joint reconstruction: an in vitro comparison of various constructs. *The Journal of hand surgery*. 2007 May-Jun;32(5):688-96. PubMed PMID: 17482010.
30. Koff MF, Ugwonalu OF, Strauch RJ, Rosenwasser MP, Ateshian GA, Mow VC. Sequential wear patterns of the articular cartilage of the thumb carpometacarpal joint in osteoarthritis. *The Journal of hand surgery*. 2003;28(4):597-604.

31. Kaufman KR, An KN, Litchy WJ, Cooney WP, 3rd, Chao EY. In-vivo function of the thumb muscles. *Clinical biomechanics* (Bristol, Avon). 1999 Feb;14(2):141-50. PubMed PMID: 10619102. Epub 2000/01/05. eng.
32. Ballard DH. Generalizing the Hough Transform to Detect Arbitrary Shapes. *Pattern Recognition*. 1981;13(2):111-22. English.
33. Ladd AL, Lee J, Hagert E. Macroscopic and microscopic analysis of the thumb carpometacarpal ligaments: a cadaveric study of ligament anatomy and histology. *The Journal of bone and joint surgery American volume*. 2012 Aug 15;94(16):1468-77. PubMed PMID: 22992815. Pubmed Central PMCID: PMC3412634. Epub 2012/09/21. eng.
34. Davis TR, Brady O, Dias JJ. Excision of the trapezium for osteoarthritis of the trapeziometacarpal joint: a study of the benefit of ligament reconstruction or tendon interposition. *The Journal of hand surgery*. 2004 Nov;29(6):1069-77. PubMed PMID: 15576217.