

A case report of azathioprine-induced recurrent acute pancreatitis associated with high levels of 6-thioguanine nucleotides in a renal transplant recipient

MAURÍLIO PACHECO-NETO¹, ATECLA N. L. ALVES¹, ALEXANDRE S. FORTINI¹, NAIRO M. SUMITA¹, MARIA E. MENDES¹, LARISSA H. L. TORRES², JOHN A. DULEY³, WILLIAM C. NAHAS⁴, PEDRO R. CHOCAIR⁴

¹Hospital das Clínicas, Medical School, Universidade de São Paulo (HC-FMUSP), Central Laboratory Division, Laboratory of Medical Investigation 03, Department of Clinical Pathology, FMUSP, SP, Brazil

²Department of Toxicology, Pharmaceutical Sciences School, Universidade de São Paulo (USP), SP, Brazil

³School of Pharmacy, University of Queensland, and Mater Medical Research Institute, Brisbane, Australia

⁴Renal Transplantation Unit, HC-FMUSP, SP, Brazil

SUMMARY

Background: Myelotoxicity is the most common side effect associated with the use of azathioprine (AZA) in transplant recipients, while other side effects – rash, nausea, flu-like symptoms, diarrhea, hepatitis, and pancreatitis – are relatively rare. This is the first report of the evolution in a kidney transplant recipient of recurrent acute pancreatitis related to the use of AZA and high levels of 6-thioguanine nucleotide (6-TGN). **Case report:** A 57-year-old Brazilian male renal transplant patient remained stable for 30 years on a maintenance immunosuppressive regimen of AZA and prednisone. The patient experienced three episodes of mild acute pancreatitis in 2004, 2007 and 2008, and despite intensive investigation, AZA was not suspected as the causal agent of pancreatitis. In October 2008 the patient was found to have raised levels of erythrocyte 6-TGN, which resolved rapidly when AZA was interrupted. His maintenance immunosuppression regimen was subsequently changed to mycophenolate mofetil/ tacrolimus/ prednisone. **Discussion:** Despite the classic pharmacogenetic model for thiopurines afforded by thiopurine methyltransferase (TPMT) and highly variable pharmacokinetics, AZA continues to be used empirically, i.e. mg/kg. In transplant recipients, AZA is usually employed as part of polytherapy, which complicates the elucidation of the cause of drug-related side effects. We propose that therapeutic drug monitoring of AZA metabolites is useful for differential diagnosis of the causes of drug-related side effects, such as acute pancreatitis.

Keywords: Azathioprine; renal transplant; pancreatitis; 6-TGN; immunosuppression.

©2012 Elsevier Editora Ltda. All rights reserved.

RESUMO

Relato de caso de pancreatite aguda recorrente induzida por azatioprina associada a altos níveis de nucleotídeos de 6-tioguanina em receptor de transplante renal

Introdução: A mielotoxicidade é o efeito colateral mais comum associado ao uso de azatioprina (AZA) em transplante, enquanto outros efeitos colaterais – erupção cutânea, náusea, sintomas semelhantes à gripe, diarreia, hepatite e pancreatite – são relativamente raros. Apresentamos um primeiro relato sobre a evolução de um receptor de transplante renal com pancreatite aguda recorrente relacionada ao uso de AZA e altos níveis de nucleotídeos de 6-tioguanina (6-TGN). **Relato de caso:** Paciente brasileiro, 57 anos, sexo masculino, transplantado renal em condição estável durante 30 anos com regime imunossupressor de manutenção constituído de AZA e prednisona. O paciente apresentou três episódios de pancreatite aguda leve em 2004, 2007 e 2008, e apesar de intensa investigação, não houve suspeita da AZA como agente causal da pancreatite. Em outubro de 2008 foram encontrados níveis elevados de 6-TGN eritrocitária no paciente, o que se resolveu rapidamente quando a AZA foi interrompida. Seu regime de imunossupressão de manutenção foi posteriormente alterado para micofenolato mofetil/ tacrolimus/ prednisona. **Discussão:** Apesar do modelo farmacogenético clássico para tiopurinas, proporcionado pela tiopurina metiltransferase (TPMT) e farmacocinética altamente variável, a AZA continua a ser usada de forma empírica, ou seja, em mg/kg. Para transplantados, AZA é normalmente usada em politerapias, o que dificulta a elucidação da causa de efeitos colaterais relacionados à terapia medicamentosa. Propomos que o monitoramento de drogas terapêuticas de metabólitos AZA é útil para o diagnóstico diferencial das causas de efeitos colaterais relacionados à droga, como pancreatite aguda.

Unitermos: Azatioprina; transplante renal; pancreatite; 6-TGN; imunossupressão.

©2012 Elsevier Editora Ltda. Todos os direitos reservados

Correspondence to:

Pedro R. Chocair
Hospital Alemão Oswaldo Cruz
Diretoria Clínica
Rua João Julião, 331 – Paraíso
CEP: 01323-903
São Paulo, SP, Brazil
Phone/Fax: +55 (11) 3549-0000
3287-8177
diretoriaclinica@haoc.com.br

Conflict of interest: None.

INTRODUCTION

Azathioprine (AZA) is an immunosuppressant widely used to prevent rejection in organ transplant recipients and to treat auto-immune diseases such as inflammatory bowel disease, lupus, and auto-immune hepatitis. After uptake, AZA is rapidly converted by the action of glutathione to 6-mercaptopurine, then undergoes extensive metabolism following three different routes. The anabolic pathway of hypoxanthine phosphoribosyl transferase converts 6-MP to the active metabolite 6-thioguanine nucleotide (6-TGN), a purine analogue of GTP. Two pathways are catabolic: xanthine oxidase (XO) and thiopurine methyltransferase (TPMT); these are primarily responsible for the inactivation of thiopurines, and the variability in their activity is responsible for either therapeutic ineffectiveness or increased toxicity^{1,2}. Individuals with high TPMT activity may have low 6-TGN levels and poor clinical outcome, while patients with very low TPMT activity may have 6-TGN levels above therapeutic levels and are more susceptible to myelotoxicity, a major side effect associated with the use of AZA in transplantation, while side effects such as rash, nausea, flu-like symptoms, diarrhea, hepatitis, and pancreatitis are relatively uncommon.

Pancreatitis is more frequent in patients with inflammatory bowel diseases³⁻⁵, but has also been reported in patients with other diseases⁶ and occasionally in renal transplant recipients⁷. We describe here the evolution, in a kidney transplant recipient, of recurrent acute pancreatitis related to the use of AZA and high levels of 6-TGN. According to our knowledge, this is the first report of recurrent acute pancreatitis simultaneously with high levels of 6-TGN.

CASE PRESENTATION

The patient was a 57-year-old Brazilian Caucasian man who underwent a renal transplant in 1978, and whose condition had been stable on a maintenance immunosuppressive regimen consisting of 150 mg of AZA (1.6 mg/kg) and 5 mg of prednisone daily. He presented with an episode of mild acute pancreatitis in 2004 with moderate evolution that was not suspected of having AZA as the causal agent.

The patient continued on an uncomplicated course until the beginning of 2007, when he presented with a new episode of acute pancreatitis, which was also mild. On that occasion, it was suspected that the pancreatitis was induced by acitretin, a rare cause of pancreatitis, which was then withdrawn⁸. No other known factor was found despite intensive investigation, and once again AZA was not suspected as the causal agent of pancreatitis. After AZA metabolite assays were performed in 2007 in São Paulo, a routine analysis in October 2008 found elevated levels of 6-TGN and 6-MMP of 1,549 and 6,053 nmol/8x10⁸ RBC, respectively. On that occasion, AZA was then suspected of being the cause of the two previous episodes of pancreatitis and its withdrawal was suggested.

In December 2008, before AZA withdrawal, the patient presented with a new episode of mild acute pancreatitis, with full and fast resolution. On that occasion AZA was interrupted. Two months later AZA was withdrawn, which was accompanied by a decrease in MCV and increase in his leukocyte count (Figure 1). Investigations were again negative for other known causes of acute pancreatitis.

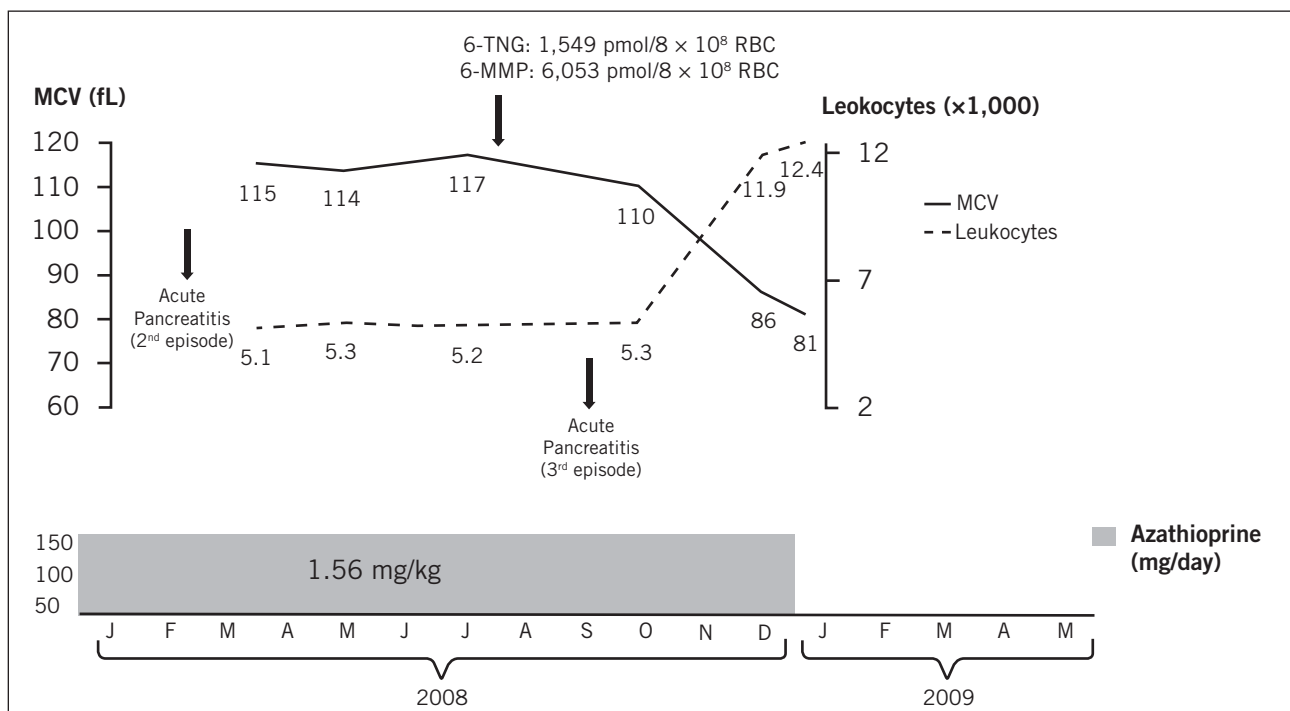


Figure 1 – Patient outcome showing pancreatitis episodes, 6-TGN and 6-MMP levels (nmol/8 x10⁸ RBC), MCV (fL) and leukocyte counts (x 1,000/mm³). Note changes after withdrawal of 150 mg/day of azathioprine.

Throughout this time, the patient maintained normal renal function with plasma creatinine ranging between 1.0 and 1.5 mg/dL and unremarkable further biochemical and clinical parameters. His current maintenance immunosuppression regimen consists of 1,000 mg of mycophenolate mofetil, 2 mg of tacrolimus and 5 mg of prednisone daily.

DISCUSSION

AZA has been used for almost 50 years in renal transplant recipients and despite that, its mechanism of action remains still poorly understood. Even today it is used empirically, i.e. mg/kg, even though the pharmacokinetics is demonstrably variable among individuals, without any correlation with body weight, but related to TPMT genetic status. This case provides the first description of the evolution of recurrent acute pancreatitis in a patient on standard dose AZA accompanied by high levels of 6-TGN.

AZA is used in the treatment of serious illnesses that often require polytherapy, a fact that complicates the elucidation of the cause of drug-related side effects. In the case reported here, the only suspected cause of recurrent acute pancreatitis following extensive investigation was the abnormal result for 6-TGN, apparently disproportionate to the dose used - about 1.5 mg/kg daily for almost thirty years.

This report shows that therapeutic drug monitoring of AZA metabolites can be useful for differential diagnosis of the causes of side effects such as acute pancreatitis and other drug-related side effects, notwithstanding the use of weight-based dosage.

ACKNOWLEDGMENTS

This study was presented in part to the III International Thiopurine Symposium, held at the Instituto de Educação e Ciências, Hospital Alemão Oswaldo Cruz, São Paulo, September 30th – October 2nd, 2010.

REFERENCES

1. Ansari A, Aslam Z, De Sica A, Smith M, Gilshenan K, Fairbanks L, et al. The influence of xanthine oxidase on thiopurine metabolism in Crohn's disease. *Aliment Pharmacol Ther.* 2008;28:749-757.
2. Evans WE. Pharmacogenetics of thiopurine S-methyltransferase and thiopurine therapy. *Ther Drug Monit.* 2004;26:186-191.
3. Bermejo F, Lopez-Sanroman A, Taxonera C, Gisbert JP, Pérez-Calle JL, Vera I, et al. Acute pancreatitis in inflammatory bowel disease, with special reference to azathioprine-induced pancreatitis. *Aliment Pharmacol Ther.* 2008;28:623-628.
4. Weersma RK, Peters FT, Oostenbrug LE, van den Berg AP, van Haastert M, Ploeg RJ, et al. Increased incidence of azathioprine-induced pancreatitis in Crohn's disease compared with other diseases. *Aliment Pharmacol Ther.* 2005;21:195.
5. Paloyan D, Levin B, Simonowitz D. Azathioprine-associated acute pancreatitis. *Digest Dis Sci.* 1977;22:839-840.
6. Guillaume P, Grandjean E, Malè PJ. Azathioprine-associated acute pancreatitis in the course of chronic active hepatitis. *Digest Dis Sci.* 1984;29:78-79.
7. Siwach V, Bansal V, Kumar A, Rao Ch U, Sharma A, Minz M. Post-renal transplant azathioprine-induced pancreatitis. *Nephrol Dial Transplant.* 1999;14:2495-2498.
8. Katz HI, Waalen J, Leach EE. Acitretin in psoriasis: An overview of adverse effects. *J Am Acad Dermatol.* 1999;41:7-12.