

## RVC OPEN ACCESS REPOSITORY – COPYRIGHT NOTICE

This is the peer-reviewed, manuscript version of an article published in *The Veterinary Journal*. The version of record is available from the journal site:

<https://doi.org/10.1016/j.tvjl.2018.02.015>.

© 2018. This manuscript version is made available under the CC-BY-NC-ND 4.0 license

<http://creativecommons.org/licenses/by-nc-nd/4.0/>.

The full details of the published version of the article are as follows:

TITLE: Phenotypic description of cardiac findings in a population of Dogue de Bordeaux with an emphasis on atrial fibrillation

AUTHORS: Gavin McAulay, Kieran Borgeat, Julia Sargent, Paul Mötsküla, Joao Neves, Joanna Dukes-McEwan, Virginia Luis Fuentes

JOURNAL: The Veterinary Journal

PUBLISHER: Elsevier

PUBLICATION DATE: 26 February 2018 (online)

DOI: 10.1016/j.tvjl.2018.02.015

## Original Article

### Phenotypic description of cardiac findings in a population of Dogue de Bordeaux with an emphasis on atrial fibrillation

Gavin McAulay <sup>a,\*</sup>, Kieran Borgeat <sup>b,1</sup>, Julia Sargent <sup>b,2</sup>, Paul Mötsküla <sup>b,3</sup>, Joao Neves <sup>c</sup>, Joanna Dukes-McEwan <sup>c</sup>, Virginia Luis Fuentes <sup>b</sup>

<sup>a</sup> *Cardio-respiratory referrals, New Priory Vets Brighton BN1 8QR, United Kingdom*

<sup>b</sup> *Royal Veterinary College, Department of Clinical Science and Services, Hatfield AL9 7TA, United Kingdom*

<sup>c</sup> *Small Animal Teaching Hospital, Institute of Veterinary Science, University of Liverpool, Chester High Road, Neston CH64 7TE, United Kingdom*

\* Corresponding author. Tel.: +44 1273 540430.

*E-mail address:* cardio@new-priory.com (G. McAulay).

<sup>1</sup> Present address: Langford Vets, University of Bristol, Bristol BS40 5DU, United Kingdom.

<sup>2</sup> Present address: Southern Counties Veterinary Specialists, Ringwood, Hampshire BH24 3JW United Kingdom.

<sup>3</sup> Present address: Anderson Moores Veterinary Specialists, Hursley, Winchester, Hampshire SO21 2LL United Kingdom.

## Highlights

- A retrospective review of Dogue de Bordeaux presenting to the cardiology services of two UK veterinary teaching hospitals was performed.
- Cardiac masses and congenital heart disease, particularly subaortic stenosis, were identified frequently.
- The frequency of supraventricular arrhythmia, specifically fast persistent atrial fibrillation, was high.
- Atrial fibrillation was inconsistently associated with structural heart disease or cardiac chamber enlargement.
- The absence of structural heart disease in some dogs with supraventricular arrhythmia suggests a possible primary arrhythmic mechanism.

## Abstract

The aim of this study was to describe the clinical phenotype of Dogue de Bordeaux (DdB) referred for cardiac investigation, with particular reference to the prevalence of atrial fibrillation and associated features. Review of canine medical records of two United Kingdom veterinary referral hospitals identified 64 DdB with available echocardiographic and electrocardiographic (ECG)/Holter data. Atrial fibrillation was documented in 25 (39%) dogs and supraventricular tachycardia was recorded in five (7.8%) dogs. In a subset of 34 dogs, excluding congenital heart disease ( $n = 17$ ), presence of a cardiac mass ( $n = 7$ ) and non-cardiac neoplasia ( $n = 6$ ), 19 (56%) dogs had atrial fibrillation, with a median heart rate of 200 beats per min (bpm) on presentation. Atrial fibrillation was inconsistently associated with cardiac chamber remodelling, but was frequently associated with systolic dysfunction (13/19, 68.4%) and right sided atrial or ventricular dilatation (14/19, 73.7%) in dogs with atrial fibrillation in this subset. No dogs in this subset had right sided atrial or ventricular dilatation in the absence of supraventricular arrhythmia or systolic dysfunction. The absence of structural heart disease in some dogs with supraventricular arrhythmias suggests that an underlying primary arrhythmic process might be responsible for initiating remodelling, although a primary cardiomyopathy cannot be ruled out.

*Keywords:* Canine; Dogue de Bordeaux; Cardiomyopathy; Supraventricular tachycardia; Subaortic stenosis

## Introduction

The Dogue de Bordeaux (DdB) is a large brachycephalic breed of dog, originating in France. The population and cardiac pathology of DdB in the United

Kingdom (UK) has not been well described; however, anecdotal reports suggest that atrial fibrillation (AF) is prevalent in this breed and a recent study suggested that the breed may have a high incidence of sudden and unexpected death (McAulay et al., 2018). The DdB is affected by a range of cardiac conditions, including subaortic stenosis (SAS), tricuspid dysplasia and dilated cardiomyopathy (DCM) (Borgarelli et al., 2006; Höllmer et al., 2008; Martin et al., 2009; Oliveira et al., 2011; Ohad et al., 2013). A breed predisposition to supraventricular tachyarrhythmia has been suggested (Locatelli et al., 2011). In a study by Ohad et al. (2013), all DdB diagnosed with tricuspid dysplasia had AF.

Atrial fibrillation has a complex pathophysiology, whereby functional and structural mechanisms promote electrical re-entry (Brundel et al., 2005). Atrial fibrillation is frequently associated with heart disease; increased atrial dimensions, inflammation, fibrosis, alterations in autonomic tone and ion channel expression promote development of AF. Large breeds of dog might be predisposed to AF because their atrial dimensions provide the critical atrial mass required to support wavelet re-entry (Moore and Spear, 1987; Guglielmini et al., 2000). Atrial fibrillation in the absence of structural heart disease has been described as 'lone' AF (Menaut et al., 2005). Frequent arrhythmia, including AF, can promote cardiac chamber remodelling and a dilated cardiomyopathy (DCM) phenotype, designated tachycardia-induced cardiomyopathy (Shinbane et al., 1997).

Since AF can be a cause, or consequence, of structural or functional disease, clarifying the association of AF with phenotype may be helpful in defining the underlying disease process. This study sought to describe the phenotype of DdB within

a cardiac referral population, specifically with reference to the prevalence and associated features of AF. We hypothesised that AF is the predominant arrhythmia in DdBs undergoing cardiac investigation and that AF reflects a primary arrhythmia, rather than consequence of structural heart disease. We hypothesised that AF would occur in some dogs in the absence of cardiac chamber remodelling.

## **Materials and methods**

### *Study group*

This study was approved by the Royal Veterinary College Ethics and Welfare Committee, (approval number 1296; date of approval 16th October 2014). The records of The Queen Mother Hospital for Animals, Royal Veterinary College, Hatfield, UK, and Small Animal Teaching Hospital, University of Liverpool, Neston, UK, were searched for DdB presenting to the cardiology services from March 2005 to July 2013. Dogs were excluded if echocardiographic or electrocardiographic (ECG) data were unavailable.

### *Echocardiography*

Echocardiographic examinations were performed as described by Thomas et al. (1993), using a Vivid 7 (GE Healthcare), with simultaneous ECG recording, and reviewed and measured using EchoPAC Clinical Workstation Software (GE Healthcare). Left ventricular measurements were obtained in M-mode using the leading edge to leading edge method (Sahn et al., 1978). The mean of three measurements for dogs in sinus rhythm and five measurements for dogs with arrhythmia were recorded for each variable. Left ventricular systolic and diastolic measurements were normalised to body weight (Cornell et al., 2004). Normalised left ventricular systolic diameter

(LVDsn) measurements exceeding 95% confidence interval (CI) predicted values were defined as a marker of systolic dysfunction ( $LVDsn > 1.26$ ). Normalised left ventricular diastolic diameter (LVDdn) measurements exceeding 95% CI predicted values were defined as a marker of ventricular dilatation ( $LVDdn > 1.85$ ).

The pre-ejection period to ejection time ratio (PEP:ET) was calculated from Doppler interrogation of aortic flow obtained from the left apical five chamber or subcostal view (de Madron, 2015). Left atrial diameter was indexed to aortic diameter (LA:Ao) (Hansson et al., 2002). Right sided dilatation was defined as right ventricular diastolic dimensions exceeding 50% of the diameter of the left ventricle or right atrial dimensions that were subjectively larger than the left atrium in any view (Bright et al., 2005; Menaut et al., 2005; Palermo et al., 2011). If dogs exhibited left ventricular dilatation, right ventricular dilatation was assessed subjectively on the basis of clinical experience.

Pulmonary hypertension (systolic) was diagnosed when Doppler-derived tricuspid regurgitation velocity exceeded 3.1 m/s ( $> 38$  mmHg) (Stepien, 2009) and was classified as mild ( $< 50$  mmHg), moderate ( $\geq 50$  mmHg to  $< 80$  mmHg) or severe ( $\geq 80$  mmHg). The aortic valve, outflow tract and Doppler profile were assessed; velocities  $> 2.5$  m/s were considered to be consistent with SAS (Bussadori et al., 2000; Höllmer et al., 2008). Pulmonic valve morphology was assessed according to Bussadori et al. (2000); pulmonic stenosis was defined by pulmonic velocities  $> 2.25$  m/s.

### *Electrocardiography*

ECG data were collected from the original ECG, Holter, echocardiographic

timing ECG and attending clinicians' records. Holter data were quantitatively analysed by Laboratory Corporations of America, Ambulatory Monitoring Services. For initial analysis, AF and supraventricular tachycardia (SVT) were described collectively as 'supraventricular arrhythmia' (Santilli et al., 2008). Atrial fibrillation was diagnosed when QRS complexes occurred without periodicity in the absence of P waves or flutter waves (Miller et al., 1999). Supraventricular tachycardia was defined as three or more QRS complexes < 0.07 s duration, occurring regularly at an instantaneous rate > 160 beats per min (bpm), paroxysmally or persistently, and deemed to be physiologically inappropriate by the attending clinician or on review of Holter data with reference to the Holter activity diary. Dogs in sinus rhythm with no evidence of paroxysmal supraventricular arrhythmia on review were classed as 'sinus rhythm'. Ventricular arrhythmia was described as 'isolated' if only individual ventricular premature complexes (VPCs) were identified, or 'complex' if couplets, triplets, bigeminy, trigeminy and/or ventricular tachycardia were documented. Dogs with only isolated VPCs on Holter were dichotomised with a cut off of 100 VPCs/24 h.

### *Statistical analysis*

After initial assessment of the whole population, dogs with congenital heart disease, cardiac masses and non-cardiac neoplasia were excluded from further assessment, and the clinical, echocardiographic and ECG findings of the remaining subset (non-CHDN) were explored further.

Statistical analysis was performed using Prism 6 (GraphPad Software). Data were assessed for normality visually and using the D'Agostino and Pearson omnibus normality test. Normally distributed data were expressed as mean  $\pm$  standard deviation

(SD). Non-normally distributed data were expressed as median and inter-quartile range (IQR). Normally distributed, continuous data were assessed by one-way analysis of variance (ANOVA). Non-parametric data were compared using the Kruskal-Wallis test and Dunns multiple comparisons test. Fisher's exact test was used to compare differences in proportions of categorical data. Statistical significance was set at  $P = 0.05$ .

## Results

The study included 64 DdB (Fig. 1). Presenting clinical signs are summarised in Table 1. Six of 64 (9.4%) DdB had a prior diagnosis of non-cardiac neoplasia and were examined to evaluate myocardial function prior to chemotherapy. Seven of 64 (10.9%) DdB had a cardiac mass identified echocardiographically. No dogs with a cardiac mass had a prior diagnosis of non-cardiac neoplasia. Cardiac masses were in variable locations and all were suspected to be neoplastic, but only one case (with haemangiosarcoma) was confirmed using histopathology. Seventeen of 64 DdB were diagnosed with congenital defects. Twelve of 64 (18.8%) had SAS (median velocity 3.47 m/s, IQR 2.6-5.4). Five dogs had other congenital defects, including two with patent ductus arteriosus, and one each with pulmonic stenosis, ventricular septal defect and atrial septal defect.

Supraventricular arrhythmia was identified in 30/64 (46.9%) DdB, persistent AF in 25/64 (39.1%) and SVT in 5/64 (7.8%). Dogs with supraventricular arrhythmia had higher heart rates at presentation, more severe left ventricular dilatation and systolic dysfunction, reduced FS% and increased PEP:ET compared to dogs in sinus rhythm (Table 2). Dogs with supraventricular arrhythmia were more likely to have left and/or



right sided atrial dilatation, or left ventricular dilatation, than those in sinus rhythm ( $P = 0.001$ ). Dogs with right sided atrial or ventricular dilatation had higher heart rates than those without atrial dilatation ( $190 \pm 77$  bpm versus  $125 \pm 52$  bpm;  $P = 0.001$ ). There was no significant difference in the frequency of supraventricular arrhythmia between dogs with or without SAS ( $P = 0.117$ ), other congenital disease ( $P > 0.999$ ), a cardiac mass ( $P = 0.433$ ) or non-cardiac neoplasia ( $P = 0.1094$ ). No dogs with a prior diagnosis of non-cardiac neoplasia had supraventricular arrhythmia.

Systolic dysfunction was observed in 21/64 (32.8%) DdB and left ventricular dilatation in 13/64 (20%) DdB, occurring concurrently in 11/64 (17.2%) cases. Systolic dysfunction was evident in 5/34 (14.7%) DdB classified as having sinus rhythm (no evidence of paroxysmal supraventricular arrhythmia on review). Pulmonary hypertension was documented in 9/64 (14%) DdB, of which 4/9 had right sided atrial or ventricular dilatation. Collapse was reported in 20/64 (31.3%) DdB and was not associated with pulmonary hypertension ( $P = 0.252$ ). Holter data were available for 16/64 (25.0%) DdB, of which 9/16 (56.3%) had AF. Ventricular arrhythmia was detected in 15/64 (23.4%) DdB, of which eight had isolated VPCs and seven had complex arrhythmias (Table 2). Holter data were available for 13/15 (86.7%) dogs with ventricular arrhythmia, with a median of 105 (IQR 5-543) VPCs/24 h. In dogs with isolated VPCs on Holter, 6/7 (85.7%) had less than 100 VPCs/24 h.

In the subset of 34 non-CHDN dogs; 19 (56%) had AF, 12 (35%) had sinus rhythm and three (9%) had SVT, which was paroxysmal in 2/3 dogs (median SVT 240 bpm) (Fig. 2; Table 3). The three dogs with SVT were younger than the 31 dogs with other arrhythmias ( $P = 0.027$ ; Fig. 3). Non-CHDN dogs with AF ( $n = 19$ ) had a median

heart rate of 200 bpm at presentation, with 17/19 (89%) of these dogs having a heart rate  $\geq$  160 bpm. Three (15.8%) non-CHDN dogs with AF did not have any chamber dilatation and were considered not to have structural cardiac heart disease, although one was classified with systolic dysfunction. Only one of these three dogs had a heart rate  $<$  160 bpm (84 bpm). Four non-CHDN dogs in sinus rhythm had systolic dysfunction, with 2/4 demonstrating  $>$ 1000 VPCs/24 h on Holter. Overall, 18/34 (52.9%) non-CHDN dogs demonstrated systolic dysfunction and 18/34 (52.9%) demonstrated right sided dilatation (atrial or ventricular), with 38% showing evidence of both systolic dysfunction and right sided dilatation. Of non-CHDN dogs with AF, 13/19 (68.5%) had systolic dysfunction and 14/19 (73.7%) had right sided dilatation. No non-CHDN dogs in sinus rhythm had right sided dilatation without concurrent systolic dysfunction (Fig. 4). Left heart dilatation and systolic dysfunction were present in 9/34 (26%) non-CHDN dogs and five (55%) of these had AF. Normalised left ventricular dimensions and indexed left atrial dimensions within the non-CHDN dogs are displayed in Fig. 5. Pulmonary hypertension was identified in six non-CHDN dogs, four with mild and two with moderate severity; the latter two had AF and right sided atrial/ventricular dilatation. The prevalence of collapse did not differ between sinus, SVT or AF rhythm ( $P = 0.958$ ).

## Discussion

In this study supraventricular arrhythmias were detected in a high proportion of DdBs assessed by veterinary cardiologists at two UK referral hospitals. Atrial fibrillation was documented in 39% of all DdB. In the non-CHDN subset (DdB without congenital heart disease or neoplasia), the prevalence of atrial fibrillation was 56%. A previous Italian study reported AF in 3/39 (7.7%) apparently healthy DdB (Locatelli et

al., 2011). Since dogs in our study were drawn from a cardiology referral population with a high prevalence of auscultated arrhythmia and exercise intolerance, it is unsurprising that the prevalence of AF in our study was higher than in a general population; however, our findings support the hypothesis that AF is the predominant arrhythmia in DdB undergoing cardiac investigation in the UK.

In the non-CHDN subset, 3/19 DdB with AF had a structurally normal heart. Atrial fibrillation in the absence of structural cardiac disease has been described as 'lone' AF (Takemura et al., 2002; Menaut et al., 2005). However, the term 'lone' AF has been questioned because of inconsistent definition and improved ability to detect predispositions to AF (Wyse et al., 2014). Low heart rates have been reported in dogs with AF without structural or functional heart disease (Menaut et al., 2005). In our study, only one non-CHDN dog with AF without structural or functional disease had a heart rate < 160 bpm on presentation. Whether fast AF rates at presentation reflect more advanced underlying disease, stress or a breed propensity to tachyarrhythmia remains unclear.

Nine of 34 (26%) non-CHDN DdB had increased left heart dimensions and systolic dysfunction, consistent with a dilated cardiomyopathy (DCM) phenotype, and 5/9 (55%) of these dogs had AF. DCM has been characterised by systolic and diastolic dysfunction, and variable ventricular dilatation (Kittleson, 1998; Tidholm et al., 2001), which can precipitate valvular incompetence, atrial dilatation and arrhythmias, particularly AF (Dukes-McEwan et al., 2003). The prevalence of AF in a previous retrospective study of DCM was 45%, with a high prevalence in the Irish wolfhound, Great Dane and Newfoundland (Tidholm and Jönsson, 1996; Vollmar, 2000; Meurs et

al., 2001a; Martin et al., 2009). DCM has been reported previously in the DdB; however, the inconsistent relationship of AF to the DCM phenotype in this population suggests that left ventricular dilatation does not always precede development of AF.

Atrial fibrillation occurs frequently in the Irish wolfhound, with and without DCM, and is reported in up to 87.6% of Irish wolfhounds with a diagnosis of DCM (Vollmar, 2000). Studies in Irish wolfhounds support an association between AF and DCM, which develops in the majority of dogs with AF (Simpson et al., 2016). Whether DCM in the Irish wolfhound reflects a primary cardiomyopathy, atrial dysfunction or sustained tachycardia is unclear (Brownlie and Cobb, 1999). Familial DCM associated with early AF has been reported in human beings (Sébillon et al., 2003), but sustained tachyarrhythmia, including AF, may result in biventricular systolic dysfunction and eccentric dilatation (Wilson et al., 1987; Shinbane et al., 1997; Schoonderwoerd et al., 2001; Dukes-McEwan et al., 2003).

A feature of DdBs in this study was the high frequency of right sided atrial or ventricular dilatation, which were evident in 27/64 (42.1%) of all dogs and over half of non-CHDN dogs in the absence of severe pulmonary hypertension. In a retrospective study of DCM in the Irish wolfhound, predominantly right sided dilatation was reported in 5.4% dogs and right sided changes only in 4.2% of dogs (Vollmar, 2000).

Right ventricular dilatation has been associated with arrhythmogenic right ventricular cardiomyopathy (ARVC) in dogs. In retrospective studies of Boxer cardiomyopathy, 21.5-43% of dogs had right ventricular dilatation (Basso et al., 2004; Palermo et al., 2011). It is possible DdB in this study were affected by a

cardiomyopathy with a predisposition for right sided pathology. A hallmark of ARVC is frequent ventricular arrhythmia, often with complexity, including couplets, triplets and ventricular tachycardia (Meurs et al., 1999; Basso et al., 2004; Palermo et al., 2011). In our study, 15/64 (23.4%) DdBs had documented ventricular arrhythmia; however, since Holter was inconsistently performed, ventricular arrhythmia might have been under-diagnosed. Alternatively, given the high frequency of DdB with AF in our study, some supraventricular QRS complexes may have been erroneously classified as ventricular because of intermittent aberrant conduction with bundle branch block, despite manual Holter review. Ventricular arrhythmia has been documented in 32% of apparently normal dogs (Meurs et al., 2001b), with normal Dobermans and Boxers reportedly having a ventricular burden  $< 50$  and  $< 91$  VPCs/24 h, respectively (Stern et al., 2010; Wess et al., 2010). On the basis of a dichotomised cut-off of 100 VPCs/24 h, approximately half of the DdB with ventricular arrhythmia in our study had isolated arrhythmia of a low frequency.

Atrial fibrillation has been described previously in DdBs with tricuspid dysplasia (Ohad et al., 2013). Tricuspid dysplasia in dogs has been defined by echocardiographic characteristics including leaflet thickening, tethering and valvular insufficiency, as assessed by right atrial dilatation and regurgitant jet area (Bonagura et al., 1999; Oyama and Sisson, 2001; Ohad et al., 2013). In human beings, functional tricuspid insufficiency due to annular distortion and alterations in papillary muscle geometry has been reported to be secondary to right and left ventricular dilatation, systolic dysfunction and respiratory phase (Rogers and Bolling, 2009; Topilsky et al., 2014; Tornos Mas et al., 2015). The assessment of tricuspid insufficiency by regurgitant jet area has been discouraged because of technical limitations (Lancellotti et al., 2010).

Alterations in papillary muscle geometry result in the echocardiographic appearance of leaflet tethering and reduced valvular coaptation (Spinner et al., 2012). In human beings with chronic AF in the absence of organic heart disease, the development and severity of tricuspid regurgitation has been associated with AF type and duration (Najib et al., 2011; Park et al., 2015). In view of the unknown influence of these factors in dogs, we could not confidently define normal or dysplastic tricuspid morphology and only described right sided dilatation. Although many DdBs with AF displayed right sided atrial or ventricular dilatation and systolic dysfunction, no non-CHDN dogs had right sided dilatation without supraventricular arrhythmia or systolic dysfunction (Fig. 4). This observation suggests that right sided dilatation might reflect cardiac dysfunction rather than primary valvular disease in some DdBs.

Five dogs in our study had supraventricular tachycardia (one persistent and four paroxysmal). Although the number of dogs with SVT was small, the three non-CHDN dogs with SVT were younger than dogs with sinus rhythm and AF. In dogs, SVT has been associated with structural heart disease and systemic disease (Kittleson, 1998; Finster et al., 2008). Atrial pathology predisposing to supraventricular arrhythmia has been described in association with ARVC (Fox et al., 2000; Basso et al., 2004; Mano et al., 2013; Vila et al., 2017), and SVT has been reported in Boxers with ARVC (Baumwart et al., 2005). In human beings, paroxysmal SVT is closely associated with paroxysmal AF and it has been suggested that SVT might predispose to AF development because of atrial stretch, reduced atrial refractoriness and vagal activation during tachycardia (Chang et al., 2008). Focal atrial tachycardia (FAT) was reported in two DdB in a series of 16 dogs diagnosed with FAT by electrophysiological study (Santilli et al., 2010). Seven of these dogs had a surface ECG diagnosis of AF. The

authors noted that FAT occurred in younger dogs, as reported in this study, and that FAT predominantly originated within the right atrium. Of the three non-CHDN dogs with SVT in our study, 2/3 had right sided dilatation potentially supportive of right sided pathology (Figs. 4 and 5). Although our study cannot clarify any temporal relationship between arrhythmia types, it is possible that SVT might precede and degenerate into AF in some DdB.

Additional findings in this retrospective study included the identification of cardiac masses in 7/64 (10.9%) DdB and increased aortic velocities, consistent with SAS, in 12/64 (18.8%) DdB. The high prevalence of increased aortic velocities is consistent with Danish and Israeli studies, which reported subaortic stenosis in 17% and 24% of DDBs in screened and referral populations, respectively (Höllmer et al., 2008; Ohad et al., 2013).

Our study has several limitations, inherent in any retrospective studies. The inclusion of dogs with concurrent disease might influence heart rate and rhythm, and no account was taken of the potential influence of medications on heart rate or cardiac dimensions. We elected to use normalised left ventricular M-mode measurements and defined values exceeding 95% CI predicted values to categorise left ventricular dimensions and systolic function because of the availability of these images. There are acknowledged limitations of M-mode measurements and it would have been preferable to have assessed left ventricular dimensions and function by calculation of end systolic volume index using Simpson's method of discs (Lang et al., 2005; Tidholm et al., 2010). The use of 95% CI predicted values determined by the Cornell method may be insensitive because of the wide prediction intervals. Quantitative evaluation of right

sided dimensions would have been preferable; however, the retrospective nature of this study meant that images optimised for right sided evaluation were rarely available. Our inability to more clearly define the presence and magnitude of right sided dilatation is a substantial limitation.

Holter ECG was inconsistently available and this may have limited our ability to obtain representative heart rates. Some cases presenting with sinus rhythm may have had unidentified paroxysmal supraventricular arrhythmia, predisposing to systolic dysfunction or chamber dilatation; our definition of SVT may include some dogs with sinus tachycardia. No cases had an electrophysiological study to clarify the mechanism of arrhythmia, so some rhythms may have been misclassified on surface ECG.

## **Conclusions**

In this UK referral population of DdB, cardiac masses and subaortic stenosis were relatively frequent. The prevalence of supraventricular arrhythmia, specifically fast AF with ventricular response rate exceeding 160 bpm, was high. Atrial fibrillation was associated with cardiac chamber dilatation in the majority of dogs. Most dogs with atrial fibrillation had right sided dilatation and systolic dysfunction; however, this was inconstantly associated with left ventricular dilatation or a DCM phenotype. After excluding dogs with congenital heart disease and neoplasia, no remaining dogs had right sided dilatation in the absence of supraventricular arrhythmia or systolic dysfunction. In view of the subjective classification of right sided dilatation in this retrospective study, any inferences drawn from these observations should be viewed cautiously. Potential aetiologies include primary cardiomyopathy with right sided predilection and/or predisposition to supraventricular arrhythmia with cardiac



remodelling secondary to tachycardia-induced cardiomyopathy. Since some cardiomyopathies may be associated with a propensity for supraventricular arrhythmia, these mechanisms may not be mutually exclusive. Serial echocardiographic and Holter studies may help to clarify if supraventricular arrhythmia typically develops as a consequence of chamber dilatation, or if it precedes cardiac chamber remodelling in the DdB, and whether the findings from this small study are representative of the wider DdB population.

#### **Conflict of interest statement**

None of the authors of this paper have a financial or personal relationship with other people or organisations that could inappropriately influence or bias the content of the paper.

#### **Acknowledgements**

Preliminary results were presented at the Veterinary Cardiovascular Society Meeting at the British Small Animal Veterinary Association Congress, Birmingham, UK, 5 April 2017.

## References

- Basso, C., Fox, P.R., Meurs, K.M., Towbin, J.A., Spier, A.W., Calabrese, F., Maron, B.J., Thiene, G., 2004. Arrhythmogenic right ventricular cardiomyopathy causing sudden cardiac death in boxer dogs: A new animal model of human disease. *Circulation* 109, 1180-1185.
- Baumwart, R.D., Meurs, K.M., Atkins, C.E., Bonagura, J.D., DeFrancesco, T.C., Keene, B.W., Koplitz, S., Fuentes, V.L., Miller, M.W., Rausch, W., et al., 2005. Clinical, echocardiographic, and electrocardiographic abnormalities in Boxers with cardiomyopathy and left ventricular systolic dysfunction: 48 cases (1985-2003). *Journal of the American Veterinary Medical Association* 226, 1-3.
- Bonagura, J., Lehmkuhl, L.B., Lehmkuhl, L., 1999. Congenital heart disease. In: Fox, P.R., Sisson, D.D., Moise, S. (Eds). *Textbook of Canine and Feline Cardiology*. Saunders, St Louis, MO, USA, pp. 471-535.
- Borgarelli, M., Santilli, R.A., Chiavegato, D., D'Agnolo, G., Zanatta, R., Mannelli, A., Tarducci, A., 2006. Prognostic indicators for dogs with dilated cardiomyopathy. *Journal of Veterinary Internal Medicine* 20, 104-110.
- Bright, J.M., Martin, J.M., Mama, K., 2005. A retrospective evaluation of transthoracic biphasic electrical cardioversion for atrial fibrillation in dogs. *Journal of Veterinary Cardiology* 7, 85-96.
- Brownlie, S.E., Cobb, M.A., 1999. Observations on the development of congestive heart failure in Irish wolfhounds with dilated cardiomyopathy. *Journal of Small Animal Practice* 40, 371-377.
- Brundel, B.J.J.M., Melnyk, P., Rivard, L., Nattel, S., 2005. The pathology of atrial fibrillation in dogs. *Journal of Veterinary Cardiology* 7, 121-129.
- Bussadori, C., Amberger, C., Le Bobinnec, G., Lombard, C.W., 2000. Guidelines for the echocardiographic studies of suspected subaortic and pulmonic stenosis. *Journal of Veterinary Cardiology* 2, 15-22.
- Chang, S., Tai, C., Lin, Y., Lo, L., Tuan, T., Udyavar, A.R., Tsao, H., Hsieh, M., Hu, Y., Chiang, S., et al., 2008. Electrophysiological characteristics and catheter ablation in patients with paroxysmal supraventricular tachycardia and paroxysmal atrial fibrillation. *Journal of Cardiovascular Electrophysiology* 19, 367-373.
- Cornell, C.C., Kittleson, M.D., Torre, Della, P., Haggstrom, J., Lombard, C.W., Pedersen, H.D., Vollmar, A., Wey, A., 2004. Allometric scaling of M-mode cardiac measurements in normal adult dogs. *Journal of Veterinary Internal Medicine* 18, 311-321.
- de Madron, É., 2015. Global left ventricular systolic function assessment, in: de Madron, E., Chetboul, V., Bussadori, C. (Eds), *Clinical Echocardiography of the Dog and Cat*. Elsevier, St Louis, MO, USA, pp. 111-125.

- Dukes-McEwan, J., Borgarelli, M., Tidholm, A., 2003. Proposed guidelines for the diagnosis of canine idiopathic dilated cardiomyopathy. *Journal of Veterinary Cardiology* 5, 7-19.
- Finster, S.T., DeFrancesco, T.C., Atkins, C.E., Hansen, B.D., Keene, B.W., 2008. Supraventricular tachycardia in dogs: 65 cases (1990-2007). *Journal of Veterinary Emergency and Critical Care* 18, 503-510.
- Fox, P.R., Maron, B.J., Basso, C., Liu, S.K., Thiene, G., 2000. Spontaneously occurring arrhythmogenic right ventricular cardiomyopathy in the domestic cat: A new animal model similar to the human disease. *Circulation* 102, 1863-1870.
- Guglielmini, C., Chetboul, V., Pietra, M., Pouchelon, J.L., Capucci, A., Cipone, M., 2000. Influence of left atrial enlargement and body weight on the development of atrial fibrillation: Retrospective study on 205 dogs. *The Veterinary Journal* 160, 235-241.
- Hansson, K., Haggstrom, J., Kwart, C., Lord, P., 2002. Left atrial to aortic root indices using two-dimensional and M-mode echocardiography in Cavalier King Charles spaniels with and without left atrial enlargement. *Veterinary Radiology* 43, 568-575.
- Harpster, N.K., 1991. Boxer cardiomyopathy. A review of the long-term benefits of antiarrhythmic therapy. *Veterinary Clinics of North America: Small Animal Practice* 21, 989-1004.
- Höllmer, M., Willesen, J.L., Jensen, A.T., Koch, J., 2008. Aortic stenosis in the Dogue de Bordeaux. *Journal of Small Animal Practice* 49, 432-437.
- Kittleson, M.D., 1998. Primary myocardial disease leading to chronic myocardial failure. In: Kittleson, M.D., Kienle, R.D. (Eds). *Small Animal Cardiovascular Medicine*. Mosby, St Louis, MO, USA, pp. 319-346.
- Lancellotti, P., Moura, L., Pierard, L.A., Agricola, E., Popescu, B.A., Tribouilloy, C., Hagendorff, A., Monin, J.-L., Badano, L., Zamorano, J.L., 2010. European Association of Echocardiography recommendations for the assessment of valvular regurgitation. Part 2: mitral and tricuspid regurgitation (native valve disease). *European Journal of Echocardiography* 11, 307-332.
- Lang, R.M., Bierig, M., Devereux, R.B., Flachskampf, F.A., Foster, E., Pellikka, P.A., Picard, M.H., Roman, M.J., Seward, J., Shanewise, J.S., et al., 2005. Recommendations for chamber quantification: A report from the American Society of Echocardiography's Guidelines and Standards committee and the Chamber Quantification Writing Group, developed in conjunction with the European Association of Echocardiography, a branch of the European Society of Cardiology. *Journal of the American Society of Echocardiography* 18, 1440-1463.

- Locatelli, C., Santini, A., Bonometti, G.A., Palermo, V., Scarpa, P., Sala, E., Brambilla, P.G., 2011. Echocardiographic values in clinically healthy adult Dogue de Bordeaux dogs. *Journal of Small Animal Practice* 52, 246-253.
- McAulay, G., Borgeat, K., Fuentes, V.L., 2018. An online health survey of Dogue de Bordeaux owners and breeders with special emphasis on cardiac disease. *The Veterinary Journal* 232, 78-82.
- Mano, H., Watanabe, I., Okumura, Y., Sonoda, K., Nagashima, K., Nakai, T., Ohkubo, K., Kofune, T., Haruta, H., Kofune, M., et al., 2013. Atrial tachycardia in a patient with arrhythmogenic right ventricular cardiomyopathy/dysplasia. *Journal of Arrhythmia* 29, 238-241.
- Martin, M.W.S., Stafford Johnson, M.J., Celona, B., 2009. Canine dilated cardiomyopathy: A retrospective study of signalment, presentation and clinical findings in 369 cases. *Journal of Small Animal Practice* 50, 23-29.
- Menaut, P., Bélanger, M.C., Beauchamp, G., Ponzio, N.M., Moïse, N.S., 2005. Atrial fibrillation in dogs with and without structural or functional cardiac disease: A retrospective study of 109 cases. *Journal of Veterinary Cardiology* 7, 75-83.
- Meurs, K.M., Miller, M.W., Wright, N.A., 2001a. Clinical features of dilated cardiomyopathy in Great Danes and results of a pedigree analysis: 17 cases (1990-2000). *Journal of the American Veterinary Medical Association* 218, 729-732.
- Meurs, K.M., Spier, A.W., Miller, M.W., Lehmkuhl, L., Towbin, J.A., 1999. Familial ventricular arrhythmias in Boxers. *Journal of Veterinary Internal Medicine* 13, 437-439.
- Meurs, K.M., Spier, A.W., Wright, N.A., Hamlin, R.L., 2001b. Use of ambulatory electrocardiography for detection of ventricular premature complexes in healthy dogs. *Journal of the American Veterinary Medical Association* 218, 1291-1292.
- Miller, M.W., Tilley, L.P., Smith, K.F.W., Fox, P., 1999. Electrocardiography. In: Fox, P.R., Sisson, D.D., Moise, S. (Eds). *Textbook of Canine and Feline Cardiology*. Saunders, St Louis, MO, USA, pp. 67-105.
- Moore, E.N., Spear, J.F., 1987. Electrophysiological studies on atrial fibrillation. *Heart Vessels Supplement* 2, 32-39.
- Najib, M.Q., Vinales, K.L., Vittala, S.S., Challa, S., Lee, H.R., Chaliki, H.P., 2011. Predictors for the development of severe tricuspid regurgitation with anatomically normal valve in patients with atrial fibrillation. *Echocardiography* 29, 140-146.
- Ohad, D.G., Avrahami, A., Waner, T., David, L., 2013. The occurrence and suspected mode of inheritance of congenital subaortic stenosis and tricuspid valve dysplasia in Dogue de Bordeaux dogs. *The Veterinary Journal* 197, 351-357.

- Oliveira, P., Domenech, O., Silva, J., Vannini, S., Bussadori, R., Bussadori, C., 2011. Retrospective review of congenital heart disease in 976 dogs. *Journal of Veterinary Internal Medicine* 25, 477-483.
- Oyama, M.A., Sisson, D.D., 2001. Evaluation of canine congenital heart disease using an echocardiographic algorithm. *Journal of the American Animal Hospital Association* 37, 519-535.
- Palermo, V., Stafford Johnson, M.J., Sala, E., Brambilla, P.G., Martin, M.W.S., 2011. Cardiomyopathy in Boxer dogs: A retrospective study of the clinical presentation, diagnostic findings and survival. *Journal of Veterinary Cardiology* 13, 45-55.
- Park, J.-H., Shin, S.-H., Lee, M.-J., Lee, M.-D., Shim, H.-I., Yoon, J., Oh, S., Kim, D.-H., Park, S.-D., Kwon, S.-W., et al., 2015. Clinical and echocardiographic factors affecting tricuspid regurgitation severity in the patients with lone atrial fibrillation. *Journal Cardiovascular Ultrasound* 23, 136-7.
- Rogers, J.H., Bolling, S.F., 2009. The tricuspid valve: Current perspective and evolving management of tricuspid regurgitation. *Circulation* 119, 2718-2725.
- Sahn, D.J., DeMaria, A., Kisslo, J., Weyman, A., 1978. Recommendations regarding quantitation in m-mode echocardiography: Results of a survey of echocardiographic measurements. *Circulation* 58, 1072-1083.
- Santilli, R.A., Perego, M., Crosara, S., Gardini, F., Bellino, C., Moretti, P., Spadacini, G., 2008. Utility of 12-lead electrocardiogram for differentiating paroxysmal supraventricular tachycardias in dogs. *Journal of Veterinary Internal Medicine* 22, 915-923.
- Santilli, R.A., Perego, M., Perini, A., Moretti, P., Spadacini, G., 2010. Electrophysiologic characteristics and topographic distribution of focal atrial tachycardias in dogs. *Journal of Veterinary Internal Medicine* 24, 539-545.
- Schoonderwoerd, B.A., Gelder, I.C., Veldhuisen, D.J., Tieleman, R.G., Grandjean, J.G., Bel, K.J., Allessie, M.A., Crijns, H.J.G.M., 2001. Electrical remodeling and atrial dilation during atrial tachycardia are influenced by ventricular rate: Role of developing tachycardiomyopathy. *Journal of Cardiovascular Electrophysiology* 12, 1404-1410.
- Sébillon, P., Bouchier, C., Bidot, L.D., Bonne, G., Ahamed, K., Charron, P., Drouin-Garraud, V., Millaire, A., Desrumeaux, G., et al., 2003. Expanding the phenotype of *LMNA* mutations in dilated cardiomyopathy and functional consequences of these mutations. *Journal of Medical Genetics* 40, 560-567.
- Shinbane, J.S., Wood, M.A., Jensen, D.N., Ellenbogen, K.A., Fitzpatrick, A.P., Scheinman, M.M., 1997. Tachycardia-induced cardiomyopathy: A review of animal models and clinical studies. *Journal American College of Cardiology* 29, 709-715.

- Simpson, S., Dunning, M.D., Brownlie, S., Patel, J., Godden, M., Cobb, M., Mongan, N.P., Rutland, C.S., 2016. Multiple genetic associations with Irish wolfhound dilated cardiomyopathy. *BioMed Research International* 2016, 6374082
- Spinner, E.M., Lerakis, S., Higginson, J., 2012. Correlates of tricuspid regurgitation as determined by 3D echocardiography: Pulmonary arterial pressure, ventricle geometry, annular dilatation, and papillary muscle displacement. *Circulation* 5, 43-50.
- Stepien, R.L., 2009. Pulmonary arterial hypertension secondary to chronic left-sided cardiac dysfunction in dogs. *Journal of Small Animal Practice* 50, 34-43.
- Stern, J.A., Meurs, K.M., Spier, A.W., Koplitz, S.L., Baumwart, R.D., 2010. Ambulatory electrocardiographic evaluation of clinically normal adult Boxers. *Journal of the American Veterinary Medical Association* 236, 430-433.
- Takemura, N., Nakagawa, K., Hirose, H., 2002. Lone atrial fibrillation in a dog. *Journal of Veterinary Medical Science* 64, 1057-1059.
- Thomas, W.P., Gaber, C.E., Jacobs, G.J., Kaplan, P.M., Lombard, C.W., Moïse, N.S., Moses, B.L., 1993. Recommendations for standards in transthoracic two-dimensional echocardiography in the dog and cat. Echocardiography Committee of the Specialty of Cardiology, American College of Veterinary Internal Medicine. *Journal of Veterinary Internal Medicine* 7, 247-252.
- Tidholm, A., Haggstrom, J., Borgarelli, M., Tarducci, A., 2001. Canine idiopathic dilated cardiomyopathy. Part I: Aetiology, clinical characteristics, epidemiology and pathology. *The Veterinary Journal* 162, 92-107.
- Tidholm, A., Jönsson, L., 1996. Dilated cardiomyopathy in the Newfoundland: a study of 37 cases (1983-1994). *Journal of the American Animal Hospital Association* 32, 465-470.
- Tidholm, A., Westling, A.B., Höglund, K., Ljungvall, I., Haggstrom, J., 2010. Comparisons of 3-, 2-dimensional, and M-Mode echocardiographical methods for estimation of left chamber volumes in dogs with and without acquired heart disease. *Journal of Veterinary Internal Medicine* 24, 1414-1420.
- Topilsky, Y., Nkomo, V.T., Vatury, O., Michelena, H.I., Letourneau, T., Suri, R.M., Pislaru, S., Park, S., Mahoney, D.W., Biner, S., et al., 2014. Clinical outcome of isolated tricuspid regurgitation. *Journal of the American College of Cardiology. Cardiovascular Imaging* 7, 1185-1194.
- Tornos Mas, P., Rodríguez-Palomares, J.F., Antunes, M.J., 2015. Secondary tricuspid valve regurgitation: A forgotten entity. *Heart* 101, 1840-1848.
- Vila, J., Pariaut, R., Moïse, N.S., Oxford, E.M., MS, P.R.F.D., Reynolds, C.A., Saelinger, C., 2017. Structural and molecular pathology of the atrium in boxer

arrhythmogenic right ventricular cardiomyopathy. *Journal of Veterinary Cardiology* 19, 57-67.

Vollmar, A.C., 2000. The prevalence of cardiomyopathy in the Irish wolfhound: A clinical study of 500 dogs. *Journal of the American Animal Hospital Association* 36, 125-132.

Wess, G., Schulze, A., Butz, V., Simak, J., Killich, M., Keller, L.J.M., Maeurer, J., Hartmann, K., 2010. Prevalence of dilated cardiomyopathy in Doberman Pinschers in various age groups. *Journal of Veterinary Internal Medicine* 24, 533-538.

Wilson, J.R., Douglas, P., Hickey, W.F., Lanocce, V., Ferraro, N., Muhammad, A., Reichel, N., 1987. Experimental congestive heart failure produced by rapid ventricular pacing in the dog: Cardiac effects. *Circulation* 75, 857-867.

Wyse, D.G., van Gelder, I.C., Ellinor, P.T., Go, A.S., Kalman, J.M., Narayan, S.M., Nattel, S., Schotten, U., Rienstra, M., 2014. Lone atrial fibrillation: Does it exist? *Journal of the American College of Cardiology* 63, 1715-1723.

**Figure legends**

Fig. 1. Summary of 64 Dogue de Bordeaux (DdB) presented for cardiac evaluation.

RVC, Royal Veterinary College, UoL, University of Liverpool.

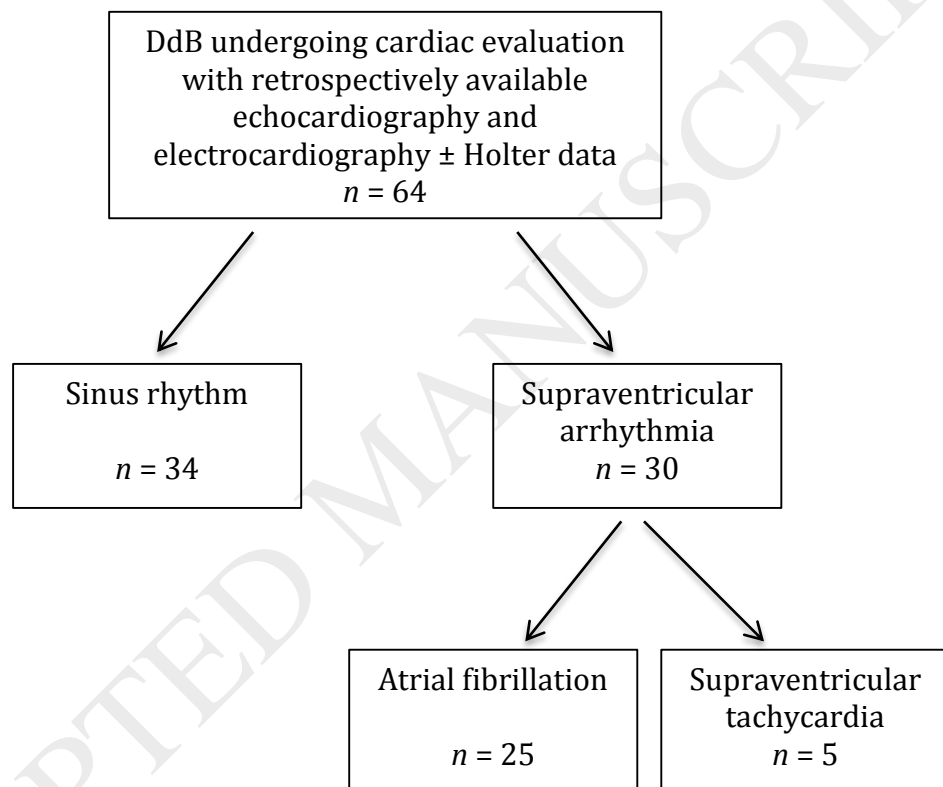




Fig. 2. Summary of congenital heart disease, cardiac mass and non-cardiac neoplasia (CHDN) in the study group of Dogue de Bordeaux (DdB) and development of subset of dogs without congenital heart disease, cardiac mass and non-cardiac neoplasia (non-CHDN). SAS, subaortic stenosis.

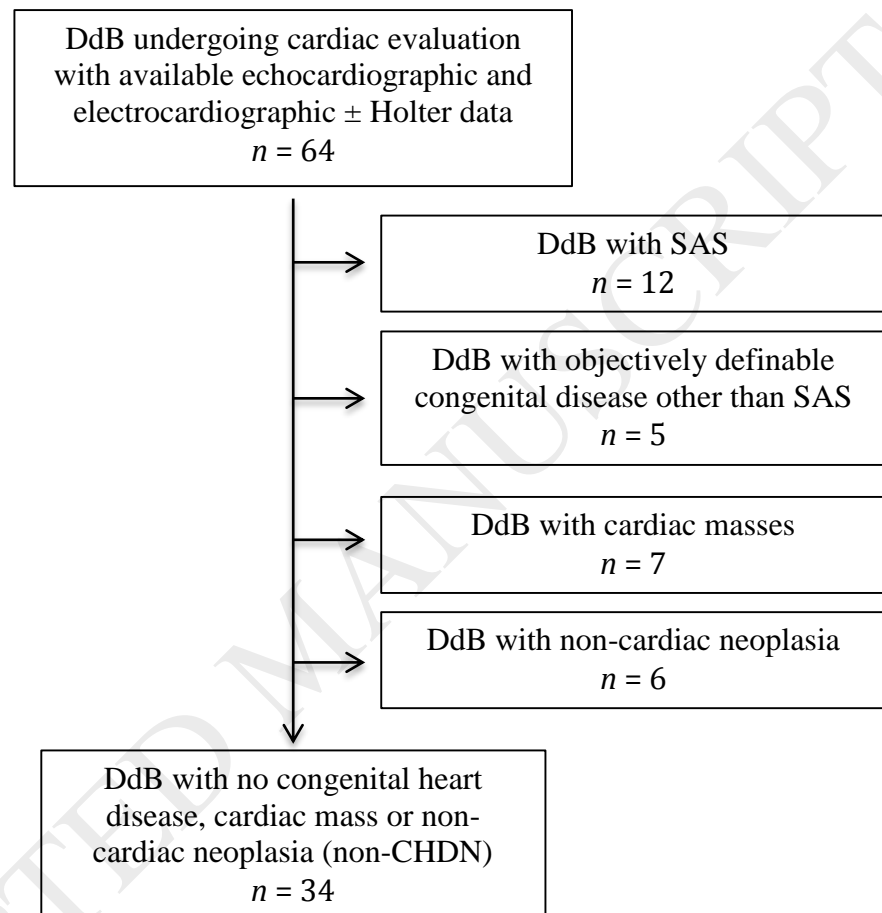


Fig. 3. Scatter plot of age associated with rhythm diagnosis in subset of 34 Dogue de Bordeaux (DdB) without congenital heart disease, cardiac mass or non-cardiac neoplasia (non-CHDN). AF, atrial fibrillation; SVT, supraventricular tachycardia.

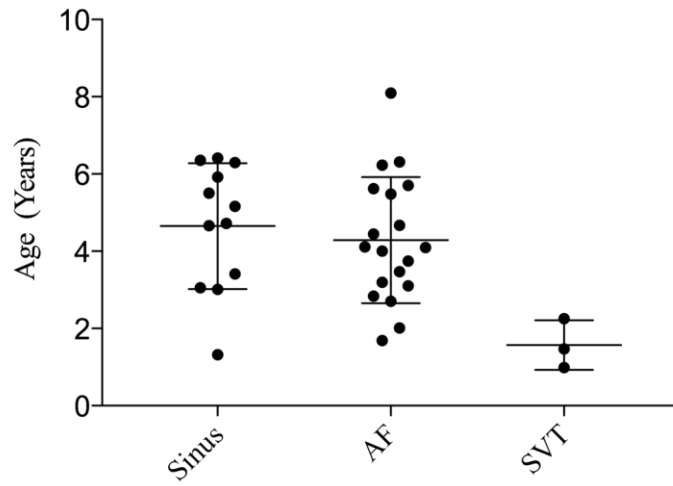


Fig. 4. Systolic dysfunction and right sided dilatation associated with rhythm diagnosis in subset of 34 Dogue de Bordeaux (DdB) without congenital heart disease, cardiac mass or non-cardiac neoplasia (non-CHDN).

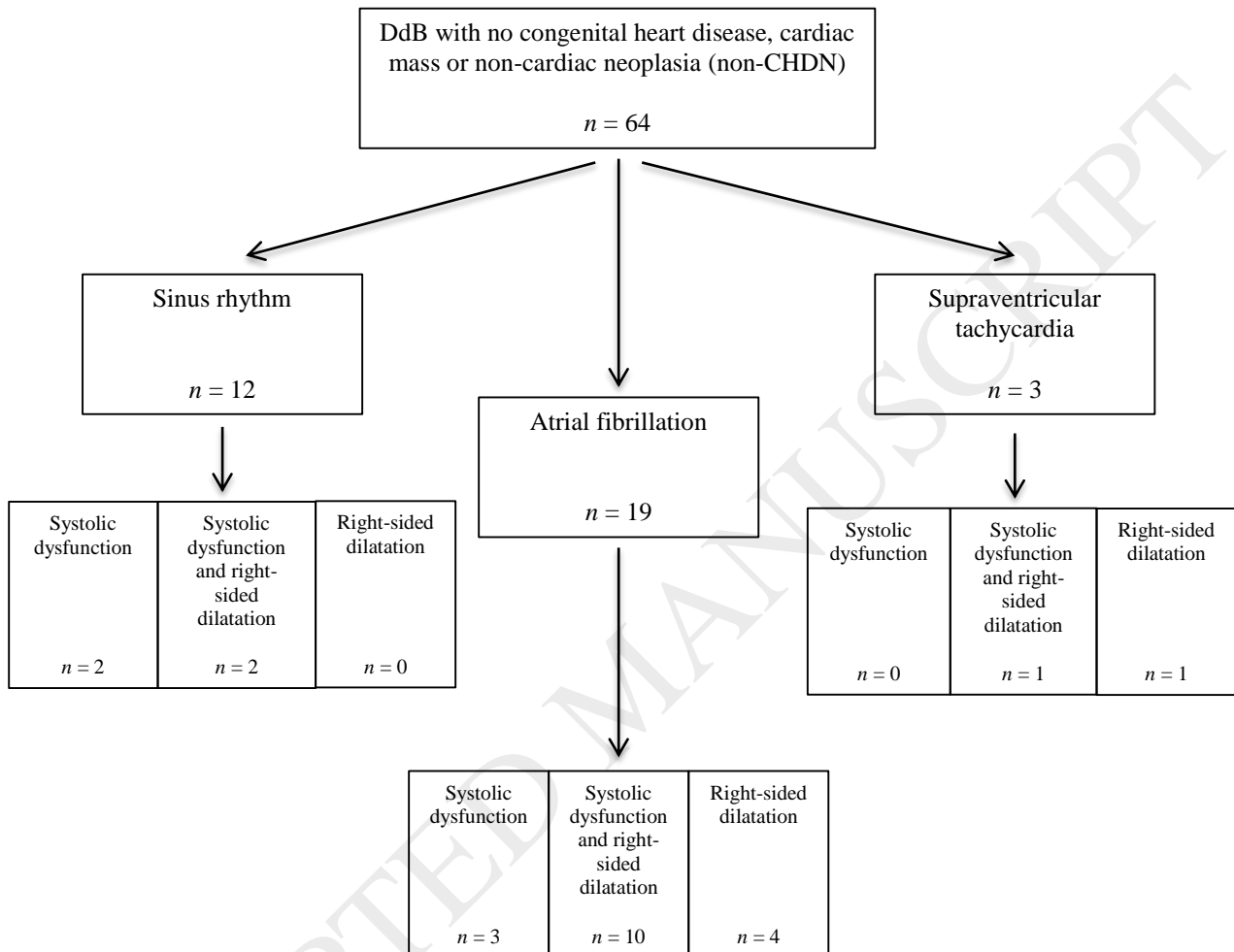
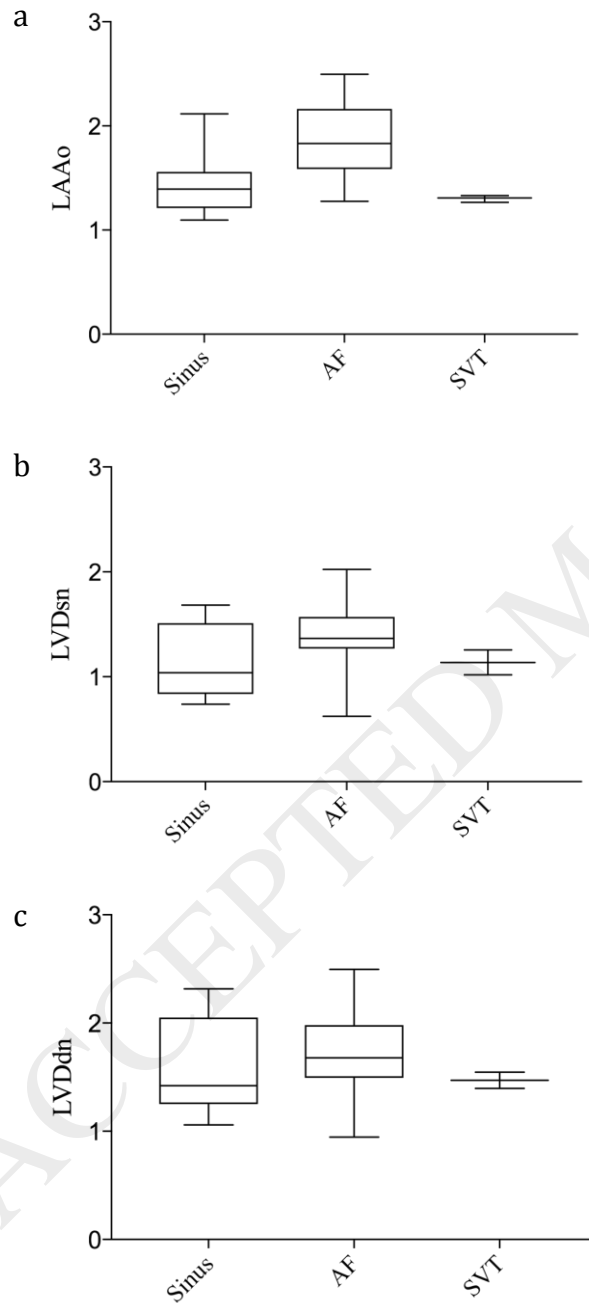


Fig. 5. Box and whisker plots of (a) left atrial-to-aortic ratio (LA:Ao); (b) normalised left ventricular systolic dimension (LVIDsn); (c) normalised left ventricular diastolic dimension (LVIDdn) according to rhythm diagnosis in subset of 34 Dogue de Bordeaux (DdB) without congenital heart disease, cardiac mass or non-cardiac neoplasia (non-CHDN).



**Table 1** Signalment and presenting clinical signs in study group of 64 Dogue de Bordeaux.

	<i>n</i>
Signalment	
Age (Years)	4.3 ( $\pm$ 2.1)
Sex (Male:Female)	49:15
Weight (kg)	57.1 ( $\pm$ 8.4)
Clinical signs	
Auscultated arrhythmia	33 (51.6%)
Exercise intolerance	26 (41%)
Anorexia	24 (37.5%)
Systolic murmur	21 (32.8%)
Dyspnoea	21 (32.8%)
Collapse	20 (31.3%)
Abdominal distension	16 (25%)
Weight loss	16 (25%)
Cough	7 (10.9%)
Gallop sound	1 (1.6%)

Normally distributed data expressed as mean  $\pm$  standard deviation (SD).

**Table 2** Signalment and echocardiographic and electrocardiographic findings in 64 Dogue de Bordeaux with sinus rhythm and supraventricular arrhythmia.

	Sinus rhythm	Supraventricular arrhythmia	<i>P</i> value
<b>Presentation</b>			
Number of cases	34	30	
RVC cases:UoL cases	20:14	23:7	0.183
Age (Years)	4.7 ± 2.34	3.9 ± 2.0	0.13
Sex (Male:Female)	25:9	24:6	0.571
Weight (kg)	56.3 ± 7.1	58.1 ± 9.7	0.387
HR Presentation	104 [84-129]	190 [120-240]	< 0.001
History of collapse or syncope	10/24 (29.4%)	10/20 (33.3%)	0.791
<b>Echocardiography</b>			
LA/Ao	1.31 [1.18-1.50]	1.8 [1.48-2.06]	< 0.001
LVDdn	1.5 ± 0.34	1.71 ± 0.37	0.032
LVDsn	1.00 ± 0.30	1.34 ± 0.34	0.002
FS%	28.6 ± 9.9	15.0 ± 9.0	< 0.001
PEP:LVET	0.41 ± 0.10	0.57 ± 0.13	< 0.001
TRV (m/s)	2.8 [2.6-3.1]	2.9 [2.3-3.0]	0.912
Right sided dilatation	6/27 (18.1%)	21/8 (72%)	0.001
No remodelling (No LVD, LAD or RSD)	23 (67%)	4 (13.3%)	0.007
<b>Rhythm</b>			
HR ECG/Holter mean	80 [68-125]	135 [98-240]	0.032
Ventricular arrhythmia	5	10	0.138
Complex ventricular arrhythmia (couplets, triplets bigeminy, trigeminy and/or ventricular tachycardia)	4	3	> 0.999
<b>Specific diagnosis</b>			
SAS	9 (26.5%)	3 (10%)	0.119
CHD (not SAS)	3 (8.8%)	2 (6.7%)	> 0.999
Cardiac mass	5 (14.7%)	2 (6.7%)	0.433
Non-cardiac neoplasia	6 (17.6%)	0 (0%)	0.016

Normally distributed data expressed as mean ± standard deviation (SD) and non-normally distributed data are expressed as median [inter-quartile range].

RVC, Royal Veterinary College; UoL, University of Liverpool; HR, heart rate; LA, left atrial diameter; Ao, aortic diameter; LVDdn, left ventricular diameter diastole normalised; LVDsn, left ventricular diameter systole normalised; FS, fractional shortening; PEP, pre-ejection period; ET, left ventricular ejection time; TRV, tricuspid regurgitant velocity; LVD, left ventricular dilatation; LAD, left atrial dilatation; RSD, right sided dilatation; SAS, subaortic stenosis.

**Table 3** Signalment, echocardiographic and electrocardiographic findings in subset of Dogue de Bordeaux excluding congenital heart disease, cardiac mass and non-cardiac neoplasia.

	Sinus	AF	SVT	<i>P</i> value
<b>Signalment</b>				
<i>n</i>	12	19	3	
Age (Years)	4.9 [3.1-6.2]	4.1 [3.1-5.6]	1.5 [1-2.3]	0.027
Sex (Male:Female)	10:2	15:4	2:1 (66.6% Male)	0.813
Weight (kg)	53.5 [48.4-54.7]	61.9 [52.9-67.6]	50.2 [45.1-66.0]	0.153
HR presentation	128 [120-170]	200 [160-240]	120 [84-360]	0.054
History of collapse or syncope	5 (41%)	8 (42.1%)	1 (33.3%)	0.959
<b>Echocardiography</b>				
LA/Ao	1.39 [1.21-1.56]	1.83 [1.59-2.16]	1.31 [1.27-1.33] <sup>a</sup>	0.004
LVDdn	1.42 [1.25-2.05]	1.37 [1.27-1.57]	1.47 [1.4-1.55]	0.324
LVDsn	1.04 [0.83-1.51]	1.37 [1.27-1.57]	1.14 [1.02-1.26]	0.298
FS (%)	25.3 [16.4-28.0]	11.7 [7.81-21.1]	16.5 [11.9-21.0] <sup>a</sup>	0.017
PEP:LVET	0.48 [0.36-0.57]	0.57 [0.54-0.69]	0.41 [0.4-0.57] <sup>a</sup>	0.017
TRV (m/s)	2.58 [2.58-3.00]	3 [2.4-3.3]	2.9 [2.8-3.0]	0.79
Left-sided dilatation	4 (33.3%)	5 (26.3%)	0 (0%)	0.504
Right sided dilatation	2 (16.7%)	14 (73.7%)	2 (66.6%)	0.007

Data are expressed as median [interquartile range]. AF, atrial fibrillation; SVT, supraventricular tachycardia; HR, heart rate; LA, left atrial diameter; Ao, aortic diameter; LVDdn, left ventricular diameter diastole normalised; LVDsn, left ventricular diameter systole normalised; FS, fractional shortening; PEP, pre-ejection period; ET, left ventricular ejection time; TRV, tricuspid regurgitant velocity. Groups were compared with a Kruskal-Wallis test and the *P* value is reported with pair-wise comparisons using Dunn's multiple comparisons test.

<sup>a</sup> Within each row, data that were not significantly different between the two indicated groups.