

Microsurgical Approach to the Temporomandibular Joint

A New Horizon

Keith L. Kreutziger, DDS, MD

● The operating microscope has revolutionized many surgical procedures. To my knowledge, this article records, for the first time, pioneering microtechniques for exploring and reconstructing the temporomandibular joint. Determination of pathologic conditions and observation of temporomandibular joint function-dysfunction are dramatic and rewarding. Precision surgery using microinstruments, microneedles, microdrills, and bipolar cautery allows accuracy of technique that previously was impossible. Two representative case presentations illustrate patient treatment, microsurgical technique employed, and clinical results obtained.

(*Arch Otolaryngol* 1982;108:422-428)

Microsurgery is an evolving, expanding field that has revolutionized many surgical procedures. The operating microscope was first introduced into medicine in the field of otolaryngology by Maier and Lion¹ in experimental animals and by Nylén² in humans. Perritt³ recorded microsurgical techniques related to ophthalmology. Kurze⁴ subsequently began revolutionizing techniques in the field of neurosurgery by using

microsurgery. This article describes the microsurgical approach to the temporomandibular joint (TMJ) and the microtechniques used.

Microsurgical techniques are applied to all intracapsular derangements of the TMJ. Such conditions include congenital conditions, trauma, hypomobility syndromes, arthritic conditions, neoplasms, and a host of miscellaneous diseases.⁵ Temporomandibular degenerative joint disease (TDJD),^{5,6} internal derangement of the TMJ,⁷ and traumatic disorders commonly result in afflictions amenable to microsurgical techniques. Internal derangements of the TMJ are common. The anteriorly displaced meniscus with permanent anterior position usually is seen as decreased jaw opening, pain, myofascial discomfort, headaches, opening and closing joint sounds, and referred pain to the ear. With severe limitations of movement, the meniscus is in a "closed-lock" position and a joint click no longer exists. Meniscus perforation, rupture of meniscus attachment, and herniated meniscus occur.

Traumatic intracapsular injuries include hemarthrosis, fractures of the bony components (mandibular condyle and glenoid fossa), and traumatic meniscus, capsule, and temporomandibular ligament injuries. In the majority of TMJ disorders, conservative therapy will relieve symptoms. Conservative therapeutic measures vary according to the pathologic con-

dition encountered.⁶ Surgical procedures are performed when conservative measures have failed, with symptoms persistent and intolerable, or when surgical disease has been diagnosed.

Roentgenographic evaluation is essential in the preoperative studies. Transparietal TMJ films in the open and closed positions are screening roentgenograms. Polytomography is obtained when bony degenerative changes are suspected. If a degenerative joint is found and surgery is indicated, an arthrogram, a more invasive procedure, is not performed. Microsurgical procedures will diagnose an internal derangement pathologic condition. Arthrography,⁸ cinefluorography,⁹ and arthrocindefluorography¹⁰ are necessary to diagnose accurately internal derangements of the meniscus. Modifications of the dynamic arthrocindefluorography, with video recording, allow evaluation of the TMJ in functional movements, resulting in the most rewarding diagnostic findings, and replace static arthrography. Meniscus movements and anterior displacements are readily observed. Therefore, dynamic arthrocindefluorography is indicated when internal derangement is highly suspected as the only pathologic condition present, conservative treatments have failed, degenerative joint changes were not seen on polytomography, and surgical procedures are being contemplated.

Accepted for publication Dec 23, 1981.

From the Department of Otorhinolaryngology, Ochsner Medical Institutions, New Orleans.

Read before the American Academy of Facial Plastic and Reconstructive Surgery, New Orleans, Sept 19, 1981.

Reprint requests to the Ochsner Clinic, 1514 Jefferson Hwy, New Orleans, LA 70121 (Dr Kreutziger).

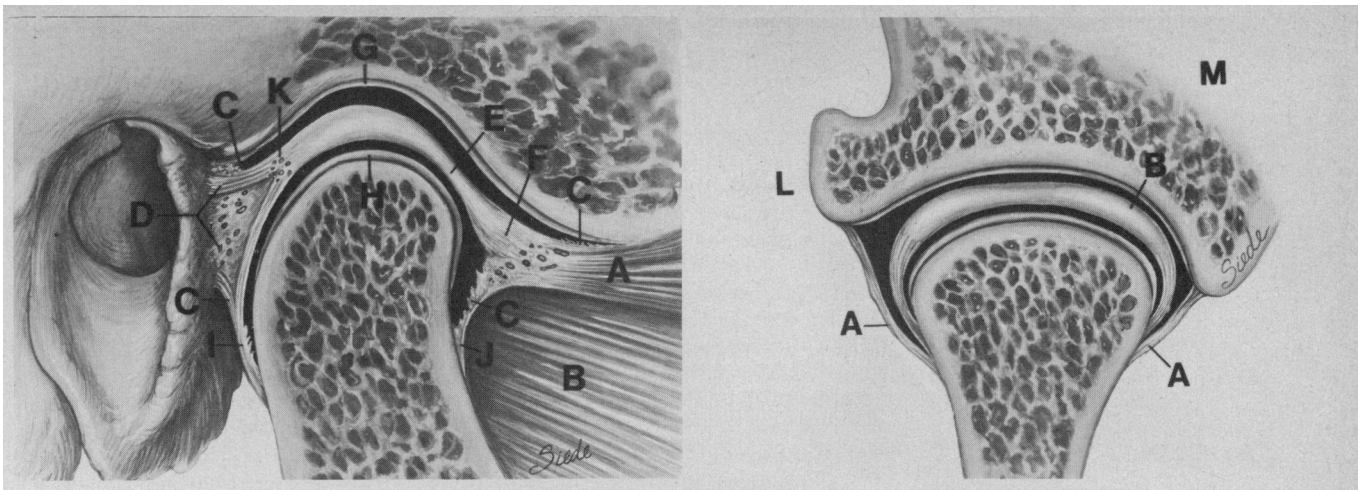


Fig 1.—Left, Sagittal anatomic view of temporomandibular joint (TMJ) indicating normal anatomy: superior (A) and inferior (B) bellies of lateral pterygoid muscle, synovial villi (C), meniscus bilaminar zone (D), pars gracilis (E), pes meniscus (F), collagen layer covering glenoid fossa, articular eminence (G), articular surface of condyle (H), posterior (I) and anterior (J) capsule, and genu vasculosa (K). Right, Frontal anatomic view of TMJ depicting separate attachments of lateral (L) and medial (M) capsule (A) and meniscus (B) to mandibular condyle. Note that all clinical photographs and anatomic drawings illustrate right TMJ with posterior identified by external auditory canal and anterior on right of figure.

SURGICAL ANATOMY OF THE TMJ

Anatomy of the TMJ is highly specific¹¹ and correlates with jaw function (Fig 1). The TMJ is a ginglymoarthrodial joint that is freely mobile with superior and inferior joint cavities separated by the meniscus. The articular surface of the mandibular condyle and the glenoid fossa of the temporal bone are covered with dense collagen fibers. The cavities are lined with synovial tissues with villae extending from the anterior and posterior meniscus to the attachments to the temporal bone and mandibular condyle.

The meniscus itself is a complex structure. The central region of the meniscus, the *pars gracilis*, is thinned avascular collagen. The meniscus projects anteriorly to form a foot-shaped process, the *pes meniscus*. This process is attached superiorly to the articular eminence and superior belly of the lateral pterygoid muscle. Inferiorly, the *pes meniscus* is attached to the condyle via a synovial membrane at the superior margin of the attachment of the inferior belly of the lateral pterygoid muscle. This area is highly vascular, with vessels supplying the lateral pterygoid muscle and structures of the joint.

The posterior meniscus attachment is the bilaminar zone, composed of two strata of fibers separated by a

central zone composed of loose areolar connective tissue. At this posterior region, the meniscus is highly vascular and is called the *genu vasculosa* (vascular knee). The posterior meniscus attaches via the superior stratum to the tympanic plate of the temporal bone. The inferior stratum attaches from the pars posterior of the meniscus to the neck of the condyle. Medially and laterally, the meniscus is tightly attached to the condyle poles, which are independent of the capsule attachments. Thus, the meniscus forms a caplike structure over the articular surface of the condyle, forming the inferior joint cavity.

The collagen fibers of the capsule inferiorly attach medially and laterally to the condyle neck independent of the meniscus. Superiorly and medially, the capsule attaches to the tympanic plate and suture line between the temporal squama and the sphenoid bone. Laterally, it attaches to the inferior border of the zygomatic process of the temporal bone. Posteriorly, the capsule fibers extend from the tympanic plate to the posterior aspect of the condyle. The collateral ligament of the joint is called the *temporomandibular ligament*. It extends from the inferolateral surface of the zygomatic arch at the anterior superior extent of the capsule and progresses posteriorly and inferiorly to attach to the lateral anterior border of the condylar neck.

Immediately over the capsule and temporomandibular ligament is the fascia parotideomasseteria, which attaches tightly to the inferior zygomatic arch border. The superficial investing fascia forms a separate layer superficial to the fascia parotideomasseteria.

During function, the meniscus attachments anteriorly and posteriorly allow the meniscus to rotate posteriorly as the condyle translates anteriorly. When internal derangements occur with anterior meniscus displacement, fibrous adhesions at the anterior meniscus attachment with rupture or excessive laxity of the posterior meniscus attachment occur. The meniscus stabilizes the convex mandibular condyle against the concavoconvex glenoid fossa and articular eminence. The posterior villi of the superior and inferior joint cavities unfold with translation, while the anterior villi unfold in the rest position. The capsule has enough laxity to allow translation and hinge movement but gives support to the joint. The temporomandibular ligament functions like a pendulum, which allows translation but resists abnormal lateral condyle displacement.

MICROSURGICAL TECHNIQUE

General anesthesia via nasotracheal intubation allows freedom for complete

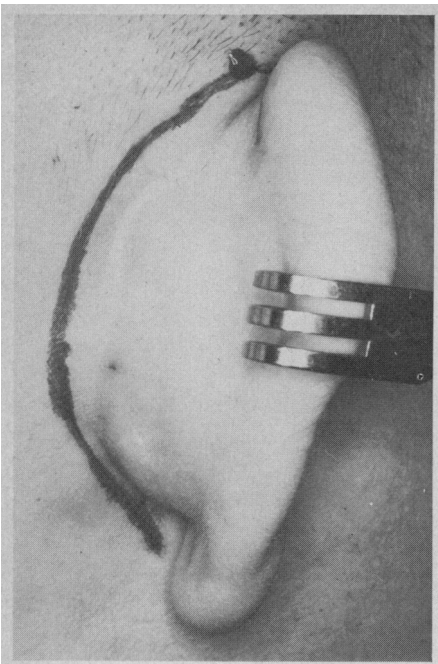


Fig 2.—Clinical photograph of incision marked 3 mm posterior to postauricular crease.

manipulation of the jaw during microsurgical evaluation of internal joint function. A postauricular incision is used (Fig 2). The incision is marked parallel and posterior to the postauricular crease approximately 3 mm. The inferior extent curves over the mastoid tip. The superior extent stops at the superior attachment of the pinna just within the hairline. The incision may be carried anterior within the hairline for extended exposure. The postauricular incision is carried sharply down to the fascia overlying the mastoid bone and the temporalis fascia superiorly.

Dissection in this layer is carried anteriorly, delineating the external auditory canal (EAC) skin. The superior temporal line is identified with blunt and sharp dissection further exposing the superior aspect of the EAC. Similar dissection is performed immediately inferior to the EAC skin. A complete crosscut of the EAC is made at the bony cartilaginous junction. Dissection is carried anteriorly immediately over the zygomatic root on the periosteum, isolating the fascia temporalis and parotideomasseteria as they attach superiorly and inferiorly, respectively, to the bone (Fig 3).

Anterior dissection is performed in the fascial layer between the middle and deep layers of the fascia temporalis and between the superficial fascia and fascia parotideomasseteria. The anterior border of the temporomandibular ligament and

capsule is the extent of the anterior dissection. Inferior dissection terminates at the attachment of the temporomandibular ligament and capsule to the mandibular condyle. An incision is made to develop an anteriorly based fascia parotideomasseteric flap (Fig 3, right; dotted line). First, an incision is made to the bone over the zygomatic root and carried posteriorly to the extent of the posterior border of the capsule. Second, a vertical component is carried inferiorly following the posterior border of the capsule to the neck of the condyle. Third, a flap is then developed anteriorly, relieving the fascia parotideomasseteria from the zygoma, temporomandibular ligament, and joint capsule (Fig 4). A self-retaining retractor is placed to hold the fascia flap and ear-skin flap anteriorly. At this point, the operating microscope is moved into position for the remaining procedures.

Incisions are made to develop a posteriorly based capsule-temporomandibular ligament flap. Three incisions are made in sequence—superior horizontal curvilinear, anterior vertical, and inferior horizontal (Fig 4, right; dashed incision line).

First, the superior horizontal curvilinear incision is made through the temporomandibular ligament-capsule from anterior to posterior. Incision into the joint cavity begins anteriorly with release of synovial fluid with entrance into the joint cavity. A microduck-billed elevator is placed into the

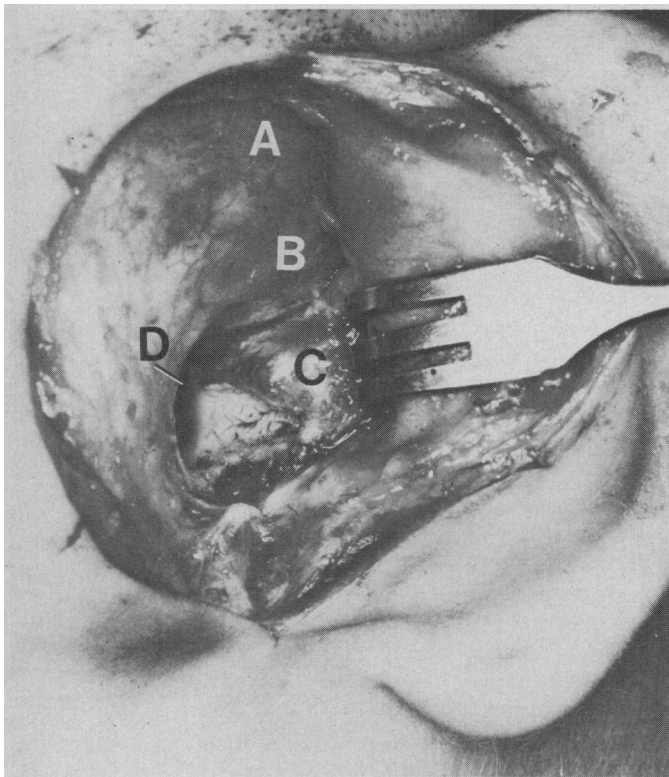
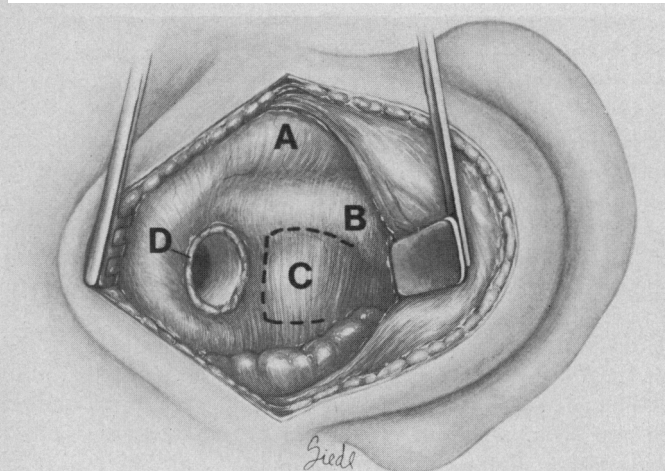


Fig 3.—Clinical photograph (left) and anatomic drawing (right) illustrating temporalis fascia (A), zygomatic process of temporal bone (B), fascia parotideomasseteria (C), and crosscut of external auditory canal (D); dotted line marks incision of parotideomasseteric fascia.



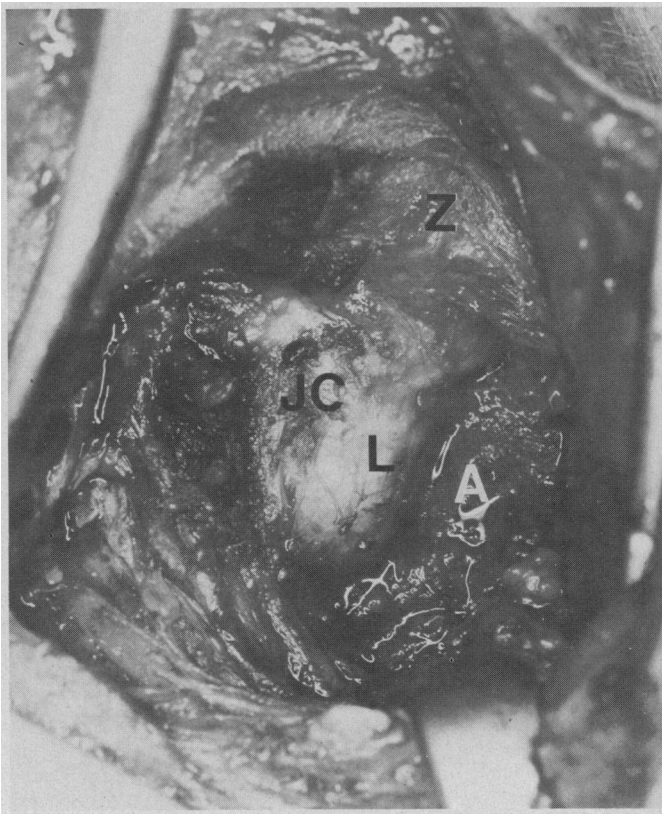


Fig 4.—Clinical photograph (left) and anatomic drawing (right) depicting fascia parotideomasseteric flap (A) anteriorly reflected exposing joint capsule (JC) and temporomandibular ligament (L). Zygomatic process of temporal bone (Z) is identified. Dotted line outlines incision of joint capsule and ligament for posterior flap development.

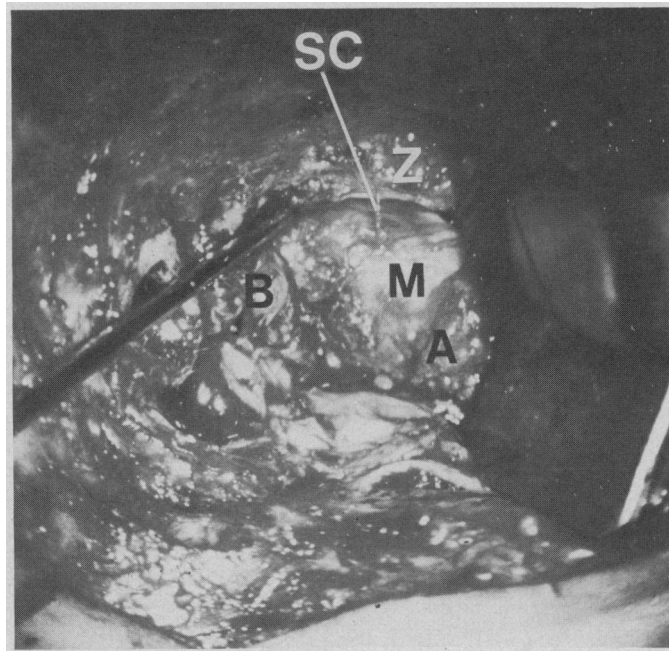
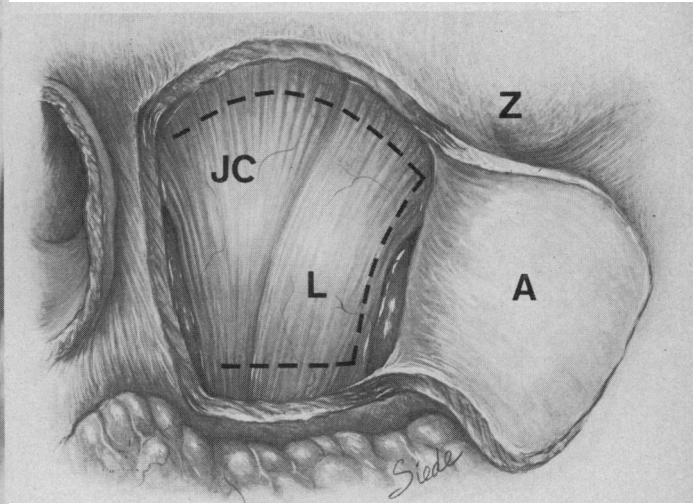
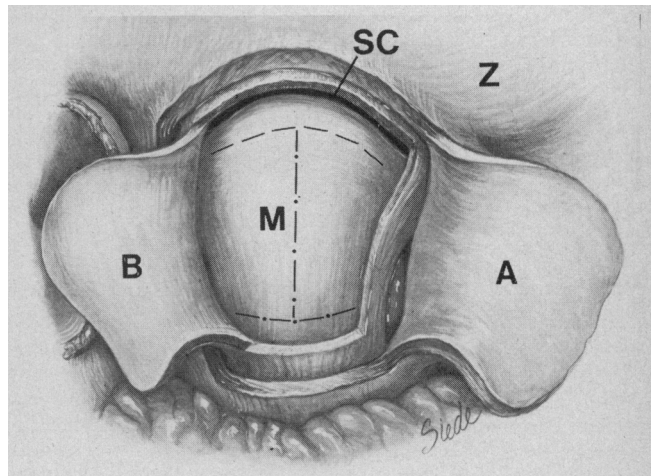


Fig 5.—Left, Clinical photograph showing zygomatic arch (Z), probe in posterior aspect of superior joint cavity, superior joint cavity (SC) and meniscus cap (M), posteriorly based capsule-temporomandibular ligament flap (B), and anteriorly based parotideomasseteric flap (A). Right, Anatomic drawing showing zygomatic arch (Z), anteriorly reflected parotideomasseteric flap (A), posteriorly reflected capsule-temporomandibular ligament flap (B) exposing superior joint cavity (SC), and meniscus cap (M). Dashed line outlines limited meniscus incision. Dotted and dashed line outlines additional incisions for extended exposure.



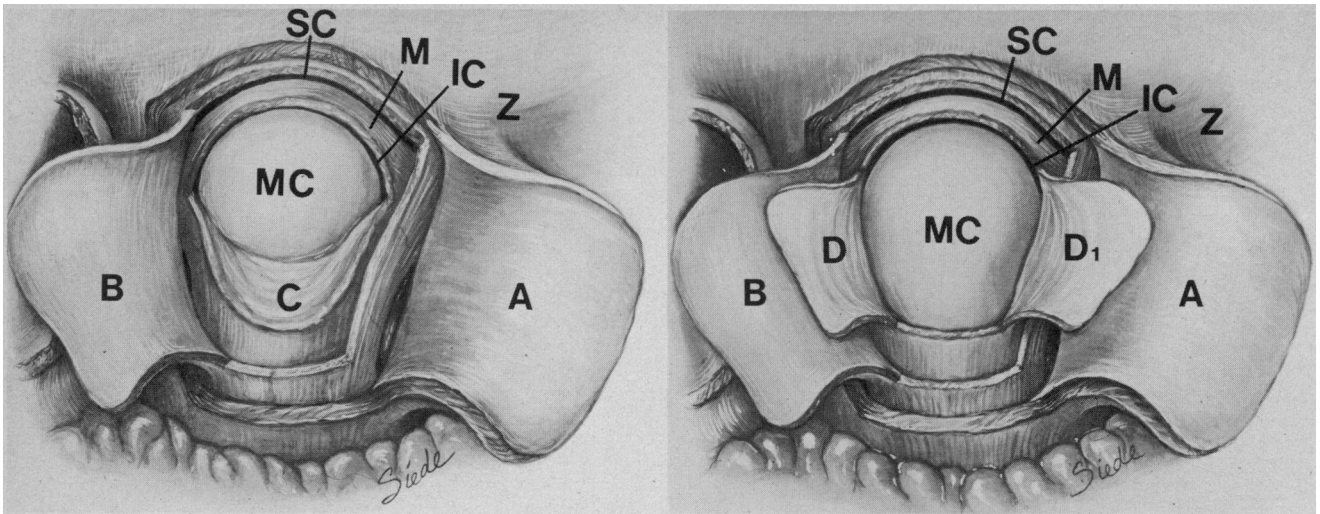


Fig 6.—Left, Anatomic drawing illustrating limited meniscus incision completed and flap (C) reflected inferiorly exposing inferior joint cavity (IC) and articular surface of mandibular condyle (MC). Zygomatic arch (Z), superior joint cavity (SC), meniscus (M), anterior parotidomasseteric flap (A), and posterior capsule-temporomandibular ligament flap (B) are identified. Right, Anatomic drawing showing extended exposure of inferior joint cavity (IC) and mandibular condyle (MC) with lateral meniscus flaps reflected anteriorly (D,) and posteriorly (D). Zygomatic arch (Z), superior joint cavity (SC), meniscus (M), anterior parotidomasseteric flap (A), and posterior capsule-temporomandibular ligament flap (B) are identified.

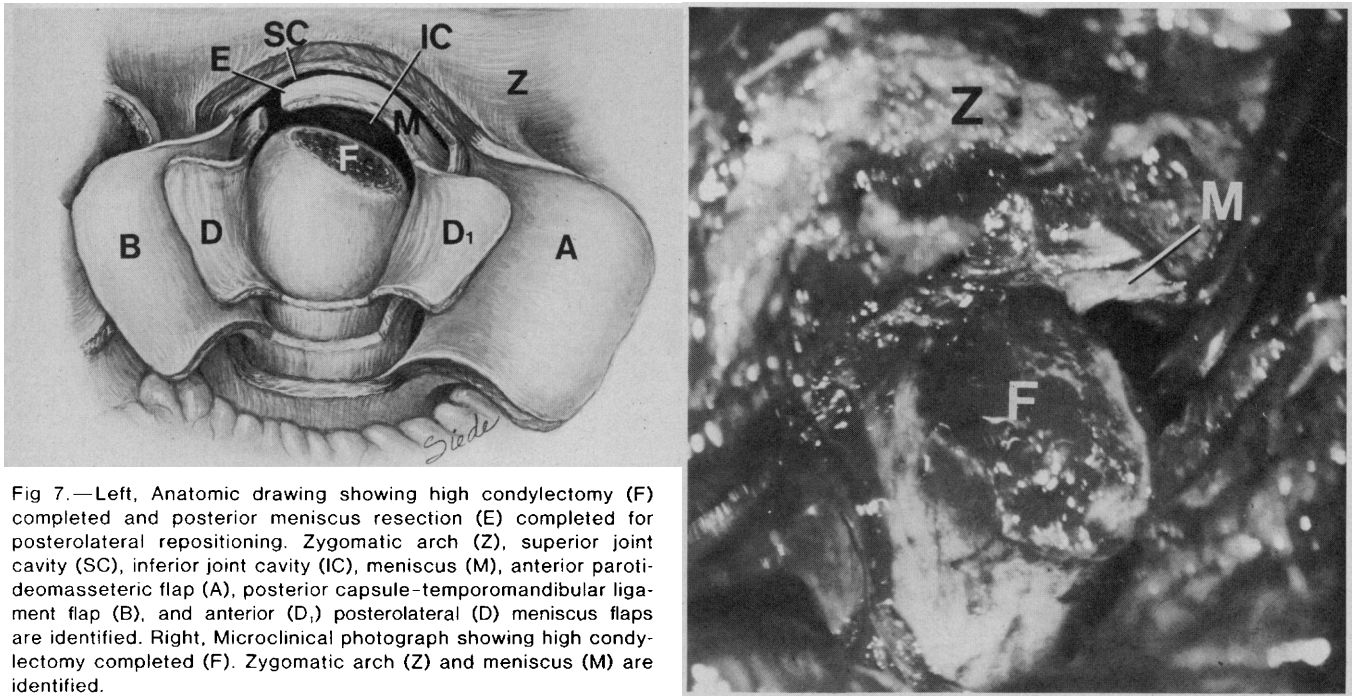


Fig 7.—Left, Anatomic drawing showing high condylectomy (F) completed and posterior meniscus resection (E) completed for posterolateral repositioning. Zygomatic arch (Z), superior joint cavity (SC), inferior joint cavity (IC), meniscus (M), anterior parotidomasseteric flap (A), posterior capsule-temporomandibular ligament flap (B), and anterior (D,) posterolateral (D) meniscus flaps are identified. Right, Microclinical photograph showing high condylectomy completed (F). Zygomatic arch (Z) and meniscus (M) are identified.

superior joint cavity, elevating the capsule laterally. This protects the internal joint and allows completion of the incision to its posterior extent. Second, an incision at the anterior extent of the capsule is carried inferiorly to its attachment to the condyle neck. Third, the inferior capsular attachment to the condylar neck is released, allowing an envelope flap to be reflected posteriorly (Fig 5, flap B). This allows inspection of the superior joint cavity, the superior surface of the meniscus, and the

glenoid fossa. Manipulation of the mandible in dynamic movements and in static open and closed positions allows inspection of the meniscus and its attachments during function.

Exploration of the inferior joint space is accomplished through a lateral meniscus incision (incision delineated in Fig 5, right). Immediately superiorly and laterally to the midline of the lateral pole of the mandibular condyle, a perforating incision of the meniscus into the inferior joint

cavity is made with release of synovial fluid. The microduck-billed elevator or nerve hook is placed into the inferior joint cavity to protect the articular surface of the mandibular condyle. The lateral meniscus is lifted laterally as the incision is extended. Extension anteriorly follows a downward curve to the anterior meniscus attachment. Posterior extension curves to the loose posterior meniscus attachment of the bilaminar zone. The flap is reflected inferiorly, exposing the inferior joint cavi-

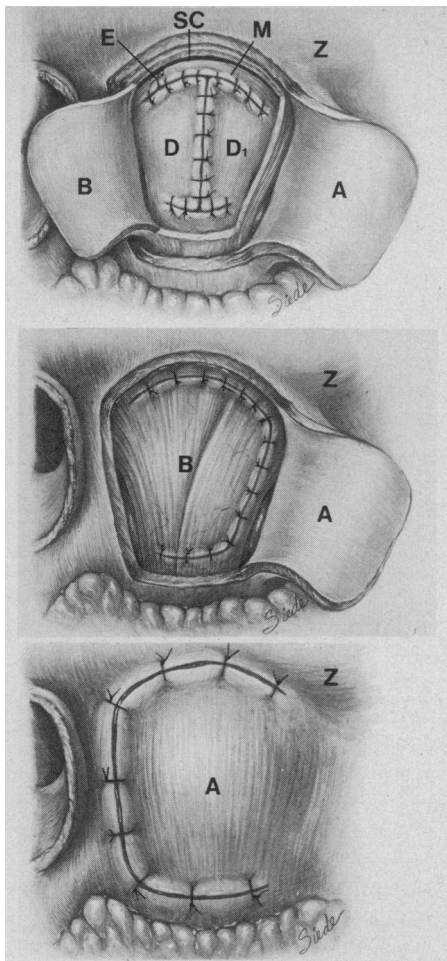


Fig 8.—Top, Anatomic drawings showing surgical closures of anterior (D) and posterolateral (D₁) meniscus flaps and meniscus posteriorly repositioned (E). Zygomatic arch (Z), superior joint cavity (SC), anterior meniscus (M), anteriorly reflected parotidomasseteric flap (A), and posteriorly reflected capsule-temporomandibular ligament flap (B) are identified. Center, Anatomic drawing showing surgical closure of the posteriorly based capsule-temporomandibular ligament flap (B). Zygomatic arch (Z) and anteriorly based fascia parotidomasseteric flap (A) are identified. Bottom, Anatomic drawing showing surgical closure of anteriorly based fascia parotidomasseteric flap (A). Zygomatic process of temporal bone (Z) is marked.

ty and mandibular condyle articular surface with limited exposure (Fig 6, left; flap C). Inspection of the inferior joint cavity of the TMJ during function and in closed and open static positions is now performed. The articular surface of the condyle is inspected, and reinspection of the superior joint space, glenoid fossa, and anterior and posterior meniscus attachments is performed.

Technical procedures now vary de-

pending on the internal derangement observed on exploration. Such findings are correlated with polytomography and dynamic arthrocinfluorography of the TMJs. When the diagnosis of internal derangement of the TMJ is made with anterior displacement of the meniscus without degenerative changes of the articular surface of the mandibular condyle, the meniscus is posteriorly repositioned. The mandibular condyle is displaced inferiorly with the jaw open maximally. An incision is made from lateral to medial just anterior to the bilaminar zone. Traction sutures are placed to the meniscus immediately anterior to the meniscus incision. With the mandible in the resting position with an incisal freeway space of 2 to 3 mm, the meniscus is repositioned posteriorly and laterally.

The meniscus is held in this position while functional movements of the mandible are performed. This determines the degree of anterior displacement and the amount of posterior resection of the meniscus. The meniscus is marked and resected from lateral to medial (Fig 7, left; label E). Microtechniques are used to suture the meniscus posteriorly with synthetic permanent suture material. If posterior resection of the meniscus is not indicated, posterior plication of the meniscus may be performed. If degenerative changes with spurs and irregularity of the articular surface of the condyle are present, they may be removed and the surface smoothed with microinstruments and microdrill.

When TDJD is severe, further exposure of the joint is necessary (Fig 5, right; dot-dash incision line). An incision is made from the midline of the lateral meniscus incision and carried inferiorly to the midpoint of the meniscus attachment to the lateral condylar neck. The inferior attachment is released from the mandibular condyle anteriorly and posteriorly. Flaps are folded anteriorly and posteriorly, exposing the entire lateral pole of the condyle (Fig 6, right; flaps D, D₁).

A high condylectomy is performed with removal of the articular surface of the mandibular condyle (Fig 7). The articular surface is sectioned from lateral to medial with a microdrill. A small medial bone fragment is left intact to protect vital structures deep to the medial condyle pole. The medial bone is then fractured by placing a periosteal elevator into the osteotomy and twisting the instrument. The residual attachment of the superior belly of the external pterygoid muscle is dissected free, and the articular surface is removed from the surgical site. The meniscus is left intact to separate the glenoid fossa from the sectioned condyle. In addition, the meniscus helps to absorb functional trau-

ma and to maintain vertical height. If removal of extensive vertical dimension is necessary, an implant of Silastic is wired to the recontoured condyle. If a posterior repositioning of the meniscus is indicated, the identical techniques as previously described are now performed (Fig 7, left; label E).

Closure is performed in reverse order. The lateral meniscus flaps are sutured into anatomic position (Fig 8, top). The capsule-temporomandibular ligament flap is returned to its anatomic position and sutured securely (Fig 8, center). The self-retaining retractor is released and the parotidomasseteric fascia flap is retracted posteriorly and sutured into its anatomic position (Fig 8, bottom). The deep tissues immediately surrounding the crosscut skin of the EAC are sutured with four to six circumferential sutures as the ear flap is returned posteriorly into its previous position. The postauricular incision is closed with standard techniques.

REPORT OF CASES

CASE 1.—A 29-year-old distraught woman complained of severe pain and loss of function to the right TMJ accompanied by excruciating temporal headache. Symptoms had been present for more than ten years, which gradually had been increasing in severity, frequency, and duration. Severity had increased dramatically in the past two years. Other initial symptoms included joint sounds of the right TMJ, occasional pain to the contralateral TMJ, right retrobulbar pain, occasional blurred vision associated with the headaches, edema of the right upper and lower eyelids, burning sensation to the scalp, right mastoid tip and cortex pain, decreased right hearing, and a burning of the right side of the tongue. The patient had received numerous treatments. Medical treatment included analgesics, narcotics, muscle relaxants, tranquilizers, aspirin, and steroids. Dental management included occlusal equilibrations on four occasions and four occlusal and repositioning splints during a ten-year period, which only seemed to cause an increase in symptoms.

Initial examination disclosed discoordinate functional movements of the mandible with an opening of 12 mm from the incised edges of the maxillary and mandibular central incisors. A class I functional occlusion was present. Palpation disclosed tenderness to the right trapezius muscle and right TMJ. Stethoscope auscultation of the right TMJ found an opening painful snap with crepitus and an occasional reciprocal click in the left TMJ. Examination included normal results of audiology testing, a normal panoramic roentgenogram, a neurology consultation identifying no neu-

rologic disease, and a psychiatric consultation describing the development of a lifestyle surrounding and drawing attention to the pain.

Dynamic arthrocinfluorography of the right TMJ demonstrated a pronounced snap on translation with an anteriorly displaced meniscus. A microsurgical arthroplasty of the right TMJ identified internal derangement with an anterior displaced meniscus with rupture of the posterior meniscus attachment. In addition, the central inferior surface of the meniscus had degeneration with hard plaquing. Posterior resection with posterolateral repositioning of the meniscus corrected the pathologic condition. Nine months postoperatively, the patient has an incisal opening of 42 mm, has no pain with mastication, and does not experience headaches; other associated symptoms have shown resolution.

CASE 2.—A 34-year-old woman was seen initially with pain and popping to the TMJs with difficulty masticating. A complex history showed that the patient's symptoms began a year earlier with locking of the jaw after a wide opening, causing severe left TMJ pain. Manipulation of the jaw, medical treatment, occlusal equilibration, and use of a bite splint partially resolved the symptoms. Evolution of symptoms disclosed severe left TMJ pain and dysfunction followed by severe right TMJ pain. The patient also had headaches and true vertigo develop, and adapted a lifestyle revolving around her pain complex. Previous therapy consisted of analgesics, including narcotics, tranquilizers, muscle relaxants, oral steroids, steroid joint injections, multiple occlusal equilibrations, use of two bite planes, and an arthrogram. The arthrogram showed a perforation of the right meniscus. The patient also underwent bilateral mandibular coronoidectomies.

Initial examination showed tenderness to palpation of the bilateral temporalis, masseter, and external pterygoid muscles. The jaw opening was 21 mm at the central incisor edges with an opening painful snap on auscultation. Scarring was present intraorally on the coronoid processes.

Laboratory tests showed normal results

of a 12-factor automated chemical analysis, thyroid function tests, two-hour postprandial glucose tolerance level, and serologic study. Normal audiology test results included pure tones, speech reception threshold, discrimination, tympanogram, and stapedial reflexes. Electronystagmography showed nonspecific changes. Internal auditory canal roentgenograms were normal. Polytomography of the TMJs showed severe degenerative changes of the left condyle with osteophyte formation and flattening of the condyle and narrowed joint space. The right joint had moderate degenerative changes. The dynamic cinefluorography arthrogram showed a perforation of the left meniscus and a right anteriorly displaced meniscus.

Specialty consultations from neurology and psychiatry indicated, respectively, muscle contracture headaches and stress involvement centered around the chronicity of her pain symptoms.

Bilateral microsurgical TMJ arthroplasties were performed with a left high condylectomy and a right posterior repositioning and plication of meniscus. Findings at surgery showed a left irregular, flattened, degenerative articular surface of the condyle, osteophyte formation, and anterior lippling. There was a microperforation of the meniscus with granulation tissue. The right condyle articular surface had a small degree of irregularity. The meniscus was completely dislocated anteriorly with fibrosis preventing its posterior movement. Six months postoperatively the patient has an incisal opening of 44 mm with normal masticatory function and no TMJ pain.

CONCLUSION

The microsurgical approach to the TMJ is an exciting new horizon in the surgical management of temporomandibular disorders. The postauricular approach allows adequate exposure with a decreased occurrence of injury to the facial nerve and excellent cosmetic results. The operating microscope allows brilliant illumination with magnified vision. The function and pathologic conditions encoun-

tered are accurately evaluated and diagnosed. Microsurgery facilitates refinement of operations and innovation of new operations. Precision surgery allows gentle tissue manipulation, small incisions, meticulous hemostasis, and accurate removal of diseased tissue. Dissection anteriorly on the periosteum of the zygomatic arch lifts the superficial and middle layers of the temporalis fascia with the ear flap. Thus, the temporal and zygomatic branches of the facial nerve are protected and retracted out of the surgical field.

Flap designs and incisions of the fascia parotideomasseteria, temporomandibular ligament, capsule, and meniscus are established in accordance with the requirements of regional anatomy and function. The incisions and flaps are designed to minimize cicatrix formation and adhesion of layers, providing more normal postsurgical anatomy and function of the joint. This design also facilitates identification of the various levels of tissues to be sutured on closure. Supplemental technology also allows videotape recording, monitoring of the surgical procedure, and movie still photography. The two representative cases illustrate the complexity of symptoms, evaluation, and management.

Patients requiring surgery to date show encouraging asymptomatic results. In particular, patients with internal derangements of the TMJ without bony degenerative changes have findings that are observed dramatically with the microscope. Such patients postoperatively become functional and asymptomatic. These patients, traditionally, have been withheld from surgical procedures. However, duration of postoperative follow-up has not been long enough for adequate data.

References

1. Maier M, Lion H: Exper Nachweis d Empolymfbewegung. *Pfluegers Arch* 1921;187:1-3.
2. Nylen CO: The microscope in aural surgery: Its first use and later development. *Acta Otolaryngol* 1954;116(suppl):226-240.
3. Perritt RA: Recent advances in corneal surgery, abstracted. *Trans Am Acad Ophthalmol Otolaryngol* 1949-1950;54:428.
4. Kurze T: Microtechniques in neurological surgery, in *Clinical Neurosurgery*. Baltimore, Williams & Wilkins Co, 1964, vol 2, pp 129-137.
5. Kreutziger KL, Mahan PE: Temporomandibular degenerative joint disease: Part I. Anatomy, pathophysiology, and clinical description. *Oral Surg* 1975;40:165-182.
6. Kreutziger KL, Mahan PE: Temporomandibular degenerative joint disease: Part II. Diagnostic procedure and comprehensive management. *Oral Surg* 1975;40:297-319.
7. Bronstein SL, Tomasetti BJ, Ryan DE: Internal derangements of the temporomandibular joint: Correlation of arthrography with surgical findings. *J Oral Surg* 1981;39:572-584.
8. Nøgaard F: *Temporomandibular Arthrography*. Copenhagen, E Munksgaard, 1974, pp 29-80.
9. Berry HM Jr: Cineradiographic observation of temporomandibular joint function. *J Prosthet Dent* 1959;9:21-33.
10. Murphy WA: Arthrography of the temporomandibular joint. *Radiol Clin North Am* 1981;19:365-378.
11. Mahan PE, Kreutziger KL: Diagnosis and management of temporomandibular joint pain, in Ailing CE, Mahan PE (eds): *Facial Pain*, ed 2. Philadelphia, Lea & Febiger, 1977, chap 13.