

UDC: 615.262:616.5-005]:616.379-008.64-092.9

DOI: 10.18413/2500-235X-2017-3-1-32-48

Seletskaya V.V.,  
Galenko-Yaroshevskii P.A.
**DERMATOPROTECTIVE ACTIVITY OF A COMBINATION  
OF ENOXIFOL WITH REXOD IN A REDUCED FORM THE BLOOD  
CIRCULATION IN THE SKIN IN DIABETES MELLITUS  
AND HYPERCHOLESTERINEMIA**

 Kuban State Medical University, 4 Sedin St., Krasnodar, 350063, Russia.  
 e-mail: seleckaya.v@mail.ru

**Abstract.** Experiments in rats showed that the 9-diethylaminoethyl-2-(3,4-dioxyphenyl)-imidazo-[1,2-a]-benzimidazole dihydrobromide with the provisional name of enoxifol (0.94 – 15 mg/kg), rexod (recombinant human superoxide dismutase; 0.002 mg/kg) and especially their combination in intravenous administration in a reduced blood circulation in the skin against the background of the normoglycemia and hyperglycemia induced by experimental (alloxanic) diabetes mellitus complicated by exogenous hypercholesterinemia have a pronounced dose-dependent dermatoprotective effect, which may be due to the activation of energy processes and increase the reserve capacity of the antioxidant support network and normalization of carbohydrate and lipid metabolism. A combination of enoxifol with alprostadiol in normoglycemia increases significantly dermatoprotective activity of alprostadiol and exceeds the activity of the combination of enoxifol with rexod. Under the conditions of normoxia and hypoxia, induced by sodium cyanide, and uncouple of oxidative phosphorylation, induced by 2,4-dinitrophenol, a combination of enoxifol with rexod, increases the viability of cultured osteoblasts and fibroblasts. Enoxifol (7.5 mg/kg, intravenously) has anti-inflammatory effect in edema induced by carrageenan, histamine, serotonin and Freund's complete adjuvant. Enoxifol (7.5 mg/kg, intravenously), rexod (0.02 mg/kg, intravenously) and especially its combination have a pronounced antiulcer action on steroid ulcers of a stomach, enoxifol activity compare poorly of the sea buckthorn oil (10 ml/kg intraperitoneally); the combination of enoximone with rexod much is much superior as enoxifol, rexod and sea buckthorn oil taken from separately.

**Key words:** enoxifol, rexod, the combination of enoxifol with rexod, alloxanic diabetes mellitus, exogenous hypercholesterinemia.

**Introduction.**

Diabetes mellitus (DM), as one of the most severe socially significant diseases, often causes circulatory disorders in various organs and tissues, including a skin, inducing ischemic manifestations in them, and sometimes necrotic changes [1-7].

Occurring in diabetes mellitus disturbances of carbohydrate, protein and lipid-metabolism cause accumulation in the body of insufficiently oxidized metabolites, the suppression of energy production in cells, and, as a consequence, often lead to organ and system lesions [8, 9].

In the recent decades, molecular changes in the tissues in diabetes are widely studied, which helped to create some effective drugs: hypoglycemic, antihypoxic and antioxidants, as well as complex preparations [2, 10-15].

Currently available anti-diabetic drugs do not always meet the needs of practical health care [11, 16, 17]. This is due to the fact that many anti-diabetic

drugs can cause various side effects: allergic reactions, idiosyncrasy, hypoglycemia, and sometimes are ineffective. That's why the development of new drugs and their combinations, which would have antihyperglycemic and cholesterol-lowering effects and did not show significant side effects is actually today [18-20].

A substance with laboratory code RU-185<sup>1</sup> (9-diethylaminoethyl-2-(3,4-dioxyphenyl)-imidazo-[1,2-a]-benzimidazole dihydrobromide), called enoxifol and domestic drug rexod, constituting recombinant human superoxide dismutase, deserve attention for that matter.

<sup>1</sup> Synthesized in Research institute of physical and organic chemistry, southern Federal University, by a leading researcher, PhD in chemistry V. A. Anisimova, under the supervision of academician of Russian Academy of Sciences V.I. Minkin.

Several studies showed that the basis of the protective action of enoxifol in acute and chronic hypoxia, cerebral ischemia and reperfusion injuries, as well as normalizing effect of this substance in disseminated intravascular coagulation (DIC) and DM is antioxidative activity and hemobiological properties [21, 22].

Superoxide dismutase belongs to the group of antioxidant enzymes, represented by a family of metalloenzymes that catalyze the dismutation of the superoxide ( $O_2^-$ ) radical. Together with catalase and other antioxidant enzymes, superoxide dismutase protects the body from constantly produced highly-toxic oxygen radicals, catalyzes the dismutation of the superoxide ( $O_2^-$ ) into oxygen and hydrogen peroxide. Thus, superoxide dismutase plays an important role in antioxidant defence of cells, or otherwise in contact with oxygen.

It is known that diabetes mellitus leads to circulatory disorders and innervation of the basal layer of the skin, that leads to its atrophy and skin laxity. It leads to fissures and ulcerations of the skin, whereby the skin loses its protective function. Special type of diabetic skin lesions is lipoidica diabetorum, as well as hyperpigmentation, erythema and lipoatrophy. The development of such disorders is related to the phenomenon of "oxidative stress", which consists in the formation in the blood of a large number of free radicals – oxygen molecules with a high ability to react. As a result of such reactions the cells of the body can be damaged. In healthy body the accumulation of the free radicals is regulated by antioxidants, which neutralize them. However, in diabetic patients, formulation of antioxidants is significantly reduced. One of the main antioxidants that show activity in the mentioned direction is superoxide dismutase. Specific activity of superoxide dismutase in antioxidant defence is to 100,000 times higher of such traditional products, like vitamins A and E.

Therefore, it seemed expedient to study the protective effects of enoxifol in combination with superoxide dismutase preparation – rexod with reduced blood circulation in the skin on the background of alloxan diabetes complicated by exogenous hypercholesterolemia (EHC).

The research objective. To improve the survival of skin under condition of reduced blood circulation against the background of normo – and hyperglycemia and exogenous hypercholesterolemia by administration a combination of enoxifol with rexod; to perform in-depth preclinical study and to develop scientific and practical recommendations for its administration.

### Experimental procedure

The study of dermatoprotective activity of a combination of enoxifol with rexod were performed according to methods described by A.V. Zelenskaya, P.A. Galenko-Yaroshevskii [26].

Experiments were performed on 676 male rats weighing 0.120 – 0.220 kg.

*The study of survival of tail tissues in reduced circulation against the background of normoglycemia* was performed by the method described by A. V. Agadzhanova et al. [24] O. N. Stoyalova et al. [25].

*The study of viability of skin fold tissues of the back in circulatory disturbance against the background of normoglycemia* was performed according to P.A. Galenko-Yaroshevskii, A.V. Tegai [27].

*The study of viability of skin flap tissues of the anterior abdominal wall in reduced circulation (arterial insufficiency and venous stasis) against the background of normoglycemia, alloxanic diabetes mellitus and exogenous hypercholesterinemia was performed* by the method described by A.V. Zelenskaya, P.A. Galenko-Yaroshevskii [26] и P.A. Galenko-Yaroshevskii, A.V. Tegai [27]. The model of alloxanic diabetes mellitus was reproduced by a single intraperitoneal injection of alloxan at a dose of 135 mg/kg. Exogenous hypercholesterinemia was induced after 14 days of modeling of DM by 2 week intragastric administration of the cholesterol emulsion (40 mg/kg) + vegetable oil (0.5 ml). The emulsion was added the ergocalciferol (12500 U/kg) to enhance peroxide stress [26].

*The study of carbohydrate composition and lipid of the blood against the background of alloxanic diabetes mellitus and exogenous hypercholesterinemia under the influence of enoxifol, rexod and their combinations* was performed by using the analyzer "Konelab-30", Termoelektron firm.

*The study of the influence of enoxifol, rexod and their combination on the proliferation of cultured fibroblasts and osteoblasts of the skin and parietal bone respectively* was performed according A.V. Zelenskaya, P.A. Galenko-Yaroshevskii [26]. For imaging cell cultures were stained methylene blue and photographed with the use of digital system "MekoS" [26].

*Antiphlogogenic effect was studied on the traditional model of acute paw inflammation* induced carrageenan (1%), Freund's complete adjuvant (CAF), histamine (2 mM) and serotonin (0,1%) [28], which were administered in a volume of 0.1 ml subplantarly in the right hind paw.

**Antiulcer activity was investigated using a model of steroid-ethanol-induced gastric ulcer of the stomach [29].** Enoxifol was injected intravenous at the dose of 7.5 mg/kg (2 ml/kg of 0.1% solution). Warm (37° C) sea buckthorn oil, administered intragastrically (10 ml/kg), was used as reference drug.

**The study of the influence of enoxifol, rexod and their combination on values of energy metabolism, antioxidant system (AOS) and the activity of lysosomal enzymes of the skin fold of the back** was performed according to the methods described by A.V. Zelenskaya, P.A. Galenko-Yaroshevskii [26].

**Cytoprotective activity of enoxifol, rexod and their combination** was studied in the experiments on the skin fold of the back. The skin samples after removal of the subcutaneous fat were homogenized at 140000 rpm, extracting solution contained 0.45 of NaCl, 50 mM of Tris-buffer, pH 7.4. There were determined the concentrations of adenylic nucleotides, creatine phosphate (CP), the level of histamine and serotonin (fluorimetric method), enzymatic activity of alanine-aminotransferase (ALAT) and aspartate aminotransferase (ASAT) (using kit "Bio-La-Test", "Lachema"), lactate dehydrogenase (LDH) (using test kit "Diachem"), NADH-cytochrome C-reductase (on the basis of the transition between the oxidized form and reduced form), lysosomal enzymes ribonuclease and concentration of cathepsin D, the rate of formation of superoxide anion, the activity of AOS (for the activity of SOD and catalase [26]).

**Statistical data processing** was performed according to A.V. Zelenskaya, P.A. Galenko-Yaroshevskii [26], using developed at the Department of pharmacology of Kuban state medical University a software for the computer IBM PC XT (USA).

**Results and evaluation**

**A comparative study of histoprotective effect of enoxifol, rexod, alprostadil and their combinations in reduced circulation in the tail and the skin. The study of the histoprotective effect of enoxifol in experiments on the tails.** it was found that on the 3rd day after the administration of enoxifol at the doses 15 and 7.5 mg/kg length of necrosis of the tails were 1.6 and 0.6%, respectively, versus 2.9% in control, and the administration of the drug at the doses of 3.75 and 0.94 mg/kg – 0.1 and 0.3% versus 13.4% in the control group. The increase in survival of the tissues of the tail after administration of enoxifol at the doses of 15.0, 7.5, 3.75 and 0.94 mg/kg for 3 days was 44.8, 79.3, 99.3 and 97.8%, respectively (table. 1).

*Table 1*  
**The histoprotective effect of enoxifol in experiments on the rat tails (M ± m, n = 9)**

№	Drug	Dose, mg/kg	Length of the necrosis, %	
			3rd day, a	7 <sup>th</sup> day, b
1	Control (normal saline solution)	-	2.9 ± 2.5 (0.4 ÷ 5.4)	70.9 ± 6.6 (55.8 ÷ 86.0) <i>p<sub>a-b</sub> &lt; 0.001</i>
2	Enoxifol	15	1.6 ± 1.8 (-0.2 ÷ 3.4) [44.8] <i>p<sub>1-2</sub> &gt; 0.05</i>	27.3 ± 8.9 (6.7 ÷ 47.9) [61.5] <i>p<sub>1-2</sub> &lt; 0.01. p<sub>a-b</sub> &lt; 0.01</i>
3	Enoxifol	7.5	0.6 ± 0.5 (-0.5 ÷ 1.7) [79.3] <i>p<sub>1-3</sub> &gt; 0.05. p<sub>2-3</sub> &gt; 0.05</i>	14.3 ± 6.8 (-1.4 ÷ 30.0) [79.8] <i>p<sub>1-3</sub> &lt; 0.001. p<sub>2-3</sub> &gt; 0.05 p<sub>a-b</sub> &gt; 0.05</i>
4	Control (normal saline solution)	-	13.4 ± 5.8 (-0.1 ÷ 26.8)	72.6 ± 5.7 (63.0 ÷ 89.4) <i>p<sub>a-b</sub> &lt; 0.001</i>
5	Enoxifol	3.75	0.1 ± 0.5 (-1.0 ± 1.2) [99.3] <i>p<sub>4-5</sub> &lt; 0.05</i>	35.7 ± 10.0 (12.5 ÷ 58.7) [50.8] <i>p<sub>4-5</sub> &lt; 0.01. p<sub>a-b</sub> &lt; 0.01</i>
6	Enoxifol	0.94	0.3 ± 0.4 (-0.5 ÷ 1.1) [97.8] <i>p<sub>4-6</sub> &lt; 0.05. p<sub>5-6</sub> &gt; 0.05</i>	55.4 ± 1.8 (51.3 ÷ 59.5) [23.7] <i>p<sub>4-6</sub> &lt; 0.01. p<sub>5-6</sub> &gt; 0.05 p<sub>a-b</sub> &lt; 0.001</i>

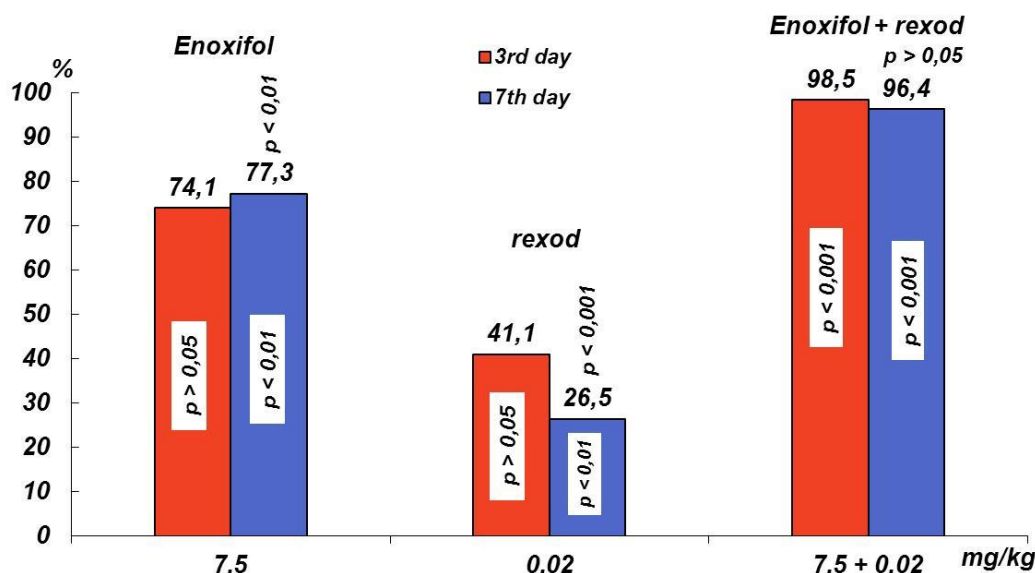
**Comment:** within the brackets: parentheses – 95% confidence interval, square – surviving part of the skin flap (%) in comparison with necrotic part of the skin flap in the control, accepted as 100%.

On the 7th day of the study with the administration of enoxifol at the doses of 15 and 7.5 mg/kg length of the necrosis was 27.3 and 14.3%, respectively, versus 70.9% in control, whereas when the drug was administered at the dose of 3.75 and 0.94 mg/kg the length of the necrosis was 35.7 and 55.4% vs 72.6% of the control. The increase in survival of the tail tissues on the back of enoxifol

administration at the doses of 15.0, 7.5, 3.75 and 0.94 mg/kg on the 7th day of the study amounted to 61.5, 79.8, 50.8 and 23.7%, respectively.

**The comparative study of histoprotective effect of enoxifol, rexod and their combination.** The experiments showed that on the 3rd day after intravenous administration of enoxifol (7.5 mg/kg), rexod (0.02 mg/kg) and their combination – enoxifol

(7.5 mg/kg) + rexod (0.02 mg/kg) the length of the tail necrosis was 2.9, 6.6 and 0.5% respectively versus 11.2 and 33.3% at the first and second controls. The survival of tissues on the back of administration of enoxifol, rexod and their combination amounted to 74.1, 41.1 and 98.5%, respectively (Figure 1).



**Figure 1.** The influence of intravenous administration of enoxifol, rexod and their combination on the survival of the tail tissues in the reduced blood circulation on the 3rd and 7th day of the study

The necrosis length of the tail on the 7th day was 16.4 and 53.4 and 2.6%, respectively, versus 72.4 and 72.0% in the first and second controls. The increase in survival of the tail tissues on the back of administration of enoxifol, rexod and their combination was 77.3, 26.5 and 96.4%, respectively.

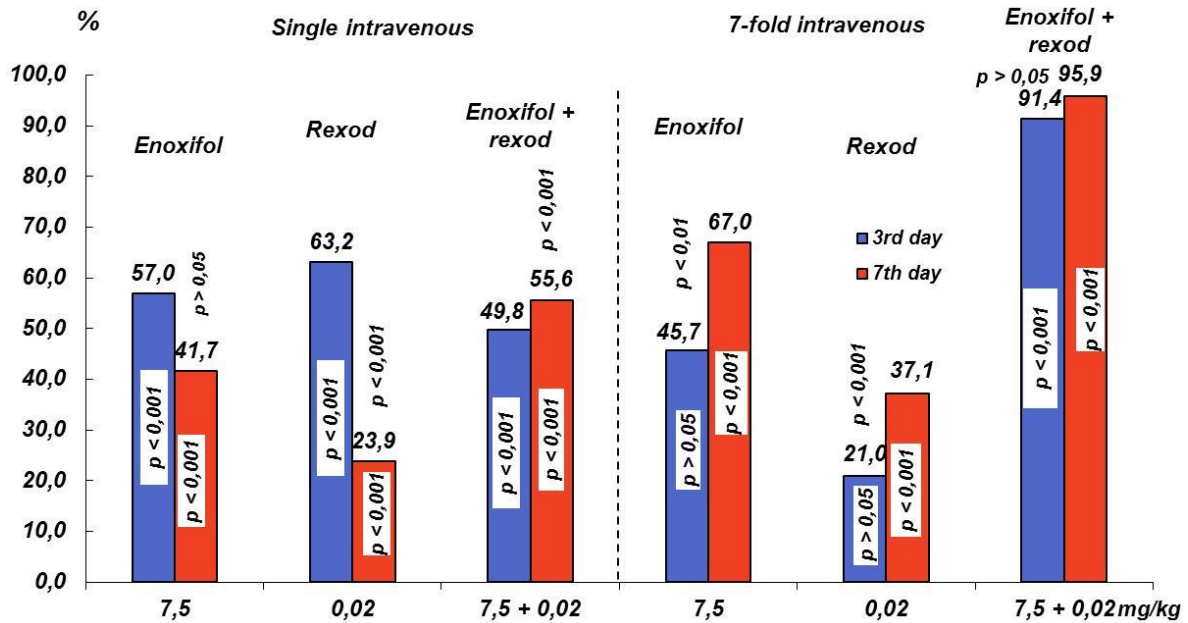
**A comparative study of the dermatoprotective effect of enoxifol, rexod and their combination in ischemic skin fold of the back.** It was found that after a single intravenous dosing of enoxifol (7.5 mg/kg), rexod (0.02 mg/kg) and their combination – enoxifol (7.5 mg/kg) + rexod (0.02 mg/kg) on the 3rd day of the experiment, the necrosis length of the skin fold of the back was 9.6, 8.2 and 11.2% respectively versus 22.3% in control. The survival rate of the skin equal 57.0, 63.2 and 49.8%, respectively.

On the 7th day of the study necrotic part of the skin fold was 41.5, 54.2 and 31.6% respectively, while in control it was 71.2%. The survival of the skin fold was 41.7, 23.9 and 55.6%, respectively (Figure 2).

With 7-fold intravenous dosing of enoxifol, rexod and their combination on the 3rd day of the experiment, the necrosis length of the skin fold of the back was 11.4, 16.6 and 1.8%, respectively, versus 21.0% of the control. The survival rate of the skin is equal to 45.7, 21.0 and 91.0%, respectively.

On the 7th day of the study necrotic part of the skin fold amounted to 30.6, 58.4 and 3.8%, respectively, while in control it was 92.9%. The survival of the skin fold was equal 67.0, 37.1 and 95.9%, respectively (Figure 2).

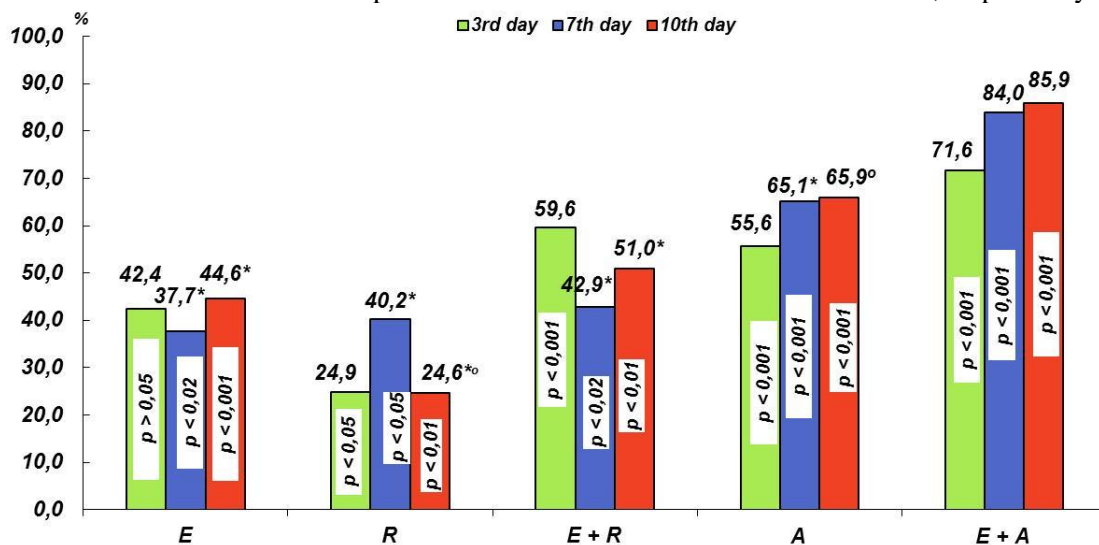




**Figure 2.** The influence of intravenous administration (single and sevenfold) of enoxifol, rexod and their combination on the survival of the ischemic skin fold of the back on the 3rd and 7th day of the study

*A comparative study of the dermatoprotective effect of enoxifol, rexod, alprostadi and their combination on the skin flap of the anterior abdominal wall in reduced circulation (arterial insufficiency and venous stasis).* Under condition of normoglycemia and arteriovenous failure induced by occlusion of the arteries and veins of the skin flap on one side, with a single intravenous administration of enoxifol (7.5 mg/kg), rexod (0.02 mg/kg), the combination of enoxifol (7.5 mg/kg) + rexod (0.02 mg/kg), alprostadi (0.00415 mg/kg) and combination of enoxifol (7.5 mg/kg) + alprostadi (0.00415 mg/kg), the necrosis area in the skin flap on the 3rd

day of the experiment was 20.1, 26.2, 14.1, 15.5 and 9.9%, respectively, versus 34.9% in the control (figure 3). The survival rate of skin was equal to 42.4, 24.9, 59.6, 55.6 and 71.6 %, respectively. On the 7th day necrosis in the skin flap under the effect of the drugs was 40.9, 39.3, 37.5, and 10.5% respectively, versus 65.7% in the control. The survival of the skin flap was equal to 37.7, 40.2, 42.9, 65.1 and 84.0%, respectively. On the 10th day of the experiment necrotic part of the skin flap reached 45.7, 62.2, 40.4, 28.1 and 12.0% respectively, versus 82.5% in the control. At that there was survived 44.6, 24.6, 51.0, 65.9 and 85.9% of the skin, respectively.



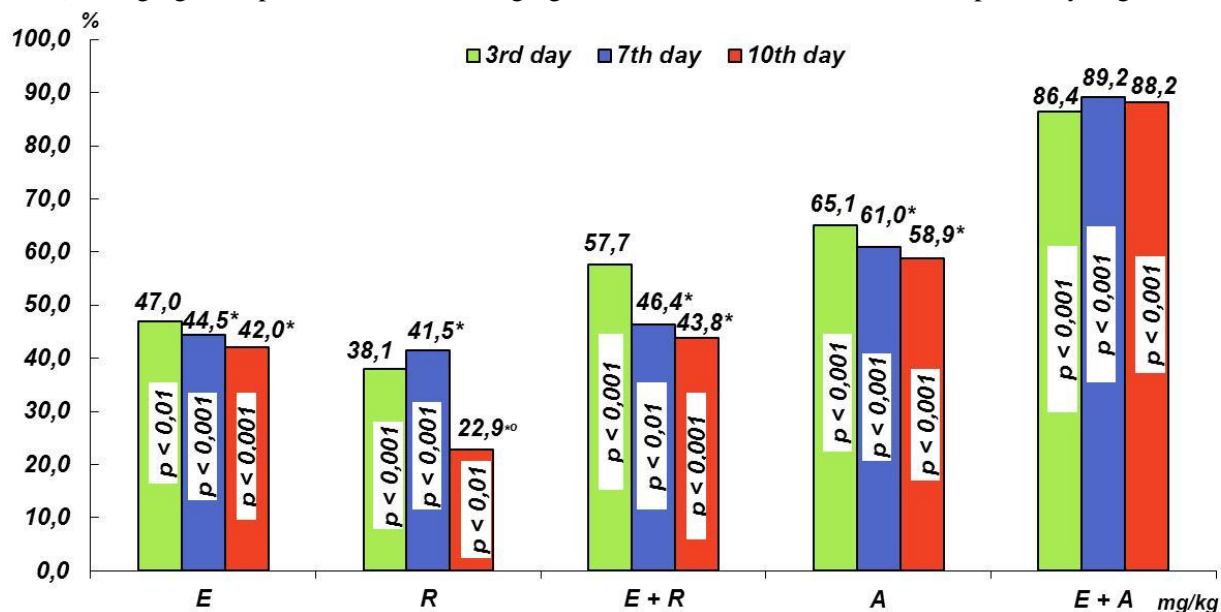
**Figure 3.** The influence of the single intravenous administration of enoxifol (E), rexod (R), combination enoxifol + rexod (E+R), alprostadi (A) and combination enoxifol + alprostadi (E+A) on the survival of the skin flap of the anterior abdominal wall in reduced circulation (arterial insufficiency and venous stasis) on the 3<sup>rd</sup>, 7<sup>th</sup> and 10<sup>th</sup> days of the study.

**Keys:** here and in figures 4 and 5: \* – 7<sup>th</sup> and 10<sup>th</sup> days statistically significantly in comparison with 3<sup>rd</sup> day, ° – 10<sup>th</sup> day statistically significantly in comparison with 7<sup>th</sup> day

We haven't studied a combination rexod (0.02 mg/kg) + alprostadil (0.00415 mg/kg) because the work of A. V. Zelenskaya, P. A. Galenko-Yaroshevskii [26] showed that this combination had no dermatoprotective activity.

Under condition of normoglycemia and arteriovenous failure induced by ligation of the arteries and veins of the skin flap on one side, with a repeated intravenous administration of enoxifol (7.5 mg/kg), rexod (0.02 mg/kg), the combination enoxifol (7.5 mg/kg) + rexod (0.02 mg/kg), alprostadil (0.00415 mg/kg) and combination enoxifol (7.5 mg/kg) + alprostadil (0,00415 mg/kg),

the necrosis area in the skin flap on the 3<sup>rd</sup> day of the experiment was 20.2, 23.6, 16.1, 13.3 and 5.2%, respectively, versus 38.1% in the control. The survival rate of the skin was equal to 47.0, 38.1, 57.7, 65.1 and 56.4%, respectively. On the 7<sup>th</sup> day, necrosis in the skin flap was 38.1, 40.2, 36.8, 26.8 and 7.4%, respectively, versus 68.7% in the control group. The increase in survival of the skin flap was 44.5, 41.5, 46.4, 61.0 and 89.2%, respectively. On the 10<sup>th</sup> day the skin necrosis was equal 46.9, 62.3, 45.4, 33.2 and 9.5%, respectively, versus 80.8% of the control. The survival rate of the skin flap was equal 42.0, 22.9, 43.8, 58.9 and 88.2%, respectively (figure 4).



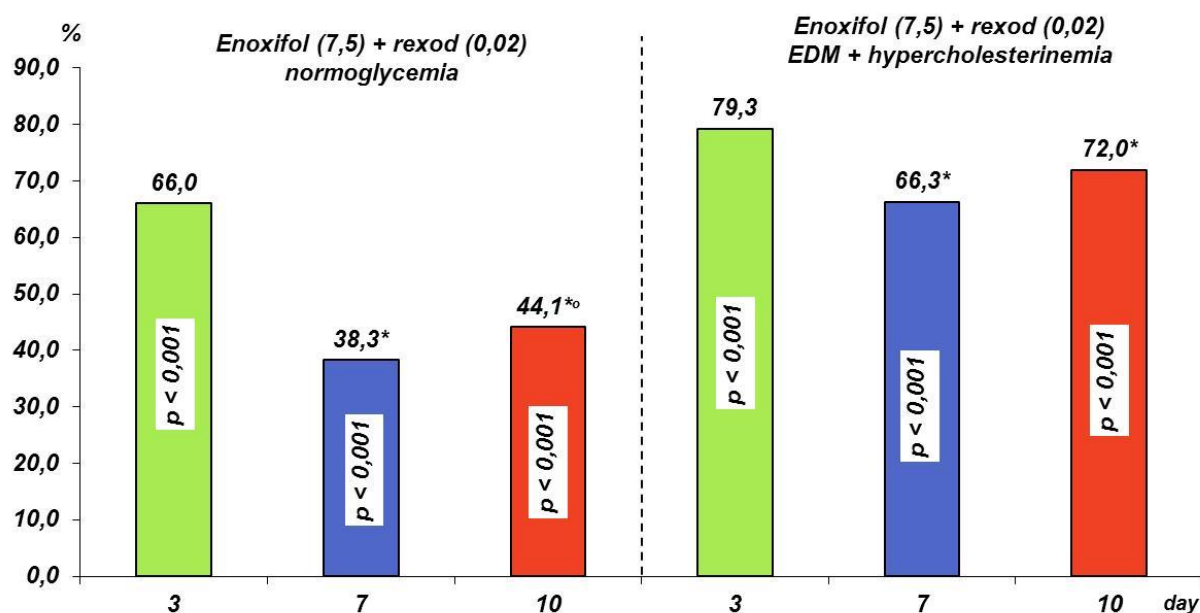
**Figure 4.** The influence of the sevenfold intravenous administration of enoxifol (E), rexod (R), combination enoxifol + rexod (E+R), alprostadil (A) and combination enoxifol + alprostadil (E+A) on the survival of the skin flap of the anterior abdominal wall in reduced circulation (arterial insufficiency and venous stasis) on the 3<sup>rd</sup>, 7<sup>th</sup> and 10<sup>th</sup> days of the study

*A study of the dermatoprotective effect of combination of enoxifol with rexod in experimental diabetes mellitus (EDM), complicated by exogenous hypercholesterinemia, in experiments on the skin flap of the anterior abdominal wall in case of partial arteriovenous failure.* It was found that administration of the combination enoxifol (7.5 mg/kg) + rexod (0.02 mg/kg) against the background of normoglycemia, the necrosis area of the anterior abdominal wall in case of partial arteriovenous failure at 3<sup>rd</sup>, 7<sup>th</sup> and 10<sup>th</sup> days was 9.8, 32.0 and 38.0% vs 28.8, 51.9 and 68.0% in controls. The survived part of the skin flap was equal 66.0, 38.3 and 44.1%, respectively.

When intravenous administration of a combination enoxifol (7.5 mg/kg) + rexod (0.02

mg/kg) for 14 days against the background of EDM complicated by exogenous hypercholesterinemia, on the 3<sup>rd</sup>, 7<sup>th</sup> and 10<sup>th</sup> days the necrosis area of the skin flap was equal 6.9, 23.2 and 23.2% versus 33.3, 63.2 and 82.8% in contros. The survived part of the skin was 79.3, 66.3 and 72.0, respectively.

In the control experiments (normal saline solution against the background of EDM and exogenous hypercholesterinemia) the necrosis area of the skin flap in comparison with group of intact animals (administration normal saline solution only) on the 3<sup>rd</sup>, 7<sup>th</sup> and 10<sup>th</sup> days statistically significantly decreased by 4.5, 11.3 and 14.8%, respectively (figure 5).



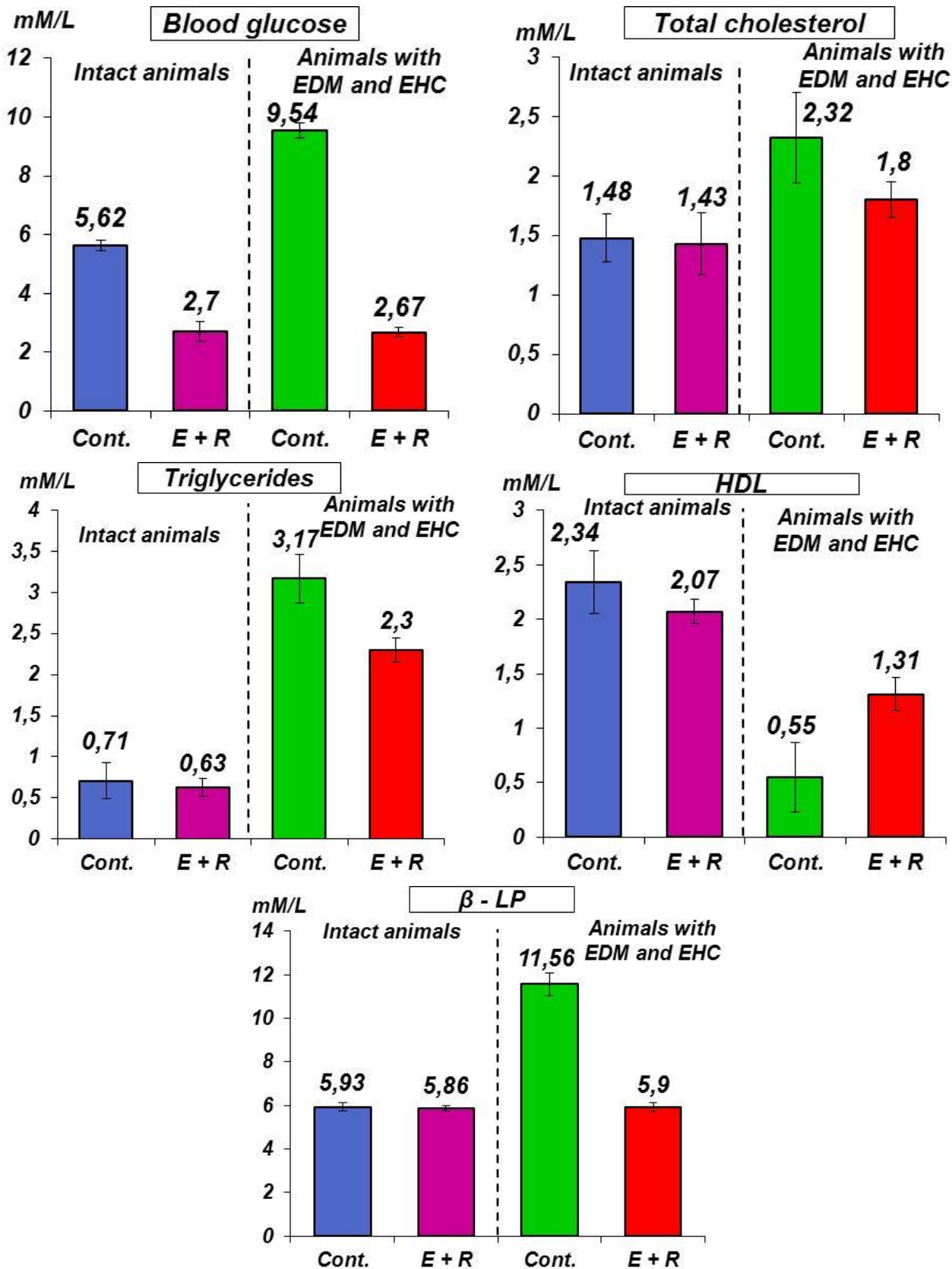
**Figure 5.** The influence of the repeated intravenous administration of combination enoxifol + rexod on the survival of the skin flap of the anterior abdominal wall in case of partial arteriovenous failure against the background of normoglycemia and exogenous hypercholesterinemia on the 3<sup>rd</sup>, 7<sup>th</sup> and 10<sup>th</sup> days of the study

Biochemical blood analysis found that the blood glucose in the group of animals with EDM and exogenous hypercholesterinemia amounted to 9.54% vs of 5.62% in the intact group, that is, the experimental rats were increased the level of the blood glucose in 1.7 times. In the case of combination enoxifol + rexod against the background of EDM and exogenous hypercholesterinemia the level of the blood glucose amounted to 2.67 mM/l versus 9.54 mM/l in the control group, that is, the blood glucose decreased in 3.6 times. When administrating the combination enoxifol + rexod in intact animals, the level of the blood glucose was 2.70 mM/l versus 5.62 mM/l in control; the level of the blood glucose decreased in 2.1 times (figure 6).

The total cholesterol in the control (normoglycemia) was 1.48 mM/l and in the group of animals with EDM and exogenous hypercholesterinemia it was 2.32 mM/l, that is, in the latter case, the level of total cholesterol increased in 1.6 times. When administration the combination enoxifol + rexod (against the background of EDM and exogenous hypercholesterinemia) the level of total cholesterol was 1.80 mM/l versus 1.48 mM/l in the control (intact animals), that is, there was a decrease in the level of total cholesterol in 1.2 times. Against the background of normoglycemia in experimental rats it level (1.43 mM/l) did not differ (1.48 mM/l) from control.

Triglycerides level in control (normoglycemia) was 0.71 mM/l and in the group of animals with EDM and exogenous hypercholesterinemia it was 3.17 Mm/l, i.e. in the latter case, it had increased in 4.5 times. When administration the combination enoxifol + rexod (against the background of EDM and exogenous hypercholesterinemia) the level of triglycerides was 2.30 mM/l vs. 3.17 mM/l in the corresponding control, i.e., it decreased in 1.4 times. Under condition of normoglycemia combination enoxifol + rexod (0.63 mM/l) had no significant effect on triglycerides in comparison with the control group (0.71 mM/l).

$\beta$ -lipoproteins ( $\beta$ -LP) in control (normoglycemia) was 5.93 mM/l, and in the group of animals with EDM and exogenous hypercholesterinemia it was 11.56 mM/l, i.e. in the latter case the level of  $\beta$ -LP was increased in 1.9 times. The level of  $\beta$ -LP after administration the combination enoxifol + rexod in the group of animals with EDM and exogenous hypercholesterinemia was equal to 5.90 mM/l versus 11.56 mM/l in the corresponding control, i.e. there was a decrease of it in the former case in 2.0 times. Under condition of normoglycemia combination enoxifol + rexod (5.86 mM/l) had no significant effect on the  $\beta$ -LP level in comparison with the control group (5.93 mM/l).



**Figure 6.** The influence of the combination enoxifol + rexod (E + R, 7.5 + 0.02 m/kg) (intravenous administration for 14 days) on the level of the glucose, total cholesterol, triglycerides, high density lipoproteins (HDL) and  $\beta$ -lipoprotein against the background of normoglycemia, EDM and exogenous hypercholesterinemia



The level of high density lipoproteins (HDL) in control (normoglycemia) was 2.34 mM/l and in the group of animals with EDM and exogenous hypercholesterinemia it was 0.55 mM/l, i.e. in the latter case, the level of HDL decreased in 4.3 times. The HDL level in consequence of administration of the combination enoxifol + rexod against the background of EDM and exogenous hypercholesterinemia was equal to 1.31 mM/l vs 0.55 mM/l in the corresponding control, i.e. there was an increase of HDL level in 2.4 times. Under condition of normoglycemia, combination enoxifol + rexod (2.07 mM/l), had no significant effect on the HDL level in comparison with the control group (2.34 mM/l) (figure 6).

**A study of some of the parties in an mechanism of dermatoprotective effect of enoxifol, rexod and its combination.** *The influence of enoxifol, rexod and its combination on the viability of the cultured fibroblasts and osteoblasts against the background of normoxia, hypoxia and uncouple of oxidative phosphorylation.* *The influence on the proliferative activity of FB.* It was found that in the control studies, the optical density of the cultivated FB samples was 2140.0 conditional units (c.u.). The administration of enoxifol at a concentration of 0.01 and 0.001 mg/ml, rexod at a concentration of 0.0001, 0.0005 and 0.001 mg/ml, the combination of enoxifol (0.01, 0.001 and 0.01 mg/ml) + rexod (0.0001, 0.0005 and 0.001 mg/ml) the optical density of the samples was equal 2284.0 and 2325.0, 1794.0, 1882.0 and 1982.0, 2284.0, 2357.0 and 1982.0 c.u., respectively; there was no statistically significant differences in comparison with control.

A study of the influence of enoxifol, rexod and its combination under condition of hypoxia of FB caused by 0.2 mM NaCN found that in control (administration NaCN only) the optical density of the cultivated FB samples was 1139.0 c.u.; it was statistically significant ( $p < 0.05$ ) in comparison with intact FB. The administration of enoxifol, rexod and its combination in the above concentrations against the background of NaCN as in the previous series of experiments did not cause statistically significant changes of the optical density of the cultivated FB samples in comparison with the control (NaCN): values of the optical density of the cultivated FB samples were equal 1448.0 and 1321.0, 935.0, 994.0 and 1050.0, 995.0, 1324.0 and 1388.0 c.u., respectively.

A study of the influence of enoxifol, rexod and its combination on the proliferative activity of FB against the background of uncouple of oxidative phosphorylation by dinitrophenol found that in the control (administration of dinitrophenol only), the viability of FB statistically significantly decreased and amounted 540.0 c.u. ( $p < 0.05$ ).

The administration of enoxifol, rexod and especially its combination at the selected concentrations

the optical density of the cultivated FB samples significantly ( $p < 0.05$  in all experimental groups) increased, accounting for 778.0 and 637.0, 763.0, 725.0 and 751.0, 922.0, 804.0 and 796.0 c.u., respectively.

*The influence on the proliferative activity of osteoblasts (OB).* Performed experiments showed that in the control the optical density of the cultivated OB samples was 1464.0 c.u. Administration of enoxifol at the concentrations of 0.01 and 0.001 mg/ml, rexod at the concentrations of 0.0001, 0.0005, 0.001 mg/ml, the combination enoxifol (0.01, 0.001 and 0.01 mg/ml) + rexod (0.0001, 0.0005 and 0.001 mg/ml) didn't show significant of the optical density of the cultivated OB samples in comparison with the control. The optical density of the cultivated OB samples was equal to 1726.0 and 1621.0, 1296.0, 1425.0 and 1646.0, 1695.0, 1677.0 and 1554.0 c.u., respectively.

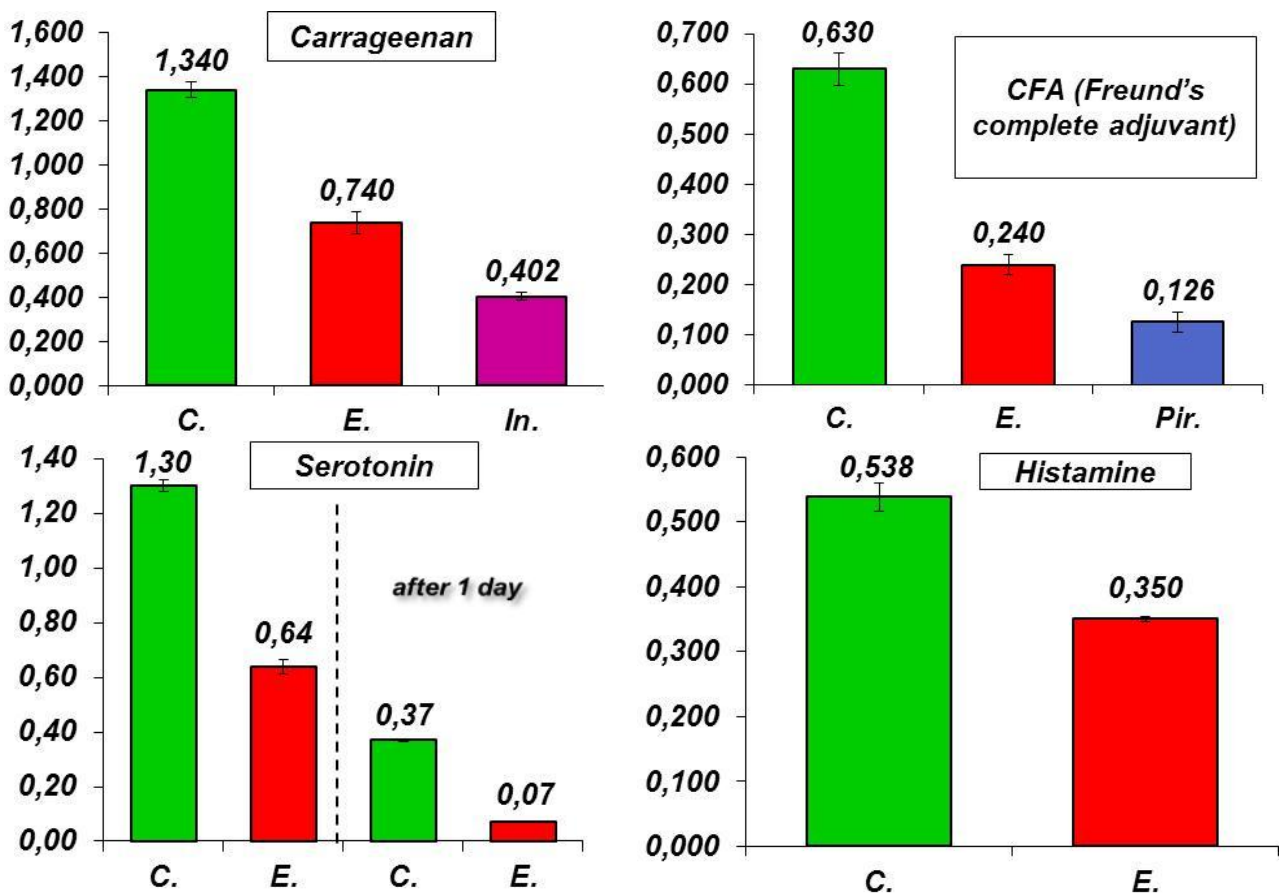
Administration of the studied drugs and its combination in the above concentrations against the background of hypoxia of OB induced by 0.2 mM NaCN, found that the proliferative activity of OB under the influence of enoxifol (1327.0 and 1256.0 c.u.) and rexod (1171.0, 1168.0 and 1057.0 c.u.), did not change significantly in comparison with control (1138.0 c.u.), whereas administration of the combination of enoxifol (0.01 and 0.001 mg/ml) + rexod (0.0001 and 0.0005 mg/ml) statistically significantly increased the optical density of the cultivated OB samples (1486.0 and 1439.0 c.u., respectively). It should be noted that with increase in combination enoxifol (0.01 mg/ml) + rexod the concentration of the latter to 0.001 mg/ml the proliferative activity of OB samples (1236.0 c.u.) did not differ significantly from control.

The study of the influence of enoxifol, rexod and its combination on the proliferative activity of OB against the background of uncouple of oxidative phosphorylation by dinitrophenol (0.5 mM) found that in the control (administration of dinitrophenol only), the viability of OB statistically significantly decreased (818,0 c.u.) in comparison with intact OB. The administration of researched drugs and its combination in the above experimental conditions showed that the optical density of the cultivated OB samples of enoxifol, taken at a concentration of 0.01 mg/ml, statistically significantly increased (1092.0 c.u.,  $p < 0.05$ ), but with increasing concentration (up to 0.001 mg/ml) it decreased (914.0 c.u.) and did not differ from control. A similar situation occurred when administrating rexod: in its concentrations of 0.0001 and 0.0005 mg/ml the OB viability a statistically significantly increased in comparison with control (dinitrophenol), the optical density of the cultivated OB samples was respectively equal to 1234.0 and 1084.0 c.u., while with increasing concentration up to 0.001 mg/ml, the optical density of the cultivated OB samples

did not differ from control. The combination of enoxifol with rexod, in which the first drug was administered at a concentration of 0.01 mg/ml, and the second – 0,0001 mg/ml increased the cultured OB viability, while the optical density of the cultivated OB samples was 1136.0 c.u. Increase in the mentioned combination the concentrations of enoxifol (0.001 and 0.01 mg/ml) and rexod (0.0005 and 0.001 mg/ml) had no significant influence on the OB proliferative activity in comparison with control. The optical density of the cultivated OB samples was 969.0 and 1056.0 c.u., respectively.

**The influence of enoxifol on acute inflammation.** It was found, that intravenous administration of enoxifol at the dose of 7.5 mg/kg

takes anti-inflammatory action in the models of acute exudative edema induced by different phlogogens: carrageenan, Freund's complete adjuvant (CFA), histamine and serotonin. Thus, the inhibition of edema in different series of experiments under the influence of the drug was: carragenine – 42.8%, CFA – 60.3% and histamine – 35.0%. While the first two models of edema enoxifol lost anti-inflammatory activity to reference drugs – indomethacin (10 mg/kg) and, to a lesser extent, piroxicam (20 mg/kg); the inhibition of inflammation by lasts was 70.0 and 68.1%, respectively (figure 7).



**Figure 7.** The influence of enoxifol (E), indomethacin (In) and piroxicam (Pir) on the acute edematization, induced by carrageenan, CFA, serotonin and histamine.

Modeling of the inflammatory edema induced by serotonin, the measurement of paw edema after 45 min and 24 h after induction of edema showed that the anti-inflammatory effect in animals treated with enoxifol, after 1 day not only kept, but were even more pronounced in comparison with the short observation period (45 min); inhibition of inflammation in the first case was 51.0%, and in the second – 81.1% (figure 7).

**A study of antiulcer activity of enoxifol, rexod and its combination in steroid-ethanol damage of a**

**gastric mucosa.** In the control studies (single intragastric administration of prednisolone at a dose of 20 mg/kg in 80% ethanol) animal gastric mucosa was hyperemic, hemorrhages, pronounced vascularization, significant erosions and ulcers were observed across the mucosa. Micromorphology showed polymorphocellular infiltration with predominance of neutrophils of a lamina propria of the mucosa and submucosa, having an essentially focal character. There were leukopedesis, paravasal granulocytes. Mucoïd cells spread more deeply. There was observed the desquamation of

surface mucous cells, typical for ulcerous erosive involvement of the stomach with pronounced burned-

out. The ulcers area was on average of 6.4 mm<sup>2</sup> or 4.7 ulcerous erosive involvement in one animal (figure 8).

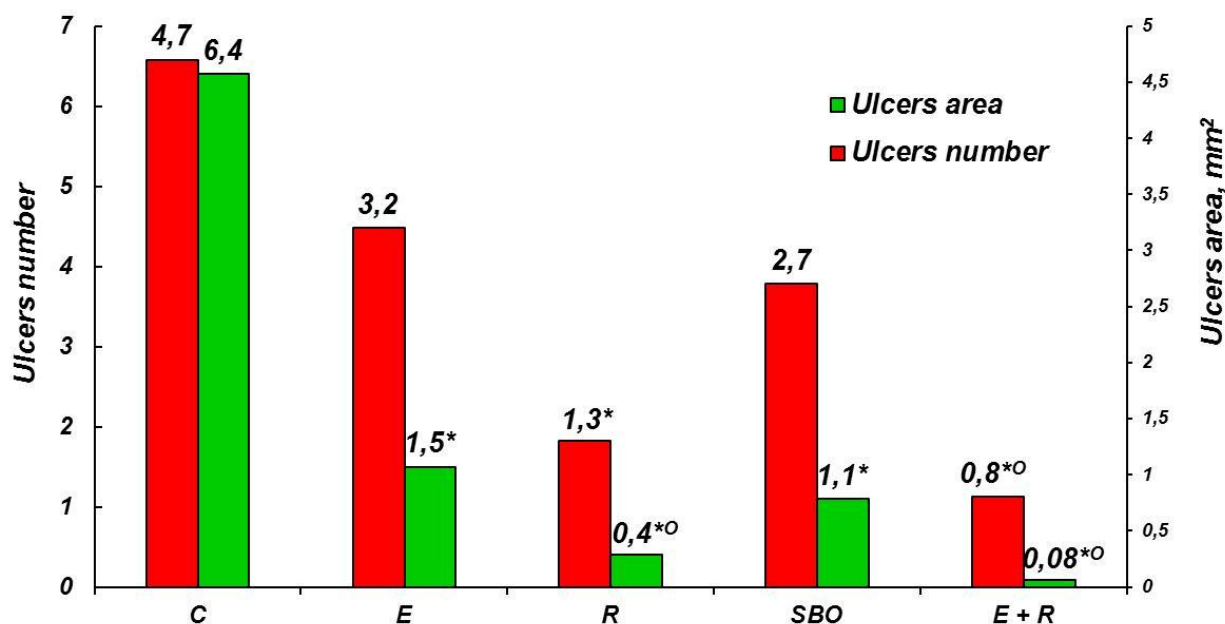


Figure 8. Antiulcer activity of enoxifol (E), rexod (R), sea buckthorn oil (SBO) ad combination enoxifol + rexod (E + R) in steroid-ethanol damage of a gastric mucosa.

Under the influence of the intravenous administration of enoxifol (7.5 mg/kg) and, to a greater extent, rexod (0.02 mg/kg) there was observed statistically significant (compared to control) reduction of the ulcers area of the gastric mucosa, that was 1.5 and 0.4 mm<sup>2</sup>, respectively. While micromorphology of the gastric mucosa did not significantly differ from it in control. As for antiulcer activity of SBO, taken as the reference drug, under its influence ulcers area of the gastric mucosa was equal to 1.1 mm<sup>2</sup> and statistically significantly differed from the control. Micromorphological changes were focal diffuse: granulocytes dominated among the free cellular elements, there were detected intraepithelial isolated leucocytes, glandular epithelium and surface mucous cells had signs of dystrophy and vacuolization (figure 8).

Intravenous administration of the combination enoxifol + rexod (E + R) took a pronounced gastroprotective effect: the ulcers area of the gastric mucosa was equal to 0.08 mm<sup>2</sup>. Micromorphologically there wasn't noted pathological changes typical for ulcerous involvement of the stomach, such as pronounced edema of the mucous and submucous, ganglia of myenteric nervous plexus. A gastric mucosa angioarchitecture has not been disrupted. Infiltrative changes were diffuse.

On antiulcer activity the studied drugs can be arranged in the following descending range: enoxifol + rexod > rexod > SBO > enoxifol.

*A study of the influence of enoxifol, rexod and its combination on the indices of intensity of the necrotic process, antioxidant defence and energy metabolism in the skin fold of the back. The influence on the indices of intensity of the necrotic process in ischemic skin.* It was found, that there were statistically significantly increase the concentration of creatine phosphokinase (CPK) in the blood (263.4%) and activity of LDH, ALAT and ASAT by 64.7, 49.2 and 40.9%, respectively in the control group of animals (ischemic skin) in comparison with intact group; killing titer increased by 156.5% (table 2).

Intraperitoneal administration of enoxifol at a dose of 7.5 mg/kg significantly decreased the concentration of CPK by 37.2% and LDH activity by 21.4% in blood of experimental groups of animals in comparison with the control group. The activity of ALAT and ASAT did not change significantly. Killing titer decreased by 33.3% (table 2).

Administration of rexod (0.02 mg/kg) in the adopted experimental conditions significantly decreased the concentration of CPK by 38.5% in comparison with control group of animals. The activity of ASAT was reduced by 10.6%. Other indices (LDH, ALAT and the killing titer) did not change significantly (table 3).

Table 2

**Antinecrotic effect of enoxifol (7.5 mg/kg) in ischemic skin (M ± m, n = 8)**

Index	Intact group	Ischemic skin	
		Control group	Experimental group
CPK, mIU/L	7.1 ± 0.2	25.8 ± 1.6*** (263.4)	16.2 ± 0.6*** <sup>xx</sup> 128.2/-37.2
LDH, mM NAD/mg of protein per min	0.17 ± 0.02	0.28 ± 0.01*** (64.7)	0.22 ± 0.01*** 29.4/-21.4
ALAT, mmM/ml	1.77 ± 0.20	2.64 ± 0.18** (49.2)	2.32 ± 0.12* 31.1/-12.1
ASAT, mmM/ml	1.15 ± 0.04	1.62 ± 0.10*** (40.9)	1.53 ± 0.20 33.0/-5.6
killing titer, CPK/ASAT	6.2 ± 0.3	15.9 ± 1.8*** (156.5)	10.6 ± 1.4*** <sup>x</sup> 71.0/-33.3

\**p* < 0.05, \*\**p* < 0.01, \*\*\**p* < 0.001 in comparison with intact group; <sup>x</sup>*p* < 0.05, <sup>xx</sup>*p* < 0.001 in comparison with control group.

Comment: 1. Here and in tables 3-7: 1. within the brackets – indices in percentage terms in relation to intact group. 2. in the numerator – indices in percentage terms in relation to intact group, in the denominator – indices in percentage terms in relation to control group.

Table 3

**Antinecrotic effect of rexod (0.02 mg/kg) in ischemic skin (M ± m, n = 7)**

Index	Intact group	Ischemic skin	
		Control group	Experimental group
CPK, mIU/L	7.7 ± 0.4	29.9 ± 2.2*** (288.3)	18.4 ± 0.8*** <sup>xx</sup> 139.0/-38.5
LDH, mM NAD/mg of protein per min	0.19 ± 0.01	0.32 ± 0.02*** (68.4)	0.26 ± 0.02* 36.8/-18.7
ALAT, mmM/ml	1.96 ± 0.10	2.96 ± 0.19*** (51.0)	2.69 ± 0.11*** 37.2/-9.1
ASAT, mmM/ml	1.19 ± 0.05	1.70 ± 0.04*** (42.9)	1.52 ± 0.07* <sup>x</sup> 27.7/-10.6
killing titer, CPK/ASAT	6.6 ± 0.4	16.3 ± 2.6*** (147.0)	12.8 ± 1.5** 93.9/-21.5

\**p* < 0.01, \*\**p* < 0.002, \*\*\**p* < 0.001 in comparison with intact group; <sup>x</sup>*p* < 0.05, <sup>xx</sup>*p* < 0.01, <sup>xxx</sup>*p* < 0.001 in comparison with control group.

Administration of combination of enoxifol (7.5 mg/kg) with rexod (0.01 mg/kg) decreased the concentration of CPK by 38.8% in comparison with the control group of animals. The activity of LDH,

ALAT and ASAT decreased by 30.6, 23.7 and 31.6% respectively. Killing titer did not change significantly (table 4).

Table 4

**Antinecrotic effect of enoxifol (7.5 mg/kg) + rexod (0.02 mg/kg) in ischemic skin (M ± m, n = 8)**

Index	Intact group	Ischemic skin	
		Control group	Experimental group
CPK, mIU/L	7.9 ± 0.3	28.6 ± 1.8** (262.0)	17.5 ± 0.5*** <sup>xxx</sup> 121.5/-38.8
LDH, mM NAD/mg of protein per min	0.18 ± 0.02	0.36 ± 0.02** (100.0)	0.25 ± 0.01*** <sup>xxx</sup> 38.9/-30.6
ALAT, mmM/ml	1.87 ± 0.10	3.80 ± 0.20** (103.2)	2.90 ± 0.10*** <sup>xxx</sup> 55.1/-23.7
ASAT, mmM/ml	1.21 ± 0.06	1.90 ± 0.20* (57.0)	1.30 ± 0.10 <sup>x</sup> 7.4/-31.6
killing titer, CPK/ASAT	6.5 ± 0.4	15.1 ± 1.5** (132.3)	13.4 ± 1.9* 106.2/-11.3

\**p* < 0.01, \*\**p* < 0.001 in comparison with intact group; <sup>x</sup>*p* < 0.02, <sup>xx</sup>*p* < 0.002, <sup>xxx</sup>*p* < 0.001 in comparison with control group.



It should be noted that of all the studied indicators of the intensity of the necrotic process, only the ASAT activity in the blood of experimental group of animals was almost comparable to it of the intact group when administration of enoxifol and its combination with rexod.

*The influence on metabolic processes in ischemic skin flap:*

– *the influence of enoxifol on the indices of the antioxidant defense and energy metabolism in the ischemic skin.* Previously, in our laboratory in the study of the influence of enoxifol on the system of energy supply, the antioxidant defense and the activity of lysosomes (histamine, cytochrome C, NAD·H – cytochrome of C-reductase, NAD<sup>+</sup>, NAD·H, NAD<sup>+</sup>/NAD·H, NAD<sup>+</sup> + NAD·H, SOD, Cu, Zn-SOD, catalase, oxyproline, cathepsin D, ribonuclease, alkaline phosphatase (ALP), β-galactosidase and the total nitrogen content) of the skin flap (on pedicle) there was showed the mechanism of dermatoprotective effect of enoxifol (RU-185) may be due to its ability to rectify the free-radical oxidation processes, to activate glycolysis and the reactions of the respiratory chain; to

influence the arachidonic acid metabolism, synthesis and breakdown of proteins and nucleic acids and associated with this, the activity of lysosomal enzymes;

– *the influence of rexod on the indices of the antioxidant defense and energy metabolism in the ischemic skin.* We have found that in the control group of animals (with a simulated skin ischemia) there was a statistically significant increase the rate formation of O<sup>2-</sup> (RFO<sup>2-</sup>) (by 93.9%), malondialdehyde (MDA) (by 8.0%), while SOD activity was decreased (by 25.9%); the glutathione peroxidase (GP) and catalase activity did not change significantly (table 5).

Intraperitoneal administration of rexod at a dose of 0.02 mg/kg in homogenates of the ischemic skin of the experimental group of animals statistically significant increased (by 70% and 24.0% respectively) the activity of SOD and GP, while the concentration of MDA was reduced (by 10.6%) in comparison with control group. RFO<sup>2-</sup> and catalase activity did not change significantly (table 6).

Table 5

**The influence of rexod (0.02 mg/kg) on the antioxidant defense in the ischemic skin (M ± m, n=7)**

Index	Intact group	Ischemic skin	
		Control group	Experimental group
RFO <sup>2-</sup> , μM/mg of protein × min	33.0 ± 5.0	64.0 ± 6.0*** (93.9)	66.0 ± 6.0*** 100.0/3.1
SOD, U/mg of protein × min	0.27 ± 0.01	0.20 ± 0.01**** (-25.9)	0.34 ± 0.02*** <sup>x</sup> 25.9/70.0
GP, nM NAD/mg of protein	2.4 ± 0.1	2.5 ± 0.1 (4.2)	3.1 ± 0.2*** <sup>x</sup> 29.2/24.0
Catalase, nM H <sub>2</sub> O <sub>2</sub> /mg of protein × min	71.0 ± 2.0	64.0 ± 4.0 (-9.9)	72.0 ± 4.0* 1.4/12.5
MDA, μM/mg of protein	0.87 ± 0.01	0.94 ± 0.03* (8.0)	0.84 ± 0.02 <sup>x</sup> -3.4/-10.6

\**p* < 0.05, \*\**p* < 0.01, \*\*\**p* < 0.002, \*\*\*\**p* < 0.001 in comparison with intact group;

<sup>x</sup>*p* < 0.02, <sup>xx</sup>*p* < 0.001 in comparison with control group.

In the study of the influence of rexod on the energy state of the ischemic skin, it was found that in the control group of animals the concentration of ADP and lactate in homogenates statistically significantly increased (by 13.9 and 47.6%, respectively), while the activity of succinate dehydrogenase (SDH) decreased (by 9.6%), LDH increased (68.4%) in comparison with intact group. Other indices (cytochrome C, AMP, NAD<sup>+</sup>, NAD·H, pyruvate and lactate/pyruvate ratio) did not change significantly (table 6).

Intraperitoneal administration of rexod at the dose of 0.02 mg/kg in homogenates of the skin of the experimental group of animals increased the content of NAD<sup>+</sup>, NAD<sup>+</sup>/NAD·H ratio, coenzyme Q10 (by 15.5, 20.5 and 57.2%, respectively), and decreased the concentration of lactate (by 15.6%) in comparison with control group. As for the content of cytochrome C, ATP, ADP, AMP, AP, NAD·H, pyruvate, lactate/pyruvate ratio and the activity of SDH and LDH, it did not change significantly (table 6).

Table 6

**The influence of rexod (0.02 mg/kg) on the system of energy supply in the ischemic skin (M ± m, n=7)**

Index	Intact group	Ischemic skin	
		Control group	Experimental group
Cytochrome C, μM/mg	0.99 ± 0.04	0.92 ± 0.01 (-7.1)	0.92 ± 0.01 -7.8/0.0
ATP, μM/g	3.51 ± 0.04	2.54 ± 0.10**** (-27.6)	2.71 ± 0.11**** -22.8/6.7
ADP, μM/g	1.44 ± 0.03	1.64 ± 0.03**** (13.9)	1.60 ± 0.02**** 11.1/-2.4
AMP, μM/g	0.53±0.04	0.65±0.04 (22.6)	0.69±0.04** 30.2/6.2
AP, μM/g	4.2 ± 0.1	3.1 ± 0.2*** (-26.2)	3.6 ± 0.2* -14.3/16.1
NAD <sup>+</sup> , μM/g	2.75 ± 0.05	2.0 ± 0.1 (-27.3)	2.31 ± 0.06**** <sup>x</sup> -16.0/15.5
NAD <sup>+</sup> ·H, μM/g	2.72 ± 0.06	2.75 ± 0.1 (1.1)	2.6 ± 0.08 -4.4/-5.5
NAD <sup>+</sup> /NAD·H	0.99 ± 0.02	0.73 ± 0.05**** (-26.3)	0.88 ± 0.02**** <sup>xx</sup> -11.1/20.5
Coenzyme Q <sub>10</sub> , mcg/g	1612.0 ± 68.0	927.0 ± 54.0 **** (-42.5)	1463.0 ± 67.0 <sup>xxx</sup> -9.2/57.2
Lactate, mcg/g	351.0 ± 24.0	518.0 ± 21.0**** (47.6)	437.0 ± 22.0* <sup>x</sup> 24.5/-15.6
Pyruvate, mcg/g	5.4 ± 0.3	6.7 ± 0.6 (24.1)	6.3 ± 0.4 16.7/-6.0
Lactate / Pyruvate	66.0 ± 6.0	82.0 ± 9.0 (24.2)	75.0 ± 6.0 13.6/-8.5
SDH, mcg of formazan /mg of protein × min	5.2 ± 0.2	4.7 ± 0.1* (-9.6)	4.7 ± 0.1* -9.6/0.0
LDH, nM NAD/mg of protein × min	0.19 ± 0.01	0.32 ± 0.02**** (68.4)	0.26 ± 0.02*** 36.8/-18.7

\**p* < 0.05, \*\* *p* < 0.02, \*\*\* *p* < 0.01, \*\*\*\* *p* < 0.001 in comparison with intact group; <sup>x</sup>*p* < 0.05, <sup>xx</sup> *p* < 0.02, <sup>xxx</sup> *p* < 0.001 in comparison with control group.

- the influence of combination of enoxifol with rexod on indices of energy supply, the antioxidant defense and lysosomal activity in ischemic skin. It was found that in the control group of animals (ischemic skin fold of the back), there was observed a statistically significantly decrease (by 79.6, 34.1, 34.1, 21.3, 36.3, 13.3 and 16.1% respectively) the content in the skin homogenates of ATP, ATP/AMP ratio, AP, cytochrome C, coenzyme Q<sub>10</sub>, the activity of SDH and consolidated figures for NAD<sup>+</sup> + NAD·H, while the concentration of LDH increased; the content of ADP, AMP, pyruvate and the lactate/pyruvate ratio, the activity of NAD·H-cytochrome of C-reductase, NAD<sup>+</sup>, NAD·H, NAD<sup>+</sup>/NAD·H ratio did not change significantly in comparison with intact group (table 7).

Intraperitoneal administration of the combination enoxifol (7.5 mg/kg) + rexod (0.01 mg/kg) statistically significantly increased the content of AP, coenzyme

Q10 and consolidated figures for NAD<sup>+</sup> + NAD·H (24.1, 30.7 and 14.6%, respectively) in the ischemic skin homogenates of the experimental group of animals in comparison with control group, while lactate concentration decreased (by 19.9%). Other indices (ATP, ADP, AMP, ATP/AMP ratio, cytochrome C, pyruvate, lactate/pyruvate ratio and the activity of SDH, NAD·H-cytochrome of C-reductase, NAD<sup>+</sup>, NAD·H and NAD<sup>+</sup>/NAD·H ratio) were unchanged (table 7).

Indices of the antioxidant defense and a condition of the hydrolytic function of lysosomes also changed: in the control group of animals (with the skin ischemia) there were increased RFO<sup>2-</sup>, activity of the catalase, cathepsin D and alkaline phosphatase (by 185.7, 48.8, 60.7 and 81.8%, respectively), while the activity of SOD decreased (by 19.9%) and ribonuclease activity did not change significantly in comparison with intact group (table 7).

Table 7

**The influence of the combination enoxifol (7.5 mg/kg) + rexod (0.01 mg/kg) on the indices of the energy supply systems, the antioxidant defense and lysosomal activity in the ischemic skin (M ± m, n=8)**

Index	Intact group	Ischemic skin	
		Control group	Experimental group
ATP, μM/g	14.2 ± 0.2	2.9 ± 0.2 <sup>*****</sup> (-79.6)	3.5 ± 0.2 <sup>*****</sup> -75.4/20.7
ADP, μM/g	1.9 ± 0.3	2.0 ± 0.2 (5.3)	1.9 ± 0.2 0.0/-5.0
AMP, μM/g	0.6 ± 0.1	0.8 ± 0.1 (33.3)	0.7 ± 0.1 16.7/-12.5
ATP/AMP	2.2 ± 0.2	1.45 ± 0.13 <sup>***</sup> (-34.1)	1.8 ± 0.2 -18.2/24.1
AP, μM/g	4.4 ± 0.2	2.9 ± 0.1 <sup>*****</sup> (-34.1)	3.6 ± 0.2 <sup>**xx</sup> -18.2/24.1
Cytochrome C, μM/mg	1.08 ± 0.1	0.85 ± 0.10 (-21.3)	0.90 ± 0.08 -16.7/5.9
Coenzyme Q <sub>10</sub> , mcg/g	1610.0 ± 47.0	1025.0 ± 34.0 <sup>*****</sup> (-36.3)	1340.0 ± 41.0 <sup>*****xxxx</sup> -16.8/30.7
Pyruvate, mcg/g	5.6 ± 0.2	6.0 ± 0.2 (7.1)	5.8 ± 0.2 3.6/-3.3
Lactate / Pyruvate	73.0 ± 15.0	102.0 ± 10.0 (39.7)	85.0 ± 8.0 16.4/-16.7
SDH, mcg of formazan /mg of protein × min	6.8 ± 0.3	5.9 ± 0.2* (-13.2)	6.0 ± 0.2* -11.8/1.7
NAD·H-cytochrome of C-reductase, nM of ferrocytochrome/mg per min	82.0 ± 12.0	59.0 ± 3.0 (-28.0)	69.0 ± 6.0 -15.9/16.9
NAD <sup>+</sup> , μM/g	3.0 ± 0.3	2.4 ± 0.2 (-20.0)	2.8 ± 0.2 -6.7/16.7
NAD H, μM/g	2.72 ± 0.15	2.4 ± 0.11 (-11.8)	2.7 ± 0.1 -0.7/12.5
NAD <sup>+</sup> / NAD H	1.10 ± 0.13	1.0 ± 0.1 (-9.1)	1.04 ± 0.05 -5.5/4.0
NAD <sup>+</sup> / NAD H, μmol/g	5.72 ± 0.27	4.8 ± 0.17 <sup>**</sup> (-16.1)	5.5 ± 0.2 <sup>x</sup> -3.8/14.6
RFO <sup>2-</sup> , μM/mg of protein × min	28.0 ± 4.0	80.0 ± 10.0 <sup>*****</sup> (185.7)	41.0 ± 8.0 <sup>xx</sup> 46.2/-48.8
SOD, U/g of protein	37.2 ± 2.7	29.8 ± 2.1* (-19.9)	39.4 ± 1.4 <sup>xxx</sup> 5.9/32.2
Catalase, nM H <sub>2</sub> O <sub>2</sub> /mg of protein × min	80.0 ± 10.0	119.0 ± 12.0* (48.8)	98.0 ± 7.0 22.5/-17.6
Cathepsin D, mcg of tyrosine/mg of protein per min	2.8 ± 0.2	4.5 ± 0.4 <sup>*****</sup> (60.7)	3.0 ± 0.2 <sup>xx</sup> 7.1/-33.3
Ribonuclease, mcg/mg of protein per min	1.2 ± 0.2	1.8 ± 0.2 (50.0)	1.2 ± 0.2 0.0/-33.3
ALP, nM/mg of protein per min	2.2 ± 0.3	4.0 ± 0.4 <sup>****</sup> (81.8)	2.8 ± 0.2 <sup>x</sup> 27.3/-30.0

\**p* < 0.05, \*\**p* < 0.02, \*\*\**p* < 0.01, \*\*\*\**p* < 0.002, \*\*\*\*\**p* < 0.001 in comparison with intact group; <sup>x</sup>*p* < 0.02, <sup>xx</sup>*p* < 0.01, <sup>xxx</sup>*p* < 0.002, <sup>xxxx</sup>*p* < 0.001 in comparison with control group.

Intraperitoneal administration of the combination enoxifol (7.5 mg/kg) + rexod (0.01 mg/kg) statistically significantly decreased the RFO<sup>2-</sup>, activity of the cathepsin D and ALP (48.8, 33.3, and 30.0%, respectively) in the ischemic skin homogenates of the experimental group of animals in comparison with control group, while the activity of SOD increased (by 32.2%); activity of the catalase and ribonuclease did not change significantly (table 7).

### Conclusions

1. Against the background of the ischemia of the rat tail tissues, induced by the occlusion of most of its blood vessels, and skin ischemia, induced by sewing of the skin fold of the back, the combination of enoxifol with rexod in single and, increasingly, repeated (for 7 days) intravenous administration has a more pronounced histoprotective effect than enoxifol and rexod, taken as reference drugs.

2. Against the background of the arterial insufficiency and venous stasis of the skin flap of the anterior abdominal wall of rats induced by occlusion (of the left side) of the celiac artery and vein, dermatoprotective activity of enoxifol, rexod, alprostadil and its combination as single and repeated (for 7 days) intravenous administration can be arranged in the following descending range: enoxifol + alprostadil > alprostadil > enoxifol + rexod > enoxifol > rexod.

3. Repeated (for 14 days) intravenous administration of enoxifol with rexod to rats with experimental diabetes mellitus complicated with exogenous hypercholesterinemia, has more pronounced dermatoprotective activity (on the skin flap of the anterior abdominal wall) than the administration of this combination against the background of normoglycemia. The combination of enoxifol with rexod decreases the level of blood glucose as under the condition of normoglycemia, as experimental diabetes mellitus and exogenous hypercholesterolemia; it causes a decrease the concentration of total cholesterol, triglycerides,  $\beta$ -lipoproteins and increasing of the high density lipoproteins; it has no significant effect on lipid parameters under the condition of normoglycemia.

4. Under the conditions of normoxia and hypoxia, induced by sodium cyanide, uncoupling of oxidative phosphorylation, induced by 2,4-dinitrophenol, enoxifol, rexod and its combinations are capable of, in the first case, to increase the viability of cultured osteoblasts, and in the second case, as osteoblasts, as fibroblasts of rats.

5. Enoxifol has anti-inflammatory action on edema, caused by histamine, serotonin and, to a greater extent, carageenan and Freund's complete adjuvant, but compare poorly of peroxicam and indomethacin. The mechanism of antiphlogogenic action of enoxifol may be due to the inhibitory effect of it on a prostaglandin phase of exudation and the phase of arachidonic acid metabolism, realized by 5-lipoxygenase way.

6. Under the condition of steroid gastric ulcers in rats enoxifol, rexod and, especially, its combination possess antiulcer action, enoxifol activity compare poorly of the sea buckthorn oil; the combination of enoxifol with rexod is much superior as enoxifol, rexod and sea buckthorn oil taken from separately.

7. The combination of enoxifol with rexod has a more significant positive influence on energy processes and antioxidant system that is increasing the efficiency of mitochondrial oxidation, decreasing the level of products of free radical oxidation in ischemic tissues, increasing the energy potential and

stabilizing membrane structures of cells than separately administrated enoxifol and rexod.

#### References.

1. Бенсман, В. М. Хирургия гнойно-некротических осложнений диабетической стопы. – М. : Медпрактика-М, 2010. – 472 с. [[eLIBRARY](#)]
2. Дедов, И. И. Проект «Консенсус совета экспертов Российской ассоциации эндокринологов (РАЭ) по инициации и интенсификации сахароснижающей терапии СД 2 типа» / И. И. Дедов, М. В. Шестакова [и др.] // *Сахарный диабет*. – 2011. – №1. – С. 95-105. [[eLIBRARY](#)]
3. Дедов, И. И. Алгоритмы специализированной медицинской помощи больным сахарным диабетом : клинические рекомендации. / под ред. И. И. Дедова, М. В. Шестаковой // *Сахарный диабет*. – 2015. – Вып. 7, №18 (1S), – С. 1-112. [[eLIBRARY](#)]
4. Майоров А. Ю. Сахарный диабет 2 типа : рук. для врачей общ. практики. / А. Ю. Майоров, Е. В. Суркова; под ред. И. И. Дедова. – М., 2011. – Изд. Второе. – 135 с.
5. Nathan, D. M. Management of hyperglycemia in type 2 diabetes: a consensus algorithm for the initiation and adjustment of therapy. A consensus statement from the American Diabetes Association and the European Association for the Study of Diabetes / D. M. Nathan [et al.] // *Diabetologia*. – 2008. – Vol. 49. – P. 1711-1721.
6. Nathan, D. M. Medical Management of Hyperglycemia in Type 2 Diabetes: A Consensus Algorithm for the Initiation and Adjustment of Therapy / M. David [et al.] // *Diabetes Care*. – 2009. – Vol. 32, № 1. – P. 193-203. [[PMC](#)]
7. Колуэлл, Дж. А. Сахарный диабет. Новое в лечении и профилактике / Дж. А. Колуэлл; пер. с англ. – М. : БИНОМ. Лаборатория знаний, 2010. – 288 с.
8. Майоров, А. Ю. Фармакотерапия сахарного диабета 2-го типа : рук. для врачей / А. Ю. Майоров, Е. В. Суркова, О. В. Луныкина ; под ред. И. И. Дедова. – М. : Медицина для Вас, 2008. – 76 с.
9. Rodbard, H. W. Statement by an American Association of Clinical Endocrinologists/American College of Endocrinology Consensus Panel on Type 2 Diabetes Mellitus: An Algorithm for Glycemic Control / H. W. Rodbard [et al.] // *Endocr. Pract.* – 2009. – Vol. 15. – № 6 – P.540-559. [[PubMed](#)]
10. Машковский, М. Д. Лекарственные средства. – 16-е изд., перераб., испр. и доп. – М. : Новая волна, 2010. – 1216 с.
11. Аметов, А. С. Сахарный диабет 2 типа. Проблемы и решения. – 3-е изд., перераб. и доп. – М. : ГЕОТАР-Медиа, 2015. – в 4 т. : Т. 1 – 352 с.
12. Дедов, И. И. [ред.] Сахарный диабет : острые и хронические осложнения / под ред. И. И. Дедова, М. В. Шестаковой – М. : Мед. информ. агентство, 2011. – 477 с. [[eLIBRARY](#)]
13. Дедов, И. И. Оптимизация и интенсификация инсулинотерапии при СД 2-го типа (клинические рекомендации) / И. И. Дедов, М. В. Шестакова //



*Сахарный диабет.* – 2010. – Спец. вып. – С. 9-16. [\[eLIBRARY\]](#)

14. Шахмарданова, С. А. Металлокомплексные производные 1-алкеннилимидазола. Антигипоксические свойства, механизмы действия, перспективы клинического применения / С. А. Шахмарданова, П. А. Галенко-Ярошевский. – Краснодар, 2015. – 267 с.

15. International Diabetes Federation. Diabetes Atlas – 5th edition. – Brussels, 2011.

16. Кроненберг, Генри М. Сахарный диабет и нарушение углеводного обмена / Генри М. Кроненберг, Рид П. Ларсен, Мелмед Шломо, Кеннет С. Полонски. – М. : GEOTAR-Медиа, 2010. – 840 с.

17. World Health Organization. Use of Glycated Haemoglobin (HbA1c) in the Diagnosis of Diabetes Mellitus. Abbreviated Report of a WHO Consultation. – World Health Organization, 2011 (WHO/NMH/CHP/CPM/11.1).

18. Галенко-Ярошевский, П. А. Антипероксидантная активность сердечно-сосудистых средств / П. А. Галенко-Ярошевский, В. В. Гацура – Краснодар, 2009. – 238 с. [\[eLIBRARY\]](#)

19. Шабанов, П. Д. Метаболические корректоры гипоксии / П. Д. Шабанов, И. В. Зарубина, В. Е. Новиков, В. Н. Цыган; ред. А.Б. Белевитин. – СПб. : Информ-Навигатор, 2010. – 912 с. [\[eLIBRARY\]](#)

20. Леонтьев, В. К. Хронический генерализованный пародонтит: клиническая и экспериментальная фармакотерапия метаболическими корректорами / В. К. Леонтьев, Л. А. Фаустов, П. А. Галенко-Ярошевский, В. Л. Попков, Н. Л. Сычева, Л. В. Попкова, Л. Л. Ордян. – Краснодар : Просвещение-Юг, 2012. – 403 с. [\[eLIBRARY\]](#)

21. Косолапов, В. А. Влияние нового антиоксидантного соединения эноксифол на пространственную ориентацию и память / В. А. Косолапов, И. А. Трегубова, В. А. Анисимова // *Обзоры по клинической фармакологии и лекарственной терапии.* – 2015. – Т. 13, спец. вып. – С. 75.

22. Кучерявенко, А. Ф. Конденсированные производные бензимидазола – новый класс антитромбогенных средств : автореф. ... д-ра мед. наук. – Волгоград. – 2012. – 47 с. [\[eLIBRARY\]](#)

23. Миронов, А. Н. [ред.] Руководство по проведению доклинических исследований

лекарственных средств. – Ч. 1. – М.: Гриф и К, 2012. – 944 с. [\[eLIBRARY\]](#)

24. Агаджанова, А. В. Эффективность сочетанного применения реамберина и супероксиддисмутазы при редуцированном кровообращении в коже / А. В. Агаджанова, О. Н. Стоялова, В. В. Галка, В. П. Галенко-Ярошевский, Л. В. Попкова // *Конгресс «Человек и лекарство. Краснодар – 2008».* – Краснодар. – 2008. – С. 2-4.

25. Стоялова, О. Н. Исследование раздельного и сочетанного применения мафусола и супероксиддисмутазы в условиях артериовенозной недостаточности / О.Н. Стоялова, А.В. Агаджанова, В.В. Галка (В.В. Селецкая), В.П. Галенко-Ярошевский, Л.В. Попкова // *Сб. тезисов и докладов конгресс «Человек и лекарство. Краснодар – 2008».* – 2008. – С. 86-87.

26. Зеленская, А.В. Реамберин и рексод. Фармакотерапевтическая коррекция редуцированного кровообращения в коже при сахарном диабете / А.В. Зеленская, П.А. Галенко-Ярошевский // Издательство ООО «Просвещение-Юг». – Краснодар, 2013. – С. 202. [\[eLIBRARY\]](#)

27. Галенко-Ярошевский, П.А. Влияние диабенола на выживаемость кожного лоскута в условиях гипергликемии / П.А. Галенко-Ярошевский, А.В. Тегай // В кн.: Антидиабетогенный потенциал бензимидазолов: химия, фармакология, клиника: монография / под ред. акад. РАН А.А. Спасова; акад. РАН В.И. Петрова, акад. РАН В.И. Минкина. – Волгоград: Изд-во ВолгГМУ, 2016. – С. 334-354.

28. Шварц, Г.Я. Методические рекомендации по доклиническому изучению нестероидных противовоспалительных лекарственных средств / Г.Я. Шварц, Р.Д. Сюбаев // В кн.: Руководство по проведению доклинических исследований лекарственных средств. Часть первая. – М.: Гриф и К, 2012. – С. 748-760.

29. Савенко, И.А. Фармакологическое исследование влияния когитума на моделированную патологию желудка крыс / И.А. Савенко, А.В. Крищенко, А.В. Сергиенко, М.Н. Ивашев // *Биомедицина.* – 2010. – №5. – С. 123-125. [\[eLIBRARY\]](#)

**Seletskaya Valeria Viktorovna** – Assistant Lecturer of the Department of Pharmacology.

**Galenko-Yaroshevskii Pavel Aleksandrovich** – Corresponding member of RAMS, Doctor of Medicine, Professor, Head of the Department of Pharmacology.