

UDC 616.37-007.41:616.342:572.7

*Dolzhikov A.A.,
Tverskoi A.V.*

**MORPHOLOGICAL CHARACTERISTICS
OF THE PANCREATIC HETEROTOPIA
IN THE MAJOR DUODENAL PAPILLA**

Dolzhikov Alexander Anatolievich, *Doctor of Medicine, Professor*

Department of Histology, Medical Institute, Belgorod State National Research University
85 Pobeda St., Belgorod, 308015, Russia

Tverskoi Aleksei Vladimirovich, *PhD in Medicine, Associate Professor*

Department of Human Anatomy, Medical Institute, Belgorod State National Research University
85 Pobeda St., Belgorod, 308015, Russia

АБСТРАКТ

The anatomical, morphometrical, histological and immunohistochemical studies of the major duodenal papilla were performed on the materials of 327 autopsy cases. The pancreatic heterotopia was revealed in 14,7% cases. This abnormality was associated with an existence of gallstone disease. More often the heterotopic pancreatic tissue was detected in the medial wall of the major duodenal papilla and its septum. Exocrine, complete and ductular histological variants of pancreatic heterotopia were revealed. The latter existed either as a morphological basis of papillary adenomas with cellular hyperplasia possessing smooth muscle immunophenotype, or as the result of atrophy and sclerosis of the exocrine heterotopic structures.

Key words: heterotopic pancreatic tissue; major duodenal papilla; papilla of Vater; morphology.

*Должиков А.А.,
Тверской А.В.*

**МОРФОЛОГИЧЕСКАЯ ХАРАКТЕРИСТИКА
ГЕТЕРОТОПИИ ПОДЖЕЛУДОЧНОЙ
ЖЕЛЕЗЫ В БОЛЬШОЙ СОСОЧЕК
ДВЕНАДЦАТИПЕРСТНОЙ КИШКИ**

Должиков Александр Анатольевич,

зав.кафедрой гистологии, доктор медицинских наук, профессор

Федеральное государственное автономное образовательное учреждение высшего профессионального образования «Белгородский государственный национальный исследовательский университет» (НИУ «БелГУ»), ул. Победы, 85, г. Белгород, 308015, Россия, E-mail: info@bsu.edu.ru

Тверской Алексей Владимирович,

зав.кафедрой анатомии человека, кандидат медицинских наук, доцент

Федеральное государственное автономное образовательное учреждение высшего профессионального образования «Белгородский государственный национальный исследовательский университет» (НИУ «БелГУ»), ул. Победы, 85, г. Белгород, 308015, Россия, E-mail: info@bsu.edu.ru

Аннотация

На материале 327 аутопсий выполнено комплексное анатомо-гистологическое, иммуногистохимическое и морфометрическое исследование большого сосочка двенадцатиперстной кишки. Гетеротопия поджелудочной железы обнаружена в 14,7% наблюдений. Данная аномалия сосочка связана с наличием желчно-каменной болезни. Наиболее частой локализацией гетеротопии являются медиальная стенка сосочка и межпротоковая перегородка. При микроскопическом исследовании выявлены экзокринный, полный и протоковый варианты гетеротопии. Протоковый вариант являлся составной частью аденомиоза или являлся следствием атрофии и склероза эктопических структур при экзокринном варианте. Иммуногистохимически выявлена гиперплазия клеток с гладкомышечным иммунофенотипом в гетеротопической поджелудочной железе.

Ключевые слова: гетеротопия поджелудочной железы; большой сосочек двенадцатиперстной кишки; Фатеров сосок; морфология.

INTRODUCTION

The major duodenal papilla is one of the principal objects of different surgical invasions with the lesions of the bile ducts, gallbladder, and pancreas. Apart from primary pathology of parapapillary areas, the main complications after surgical procedures and operations still remain the main problem. Sometimes they are even more dangerous than the lesions themselves.

The overall account of structural features of the major duodenal papilla is one of the ways of preventing postmanipulating complications. The most difficult factor taken into account is heterotopic pancreatic tissue (aberrant pancreas, heterotopic pancreas, ectopic pancreas, pancreatic heterotopias) in the papilla of Vater. Heterotopic or ectopic tissue is a congenital anomaly defined as the presence of the tissue outside its normal location. This tissue is usually discovered incidentally and may be asymptomatic or may present with non-specific gastrointestinal symptoms [3, 4, 9, 14].

Heterotopic pancreatic tissue is found, according to the data of different authors, with the frequency of 10-12% in autopsy [5]. Heterotopic pancreatic tissue can be located anywhere along the gastrointestinal tract; the most common sites are the stomach (27.5%), duodenum (25.5%), colon (15.9%), esophagus, and Meckel's diverticulum [1, 2, 6, 11, 16, 17]. It can also occur in the gallbladder, biliary tract, spleen, liver, jejunum, omentum, mesentery, lung, pelvis [5, 15]. Mediastinum and cranium are very rare location of HP [13]. However, its occurrence in the retroperitoneal space is an extremely rare and inexplicable phenomenon [7].

It is necessary to go on with searching gross diagnostic signs of HP. Heterotopic pancreatic tissue can malingere acute and chronic cholecystitis, pancreatitis, gastric and duodenal ulcer. It can cause gastrointestinal bleeding and malignant tumors of gastrointestinal tract [3, 10, 12]. HP can also leads to gastric outlet obstruction or duodenal stenosis [8].

Earlier there were only single cases of possible relations between acute pancreatitis and heterotopic pancreas (HP). Today this possibility is not debated.

MATERIALS AND METHODS

The study was performed on the materials of 327 autopsies, sex, age, clinical data, pathological and clinical diagnoses taken into consideration. All the received data were counted by MS Excel. The materials researched were taken during the period from 4-24 hours after death. Pancreas with duodenum were examined macroscopically. Then the tail and part of the pancreatic body were cut off, pancreatic and common bile ducts were found and washed with physiological solution. The prepared samples were fixed in 10% neutral formalin. After that the position and shape of papilla of Vater were identified macroscopically. Then papilla of Vater was cut into two equal parts. We determined the way of fusion of common bile duct and pancreatic duct, the size of mucous membrane folds, the presents of polypoid changes, measured the common canal length, and interductular septum width. The 10 samples were used for preparing transverse cutting. The rest samples were cut longitudinally through the center of major duodenal papilla. As a result two symmetrical parts were received for the following investigations. The 10 histological specimens were made from each one. Hematoxylin and eosin, Van Gieson, PAS-reaction were used for staining by Autostaniner XL ST5010; Leica, Germany. A-cells and B-cells of pancreas were stained by impregnation AgNO_3 and «Fenaf» technique respectively. Immunohistochemical reactions were performed with Cytokeratin, Clone MNF 11 «Dako Cytomation», Mouse Anti-Human Alpha Smooth Muscle Actin, Clone 1A4 «Dako Cytomation» (LSAB kit, DAB was used as chromogen).

Photoprotocoling and morphometrical measurements were performed using Mirax Desk (Carl Zeiss Microimaging GmbH, Germany). The arithmetical mean, standard deviation, standard error, median, mode, Student's t-criteria, χ^2 -criteria, F-criteria were calculated by Statistica 6.0.

The purpose of our research is to investigate the features and variants of morphogenesis of heterotopic pancreatic tissue in the major duodenal papilla.

The study was performed on the materials of 327 autopsies.

Table 1

Distribution of cases by sex and age

Groups of cases	Sex		Middle age	
	Male	Female	Male	Female
Without ectopy (n=279)	153	126	60,7±1,3	63,8±1,2
With ectopy (n=48)	26	22	58±3,1	63,2±2,7
In all:	179	148		
Total:	327			

Heterotopic pancreatic tissue in the papilla of Vater and periampullar region was found in 48 cases (14,7%). The macroscopical changes of the major duodenal papilla were identified in 1 case only (2,1%). It was suspected as a tumour of papilla of Vater. All other 47 cases had no macroscopical changes. All material was divided into two groups: with heterotopic pancreas (HP) and without HP. Also sex, age, diagnoses were taken into consideration. The male were 153 (54,8%) and 26 (54,2%) cases in the group with and without HP respectively. This naturally reflects the structure of mortality. The distribution of cases with and without HP was the same. In adulthood HP was found in 37,5% in the group with ectopia, and in 28,7% in the group without ectopia. In advanced age HP was identified in 45,8% in the group with ectopia, and in 47,3% in the group without ectopia. In general population the frequency of HP decreases from the first period of adulthood (18,2%) to the senile age (13,6%). The differences were not obtained in the age groups in accordance with nonparametric test ($\chi^2 < 3,0$). In accordance with gastrointestinal tract diseases significant differences were found in the two groups ($\chi^2 = 4,0403$; $p < 0.05$ by F-criteria). Primarily it concerns the cholelithiasis.

During the investigation the cone-shape, cylindrical and flat forms of the major duodenal papilla were found. The significant differences were not present in both groups with different forms of the papilla of Vater.

The histological examination revealed the presence of HP position in the medial wall of the major duodenal papilla in 37,5% of cases, in the interductular septum – in 37,5% , in the lateral wall – in 16,7%, and in the parapapillary area of duodenum – in 8,3%.

The histotopographical examination revealed the presence of HP in duodenal submucosa (2 cases, 4,2%), in the inner circular layer of muscularis externa (4 cases, 8,4%), in the free edge of interductular septum (10 cases, 20,8%), in the mucosa and muscular-glandular layer of papilla of Vater (13 cases, 27,1%), in the walls of papilla of Vater and base of interductular septum (19 cases, 39,6%).

At the histopathological evaluation, the Heinrich classification system was used to classify heterotopic pancreas which consists of three anatomical variations: Type 1 (Containing acini, islets and ducts), Type 2 (Acini and ducts, no islets), Type 3 (Ducts alone) [3].

Multiple and vast areas of HP in view of lower magnificent microscope were detected in 7 (14,6%) cases. In 4 cases the pancreatic heterotopic areas were equal to one field of lower magnificent microscope vision. In most cases ectopic pancreas was presented by a small single parts of pancreatic tissue.

The study of heterotopic pancreas microstructure in the papilla of Vater, histochemical and immunohistochemical features of the components, some of morphometrical measures made it possible to identify the main histological variants of pancreatic heterotopia. It is advisable to distinguish the following histological variants: exocrine, complete, and ductal.

The exocrine variant is characterized by the presence of pancreatic acini and ducts of a different size. The number of acini and ducts can be varied. A significant prevalence of secretory structures and the absence of ducts can give a false imaging of acinar HP structures only. According to our data such variant does not exist. First, the ducts can be innumerable and presented

by intercalated ducts and intercellular canaliculi. This variant is typical for superficial HP position to the mucous of the major duodenal papilla. Second, the ducts can be isolated from acini. It is characteristic of major duodenal papilla with fibrous changes caused by age involutions or inflammation consequences. The similar structure

can be seen when ectopic acini are located in the papillary sphincter or close to large groups of its own glands. In both cases a serial of cutting is necessary. It can also be helpful to use immunohistochemical staining for identification of the mucus as its production is typical for even very small ducts of heterotopic pancreatic tissue.

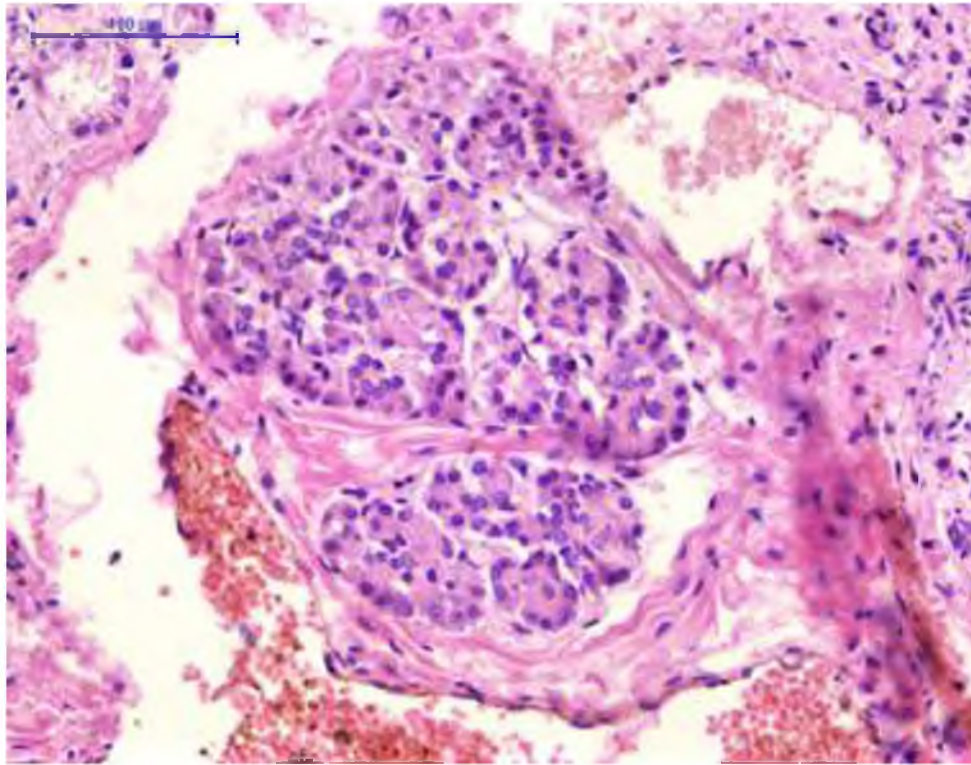


Figure 1. Exocrine variant of heterotopic pancreas in the major duodenal papilla. Hematoxylin & eosin. $\times 200$

Depending on the combination of acini and ducts, the division of exocrine variant into predominantly acinar, acinar-ductal, and predominantly ductal is considered to be the most correct in our opinion.

This relative divisions of HP are based on different quantity of pancreatic acini and ducts. If we see small or bad visible ducts and a lot of acini it will be predominantly acinar variant of HP. When the quantity of acini is almost equal to ducts it will be acinar-ductal variant of HP. If we see a lot of ducts and small quantity of pancreatic acini it will be predominantly ductal variant of HP. They can be presence as independent variant or stage of heterotopic pancreatic tissue transformation during sclerotic and atrophic changes. Sclerotic and atrophic processes of pancreatic acini are characterized by often zymogen granules loss, dilatation of

acini. Possibly this ductular transformation of acini is the result of the lack of releasing alkaline fluid and proenzymes to the duodenum via the pancreatic ducts.

The immunohistochemical staining revealed the cells with positive smooth muscle reaction, but hematoxylin and eosin staining showed these elements like a fibroblasts. The spindle-shaped and concentrically oriented cells were present on routine specimens. One part of them looked like as fibroblasts, another one like myoepithelial cells. The immunohistochemical staining with smooth muscle actine was positive in cytoplasm of these cells which were found around HP and was negative in normal pancreas. We can probably suppose that tissue's reorganization of stromal cells with the acquiring new features like in myoepithelial cells or myofibroblasts occurs in HP.

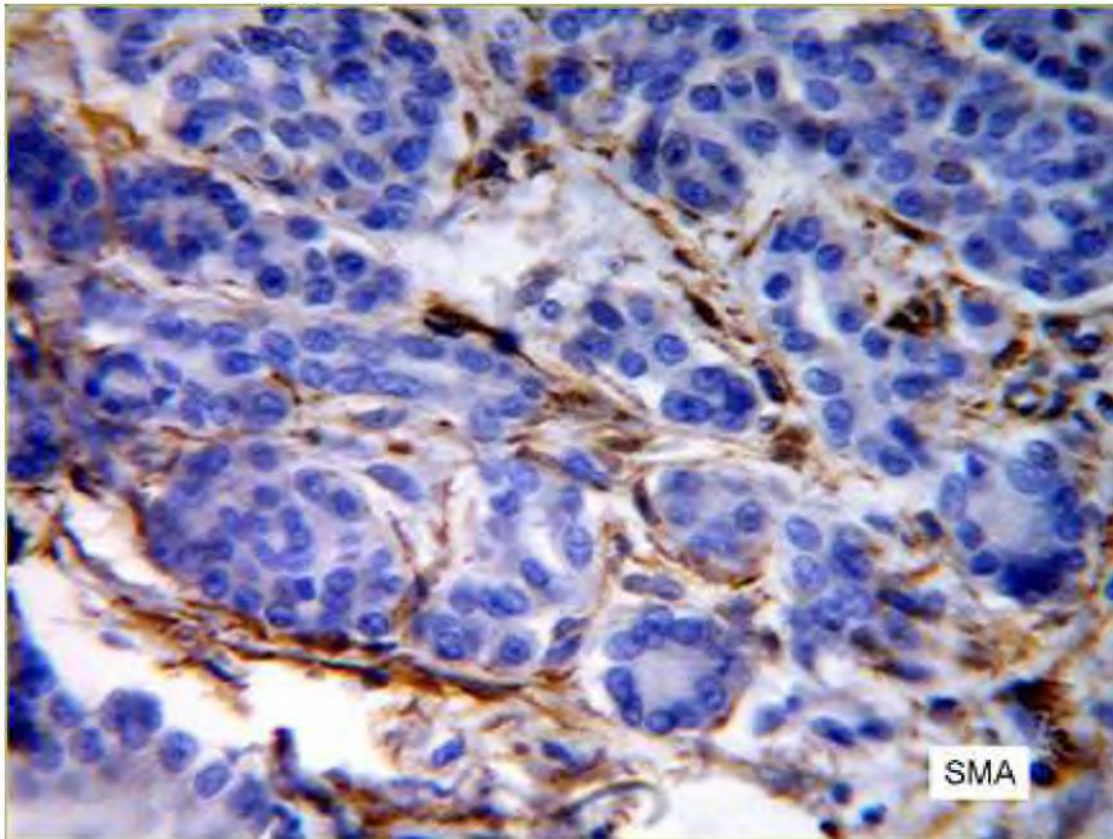


Figure 2. The spindle-shaped cells with smooth muscle actin positive reaction (Mouse Anti-Human Alpha Smooth Muscle Actin, Clone 1A4 “Dako Cytomation”, LSAB kit, DAB was used as chromogen) $\times 400$.

The complete variant is characterized by the presence of all structural components of the pancreas: acini, ducts, islets of Langerhans or the complex of isolated endocrine cells. Ratio of the structural components may be different. It depends on the stage of involutional and pathological acini atrophy. The complete variant is not obvious because it is not in all cases that the typical islets of Langerhans are distinguished. More often the groups of A- or B-cells are visible after histochemical staining.

The complete variant of HP was found in 5 cases (10,4%) but only in one case the islet of Langerhans was seen on hematoxylin and eosin stained specimen. In other cases the A-cells and B-cells of HP were stained by impregnation AgNO_3 and «Fenaf» technique respectively. In the case with the complete variant of HP

its histological structure almost entirely corresponded to the structure of the pancreas. Each acinus was composed of several pyramid-shaped pancreatic acinar cells with intercalated and interlobular ducts. The endocrine portion was composed of small, spherical clumps of cells, islet of Langerhans, which were richly endowed by capillaries. Islet of Langerhans were connected with the small ducts and acinar elements especially if the latter were dilated and overfilled with oxyphyle secretory products. The involution and acini atrophy were also detected in surrounding cells. These changes were found in the papilla of Vater without chronic alteration signs, too. They were related with local fibrosis in the HP, intercalated and interlobular ducts constriction.

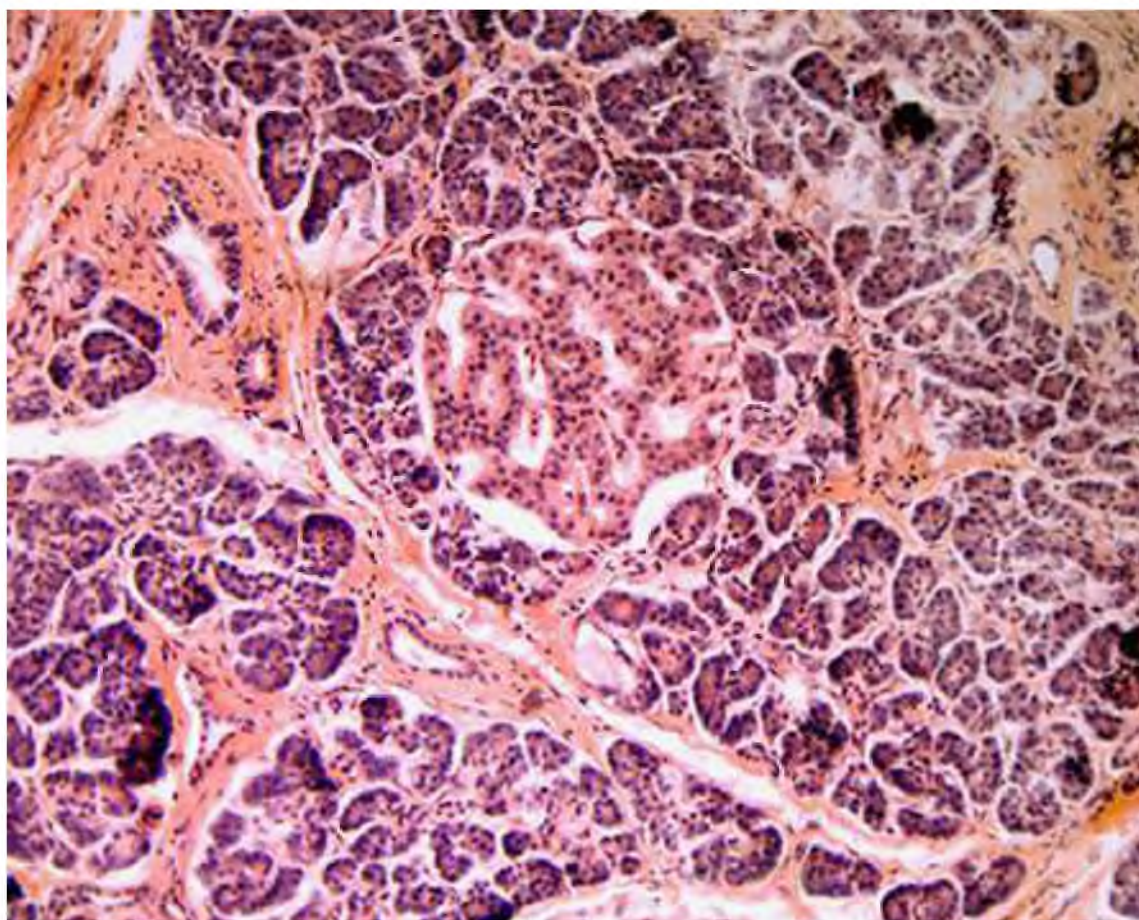


Figure 3. Complete variant of heterotopic pancreas in the major duodenal papilla. Interlobular ducts on a white arrow. Islet of Langerhans on a black arrow. Hematoxylin & eosin. $\times 200$

The ductal variant is characterized by the presence of small intercalated and interlobular ducts which form the lobule. Single acini or small groups of acinar cells help to identify this variant of HP. The ductular structures were characterized by the diameter of ducts from 12 to 40 μm and dense arrangement. Simple columnar or cuboidal epithelium with alcian blue and PAS positive secretory products forms and lines these ducts. This variant of HP was found in 8 cases (16,7%). The ectopic areas were multiple, with 100-350 μm in diameter of lobules. Loose connective tissue forms the stroma of HP and contains the spindle-shaped cells which look like fibroblasts or myoepithelial cells. The immunohistochemical

staining with smooth muscle actin revealed the positive reaction in spindle-shaped cells inside and particularly around the ductular structures of HP. On hematoxylin and eosin stained specimens they located surrounding the HP, their form was spindle with compact elongated nuclei resembling in appearance myoepithelial elements. The positive immunohistochemical reaction with smooth muscle actin unambiguously revealed the location of these elements in the structure of heterotopic pancreatic tissue. They were not numerous in surrounding tissues or were absent. We can also describe with structures as the adenomyomatous hamartoma or adenomyoma.

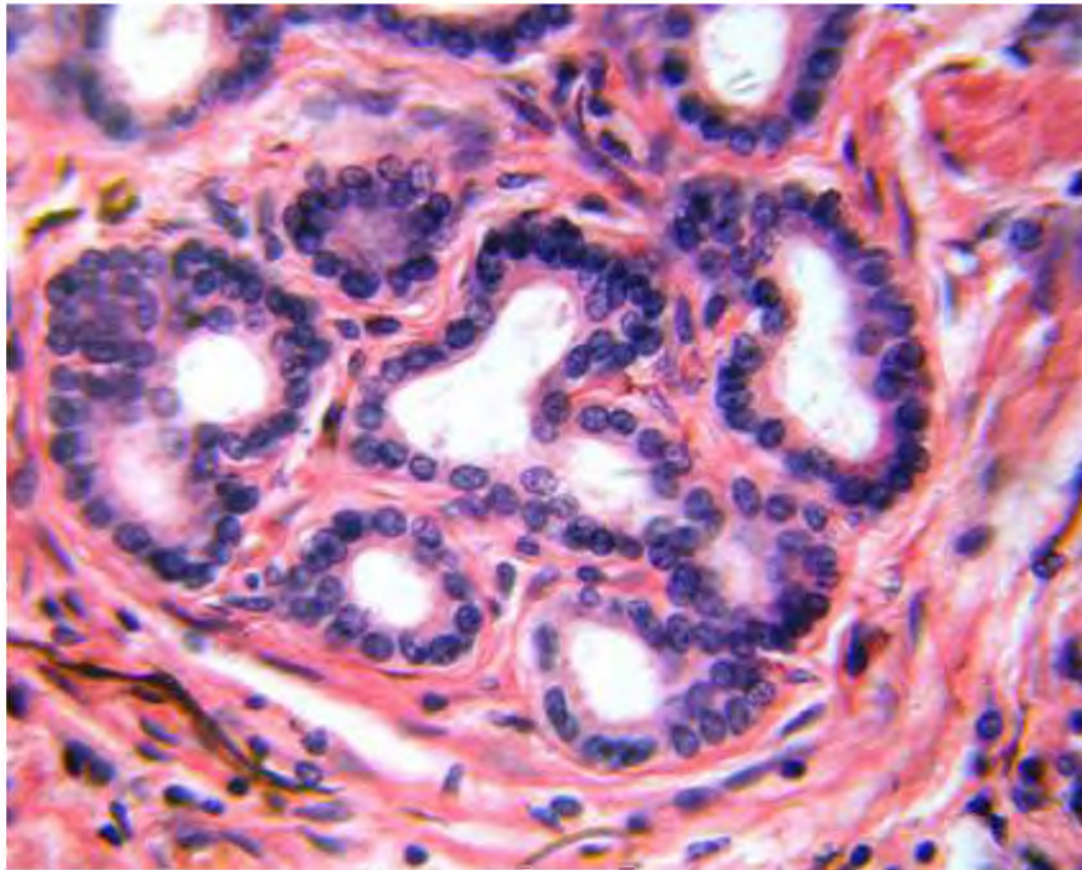


Figure 4. Ductal variant of heterotopic pancreas in the major duodenal papilla which looks like adenomyoma. Hematoxylin & eosin. $\times 320$

All in all the exocrine HP was prevalent variant and was found in 72,9% of cases.

Thus, the heterotopic pancreatic tissue is not rare congenital lesion of the major duodenal papilla and often is diagnosed on its serial histological sections. The correlation between HP and cholelithiasis was determine. Most common histotopographical location of HP was the inter-

ductular septum or medial wall of the major duodenal papilla near the pancreatic duct. It is advisable to distinguish the exocrine variant with different ratio of the acini and ducts, complete variant with all typical components for pancreas, and the ductal histological variant as a self-dependent subtype and a sequent of acinar structures atrophy.

REFERENCES:

- Heterotopic pancreas involving stomach and duodenum / Agale S.V., Agale V.G., Zode R.R., Grover S., Joshi S. // *J Assoc Physicians India*. 2009, 57: 653-7. [PMID 20214004].
- Double heterotopic pancreas and Meckel's diverticulum in a child: do they have a common origin? / Baysoy G., Balamtekin N., Uslu N., Karavelioglu A., Talim B. // *The Turkish Journal of Pediatrics*. 2010, 52: 336-338.
- De Castro Barbosa J.J. Pancreatic heterotopia; review of the literature and report of 41 authenticated surgical cases, of which 25 were clinically significant // *Surg Gynecol Obstet*. 1946; 82: 527-542.
- Dolan R.V. The fate of heterotopic pancreatic tissue. A study of 212 cases // *Arch Surg*. 1974, 109: 762-765.
- Heterotopic pancreas of the jejunum: associations between CT and pathology features / Dong Wook Kim, Jin Hee Kim, Seong Ho Park, Jong Seok Lee, Seung-Mo Hong, Misung Kim, Hyun Kwon Ha // *Abdom Imaging*. 2015, 40: 38-45. DOI: 10.1007/s00261-014-0177-y.
- Heterotopic Pancreas in the Stomach: A Case Report and a Brief Review of the Literature / Gokhale U.A., Nanda A., Pillai R., Al-Layla D. // *J Pancreas (Online)*. 2010, May 5; 11(3): 255-257.
- Heterotopic gastrointestinal mucosa and pancreatic tissue in a retroperitoneal tumor / Hashimoto N., Hakamada K., Narumi S., Tot-suka E., Aoki K., Kamata Y., Sasaki M. // *J Hepatobiliary Pancreat Surg* (2006) 13:351-354. DOI 10.1007/s00534-005-1089-6.
- Gastric Outlet Obstruction Caused by a Heterotopic Pancreas in a Pregnant Woman: Report of a Case / Ikematsu Y., Nishiwaki Y., Kida H., Iwaoka Y., Nagashima S., Ozawa T., Hasegawa S., Okawada T., Waki S. // *Surg Today*. 2003, 33: 952-955. DOI 10.1007/s00595-003-2614-3.
- Khasab M.A. Ligation assisted endoscopic mucosal resection of gastric heterotopic pancreas // *World J Gastroenterol* 2009; 15:2805-8. [PMID 19522034].
- Adenocarcinoma Arising From Heterotopic Pancreas in the Duodenum / Kinoshita H., Yamaguchi S., Shimizu A., Sakata Y., Arii K., Mori K., Nasu T. // *Int Surg*. 2012, 97: 351-355.
- Premalignant lesion of heterotopic pancreas combined with gastritis cystica profunda in gastric fundus / Lee M.S., Cho B.S., Park J.S., Koo H.C., Han H.Y., Kang D.W. // *J Gastrointest Liver Dis*, September. 2013, Vol. 22 No 3: 337-340.
- Ectopic Pancreas of the Gastric Antrum Contiguous to a Gastrointestinal Stromal Tumor Manifesting as Upper Gastrointestinal Bleeding: Report of a Case / Teke Z., Kabay B., Kelten C., Yilmaz M., Duzcan E. // *Surg Today*. 2007, 37:74-77. DOI 10.1007/s00595-006-3340-4.
- Nonfunctioning endocrine tumor arising from intracranial ectopic pancreas associated with congenital brain malformation / Tsugu H., Oshiro S., Kawaguchi H., Fukushima T., Nabeshima K., Matsumoto S., Nomura Y., Yasumoto S., Takano K., Utsunomiya H. // *Childs Nerv Syst*. 2007, 23: 1337-1340. DOI 10.1007/s00381-007-0391-9.
- Acute inflammation occurring in gastric aberrant pancreas followed up by endoscopic ultrasonography / Watanabe K., Irisawa A, Hikichi T, Takagi T, Shibukawa G, Sato M, Obara K, Ohira H. // *World J Gastrointest Endosc.*, 2012 Jul 16; 4 (7): 331-4. DOI: 10.4253/wjge.v4.i7.331.
- Pancreatic and gastric heterotopy in the gastrointestinal tract / Wlaź J., Mądro A., Kaźmierak W., Celiński K, Slomka M. // *Postepy Hig Med Dosw (Online)*. 2014, Sep 3; 68: 1069-75.
- Yenon K. Aberrant pancreas with a double intestinal location // *Ann Chir*. 2005, Jul-Aug; 130 (6-7): 414-6. Epub 2005 Apr 14.
- Heterotopic pancreas in the gastrointestinal tract / Yuan Z., Chen J., Zheng Q., Huang X.Y., Yang Z., Tang J. // *World J Gastroenterol*. 2009, 15: 3701-3. [PMID 19653355].