



McDonald, S. W. and MacFarlane, N. G. (2018) The mouth, stomach and intestines. *Anaesthesia and Intensive Care Medicine*, 19(3), pp. 128-132.(doi:[10.1016/j.mpaic.2018.01.003](https://doi.org/10.1016/j.mpaic.2018.01.003))

This is the author's final accepted version.

There may be differences between this version and the published version. You are advised to consult the publisher's version if you wish to cite from it.

<http://eprints.gla.ac.uk/158080/>

Deposited on: 05 April 2018

Enlighten – Research publications by members of the University of Glasgow  
<http://eprints.gla.ac.uk>

## **The mouth, stomach and intestines**

Stuart W McDonald and Niall G MacFarlane

School of Life Sciences, University of Glasgow, Glasgow G12 8QQ.

### *Abstract*

Food is chewed into digestible portions in the mouth and swallowed – a complex reflex process involving several cranial nerves. The stomach homogenizes food, begins digestion and regulates the rate at which food enters the duodenum. Pancreatic juices containing powerful digesting enzymes are added and digestion is completed in the small intestine. The large bowel dehydrates the gastrointestinal contents.

**Keywords** Colon; digestive enzymes; gastro-oesophageal sphincter; intestinal secretions; small intestine; stomach; stomach acid; swallowing

### **Royal College of Anaesthetists CPD matrix:**

#### *Introduction*

Food is chewed in the mouth and swallowed in boluses of a size appropriate to pass down the oesophagus and into the stomach. Lubrication with saliva makes them easier to swallow.

#### *Chewing*

Chewing involves the muscles which primarily move the mandible (see Figure 1): masseter, temporalis and the medial and lateral pterygoids (all supplied by mandibular division of the trigeminal nerve). Their differential contraction not only opens and closes the mouth and protracts and retracts the mandible; but they bring about side-to-side movements. This movement occurs at the complex temporomandibular joint.

When the mouth opens and closes, the fulcrum of the movement lies, not at the joint, but at the mandibular foramen so that the inferior alveolar nerves and vessels entering the bone at this site

undergo minimal stretch. The process of chewing, however, involves muscle other than those that are classed as 'muscles of mastication'. In particular, the tongue manipulates the bolus of food and pushes it between the teeth. Similarly, the buccinator muscle in the cheek and muscles of the lips (which are all muscles of facial expression and thus supplied by the facial nerve) ensure that food does not build up in the mouth and so a patient with facial palsy will have difficulty eating

### *Swallowing*

Swallowing is coordinated by the swallowing centre in the medulla. Liquids are swallowed by a backwards movement of the tongue. The right and left styloglossus muscle are well placed to facilitate this movement and the intrinsic muscle of the tongue will form a shape appropriate to this piston like action. Solids are separated into boluses by the tongue being placed against the hard palate and food forced back into the oropharynx. The initial movement is voluntary but as the bolus passes into the oropharynx a number of reflex contractions occur. The nasopharynx is closed off by the soft palate meeting the posterior wall of the pharynx. The superior constrictor muscle of the pharynx starts to propel the bolus. The glottis is closed and the larynx is elevated and moved anteriorly, out of the way of the bolus, and is covered and protected by the epiglottis. These effects are produced by intrinsic and extrinsic laryngeal muscles but the protective movement of the epiglottis is passive as the bolus presses on it.

The whole process is coordinated with breathing. A peristaltic-type wave starts in the superior constrictor muscle and progresses to the middle and inferior constrictors, moving the bolus into the oesophagus. In the laryngopharynx, the bolus strikes the pharyngeal surface of the leaf shaped epiglottis and is directed inferolaterally through the piriform fossa on either side. The piriform fossa is a pear-shaped recess and, along with the vallecula, the recesses between the tongue and the epiglottis are notorious sites for fish bones being lodged.

The oesophagus consists of skeletal muscle in the upper third, skeletal and smooth muscle in the middle third and smooth muscle alone in the lower third. The muscles are supplied by trigeminal,

facial, glossopharyngeal, vagus and hypoglossal nerves. The upper oesophageal sphincter relaxes to receive the bolus and then closes, which prevents the swallowing of air. Food moves down the oesophagus by a peristaltic wave (this is an active reflex in the upper oesophagus, started skeletal muscle and lost if the vagus is cut).

In the lower oesophagus, peristalsis is mediated by the enteric nervous system and propels the food bolus towards the stomach at a slow rate ( $2-6 \text{ cm}\cdot\text{s}^{-1}$ ) and so it takes approximately 10 seconds for a food bolus to pass through the oesophagus. If the first peristaltic wave does not clear the food bolus from the oesophagus then its distension initiates further peristaltic waves until the food enters the stomach. Liquids drunk when an individual is erect will reach the stomach before the peristaltic wave.

Pressure in the upper oesophageal sphincter is quite high (at around  $60 \text{ cmH}_2\text{O}$ ). In the body of the oesophagus, the pressure will reflect the intrathoracic pressure and can vary, with ventilation, between  $-5$  and  $-10 \text{ cmH}_2\text{O}$ . The lower oesophageal sphincter is important for preventing regurgitation of acidic stomach contents, which could contaminate the respiratory tract. The lower oesophageal sphincter pressure is around  $+30 \text{ cmH}_2\text{O}$  and the smooth muscle is tonically active but relaxes on swallowing.

#### *Gastro-oesophageal sphincter*

This has three components: (i) oesophageal smooth muscle is thicker at the sphincter than in the remainder of the oesophagus; (ii) the fibres of the diaphragm surround the sphincter and exert a positive pressure acting as a pinch-cock; (iii) the oblique angle at which the oesophagus enters the stomach creates a flap valve that helps to close the stomach off from the oesophagus and prevent reflux (Figure 2). The smooth muscle sphincter is under neural control via the cholinergic fibres of the vagus; it relaxes to let food enter in response to nitric oxide and vasoactive intestinal peptide

released from interneurons in the enteric system. The diaphragm is a skeletal muscle and swallowing is coordinated with respiration.

### *The stomach*

Anatomically, the stomach is divided into five regions: cardia, fundus, corpus (body), antrum and pylorus; functionally, there are two: proximal and distal (Figure 2). The proximal region (cardia, fundus and proximal one-third of the corpus) acts as a reservoir; the distal region (distal two-thirds of the corpus, antrum and pylorus), which is more muscular, mixes the stomach contents before delivering them to the duodenum (Figure 2).

The proximal stomach relaxes to receive swallowed food. This adaptive relaxation is centrally mediated in the medulla and innervated via vagal inhibitory fibres in the enteric plexus. The empty stomach is relatively inactive, and the pylorus open. Periodic contractions (migratory motor complexes) occur approximately every 45-180 minutes, sweeping gastric residue into the duodenum. Digestion of food in the stomach produces a homogeneous semi-fluid material (chyme).

After a meal, the distal stomach undergoes peristaltic contractions (approximately three per minute) caused by action potentials superimposed on slow rhythmical electrical waves. These originate in the gastric pacemaker on the greater curvature of the stomach at the junction of the proximal and distal regions. Two successive contractions occur 2-3 seconds apart. The first results in some chyme entering the duodenum through the pylorus, which causes the pylorus to close; when the second wave arrives, the rest of the bolus is forced back into the stomach to continue homogenization and digestion. Parasympathetic stimulation increases gastric contractions and sympathetic stimulation inhibits them (and so cutting the vagus nerve slows gastric emptying).

### *Gastric emptying*

Gastric emptying is affected by a number of factors. Liquids empty faster than solids and isotonic fluids faster than those that are hypertonic or hypotonic (the duodenum seems to have

osmoreceptors). The rate of gastric emptying is proportional to the volume of chyme (with smaller particles emptying faster than large ones).

Normally, chyme passing into the duodenum contains particles less than 2 mm in diameter; 90% of them are less than 0.25 mm. A decrease in duodenal pH (pancreatic secretions are alkaline) slows gastric emptying and inhibits gastric motility. Lipids also slow gastric emptying: products of fat digestion (glycerides and fatty acids) arriving in the duodenum stimulate the secretion of cholecystokinin (CCK) from endocrine cells in the duodenal epithelium, which closes the pyloric sphincter. If too much chyme with high osmolality passes into the duodenum then there is a shift of extracellular fluid into the lumen. This can cause hypovolaemia, resulting in the 'dumping syndrome' sometimes observed after gastrectomy.

### *Intestinal secretions*

Approximately 7-10 litres of fluid are added to the GI tract each day from the various glands (salivary, pancreas), liver (bile) and intestinal wall.

**Saliva:** this is secreted by the salivary glands under autonomic (parasympathetic) control. It is alkaline and contains salivary amylase, which digests starch and protects the teeth from decay. It is a mixture of mucous and serous fluid and is hypoosmolar (10-50 mosmol/kgH<sub>2</sub>O) when compared with plasma.

**Gastric secretions:** the stomach produces approximately 1-3 litres of gastric juice per day containing hydrochloric acid (around pH 1), pepsin, mucous and intrinsic factor (important in the absorption of vitamin B<sub>12</sub> and therefore essential).

Although the stomach is not absolutely essential for digestion, the low pH provides protection against ingested microorganisms. Gastric juice is produced mainly by oxyntic glands at the bottom of gastric pits (Figure 3); these are located in the body and fundus and contain a number of different types of cell: parietal cells, which produce hydrochloric acid; chief or peptic cells, which produce

pepsinogen (the precursor of the proteolytic enzyme pepsin); endocrine cells; and neck mucous cells. The endocrine cells produce histamine (enterochromaffin-like cells (ECL)) and somatostatin (D cells). Neck mucous cells are stem cells for most of the other types of cells and replace them as necessary. The surface of the stomach is lined by columnar epithelium that secretes mucus and an alkaline bicarbonate-containing fluid.

**Gastric acid:** hydrochloric acid is synthesized in the parietal cells.  $H^+$  comes from carbonic acid (synthesized by carbonic anhydrase) and is secreted into the gastric lumen by an  $H^+/K^+$ -ATPase, that is, the proton pump. The  $K^+$  taken into the cell passes back into the gastric lumen via a potassium ion channel.

The  $HCO_3^-$  created by the carbonic anhydrase leaves the oxyntic cell and passes into the general circulation, causing a rise in blood pH; this phenomenon is seen after a heavy meal. The

'proton pump' is inhibited by omeprazole.

The stimuli for gastric acid secretion by parietal cells are as follows.

- histamine is produced by ECL cells and acts in a paracrine fashion; it stimulates  $H_2$  receptors on the parietal cells and can be blocked by  $H_2$  blockers such as ranitidine
- acetylcholine is released by vagal nerve endings
- gastrin, produced by antral G cells, stimulates parietal cell secretion via the bloodstream.

These three stimuli all potentiate each other (i.e. the total effect is greater than the sum of the parts), so  $H_2$  blockers block more acid released than that being stimulated by the ECL cells alone.

**Gastric secretion:** this is controlled by a complex series of inter-linked processes. Classically, in response to a meal, it has three phases: cephalic (responsible for 40% of HCl secretion), gastric (50%) and intestinal (10%). The cephalic phase is a response to the sight and smell of a meal and is mediated by the vagus via acetylcholine acting on the parietal cells directly. The gastric phase is also

mediated by the vagus: gastrin-releasing peptide is secreted by vagal postganglionic neurones and antral somatostatin release (which inhibits gastrin release) from D cells is inhibited by cholinergic nerves.

**Gastric protection:** in life, the surface of the stomach is protected by a mucous layer rich in bicarbonate, the pH of which is close to 7, whereas the pH of the stomach lumen is about 2. This protective layer, secreted by mucous cells, provides both physical and chemical protection for the epithelium and is increased by vagal stimulation. Additional protection is provided by surface active phospholipids whose positively charged heads are attracted to the mucous layer, which is negatively charged. The lipid tails are hydrophobic and provide an additional protection against stomach acid and any acid that does leak into the mucosa will stimulate nitric oxide and prostaglandin, which increasing blood flow and flushing the H<sup>+</sup> away. Damaged areas of epithelium are covered by migrating undifferentiated mucous cells. Cell turnover in the stomach epithelium is quite high (with cells replaced every few days).

#### *The exocrine pancreas*

The exocrine pancreas secretes approximately 1500 ml of alkaline pancreatic juice per day with a high HCO<sub>3</sub><sup>-</sup> content. Together with the bile, it neutralizes the gastric acid so that duodenal pH is approximately 6-7. Pancreatic juice contains powerful enzymes that break down protein (trypsin, chymotrypsin); it also contains amylase (for carbohydrate digestion), lipase (for fat digestion) and enzymes that digest nucleic acids and phospholipids.

#### *Small intestine*

In the small bowel, food is mixed with bile, pancreatic juice and the secretions of cells lining the small intestine. These include mucus, which lubricates and protects the epithelium, and various digestive enzymes, which break down disaccharides and peptides. Digestion, started in the mouth and stomach, is completed and the products absorbed along with most of the water. The small



bowel receives approximately 9 litres of water per day (with 2 litres from the diet and 7 litres from secretions) and approximately 1-2 litres pass into the colon.

Approximately 40% of the small intestine is jejunum and 60% ileum (although there is no anatomical boundary) and it is rich in lymphatic tissue. The small bowel is lined with 0.5-1 mm long finger-like projections or villi (20-40/mm<sup>2</sup>), containing a lymphatic vessel, an (end) artery, a vein and a capillary network. The villi, in turn, are covered with microvilli, making up the 'brush border'. The mucosa is incredibly folded and it has been estimated that the total area available for absorption in the small bowel is 200 m<sup>2</sup>.

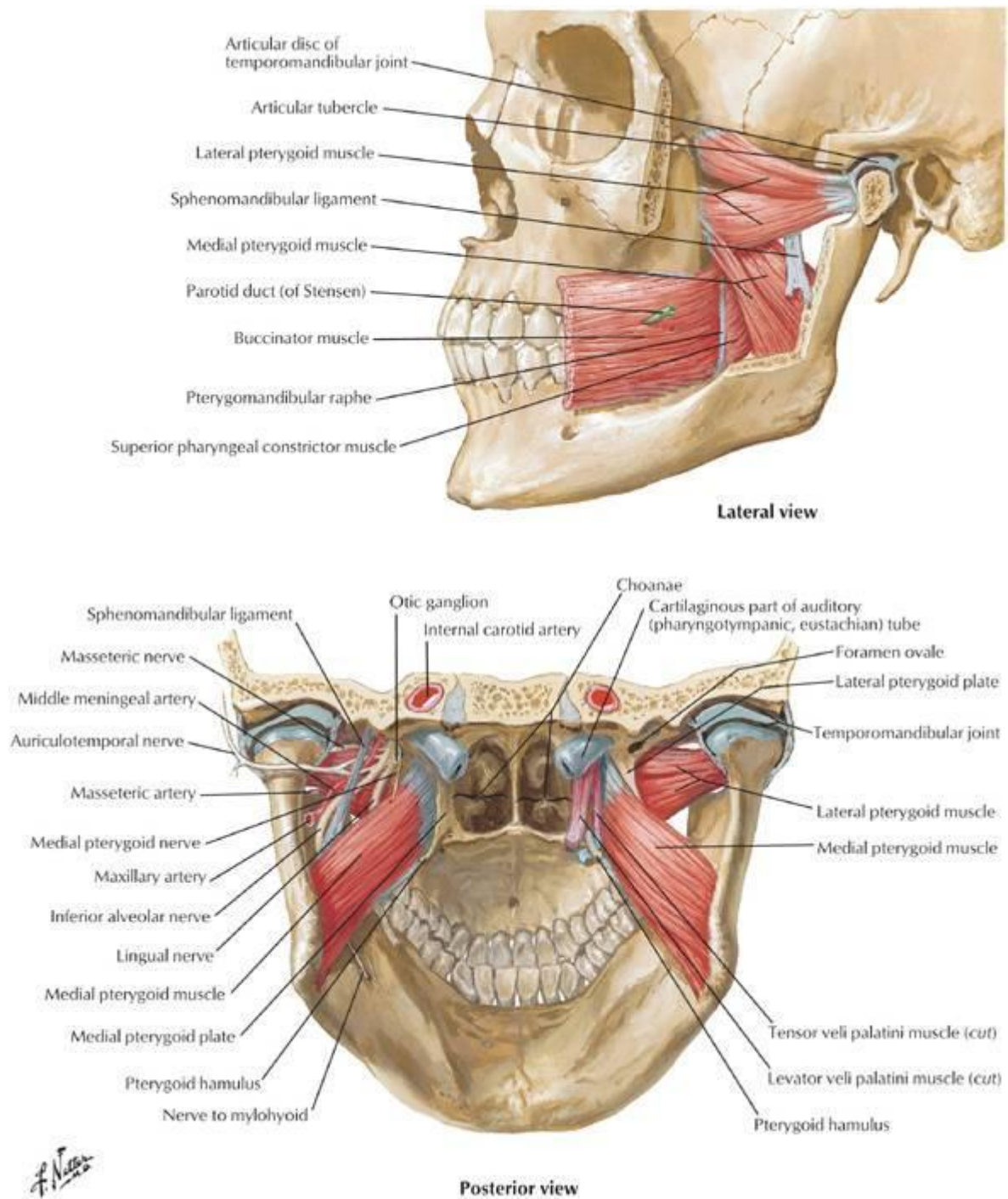
### *The colon*

The main digestive function of the large intestine is to absorb water (converting 1-2 litres of iso-osmotic chyme into 200-250 ml of semi-solid faeces).

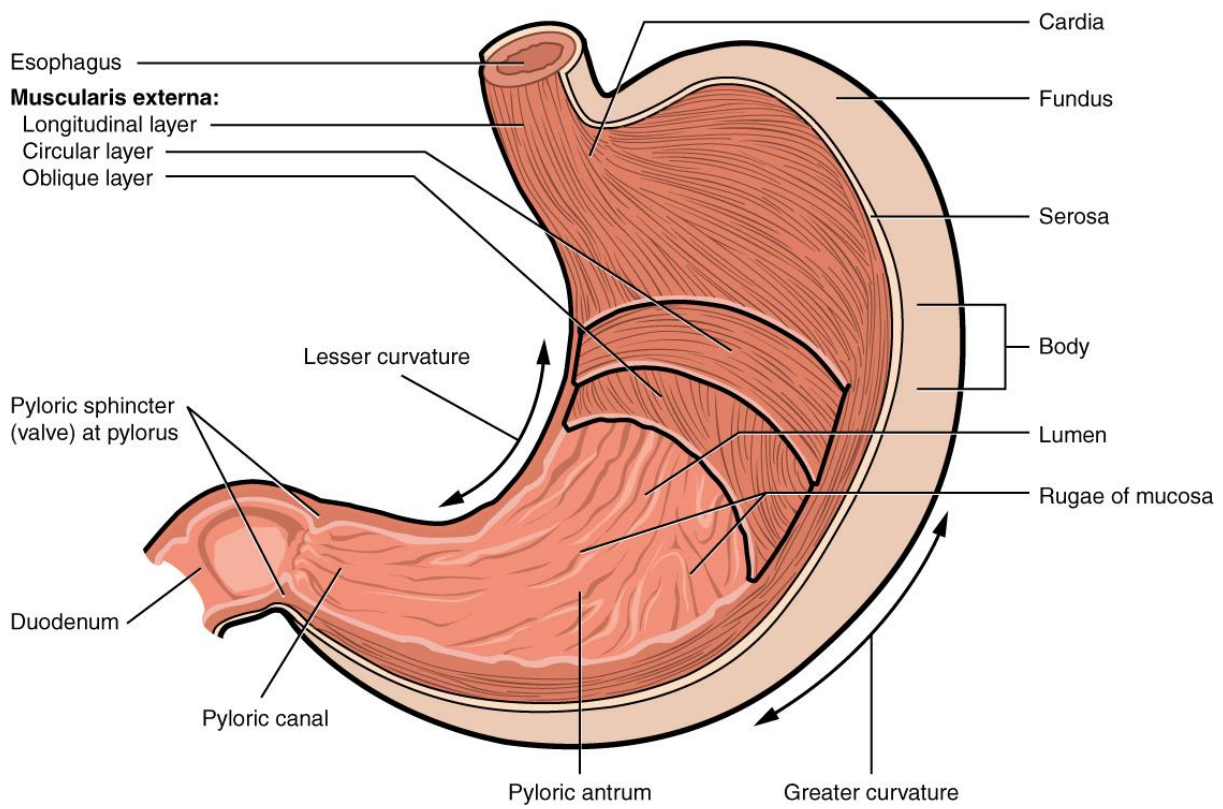
### FURTHER READING

Leonard R. Johnson. Mosby Physiology Monograph Series: Gastrointestinal Physiology, 8th Edition. Elsevier 2013.

**Figure 1** The anatomy of chewing



**Figure 2** The stomach consists of five parts anatomically and of two (proximal and distal) functionally



**Figure 3** The stomach is covered with gastric pits that open into oxyntic glands an which are lined by a variety of cells that have their own specific role in secreting gastric juices.

