

## **X-linked Inhibitor of Apoptosis complicated by Granulomatous Lymphocytic Interstitial Lung Disease (GLILD) and Granulomatous Hepatitis**

### Author affiliations

1. Dr Cathal L Steele MB BCh BAO, BA(Hons), MRCP, MRCGP. Regional Immunology Service, Royal Victoria Hospital, The Belfast Trust, Belfast, UK.
2. Dr Matthew Doré MB ChB, BSc(Hons), MRCP(UK). Regional Immunology Service, Royal Victoria Hospital, The Belfast Trust, Belfast, UK.
3. Miss Sandra Ammann MSc. Centre for Chronic Immunodeficiency, University Medical Centre Freiburg, Freiburg, Germany.
4. Dr Maurice Loughrey BSc, MRCP, FRCPath, MD. Royal Victoria Hospital, The Belfast Trust, Belfast, UK and Queen's University Belfast, Belfast, UK.
5. Dr M Angeles Montero MD, PhD. Royal Brompton and Harefield Hospitals NHS Foundation Trust, London, UK.
6. Dr Siobhan O Burns MB BAO BCh, MRCPI (Paeds), PhD. Department of Immunology, Royal Free London NHS Foundation Trust, London, UK and University College London Institute of Immunity and Transplantation, London, UK.
7. Prof Emma C Morris BA MA MB BChir PhD FRCP FRCPath. Department of Immunology, Royal Free London NHS Foundation Trust, London, UK and University College London Institute of Immunity and Transplantation, London, UK.
8. Prof H Bobby Gaspar MBBS, MRCPCH, MRCP(UK), PhD. University College London Institute of Child Health, London, UK.
9. Dr Kimberly Gilmour BSc, PhD. Department of Immunology, Great Ormond Street Hospital for Children NHS Foundation Trust, London, UK.
10. Ms Shahnaz Bibi MSc. Department of Immunology, Great Ormond Street Hospital for Children NHS Foundation Trust, London, UK
11. Dr Hiba Shendi MBBS, MD, MRCPCH, MSc, FRCPath. Regional Immunology Service, Royal Victoria Hospital, The Belfast Trust, Belfast, UK.
12. Dr Lisa Devlin MB BCh BAO, MD, MRCPCH, FRCPath. Regional Immunology Service, Royal Victoria Hospital, The Belfast Trust, Belfast, UK.
13. Dr Carsten Speckmann MD. Department of Paediatrics and Adolescent Medicine, University Medical Centre, Freiburg, Germany and Centre for Chronic Immunodeficiency, University Medical Centre Freiburg, Freiburg, Germany
14. Dr J David M Edgar MB BCh BAO, BSc, FRCP, FRCPath. Regional Immunology Service, Royal Victoria Hospital, The Belfast Trust, Belfast, UK and Queen's University Belfast, Belfast, UK.

## Introduction

The X-linked Inhibitor of Apoptosis (XIAP) deficiency is a primary immunodeficiency first described in 2006. [\(1,2\)](#) Over 70 cases have since been reported, [\(3\)](#) affecting males although there are recent reports of random X-inactivation resulting in female disease. [\(4\)](#) The clinical phenotype includes Epstein-Barr virus (EBV) driven haemophagocytic lymphohistiocytosis (HLH), Crohn's like IBD and splenomegaly. Other features such as a partial HLH, dysgammaglobulinaemia and recurring cytopenias frequently complicate this condition while uveitis, cutaneous abscesses, hepatitis, a coeliac-like enteropathy and *Giardia lamblia* enteritis have been occasionally reported. [\(5\)](#) The disease usually presents in childhood but presentation in adulthood is also recognised. No correlation has been observed between genotype/functional studies and the clinical phenotype. [\(5\)](#) XIAP, encoded by the BIRC4 gene, [\(1\)](#) belongs to a family of inhibitors of apoptosis (IAP) which have potent anti-apoptotic activity through the inactivation of caspases. [\(6\)](#) Additional functions include signal transduction through the nucleotide-binding oligomerisation domain containing 2 (NOD2) receptor and subsequent activation of mitogen-activated protein kinase (MAPK) and nuclear factor kappa B (NFκB) pathways. [\(7,8\)](#) This pro-inflammatory function of XIAP is curtailed through its negative regulatory role on the NOD-like receptor family, pyrin domain containing 3 (NLRP3) inflammasome. Additional roles in the function of Dectin-1 and regulation of tumour necrosis factor (TNF) receptor 1 signalling are reported. [\(3\)](#)

Granulomatous and Lymphocytic Interstitial Lung Disease (GLILD), as a discrete histopathological entity was first described in 2004. [\(9\)](#) The hallmarks of this condition are granulomatous and lymphoproliferative changes (lymphocytic interstitial pneumonitis, follicular bronchitis and/or lymphoid hyperplasia) on lung biopsy. GLILD has been most frequently described as a complication of CVID but has been reported with other PIDs including LRBA deficiency, [\(10\)](#) CTLA4 haploinsufficiency, [\(11\)](#) and hypomorphic RAG1 mutations [\(12\)](#). The pathophysiology of GLILD is incompletely understood but treatment is directed against infiltrating T and B lymphocytes.

Combination Rituximab and Azathioprine has been used in GLILD with reported improvements in pulmonary function (FEV<sub>1.0</sub> and FVC) and CT appearances.(14)

Here we report the first case of XIAP deficiency complicated by granulomatous hepatitis and GLILD, expanding the clinical phenotype of XIAP deficiency.

### **Clinical Case**

A male patient (#3) [\(15\)](#) was diagnosed aged 4 with EBV primary infection presenting with fever, tonsillitis, cervical lymphadenopathy and hepatosplenomegaly. He had microcytic anaemia and detectable EBV IgM. A bone marrow aspirate was reported as reactive. Computed tomography (CT) of chest, abdomen and pelvis did not demonstrate additional pathology. IgG, IgA and IgM were normal. The patient recovered uneventfully.

Aged 16 the patient presented with a 3-month history of malaise and fever. Massive splenomegaly and firm jugulodigastric and inguinal lymph nodes were palpable. Blood results are available (table 1). CT imaging showed widespread mediastinal and abdominal lymphadenopathy, massive splenomegaly and patchy areas of opacification throughout both lung fields. Plasma cells were not identified on bone marrow biopsy. There was no evidence of HLH. Lymph node histology confirmed reactive hyperplasia and prominent lymphoid follicles with large germinal centres. Immunohistochemical stains suggested reactive hyperplasia. A few small collections of histiocytes were seen but there were no granulomas. Haemophagocytosis was not identified. Mycobacterial stains and cultures were negative. EBV was not detectable in tissue sections or peripheral blood. SLAM-associated protein (SAP) expression was abnormal by Immunoblot. Symptoms resolved spontaneously over 6 weeks with resolution of cytopenias and lymphadenopathy. Intravenous immunoglobulin replacement therapy was commenced and arrangements made for assessment in a national haematopoietic stem cell transplant centre. Lymphocyte phenotyping showed almost complete absence of class-switched memory B cells, elevated transitional B cells (6.9% reference

0.6-3.4%), and mild increase in CD21<sup>lo</sup>CD38<sup>lo</sup> B cells (7.8% reference 0.9-7.6%). Repeat SAP expression by flow cytometry was normal and no mutations were found in the SH2D1A gene. XIAP protein expression was reduced and sequencing of XIAP exons 1 to 7 showed a novel missense mutation in exon 2 (c.497G→A. p.Arg166Lys variant) (figure 1). The same mutation and reduced XIAP expression was identified in 2 healthy brothers (aged 21 and 14; #4&5). The significance of the mutation was therefore uncertain. Immunoglobulins G, A and M were within normal limits for both brothers, lymphocyte phenotyping showed reduced NK cells (table 1).

At age 19 years, another episode of presumed 'partial' haemophagocytic lymphohistiocytosis (HLH) occurred. Corticosteroid therapy (Prednisolone 30mg) improved the pyrexia, weight loss and platelet counts but had no impact on splenomegaly. Liver function tests deteriorated over several months and granulomatous inflammation with very mild fibrosis was found at biopsy (figure 3). Corticosteroid dose was slowly tapered and Sirolimus introduced but this had no effect on haematological or biochemical parameters or splenic diameter. Another 'partial' HLH episode occurred 23 months later and responded similarly to oral prednisolone treatment. Haemophagocytosis was present on a bone marrow aspirate without evidence of EBV (figure 3). Progressive cough and dyspnoea was reported over several months and CT imaging (figure 4) revealed progressive interstitial changes and multiple nodular opacities, pronounced mediastinal lymphadenopathy, more marked in the lower lung zones. Pulmonary function testing (PFT) confirmed deteriorating lung function (table 2). A thoracoscopic lung biopsy identified a non-necrotising granulomatous pneumonitis, cellular and follicular bronchiolitis and moderate areas of acute and fibrosing organising pneumonia consistent with GLILD (figure 5). There was a predominantly B cell chronic mononuclear infiltrate in lung biopsy tissue. Routine tissue culture, staining for HHV8, EBV and CMV and 16S real time PCR testing were all negative. Combination chemotherapy with Rituximab (375mg/m<sup>2</sup>BSA x 4 doses) and Azathioprine (2mg/kg) led to a sustained improvement in pulmonary function and CT appearances while splenomegaly remained unchanged.

## **Methods**

### **XIAP expression**

Intracellular XIAP expression was assessed by flow cytometry as described previously [\(16\)](#) using purified anti- XIAP IgG1.

### **Activation-induced cell death**

Activation induced cell death (AICD) was performed on day 8 PHA/IL-2 blasts and were incubated with medium or plate-bound anti-CD3 or different concentrations (10, 25, 50, 100ng) of Fas Ligand (FasL) for 24 hours, stained with Annexin V (AV) and Propidium iodide (PI) and analysed by flow cytometry. The percentage of surviving cells was quantified: % AV-PI negative cells after incubation with anti-CD3 divided through % AV-PI negative cells after incubation with medium x 100.

### **Functional L18-MDP Assay**

As described previously, [\(15\)](#) PBMCs were isolated and incubated in (a) medium alone or (b) in medium supplemented with lipidated muramyl dipeptide (L18-MDP) or (c) lipopolysaccharide (LPS). After staining with mAbs against CD14 and HLA-DR the cells were fixed, permeabilised and stained for TNF $\alpha$  and results acquired by flow cytometry.

## **Results**

AICD studies failed to show increased apoptosis of activated T cells after re-stimulation with CD3/FasL in the patient or any family member (data not shown). Production of TNF $\alpha$  from monocytes using a NOD2 specific ligand (muramyl dipeptide) was absent in patient #3 and both brothers (#4 and #5) while normal for their mother (#2). Monocyte production of TNF $\alpha$  in response to lipopolysaccharide was normal (Figure 2). Given the history of HLH, the mutation in XIAP and the functional assay results the diagnosis of XIAP deficiency for #3 was confirmed, complicated by GLILD

and granulomatous hepatitis. Both brothers (#4 and #5) have confirmed asymptomatic XIAP deficiency.

The patient, now 23, continues to be considered for allogeneic haematopoietic stem cell transplantation (HSCT). A fully matched HLA sister (#6) is available.

## **Discussion**

This is the first reported case of granulomatous hepatitis and GLILD occurring in XIAP deficiency. Furthermore we demonstrate the success of combination chemotherapy with Rituximab and Azathioprine in this context. Neither Rituximab/Azathioprine nor Sirolimus alone were effective in reducing splenomegaly, despite their utility in reducing splenomegaly in CVID and Autoimmune Lymphoproliferative Syndrome (ALPS). [\(14,17\)](#) It is hoped that optimisation of pulmonary function will enhance preparation for HSCT.

The patient and his clinical phenotype have been partially reported previously.[\(15\)](#) The near normal expression of XIAP suggests a hypomorphic mutation, which could explain the normal AICD study, as there is sufficient residual expression to inhibit apoptosis *in vitro*. Two asymptomatic brothers similarly had near normal expression of XIAP and normal AICD studies while all three brothers had defective production of TNF $\alpha$  following stimulation with a NOD2 specific ligand. We speculate that there must be additional unknown environmental and/or genetic factors which influence the phenotypic expression of disease in this condition. Normal apoptosis studies do not exclude XIAP deficiency and therefore limit their clinical utility in this disease. [\(18\)](#) The roles of XIAP in signal transduction through NOD1/2 and in regulation of inflammasomes continue to be elucidated [\(3\)](#) but the failure of effective pathogen sensing coupled with defective inhibitory pathways of inflammasome control might explain some of the inflammation in this condition. It is of note that the inflammation seen in Crohn's disease is associated with aberrant signalling through NOD2,[\(19,20\)](#) and the defective NOD2 signalling seen in this case may implicate this pathway as

important in the pathophysiology of GLILD and granulomatous hepatitis. This case highlights a potential broadening of the clinical phenotype of XIAP deficiency and the importance and complexity of molecular case definition. It is important to consider the possibility of GLILD and granulomatous hepatitis in XIAP deficiency and indeed the possibility of XIAP deficiency in 'atypical' or severe CVID.

## References

- (1) [Rigaud S, Fondaneche MC, Lambert N, Pasquier B, Mateo V, Soulas P, et al. XIAP deficiency in humans causes an X-linked lymphoproliferative syndrome. Nature 2006 Nov 2;444\(7115\):110-114.](#)
- (2) [Marsh RA, Madden L, Kitchen BJ, Mody R, McClimon B, Jordan MB, et al. XIAP deficiency: a unique primary immunodeficiency best classified as X-linked familial hemophagocytic lymphohistiocytosis and not as X-linked lymphoproliferative disease. Blood 2010 Aug 19;116\(7\):1079-1082.](#)
- (3) [Latour S, Aguilar C. XIAP deficiency syndrome in humans. Semin Cell Dev Biol 2015 Mar;39:115-123.](#)
- (4) [Dziadzio M, Ammann S, Canning C, Boyle F, Hassan A, Cale C, et al. Symptomatic Males and Female Carriers in a Large Caucasian Kindred with XIAP Deficiency. J Clin Immunol 2015 May 6.](#)
- (5) [Speckmann C, Lehmeberg K, Albert MH, Damgaard RB, Fritsch M, Gyrd-Hansen M, et al. X-linked inhibitor of apoptosis \(XIAP\) deficiency: the spectrum of presenting manifestations beyond hemophagocytic lymphohistiocytosis. Clin Immunol 2013 Oct;149\(1\):133-141.](#)
- (6) [Salvesen GS, Duckett CS. IAP proteins: blocking the road to death's door. Nat Rev Mol Cell Biol 2002 Jun;3\(6\):401-410.](#)
- (7) [Park JH, Kim YG, Shaw M, Kanneganti TD, Fujimoto Y, Fukase K, et al. Nod1/RICK and TLR signaling regulate chemokine and antimicrobial innate immune responses in mesothelial cells. J Immunol 2007 Jul 1;179\(1\):514-521.](#)
- (8) [Hasegawa M, Fujimoto Y, Lucas PC, Nakano H, Fukase K, Nunez G, et al. A critical role of RICK/RIP2 polyubiquitination in Nod-induced NF-kappaB activation. EMBO J 2008 Jan 23;27\(2\):373-383.](#)
- (9) [Bates CA, Ellison MC, Lynch DA, Cool CD, Brown KK, Routes JM. Granulomatous-lymphocytic lung disease shortens survival in common variable immunodeficiency. J Allergy Clin Immunol 2004 Aug;114\(2\):415-421.](#)
- (10) [Gamez-Diaz L, August D, Stepensky P, Revel-Vilk S, Seidel MG, Noriko M, et al. The extended phenotype of LPS-responsive beige-like anchor protein \(LRBA\) deficiency. J Allergy Clin Immunol 2016 Jan;137\(1\):223-230.](#)

[\(11\) Schubert D, Bode C, Kenefeck R, Hou TZ, Wing JB, Kennedy A, et al. Autosomal dominant immune dysregulation syndrome in humans with CTLA4 mutations. Nat Med 2014 Dec;20\(12\):1410-1416.](#)

[\(12\) Schuetz C, Huck K, Gudowius S, Megahed M, Feyen O, Hubner B, et al. An immunodeficiency disease with RAG mutations and granulomas. N Engl J Med 2008 May 8;358\(19\):2030-2038.](#)

[\(13\) De Dios JA, Javaid AA, Ballesteros E, Metersky ML. An 18-year-old woman with Kabuki syndrome, immunoglobulin deficiency and granulomatous lymphocytic interstitial lung disease. Conn Med 2012 Jan;76\(1\):15-18.](#)

[\(14\) Chase NM, Verbsky JW, Hintermeyer MK, Waukau JK, Tomita-Mitchell A, Casper JT, et al. Use of combination chemotherapy for treatment of granulomatous and lymphocytic interstitial lung disease \(GLILD\) in patients with common variable immunodeficiency \(CVID\). J Clin Immunol 2013 Jan;33\(1\):30-39.](#)

[\(15\) Ammann S, Elling R, Gyrd-Hansen M, Duckers G, Bredius R, Burns SO, et al. A new functional assay for the diagnosis of X-linked inhibitor of apoptosis \(XIAP\) deficiency. Clin Exp Immunol 2014 Jun;176\(3\):394-400.](#)

[\(16\) Bryceson YT, Pende D, Maul-Pavicic A, Gilmour KC, Ufheil H, Vraetz T, et al. A prospective evaluation of degranulation assays in the rapid diagnosis of familial hemophagocytic syndromes. Blood 2012 Mar 22;119\(12\):2754-2763.](#)

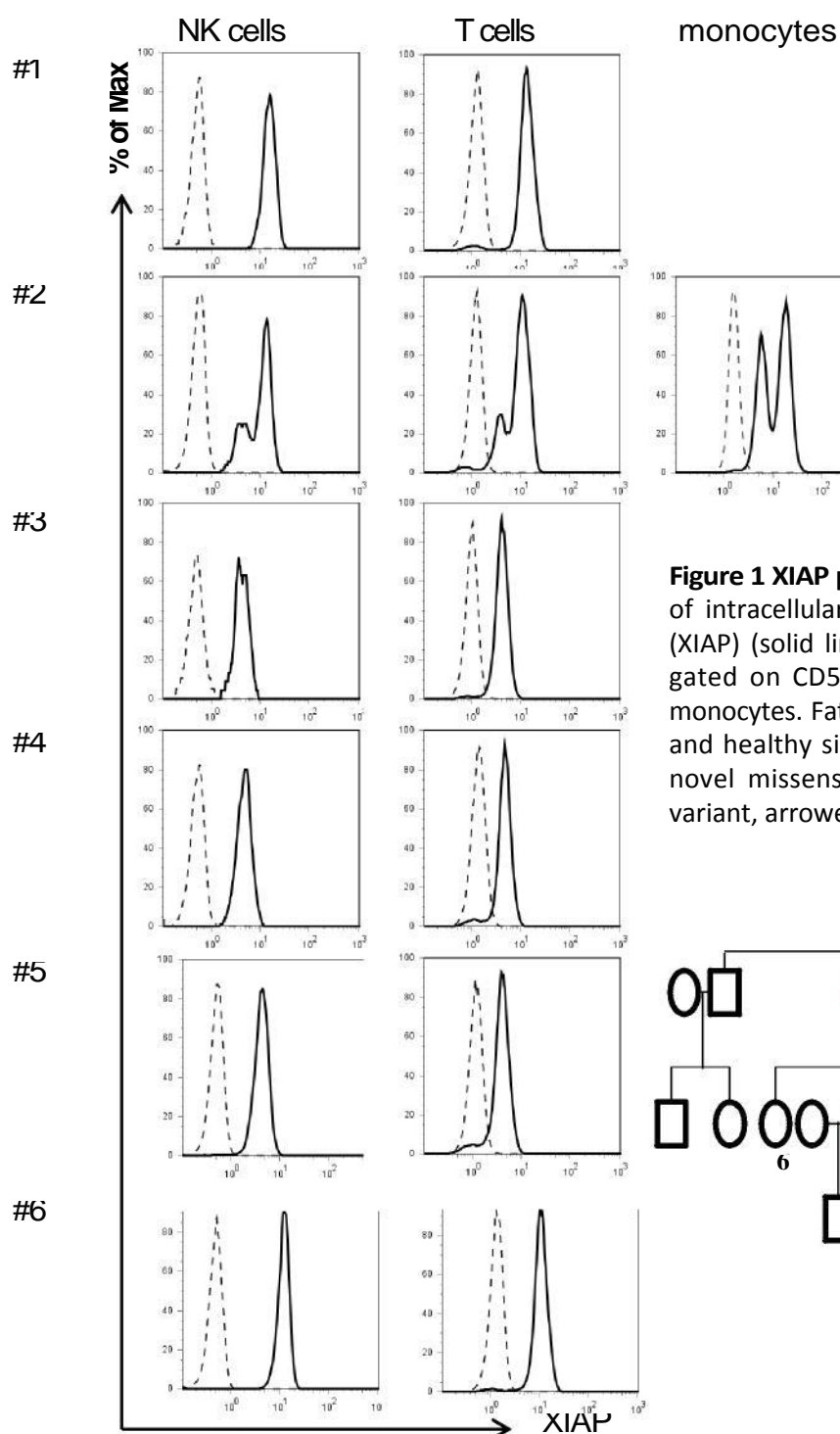
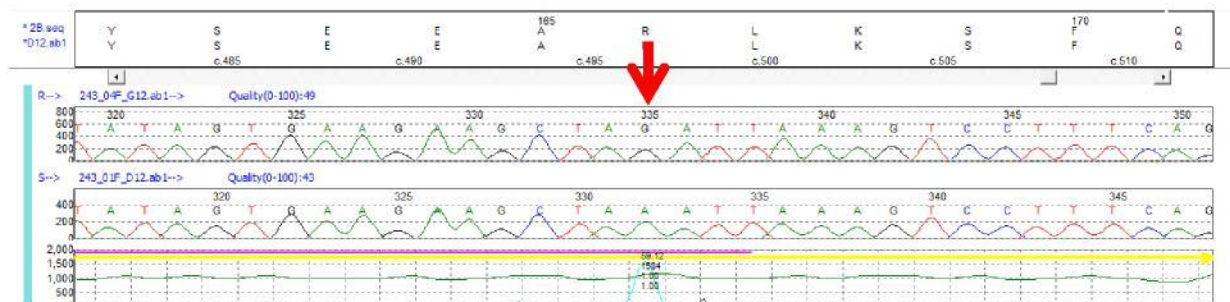
[\(17\) Teachey DT. New advances in the diagnosis and treatment of autoimmune lymphoproliferative syndrome. Curr Opin Pediatr 2012 Feb;24\(1\):1-8.](#)

[\(18\) Speckmann C, Lehmborg K, Albert MH, Damgaard RB, Fritsch M, Gyrd-Hansen M, et al. X-linked inhibitor of apoptosis \(XIAP\) deficiency: the spectrum of presenting manifestations beyond hemophagocytic lymphohistiocytosis. Clin Immunol 2013 Oct;149\(1\):133-141.](#)

[\(19\) Hugot JP, Chamaillard M, Zouali H, Lesage S, Cezard JP, Belaiche J, et al. Association of NOD2 leucine-rich repeat variants with susceptibility to Crohn's disease. Nature 2001 May 31;411\(6837\):599-603.](#)

[\(20\) Strober W, Asano N, Fuss I, Kitani A, Watanabe T. Cellular and molecular mechanisms underlying NOD2 risk-associated polymorphisms in Crohn's disease. Immunol Rev 2014 Jul;260\(1\):249-260.](#)





**Figure 1 XIAP protein expression and mutational analysis** Overlay of intracellular staining with anti-X-linked inhibitor of apoptosis (XIAP) (solid line) and an isotype control antibody (dashed line), gated on CD56+CD3- NK cells, CD3+ T lymphocytes or CD14+ monocytes. Father #1, Mother #2, index-patient #3, brothers #4+5 and healthy sister #6. Sequencing of XIAP exons 1 to 7 shows a novel missense mutation in exon 2 (c.497G→A. p.Arg166Lys variant, arrowed).

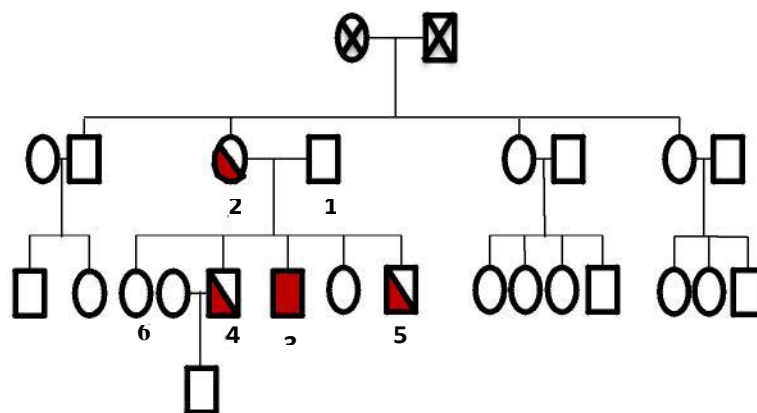
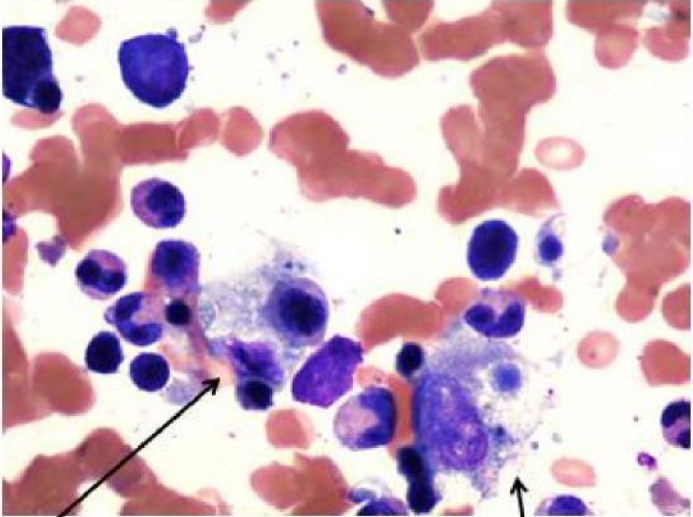
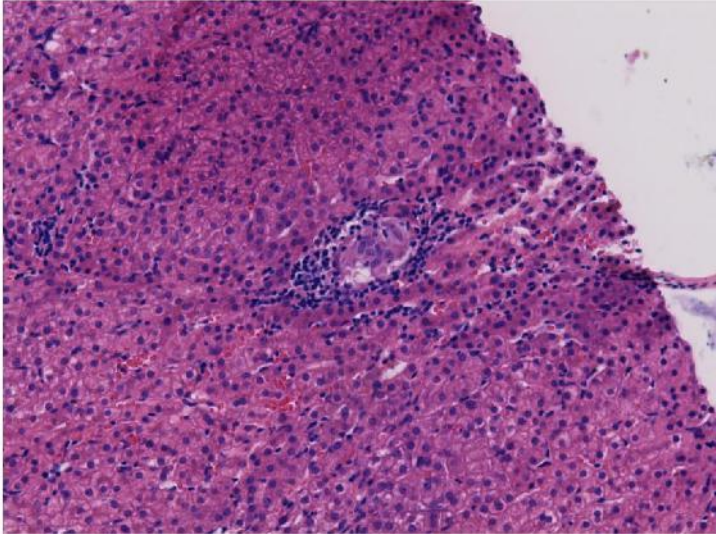




Figure 3. Liver biopsy and Bone Marrow aspirate. Liver biopsy shows scattered small epithelioid non-caseating granulomata with a surrounding cuff of lymphoid cells, located within the liver parenchyma. Surrounding parenchyma shows minimal inflammation. Portal areas (not shown) were unremarkable. Bone marrow aspirate shows activated histiocytes present with phagocytosed erythroblasts and giant platelets.



Histiocyte with 2 erythroblasts

Histiocyte with giant platelet

Figure 4. High resolution CT chest appearances before (a) and after (b) combination chemotherapy.

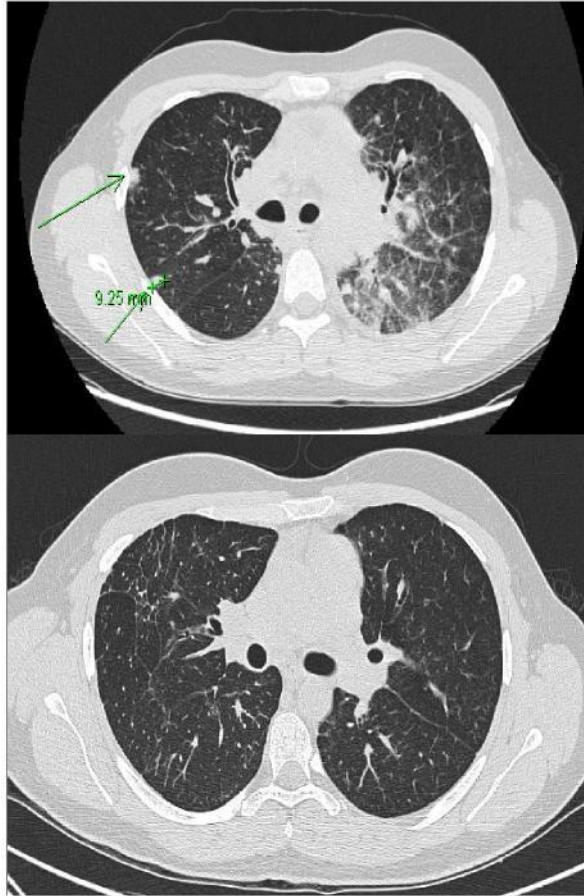
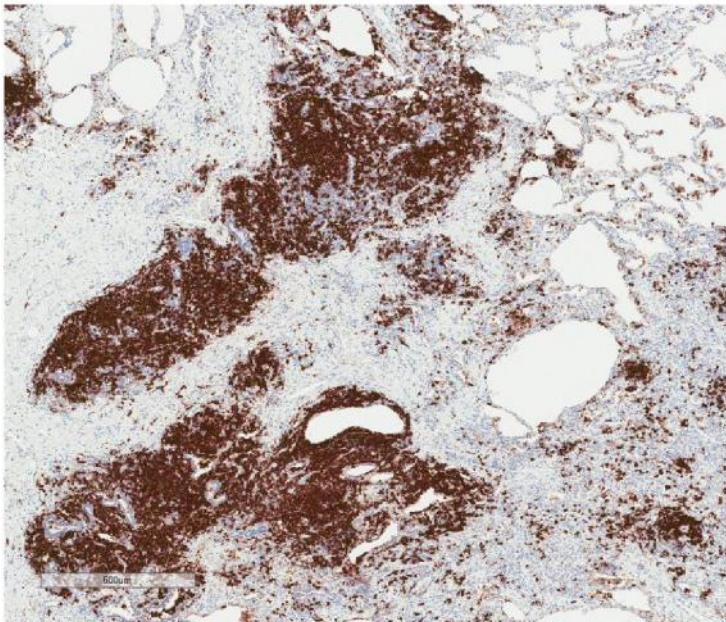
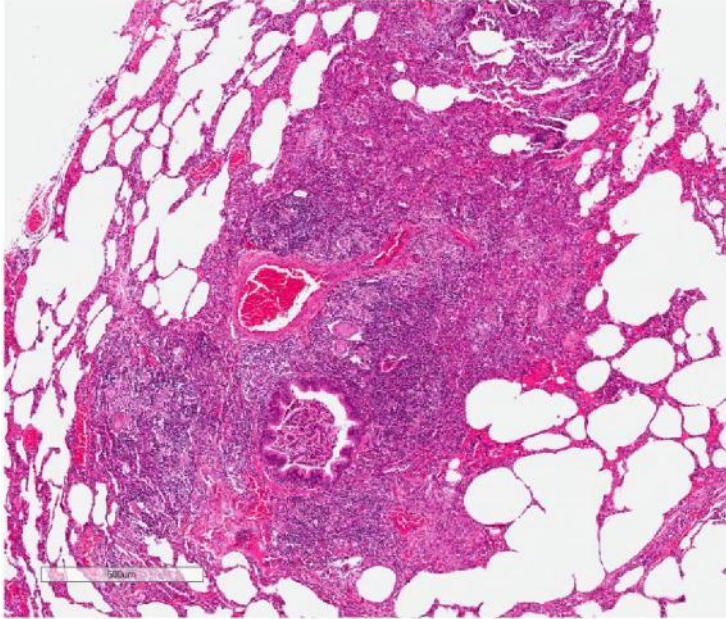
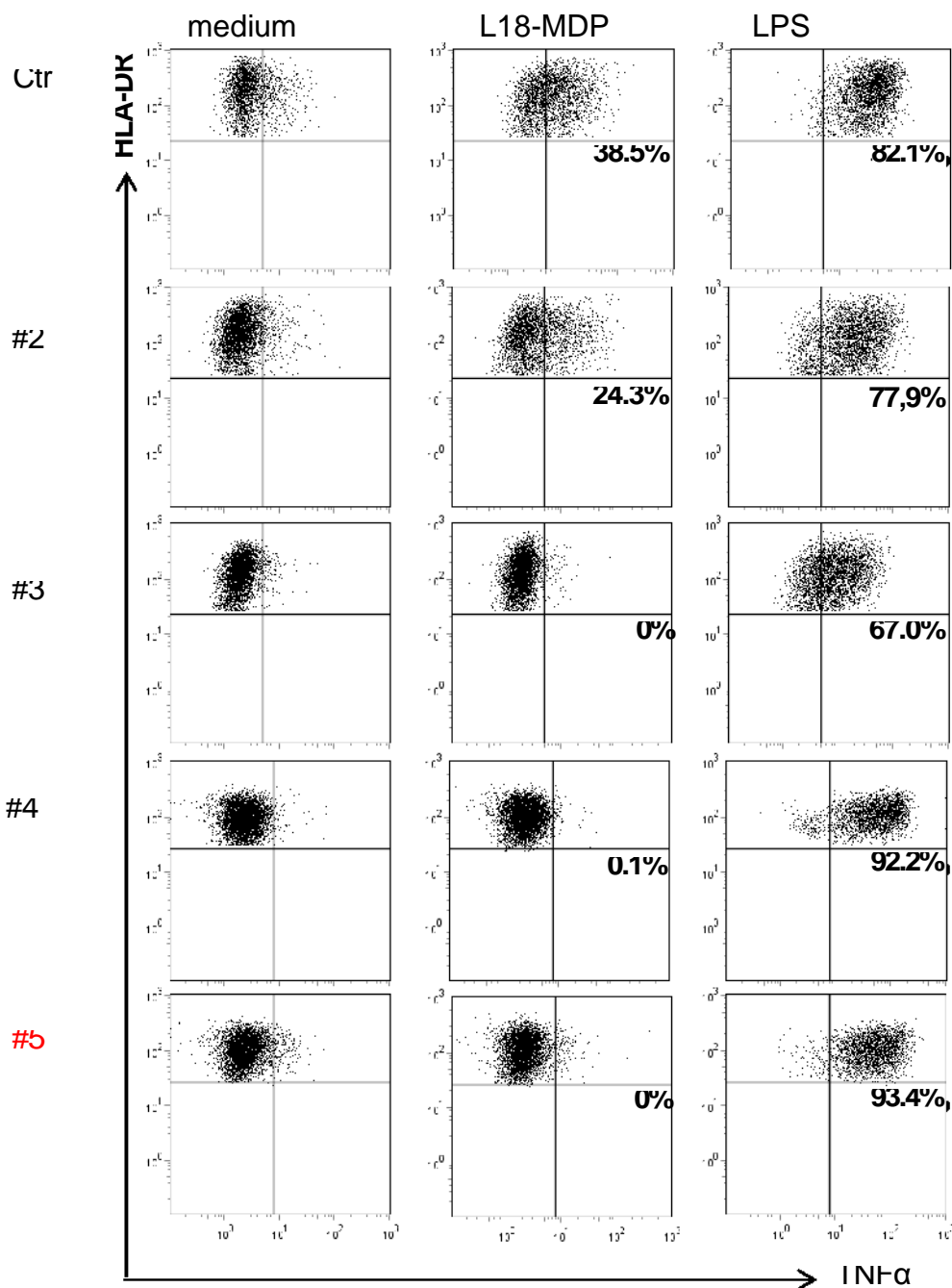




Figure 5. Lung biopsy. Centrilobular cellular and fibrotic chronic and non-necrotising granulomatous inflammation. Loose granulomas which comprise aggregates of multinucleated giant cells are the main feature. Chronic mononuclear inflammation comprise mainly B lymphocytes (>75%). This is highlighted by immunohistochemistry for CD20, which shows an intense and diffuse staining in B cell lymphocytes.





### Figure 2: Functional analysis of XIAP with L18-MDP stimulation:

TNF-producing monocytes from a healthy donor, the mother (#2) and the index patient (#3) and affected brothers (#4+5) stimulated with medium alone, 200 ng/ml L18-MDP or 200 ng/ml lipopolysaccharide (LPS). The percentages indicate the delta percentage of TNF-positive cells (stimulated - medium) of all HLA-DR+CD14+ monocytes.

Table 1. Results of investigations for patients #3, #4 & #5. Lymphocyte phenotyping reference ranges from O’Gorman (2010)

	Reference range	Index patient (#3)	Brother (#4)	Brother (#5)
Hb	130-180 g/L	96 g/L	163 g/L	147 g/L
Platelets	150-450 x10 <sup>9</sup> /L	51 x10 <sup>9</sup> /L	204 x10 <sup>9</sup> /L	216 x10 <sup>9</sup> /L
White cell count	4.0-10.0 x10 <sup>9</sup> /L	3.0 x10 <sup>9</sup> /L	5.8 x10 <sup>9</sup> /L	6.4 x10 <sup>9</sup> /L
Neutrophils	2.0-7.5 x10 <sup>9</sup> /L	1.63 x10 <sup>9</sup> /L	3.4 x10 <sup>9</sup> /L	3.7 x10 <sup>9</sup> /L
AST	5-40 U/L	96 U/L	38 U/L	41 U/L
GGT	10-71U/L	81 U/L	10-71 U/L	12 U/L
Triglycerides	<1.70 mmol/L	2.85 mmol/L	1.13 mmol/L	1.85 mmol/L
Fibrinogen	2-6 g/L	1.68 g/L	n/a	n/a
Ferritin	30-400 µg/L	16437 µg/L	176 µg/L	72 µg/L
IgG	6.0-16.0 g/L	<0.66 g/L	9.05 g/L	9.74 g/L
IgA	0.80-2.80 g/L	<0.05 g/L	1.71 g/L	1.34 g/L
IgM	0.50-2.00 g/L	<0.05 g/L	0.93 g/L	0.59 g/L
Lymphocytes	1.56-4.57 x10 <sup>9</sup> /L	1.81 x10 <sup>9</sup> /L	1.54 x10 <sup>9</sup> /L	2.00 x10 <sup>9</sup> /L
CD3 absolute	1.05-3.03 x10 <sup>9</sup> /L	1.62 x10 <sup>9</sup> /L	1.20 x10 <sup>9</sup> /L	1.35 x10 <sup>9</sup> /L
CD4 absolute	0.55-1.72 x10 <sup>9</sup> /L	0.62 x10 <sup>9</sup> /L	0.81 x10 <sup>9</sup> /L	0.89 x10 <sup>9</sup> /L
CD8 absolute	0.33-1.31 x10 <sup>9</sup> /L	0.91 x10 <sup>9</sup> /L	0.34 x10 <sup>9</sup> /L	0.41 x10 <sup>9</sup> /L
CD19 absolute	0.20-1.14 x10 <sup>9</sup> /L	0.16 x10 <sup>9</sup> /L	0.26 x10 <sup>9</sup> /L	0.52 x10 <sup>9</sup> /L
CD 16/56 absolute	0.14-1.03 x10 <sup>9</sup> /L	0.01 x10 <sup>9</sup> /L	0.06 x10 <sup>9</sup> /L	0.09 x10 <sup>9</sup> /L

**Table 2. pulmonary function test results before and after treatment with Rituximab/Azathioprine (RA)**

	Aged 18	Aged 21	Aged 21 (2m pre- RA)	3m post- RA	6m post- RA	8m post- RA	21 m post- RA
FEV <sub>1</sub> (% predicted)	3.38 (86)	3.05 (78)	2.02 (53)	3.20 (82)	3.17 (81)	3.28 (84)	3.22 (82)
FVC (% predicted)	3.64 (80)	3.45 (76)	2.27 (51)	3.50 (77)	3.66 (80)	3.72 (82)	3.80 (83)
FEV <sub>1</sub> /FVC	83%	88%	89%	91%	86%	88%	85%
Transfer factor TLCO	78%	7.19 (67)	N/A	7.03 (66)	7.84 (73)	7.89 (74)	8.04 (75)
KLCO		1.59 (85)	N/A	1.66 (88)	1.74 (93)	1.76 (94)	1.82 (97)
TLC		4.61 (77)	N/A	4.39 (73)	4.62 (77)	4.54 (75)	4.68 (77)
RV		1.13 (76)	N/A	1.04 (70)	0.94 (63)	0.86 (58)	0.97 (64)



## **X-linked Inhibitor of Apoptosis complicated by Granulomatous Lymphocytic Interstitial Lung Disease (GLILD) and Granulomatous Hepatitis**

### Author affiliations

1. Dr Cathal L Steele MB BCh BAO, BA(Hons), MRCP, MRCPGP. Regional Immunology Service, Royal Victoria Hospital, The Belfast Trust, Belfast, UK.
2. Dr Matthew Doré MB ChB, BSc(Hons), MRCP(UK). Regional Immunology Service, Royal Victoria Hospital, The Belfast Trust, Belfast, UK.
3. Miss Sandra Ammann MSc. Centre for Chronic Immunodeficiency, University Medical Centre Freiburg, Freiburg, Germany.
4. Dr Maurice Loughrey BSc, MRCP, FRCPath, MD. Royal Victoria Hospital, The Belfast Trust, Belfast, UK and Queen's University Belfast, Belfast, UK.
5. Dr M Angeles Montero MD, PhD. Royal Brompton and Harefield Hospitals NHS Foundation Trust, London, UK.
6. Dr Siobhan O Burns MB BAO BCh, MRCPI (Paeds), PhD. Department of Immunology, Royal Free London NHS Foundation Trust, London, UK and University College London Institute of Immunity and Transplantation, London, UK.
7. Prof Emma C Morris BA MA MB BChir PhD FRCP FRCPath. Department of Immunology, Royal Free London NHS Foundation Trust, London, UK and University College London Institute of Immunity and Transplantation, London, UK.
8. Prof H Bobby Gaspar MBBS, MRCPCH, MRCP(UK), PhD. University College London Institute of Child Health, London, UK.
9. Dr Kimberly Gilmour BSc, PhD. Department of Immunology, Great Ormond Street Hospital for Children NHS Foundation Trust, London, UK.
10. Ms Shahnaz Bibi MSc. Department of Immunology, Great Ormond Street Hospital for Children NHS Foundation Trust, London, UK
11. Dr Hiba Shendi MBBS, MD, MRCPCH, MSc, FRCPath. Regional Immunology Service, Royal Victoria Hospital, The Belfast Trust, Belfast, UK.
12. Dr Lisa Devlin MB BCh BAO, MD, MRCPCH, FRCPath. Regional Immunology Service, Royal Victoria Hospital, The Belfast Trust, Belfast, UK.
13. Dr Carsten Speckmann MD. Department of Paediatrics and Adolescent Medicine, University Medical Centre, Freiburg, Germany and Centre for Chronic Immunodeficiency, University Medical Centre Freiburg, Freiburg, Germany
14. Dr J David M Edgar MB BCh BAO, BSc, FRCP, FRCPath. Regional Immunology Service, Royal Victoria Hospital, The Belfast Trust, Belfast, UK and Queen's University Belfast, Belfast, UK.

## Introduction

The X-linked Inhibitor of Apoptosis (XIAP) deficiency is a primary immunodeficiency first described in 2006. [\(1,2\)](#) Over 70 cases have since been reported, [\(3\)](#) affecting males although there are recent reports of random X-inactivation resulting in female disease. [\(4\)](#) The clinical phenotype includes Epstein-Barr virus (EBV) driven haemophagocytic lymphohistiocytosis (HLH), Crohn's like IBD and splenomegaly. Other features such as a partial HLH, dysgammaglobulinaemia and recurring cytopenias frequently complicate this condition while uveitis, cutaneous abscesses, hepatitis, a coeliac-like enteropathy and *Giardia lamblia* enteritis have been occasionally reported. [\(5\)](#) The disease usually presents in childhood but presentation in adulthood is also recognised. No correlation has been observed between genotype/functional studies and the clinical phenotype. [\(5\)](#) XIAP, encoded by the BIRC4 gene, [\(1\)](#) belongs to a family of inhibitors of apoptosis (IAP) which have potent anti-apoptotic activity through the inactivation of caspases. [\(6\)](#) Additional functions include signal transduction through the nucleotide-binding oligomerisation domain containing 2 (NOD2) receptor and subsequent activation of mitogen-activated protein kinase (MAPK) and nuclear factor kappa B (NFκB) pathways. [\(7,8\)](#) This pro-inflammatory function of XIAP is curtailed through its negative regulatory role on the NOD-like receptor family, pyrin domain containing 3 (NLRP3) inflammasome. Additional roles in the function of Dectin-1 and regulation of tumour necrosis factor (TNF) receptor 1 signalling are reported. [\(3\)](#)

Granulomatous and Lymphocytic Interstitial Lung Disease (GLILD), as a discrete histopathological entity was first described in 2004. [\(9\)](#) The hallmarks of this condition are granulomatous and lymphoproliferative changes (lymphocytic interstitial pneumonitis, follicular bronchitis and/or lymphoid hyperplasia) on lung biopsy. GLILD has been most frequently described as a complication of CVID but has been reported with other PIDs including LRBA deficiency, [\(10\)](#) CTLA4 haploinsufficiency, [\(11\)](#) and hypomorphic RAG1 mutations [\(12\)](#). The pathophysiology of GLILD is incompletely understood but treatment is directed against infiltrating T and B lymphocytes.

Combination Rituximab and Azathioprine has been used in GLILD with reported improvements in pulmonary function (FEV<sub>1.0</sub> and FVC) and CT appearances.(14)

Here we report the first case of XIAP deficiency complicated by granulomatous hepatitis and GLILD, expanding the clinical phenotype of XIAP deficiency.

### **Clinical Case**

A male patient (#3) [\(15\)](#) was diagnosed aged 4 with EBV primary infection presenting with fever, tonsillitis, cervical lymphadenopathy and hepatosplenomegaly. He had microcytic anaemia and detectable EBV IgM. A bone marrow aspirate was reported as reactive. Computed tomography (CT) of chest, abdomen and pelvis did not demonstrate additional pathology. IgG, IgA and IgM were normal. The patient recovered uneventfully.

Aged 16 the patient presented with a 3-month history of malaise and fever. Massive splenomegaly and firm jugulodigastric and inguinal lymph nodes were palpable. Blood results are available (table 1). CT imaging showed widespread mediastinal and abdominal lymphadenopathy, massive splenomegaly and patchy areas of opacification throughout both lung fields. Plasma cells were not identified on bone marrow biopsy. There was no evidence of HLH. Lymph node histology confirmed reactive hyperplasia and prominent lymphoid follicles with large germinal centres. Immunohistochemical stains suggested reactive hyperplasia. A few small collections of histiocytes were seen but there were no granulomas. Haemophagocytosis was not identified. Mycobacterial stains and cultures were negative. EBV was not detectable in tissue sections or peripheral blood. SLAM-associated protein (SAP) expression was abnormal by Immunoblot. Symptoms resolved spontaneously over 6 weeks with resolution of cytopenias and lymphadenopathy. Intravenous immunoglobulin replacement therapy was commenced and arrangements made for assessment in a national haematopoietic stem cell transplant centre. Lymphocyte phenotyping showed almost complete absence of class-switched memory B cells, elevated transitional B cells (6.9% reference

0.6-3.4%), and mild increase in CD21<sup>lo</sup>CD38<sup>lo</sup> B cells (7.8% reference 0.9-7.6%). Repeat SAP expression by flow cytometry was normal and no mutations were found in the SH2D1A gene. XIAP protein expression was reduced and sequencing of XIAP exons 1 to 7 showed a novel missense mutation in exon 2 (c.497G→A. p.Arg166Lys variant) (figure 1). The same mutation and reduced XIAP expression was identified in 2 healthy brothers (aged 21 and 14; #4&5). The significance of the mutation was therefore uncertain. Immunoglobulins G, A and M were within normal limits for both brothers, lymphocyte phenotyping showed reduced NK cells (table 1).

At age 19 years, another episode of presumed 'partial' haemophagocytic lymphohistiocytosis (HLH) occurred. Corticosteroid therapy (Prednisolone 30mg) improved the pyrexia, weight loss and platelet counts but had no impact on splenomegaly. Liver function tests deteriorated over several months and granulomatous inflammation with very mild fibrosis was found at biopsy (figure 3). Corticosteroid dose was slowly tapered and Sirolimus introduced but this had no effect on haematological or biochemical parameters or splenic diameter. Another 'partial' HLH episode occurred 23 months later and responded similarly to oral prednisolone treatment. Haemophagocytosis was present on a bone marrow aspirate without evidence of EBV (figure 3). Progressive cough and dyspnoea was reported over several months and CT imaging (figure 4) revealed progressive interstitial changes and multiple nodular opacities, pronounced mediastinal lymphadenopathy, more marked in the lower lung zones. Pulmonary function testing (PFT) confirmed deteriorating lung function (table 2). A thoracoscopic lung biopsy identified a non-necrotising granulomatous pneumonitis, cellular and follicular bronchiolitis and moderate areas of acute and fibrosing organising pneumonia consistent with GLILD (figure 5). There was a predominantly B cell chronic mononuclear infiltrate in lung biopsy tissue. Routine tissue culture, staining for HHV8, EBV and CMV and 16S real time PCR testing were all negative. Combination chemotherapy with Rituximab (375mg/m<sup>2</sup>BSA x 4 doses) and Azathioprine (2mg/kg) led to a sustained improvement in pulmonary function and CT appearances while splenomegaly remained unchanged.

## **Methods**

### **XIAP expression**

Intracellular XIAP expression was assessed by flow cytometry as described previously [\(16\)](#) using purified anti- XIAP IgG1.

### **Activation-induced cell death**

Activation induced cell death (AICD) was performed on day 8 PHA/IL-2 blasts and were incubated with medium or plate-bound anti-CD3 or different concentrations (10, 25, 50, 100ng) of Fas Ligand (FasL) for 24 hours, stained with Annexin V (AV) and Propidium iodide (PI) and analysed by flow cytometry. The percentage of surviving cells was quantified: % AV-PI negative cells after incubation with anti-CD3 divided through % AV-PI negative cells after incubation with medium x 100.

### **Functional L18-MDP Assay**

As described previously, [\(15\)](#) PBMCs were isolated and incubated in (a) medium alone or (b) in medium supplemented with lipidated muramyl dipeptide (L18-MDP) or (c) lipopolysaccharide (LPS). After staining with mAbs against CD14 and HLA-DR the cells were fixed, permeabilised and stained for TNF $\alpha$  and results acquired by flow cytometry.

## **Results**

AICD studies failed to show increased apoptosis of activated T cells after re-stimulation with CD3/FasL in the patient or any family member (data not shown). Production of TNF $\alpha$  from monocytes using a NOD2 specific ligand (muramyl dipeptide) was absent in patient #3 and both brothers (#4 and #5) while normal for their mother (#2). Monocyte production of TNF $\alpha$  in response to lipopolysaccharide was normal (Figure 2). Given the history of HLH, the mutation in XIAP and the functional assay results the diagnosis of XIAP deficiency for #3 was confirmed, complicated by GLILD

and granulomatous hepatitis. Both brothers (#4 and #5) have confirmed asymptomatic XIAP deficiency.

The patient, now 23, continues to be considered for allogeneic haematopoietic stem cell transplantation (HSCT). A fully matched HLA sister (#6) is available.

## **Discussion**

This is the first reported case of granulomatous hepatitis and GLILD occurring in XIAP deficiency. Furthermore we demonstrate the success of combination chemotherapy with Rituximab and Azathioprine in this context. Neither Rituximab/Azathioprine nor Sirolimus alone were effective in reducing splenomegaly, despite their utility in reducing splenomegaly in CVID and Autoimmune Lymphoproliferative Syndrome (ALPS). [\(14,17\)](#) It is hoped that optimisation of pulmonary function will enhance preparation for HSCT.

[The patient and his clinical phenotype have been partially reported previously. The mutation present in this case was previously reported. \(15\)](#) The near normal expression of XIAP suggests a hypomorphic mutation, which could explain the normal AICD study, as there is sufficient residual expression to inhibit apoptosis *in vitro*. Two asymptomatic brothers similarly had near normal expression of XIAP and normal AICD studies while all three brothers had defective production of TNF $\alpha$  following stimulation with a NOD2 specific ligand. We speculate that there must be additional unknown environmental and/or genetic factors which influence the phenotypic expression of disease in this condition. Normal apoptosis studies do not exclude XIAP deficiency and therefore limit their clinical utility in this disease. [\(18\)](#) The roles of XIAP in signal transduction through NOD1/2 and in regulation of inflammasomes continue to be elucidated (3) but the failure of effective pathogen sensing coupled with defective inhibitory pathways of inflammasome control might explain some of the inflammation in this condition. It is of note that the inflammation seen in Crohn's disease is associated with aberrant signalling through NOD2, (19,20) and the defective NOD2

signalling seen in this case may implicate this pathway as important in the pathophysiology of GLILD and granulomatous hepatitis. This case highlights a potential broadening of the clinical phenotype of XIAP deficiency and the importance and complexity of molecular case definition. It is important to consider the possibility of GLILD and granulomatous hepatitis in XIAP deficiency and indeed the possibility of XIAP deficiency in 'atypical' or severe COVID.

## References

- (1) [Rigaud S, Fondaneche MC, Lambert N, Pasquier B, Mateo V, Soulas P, et al. XIAP deficiency in humans causes an X-linked lymphoproliferative syndrome. Nature 2006 Nov 2;444\(7115\):110-114.](#)
- (2) [Marsh RA, Madden L, Kitchen BJ, Mody R, McClimon B, Jordan MB, et al. XIAP deficiency: a unique primary immunodeficiency best classified as X-linked familial hemophagocytic lymphohistiocytosis and not as X-linked lymphoproliferative disease. Blood 2010 Aug 19;116\(7\):1079-1082.](#)
- (3) [Latour S, Aguilar C. XIAP deficiency syndrome in humans. Semin Cell Dev Biol 2015 Mar;39:115-123.](#)
- (4) [Dziadzio M, Ammann S, Canning C, Boyle F, Hassan A, Cale C, et al. Symptomatic Males and Female Carriers in a Large Caucasian Kindred with XIAP Deficiency. J Clin Immunol 2015 May 6.](#)
- (5) [Speckmann C, Lehmborg K, Albert MH, Damgaard RB, Fritsch M, Gyrd-Hansen M, et al. X-linked inhibitor of apoptosis \(XIAP\) deficiency: the spectrum of presenting manifestations beyond hemophagocytic lymphohistiocytosis. Clin Immunol 2013 Oct;149\(1\):133-141.](#)
- (6) [Salvesen GS, Duckett CS. IAP proteins: blocking the road to death's door. Nat Rev Mol Cell Biol 2002 Jun;3\(6\):401-410.](#)
- (7) [Park JH, Kim YG, Shaw M, Kanneganti TD, Fujimoto Y, Fukase K, et al. Nod1/RICK and TLR signaling regulate chemokine and antimicrobial innate immune responses in mesothelial cells. J Immunol 2007 Jul 1;179\(1\):514-521.](#)
- (8) [Hasegawa M, Fujimoto Y, Lucas PC, Nakano H, Fukase K, Nunez G, et al. A critical role of RICK/RIP2 polyubiquitination in Nod-induced NF-kappaB activation. EMBO J 2008 Jan 23;27\(2\):373-383.](#)
- (9) [Bates CA, Ellison MC, Lynch DA, Cool CD, Brown KK, Routes JM. Granulomatous-lymphocytic lung disease shortens survival in common variable immunodeficiency. J Allergy Clin Immunol 2004 Aug;114\(2\):415-421.](#)

[\(10\) Gamez-Diaz L, August D, Stepensky P, Revel-Vilk S, Seidel MG, Noriko M, et al. The extended phenotype of LPS-responsive beige-like anchor protein \(LRBA\) deficiency. J Allergy Clin Immunol 2016 Jan;137\(1\):223-230.](#)

[\(11\) Schubert D, Bode C, Kenefeck R, Hou TZ, Wing JB, Kennedy A, et al. Autosomal dominant immune dysregulation syndrome in humans with CTLA4 mutations. Nat Med 2014 Dec;20\(12\):1410-1416.](#)

[\(12\) Schuetz C, Huck K, Gudowius S, Megahed M, Feyen O, Hubner B, et al. An immunodeficiency disease with RAG mutations and granulomas. N Engl J Med 2008 May 8;358\(19\):2030-2038.](#)

[\(13\) De Dios JA, Javaid AA, Ballesteros E, Metersky ML. An 18-year-old woman with Kabuki syndrome, immunoglobulin deficiency and granulomatous lymphocytic interstitial lung disease. Conn Med 2012 Jan;76\(1\):15-18.](#)

[\(14\) Chase NM, Verbsky JW, Hintermeyer MK, Waukau JK, Tomita-Mitchell A, Casper JT, et al. Use of combination chemotherapy for treatment of granulomatous and lymphocytic interstitial lung disease \(GLILD\) in patients with common variable immunodeficiency \(CVID\). J Clin Immunol 2013 Jan;33\(1\):30-39.](#)

[\(15\) Ammann S, Elling R, Gyrd-Hansen M, Duckers G, Bredius R, Burns SO, et al. A new functional assay for the diagnosis of X-linked inhibitor of apoptosis \(XIAP\) deficiency. Clin Exp Immunol 2014 Jun;176\(3\):394-400.](#)

[\(16\) Bryceson YT, Pende D, Maul-Pavicic A, Gilmour KC, Ufheil H, Vraetz T, et al. A prospective evaluation of degranulation assays in the rapid diagnosis of familial hemophagocytic syndromes. Blood 2012 Mar 22;119\(12\):2754-2763.](#)

[\(17\) Teachey DT. New advances in the diagnosis and treatment of autoimmune lymphoproliferative syndrome. Curr Opin Pediatr 2012 Feb;24\(1\):1-8.](#)

[\(18\) Speckmann C, Lehmborg K, Albert MH, Damgaard RB, Fritsch M, Gyrd-Hansen M, et al. X-linked inhibitor of apoptosis \(XIAP\) deficiency: the spectrum of presenting manifestations beyond hemophagocytic lymphohistiocytosis. Clin Immunol 2013 Oct;149\(1\):133-141.](#)

[\(19\) Hugot JP, Chamaillard M, Zouali H, Lesage S, Cezard JP, Belaiche J, et al. Association of NOD2 leucine-rich repeat variants with susceptibility to Crohn's disease. Nature 2001 May 31;411\(6837\):599-603.](#)

[\(20\) Strober W, Asano N, Fuss I, Kitani A, Watanabe T. Cellular and molecular mechanisms underlying NOD2 risk-associated polymorphisms in Crohn's disease. Immunol Rev 2014 Jul;260\(1\):249-260.](#)





