

# **Disseminated adenovirus infection after allogeneic stem cell transplant and the potential role of brincidofovir – case series and 10 year experience of management in an adult transplant cohort**

**Isobel D Ramsay<sup>a</sup>, Charlotte Attwood<sup>b</sup>, Dianne Irish<sup>a</sup>, Paul D Griffiths<sup>a,c</sup>, Charalampia Kyriakou<sup>b\*</sup>, David M Lowe<sup>c,d\*</sup>**

**a. Department of Virology, Royal Free Hospital London, UK**

**b. Department of Haematology Royal Free Hospital London, UK**

**c. Institute of Immunity and Transplantation, Royal Free Campus, University College London, UK**

**d. Department of Immunology, Royal Free Hospital London, UK**

\* These authors contributed equally

## **Corresponding Author**

Dr David Lowe

Institute of Immunity and Transplantation

University College London

Royal Free Campus

Pond Street, London, NW3 2QG, UK

**Email:** [d.lowe@ucl.ac.uk](mailto:d.lowe@ucl.ac.uk)

**Tel:** 00 44 (0) 20 7794 0500

## **Word Counts:**

Manuscript 2896

Abstract 238

**Disseminated adenovirus infection after allogeneic stem cell transplant  
and the potential role of brincidofovir – case series and 10 year  
experience of management in an adult transplant cohort**

**Isobel D Ramsay <sup>a</sup>, Charlotte Attwood<sup>b</sup>, Dianne Irish<sup>a</sup>, Paul D Griffiths<sup>a,c</sup>,  
Charalampia Kyriakou<sup>b</sup>, David M Lowe<sup>c,d</sup>**

**(see separate title page for details)**

## **ABSTRACT**

### **Background**

Adenovirus infection is a recognized complication following haematopoietic stem cell transplantation. We present a review of our experience of these infections in our transplant cohort over 10 years including 3 patients treated with the novel antiviral brincidofovir.

### **Objectives**

We aimed to describe the presentation, response to treatment and outcomes of adult stem cell transplant patients with disseminated adenovirus infection.

### **Study design**

All adult cases of disseminated adenovirus infection following haematopoietic stem cell transplant in our unit between 2005 and 2015 were identified.

Transplant details and data on timing of diagnosis, course of infection, viral co-infection and treatment were collected.

### **Results**

Of 733 patients transplanted, 10 patients had disseminated infection, including 4 male and 6 female patients with median age of 36.5 (range 19 – 59) years. 6/10 received an allograft from an unrelated donor. Median post-transplant time to detection of viraemia was 67 days (range 20-1140 days). Median peak viral load was 3133 copies/ml (352-11,000,000) in survivors and 1,580,000 copies/ml (41,999-3,000,000) in those who died.

Five patients received cidofovir alone, one cidofovir then brincidofovir and two brincidofovir alone. 8/10 patients had a decrease in viral load following antivirals and/or reduction in immunosuppression including all on brincidofovir. Three died on treatment.

## **Conclusions**

Disseminated adenovirus infection is uncommon in adult transplant patients and uncertainties remain surrounding effective treatment. In our cohort, brincidofovir has shown promise in treatment of adenoviral infection. However, randomized controlled studies are required to confirm this impression.

## **Background**

Adenovirus infection is a recognized cause of morbidity and mortality following haematopoietic stem cell transplantation (HSCT) occurring in 5% to 47% of recipients.[1-7]

Infection is often asymptomatic but may result in end-organ disease including colitis, pneumonitis, hepatitis, nephritis, haemorrhagic cystitis, conjunctivitis, encephalitis or multi-site disease following viraemic spread.[8] More commonly seen in the paediatric population [9], disseminated disease may occur in adult transplant recipients and carries a high mortality of up to 26% [10]. Reported risk factors include T cell depleting conditioning regimes [11], acute graft versus host disease (GVHD) [9], unrelated donor allograft [3] and use of alemtuzumab or antithymocyte globulin (ATG) [12].

Diagnosis of disease is typically made by combining clinical features with detection of viral DNA using polymerase chain reaction (PCR) or identification of viral inclusions on histopathology. Virus detection does not in itself prove significant end-organ disease, but detection at more than one site and increasing viral load, especially in blood, is taken to indicate a high risk. Management in these circumstances is orientated towards reducing viraemia. Interventions include reducing immunosuppression and consideration of antivirals; because no antiviral drugs are currently licensed for the treatment of adenoviral disease, such treatments are necessarily investigational. Adoptive T cell immunotherapy holds promise as a treatment [13] although its widespread use is limited by the time-intensive nature of generating virus specific T cells [14]. Intravenous immunoglobulin (IVIG) has also been used in

limited cases.[15, 16]

The published information on antiviral medications for adenovirus disease, including cidofovir and ribavirin, is limited at present to case series and small non-randomized studies.[17] Cidofovir is an acyclic phosphonate nucleotide analogue whose diphosphate is an inhibitor of the viral DNA polymerase and reduces adenovirus replication in vitro.[18] Its use is limited by side effects including significant nephrotoxicity [19] which can be reduced by pre-hydration and probenecid to decrease tubular secretion of the drug. This introduces a significant management problem in patients undergoing HSCT who often receive nephrotoxic medication for GVHD prophylaxis and antimicrobial, antifungal and antiviral agents.

Brincidofovir (CMX 001, Chimerix Inc, Durham, North Carolina, USA) is an unlicensed orally bioavailable lipid conjugate of cidofovir which demonstrates greater intracellular uptake than cidofovir with a lower propensity for renal accumulation [20, 21]. Brincidofovir has activity against adenovirus in immunosuppressed animal models [22] and is currently under investigation for adenovirus infection in Phase III trials (ClinicalTrials.gov Identifier: NCT02087306).

Here we report 3 cases of disseminated adenovirus infection treated with brincidofovir and relate these to our experience of treating disseminated adenovirus infections in our transplant cohort over 10 years.

### **Retrospective review of transplant cohort**

All adult cases of adenovirus infection following haematopoietic stem cell

transplant managed by our unit between January 2005 and February 2015 were retrospectively identified by searching the virology department database. The screening strategy for adenoviral infection changed over the 10 year period. In the year 2005-06, our laboratory carried out a pilot of routine screening: blood adenovirus PCR was sent in alternate weeks post transplant. However, there were no cases of disseminated infection detected in this time and on this basis, it was decided to move away from routine screening. From that point on, blood samples for adenoviral PCR have been sent in patients with clinical suspicion for infection only. CMV and EBV are routinely screened for by PCR in blood weekly (EBV) or twice weekly (CMV) for the first 90 days post transplant, allowing pre-emptive therapy of CMV viraemia. We extracted basic patient, disease and transplant data (age, sex, transplant type, conditioning, site of sample(s)) on all patients with a positive PCR for adenovirus in any clinical sample, and more extensive data (post-transplant immunosuppression, time of diagnosis in relation to transplant, course of infection, adenovirus treatment and clinical outcome) on patients with disseminated infection, defined as detection of adenovirus from 2 or more sites in the presence of viraemia with compatible symptoms.[23] Relevant clinical data were collected from case notes.

## **Results**

### **Patient characteristics**

Over the past 10 years, our unit has carried out 733 HSCTs of which 152 underwent allogeneic myeloablative (MAC), 277 reduced intensity conditioning (RIC) and 312 received autologous haemopoietic stem cell transplantation (ASCT). Of these 44 had adenovirus DNA detected at one or more sites by PCR. These included 20 females and 24 males with a median age at transplantation of 40 (Range 17-66). Three received autologous stem cell transplantation. Of those receiving allografts, 9 patients were treated with MAC (sibling donor n=5) and 32 with RIC Allo SCT (sibling donor n=18).

### **Site of infection**

The sites most commonly infected were gastrointestinal (GI) tract (n=25), respiratory tract (n=21) and urinary tract (n=6). In addition 1 patient had adenovirus detected in CSF and 3 on eye swabs.

Forty-three of the 44 patients who had adenoviral DNA detected at one organ site also had their blood tested by adenovirus PCR to look for disseminated infection. Seventeen patients had viraemia with a median peak viral load of 3344 (352-11,000,000). Ten patients (23%) including cases 1-3 (detailed below) met criteria for disseminated infection.

### **Characteristics of patients with disseminated infection**

The characteristics of the 10 patients with disseminated infection are summarized in Table 1. They included 4 male and 6 female patients with a median age of 36.5 (range 19 – 59) years, with 8/10 receiving T cell depleted grafts. Median post-transplant time to detection of viraemia was 65 days (range 20-1,140 days). The median peak viral load was 3,133 copies/ml (352-



11,000,000) in those who survived and 165,415 copies/ml (41,999-3,000,000) in those who did not. Median duration of viraemia was 14 days (range 7-67) in survivors and 21 days (range 2-103) in those who died. As shown in Table 1, co-infection with other viruses during the hospital admission was common.

### **Treatment and outcomes**

Five patients received IV cidofovir alone, one cidofovir then brincidofovir (Case 1 described below) and two brincidofovir alone (Cases 2 and 3). Cidofovir doses ranged from 1.5-2mg/kg 3 times a week and brincidofovir doses from 50-100mg twice weekly. Total duration of antiviral treatment ranged from 2 to 63 days. Among patients given cidofovir, treatment was discontinued in two cases due to nephrotoxicity, in one case was changed to brincidofovir due to lack of efficacy (Case 1), and two patients died with ongoing viraemia.

Information on immunosuppression was available for 9 patients and 6 of these had their immunosuppression reduced. Two patients with disseminated infection only had their immunosuppression reduced and did not receive antivirals. Only two patients received IVIG as part of their treatment. Seven patients became aviraemic (median reduction in viral load of 1.20 log (0.25-4.74log)) and one had a 1.19 log decrease in viral load (case 2). Three died while on treatment (a mortality rate of 30% in those with disseminated infection), although adenovirus disease was only thought to be the primary cause of death in 1 patient (case 4). All those who died had an absolute lymphocyte count of less than  $0.25 \times 10^9/L$  at the point of diagnosis.

## Case reports

**Cases 1-3 from Table 1 who received brincidofovir as part of their treatment are described in detail below.**

### Case 1

A 59 year old woman underwent a fludarabine, melphalan, alemtuzumab matched unrelated donor peripheral haematopoietic stem cell transplant (MUD Allo SCT) for treatment of acute myeloid leukaemia in second remission. Cyclosporin A and mycophenolate mofetil were given for GVHD prophylaxis. On day ten following transplantation, the patient developed severe diarrhoea (6-8 litres daily). Bacterial stool culture and *C.difficile* toxin tests were negative. Her neutrophil count was  $0.81 \times 10^9/L$ . Examination of stool and blood samples by PCR on day 20 post-transplant (in-house assay adapted from Heim et al [24]) detected adenovirus. Quantitative PCR showed 8872 copies/ml of whole blood. Flexible sigmoidoscopy revealed patchy colitis with chronic damage and regeneration without features diagnostic of current acute GVHD on histology.

PCR on the colonic biopsy detected adenovirus. On day 22 post-transplant, treatment with intravenous (IV) cidofovir 1.5mg/kg three times weekly with probenecid was commenced. Despite this, her condition continued to deteriorate with ongoing diarrhoea and no sustained improvement in her viral load (Fig. 1).

She developed a worsening cough and shortness of breath with increasing oxygen requirement. Adenovirus, respiratory syncytial virus (RSV) and influenza A were detected by PCR from nasopharyngeal samples. High

resolution computed tomography of the chest showed ground glass and bronchiolitic changes suggestive of viral infection. She received a ten day course of oseltamivir then IV zanamivir for ten days, after which influenza cleared from her nasopharynx.

After 17 days of cidofovir, her respiratory and gastrointestinal symptoms worsened, requiring intensive care admission and ventilatory support. The immunosuppression was rapidly reduced and discontinued in the absence of any evidence of GVHD. Intravenous immunoglobulin infusion (IVIg) was administered twice weekly at a dose of 400mg/kg for 6 weeks.

Following approval for its use on a compassionate basis, brincidofovir was commenced at 100mg twice weekly (at day 44 post transplant). After two doses her viral load in blood had dropped by 2 log<sub>10</sub> copies/ml and her respiratory symptoms were improving. However, the diarrhoea persisted for a further 2 weeks. The dose of brincidofovir was reduced to 50mg twice weekly on the grounds that it might be contributing to the diarrhea. However her viral load remained static and given the lack of improvement in her diarrhoeal symptoms, the dose was again increased to 100mg twice weekly. A repeat colonic biopsy at 60 days post-transplant showed epithelial cell apoptosis, a finding which has been documented in both GVHD and adenoviral infection. Adenovirus PCR of this sample was positive. As the viral load continued to decrease in her blood, the brincidofovir dose was again reduced to 50mg twice weekly and her diarrhoea began to settle. After 41 days of brincidofovir treatment, adenovirus became undetectable in blood (<200 copies/ml) and on nasopharyngeal swab. Of note, she did not develop renal impairment at any stage.

## **Case 2**

A 54 year old woman received sibling allograft with fludarabine and melphalan conditioning for treatment of relapsed IgA myeloma. By day 29 post-transplant, she had developed diarrhea; adenoviral PCR in blood and stool was negative. Her liver function tests became deranged and she developed mucositis, felt to be consistent with acute GVHD. She was commenced on treatment with methylprednisolone and subsequently with mycophenolate mofetil (MMF) and infliximab. She developed progressive shortness of breath and cough and was found to have a positive adenovirus PCR on a nasopharyngeal sample collected on day 50 post-transplant. She was also viraemic at this point at 4,782 copies/ml rising to a peak of 3,000,000 copies/ml. Adenovirus was also detected in stool. Her steroid dose was reduced and brincidofovir 100mg twice weekly was started at day 52 post transplant with a virological response noted after 8 days of treatment (viral load decreased to 196,201 copies/ml). The contribution of adenovirus to her symptoms is unclear and no symptomatic improvement was seen despite antivirals and GVHD treatment. She continued to deteriorate and died at day 71 post transplantation. Her primary cause of death was felt to be GVHD.

## **Case 3**

A 34-year-old male received a one antigen mismatched unrelated T-deplete allograft with fludarabine, cyclophosphamide, total body irradiation conditioning for the treatment of pre B acute lymphoblastic leukemia in third complete remission. He developed ciclosporin toxicity with abnormal renal function (corrected glomerular filtration rate (GFR) 45ml/min) and the

immunosuppression was changed to mycophenolate mofetil and tacrolimus. He also received a 6 week course of steroids commenced on day 14 post transplant for presumed acute GVHD (aGVHD). Routine blood PCR for CMV monitoring showed CMV reactivation on day 14 post-transplant and he was commenced on treatment with foscarnet and subsequently ganciclovir with no adequate response. He developed severe diarrhoea, fever and hepatitis. aGVHD and other infective causes were excluded. A colonic biopsy on day 17 post-transplant did not show evidence of aGVHD or adenoviral infection. Adenovirus was initially detected in blood at day 21 post transplant (6,100 copies/ml) and in stool at day 35. PCR for adenovirus subsequently became strongly positive on blood (peaking at >240000 copies/ml (see Fig 2). In addition he developed a haemorrhagic cystitis requiring bladder irrigation. Urinary PCR was positive for both adenovirus and BK virus. As his renal function was already abnormal (creatinine clearance 45ml/min), the immunosuppression was reduced and he received treatment on compassionate basis with brincidofovir 100mg twice weekly (started at day 36 post transplant). His symptoms gradually improved and PCR became negative in blood and stool 61 days following treatment initiation (see Fig 2). Of note the patient also had negative PCR for CMV following 5 weeks treatment with brincidofovir.

## **Discussion**

Viral infections can be life-threatening following allogeneic stem cell transplantation and present major management challenges. Although there have been improvements allowing early identification of adenovirus infection,

the optimal management strategy, including antiviral use, remains poorly defined.

There are several reports of the use of brincidofovir for treatment of adenoviral infection in humans including a recent randomized controlled phase II trial. The cases and studies reported in the literature are summarised in Table 2 [20,25-31].

The majority were allogeneic HSCT recipients (both adult and paediatric cases) and many had failed therapy with IV cidofovir prior to initiation of brincidofovir treatment. The dosage varied between 1mg/kg per week and 3mg/kg twice weekly. In this small selection of cases, virological response was often seen in those with viraemia alone, but the response was more variable in those with disseminated disease. Recent publications [29,31] have suggested a potential role for pre-emptive therapy of asymptomatic adenoviraemia to prevent progression to disseminated adenoviral disease in both paediatric and adult transplant populations.

We have here reviewed 10 years of data from adult transplant patients to identify the incidence of adenoviral infection and disease. Amongst our cohort, the incidence of adenoviral infection was 5.9% but disseminated infection was rare – seen in 1.24% total transplants. This is comparable to previous data showing an incidence of 3% with attributable mortality for all adenoviral infections of 26%[1]. Known risk factors for infection were reflected in these 10 patients with disseminated infection, the majority of whom received unrelated donor allografts and conditioning with alemtuzumab or ATG.

Viraemia was seen in 16/44 patients of whom 6 did not develop disseminated infection. In our cohort therefore 62.5% of our viraemic patients had disseminated infection of whom 3 died (a mortality rate of 30%). Other small studies have found a higher incidence of viraemia without disseminated disease in adults.[32,33] This may reflect that our patients were often tested only after detection of virus at another site rather than for routine surveillance.

Of our patients with disseminated infection, 8 were treated with antivirals with 5 surviving. For those on cidofovir, 1/6 was changed to brincidofovir due to lack of efficacy, 2/6 died with viraemia and 2/6 experienced nephrotoxic side effects requiring discontinuation of therapy. Probenecid was used in some cases with no subsequent nephrotoxicity (although these numbers are small). Overall, some virological response occurred in all our patients on brincidofovir and in 3/6 on cidofovir.

Due perhaps in part to the difficulties in diagnosing adenoviral end-organ disease in the context of GVHD and other intercurrent infection, side effects and concerns about efficacy, antivirals were not consistently started when adenovirus was initially detected.

The clinical picture in this cohort was often complicated by acute and chronic GVHD and it is interesting to note that those without documented intercurrent GVHD survived the infection. In contrast, all of those who died had active GVHD and 2/3 were treated with multiple immunosuppressive agents. Case 1 described above appears unusual, with survival despite a very high peak viral load. In other characteristics those who died and those who survived appeared generally similar.

The majority (9/10) of these patients had other concomitant viral infection including CMV reactivation. We note that 3/4 of those without CMV reactivation survived.

As demonstrated by our cases, differentiating between adenoviral disease and other potential aetiologies for symptoms in this setting can be challenging. Cases 1 and 3 initially presented with diarrhoea, non-diagnostic histology on colonic biopsy and features seen that could have represented either early GVHD or adenoviral infection. This produced a treatment dilemma, because immunosuppression for GVHD would be expected to worsen adenovirus disease. Case 2 had more definite signs of acute GVHD but continuing symptoms despite multiple treatments and the contribution of adenoviral infection to her clinical picture was unclear.

Diarrhoea is also a dose limiting side effect of brincidofovir.[34] As an experimental drug, data on the trajectory of side effects is limited. This introduced further complexity in case 1 when the symptoms of potential drug toxicity and the clinical picture overlapped and changed with time, for example the risk of GVHD increased later in her clinical course because she had engrafted and immunosuppression had been reduced in view of adenovirus infection. Indeed, these patients may experience more than one condition either simultaneously or sequentially.

## **Conclusion**

In summary, disseminated adenovirus infection is uncommon in adult



transplant recipients but can prove fatal. There remain significant uncertainties surrounding treatment. In our most recent cases, brincidofovir has shown promise in treatment of adenoviral disease without the nephrotoxicity seen with cidofovir and may have a role in preemptive therapy. Due to our screening strategy, we cannot comment on the prevalence of asymptomatic viraemia in our cohort. However given that our disseminated disease cohort reflected known risk factors for adenoviral infection, it may be possible to consider a strategy which screens the most high risk patients and considers pre-emptive therapy. Randomized controlled studies are required to confirm this impression.

## **Acknowledgements**

Our thanks to Allison Morgan and Juan Esquivel from Chimerix for providing brincidofovir and to Professor Stephen Mackinnon for his help with earlier version of this manuscript.

## References

1. La Rosa AM, Champlin RE, Mirza N, Gajewski J, Giralt S, Rolston KV et al. Adenovirus infections in adult recipients of blood and marrow transplants. *Clinical infectious diseases : an official publication of the Infectious Diseases Society of America* **2001**; 32(6): 871-6.
2. Howard DS, Phillips IG, Reece DE, Munn RK, Henslee-Downey I, Pittard M et al. Adenovirus infections in hematopoietic stem cell transplant recipients. *Clinical infectious diseases : an official publication of the Infectious Diseases Society of America* **1999**; 29(6): 1494-501.
3. Baldwin A, Kingman H, Darville M, Foot AB, Grier D, Cornish JM et al. Outcome and clinical course of 100 patients with adenovirus infection following bone marrow transplantation. *Bone marrow transplantation* **2000**; 26(12): 1333-8.
4. Runde V, Ross S, Trensche R, Lagemann E, Basu O, Renzing-Kohler K et al. Adenoviral infection after allogeneic stem cell transplantation (SCT): report on 130 patients from a single SCT unit involved in a prospective multi center surveillance study. *Bone marrow transplantation* **2001**; 28(1): 51-7.
5. Robin M, Marque-Juillet S, Scieux C, Peffault de Latour R, Ferry C, Rocha V et al. Disseminated adenovirus infections after allogeneic hematopoietic stem cell transplantation: incidence, risk factors and outcome. *Haematologica* **2007**; 92(9): 1254-7.
6. Symeonidis N, Jakubowski A, Pierre-Louis S, Jaffe D, Pamer E, Sepkowitz K et al. Invasive adenoviral infections in T-cell-depleted allogeneic hematopoietic stem cell transplantation: high mortality in the era of cidofovir. *Transplant infectious disease : an official journal of the Transplantation Society* **2007**; 9(2): 108-13.
7. Chakrabarti S, Mautner V, Osman H, Collingham KE, Fegan CD, Klapper PE et al. Adenovirus infections following allogeneic stem cell transplantation: incidence and outcome in relation to graft manipulation, immunosuppression, and immune recovery. *Blood* **2002**; 100(5): 1619-27.
8. Carrigan DR. Adenovirus infections in immunocompromised patients. *The American journal of medicine* **1997**; 102(3A): 71-4.
9. Flomenberg P, Babbitt J, Drobyski WR, Ash RC, Carrigan DR, Sedmak GV et al. Increasing incidence of adenovirus disease in bone marrow transplant recipients. *The Journal of infectious diseases* **1994**; 169(4): 775-81.
10. Lindemans CA, Leen AM, Boelens JJ. How I treat adenovirus in hematopoietic stem cell transplant recipients. *Blood* **2010**; 116(25): 5476-85.
11. Lee YJ, Chung D, Xiao K, Papadopoulos EB, Barker JN, Small TN et al. Adenovirus viremia and disease: comparison of T cell-depleted and conventional hematopoietic stem cell transplantation recipients from a single institution. *Biology of blood and marrow transplantation : journal of the American Society for Blood and Marrow Transplantation* **2013**; 19(3): 387-92.
12. Myers GD, Krance RA, Weiss H, Kuehnle I, Demmler G, Heslop HE et al. Adenovirus infection rates in pediatric recipients of alternate donor

- allogeneic bone marrow transplants receiving either antithymocyte globulin (ATG) or alemtuzumab (Campath). Bone marrow transplantation **2005**; 36(11): 1001-8.
13. Geyeregger R, Freimuller C, Stemberger J, Artwohl M, Witt V, Lion T et al. First-in-man clinical results with good manufacturing practice (GMP)-compliant polypeptide-expanded adenovirus-specific T cells after haploidentical hematopoietic stem cell transplantation. *Journal of immunotherapy* **2014**; 37(4): 245-9.
  14. Sili U, Leen AM, Vera JF, Gee AP, Huls H, Heslop HE et al. Production of good manufacturing practice-grade cytotoxic T lymphocytes specific for Epstein-Barr virus, cytomegalovirus and adenovirus to prevent or treat viral infections post-allogeneic hematopoietic stem cell transplant. *Cytotherapy* **2012**; 14(1): 7-11.
  15. Kerensky T, Hasan A, Schain D, Trikha G, Liu C, Rand K et al. Histopathologic resolution of adult liver transplantation adenovirus hepatitis with cidofovir and intravenous immunoglobulin: a case report. *Transplantation proceedings* **2013**; 45(1): 293-6.
  16. Emovon OE, Lin A, Howell DN, Afzal F, Baillie M, Rogers J et al. Refractory adenovirus infection after simultaneous kidney-pancreas transplantation: successful treatment with intravenous ribavirin and pooled human intravenous immunoglobulin. *Nephrology, dialysis, transplantation : official publication of the European Dialysis and Transplant Association - European Renal Association* **2003**; 18(11): 2436-8.
  17. Ljungman P, Ribaud P, Eyrich M, Matthes-Martin S, Einsele H, Bleakley M et al. Cidofovir for adenovirus infections after allogeneic hematopoietic stem cell transplantation: a survey by the Infectious Diseases Working Party of the European Group for Blood and Marrow Transplantation. *Bone marrow transplantation* **2003**; 31(6): 481-6.
  18. de Oliveira CB, Stevenson D, LaBree L, McDonnell PJ, Trousdale MD. Evaluation of Cidofovir (HPMPC, GS-504) against adenovirus type 5 infection in vitro and in a New Zealand rabbit ocular model. *Antiviral research* **1996**; 31(3): 165-72.
  19. Izzedine H, Launay-Vacher V, Deray G. Antiviral drug-induced nephrotoxicity. *American journal of kidney diseases : the official journal of the National Kidney Foundation* **2005**; 45(5): 804-17.
  20. Florescu DF, Pergam SA, Neely MN, Qiu F, Johnston C, Way S et al. Safety and efficacy of CMX001 as salvage therapy for severe adenovirus infections in immunocompromised patients. *Biology of blood and marrow transplantation : journal of the American Society for Blood and Marrow Transplantation* **2012**; 18(5): 731-8.
  21. Ciesla SL, Trahan J, Wan WB, Beadle JR, Aldern KA, Painter GR et al. Esterification of cidofovir with alkoxyalkanols increases oral bioavailability and diminishes drug accumulation in kidney. *Antiviral research* **2003**; 59(3): 163-71.
  22. Toth K, Spencer JF, Dhar D, Sagartz JE, Buller RM, Painter GR et al. Hexadecyloxypropyl-cidofovir, CMX001, prevents adenovirus-induced mortality in a permissive, immunosuppressed animal model. *Proceedings of the National Academy of Sciences of the United States of America* **2008**; 105(20): 7293-7.

23. Legrand F, Berrebi D, Houhou N, Freymuth F, Faye A, Duval M et al. Early diagnosis of adenovirus infection and treatment with cidofovir after bone marrow transplantation in children. *Bone marrow transplantation* **2001**; 27(6): 621-6
24. Heim A, Ebnet C, Harste G, Pring-Akerblom P. Rapid and quantitative detection of human adenovirus DNA by real-time PCR. *Journal of medical virology* 2003; 70(2): 228-39.
25. Paolino K, Sande J, Perez E, Loechelt B, Jantusch B, Painter W et al. Eradication of disseminated adenovirus infection in a pediatric hematopoietic stem cell transplantation recipient using the novel antiviral agent CMX001. *Journal of Clinical Virology* **2011**; 50: 167–70
26. Awosika OO, Lyons JL, Ciarlina P, Phillips RE, Alfson ED, Johnson EL et al. Fatal adenovirus encephalomyelorradiculitis in an umbilical cord stem cell transplant recipient. *Neurology* **2013**; 80: 1715–7
27. Keyes A, Mathias M, Boulad F, Lee YJ, Marchetti MA, Scaradavou A et al. Cutaneous involvement of disseminated adenovirus infection in an allogeneic stem cell transplant recipient. *British Journal of Dermatology* **2016**; 174: 885–888
28. Voigt S, Hofmann J, Edelmann A, Sauerbrei A, Kühl JS. Brincidofovir clearance of acyclovir-resistant herpes simplex virus-1 and adenovirus infection after stem cell transplantation. *Transpl Infect Dis* 2016; 18: 791–794
29. Hiwarkar P, Amrolia P, Sivaprakasam P, Lum SH, Doss H, O’Rafferty C et al. Brincidofovir is highly efficacious in controlling adenoviremia in pediatric recipients of hematopoietic cell transplant. *Blood* 2017; 44: blood-2016-11-749721.
30. Lee YJ, Huang YT, Kim SJ, Maloy M, Tamari R, Giralt SA et al. Adenovirus Viremia in Adult CD34(+) Selected Hematopoietic Cell Transplant Recipients: Low Incidence and High Clinical Impact. *Biology of Blood and Marrow Transplantation*. **2016** Jan;22(1):174-8.
31. Grimley MS, Chemaly RF, Englund JA, Kurtzberg J, Chittick G, Brundage TM et al. Brincidofovir for Asymptomatic Adenovirus Viremia in Pediatric and Adult Allogeneic Hematopoietic Cell Transplant Recipients: A Randomized Placebo-Controlled Phase II Trial. *Biology of Blood and Marrow Transplantation* **2017**; 23: 512–521
32. Kalpoe JS, van der Heiden PL, Barge RM, Houtzager S, Lankester AC, van Tol MJ et al. Assessment of disseminated adenovirus infections using quantitative plasma PCR in adult allogeneic stem cell transplant recipients receiving reduced intensity or myeloablative conditioning. *European journal of haematology* **2007**; 78(4): 314-21.
33. Sive JI, Thomson KJ, Morris EC, Ward KN, Peggs KS. Adenoviremia has limited clinical impact in the majority of patients following alemtuzumab-based allogeneic stem cell transplantation in adults. *Clinical infectious diseases : an official publication of the Infectious Diseases Society of America* **2012**; 55(10): 1362-70.
34. Marty FM, Winston DJ, Rowley SD, Boeckh M, Vance E, Papanicolaou G et al. CMX001 to prevent cytomegalovirus disease in hematopoietic-cell transplantation. *The New England journal of medicine* **2013**; 369(13): 1227-36.

### **Figure Legends**

**Figure 1.** Course of adenovirus viral load (black line) in blood in Case 1 according to days post-transplant and indicating treatment courses with cidofovir 1mg/kg 3 times weekly (red bar), brincidofovir 100mg twice weekly (thick green bar), brincidofovir 50mg twice weekly (thin green bar) and IVIG 0.4mg/kg (blue bar).

### **Figure 2.**

Course of adenovirus viral load (black line) in Case 3 according to days post-transplant, indicating treatment course with brincidofovir (green bar)

**Table 1.** Details of patients within our cohort of HSCT recipients with disseminated adenoviral infection

Case No.	Sex	Age	Underlying disease	Transplant type	Conditioning	T cell depletion?	Other viruses detected in same admission	GVHD at time of adenoviral infection?	Viraemia first detected (days post transplant)	Peak viral load (copies/ml)	Time from first positive to first negative blood PCR or death (days)	Sites detected	Antiviral treatment	Dose and duration	IVIg	IS at time of adenoviral infection	IS reduced	ALC ( x 10 <sup>9</sup> /L)	Outcome
1	F	59	AML	MUD allo	RIC	Yes, alemtuzumab	Influenza A, RSV	None	22	11,000,000	53	Lung, GI	1. Cidofovir 2. Brincidofovir	1. 1.5 mg/kg 3 times weekly for 7 doses (with probenecid) 2. 50-100mg twice weekly for 7 doses.	Yes	Ciclosporin	Yes	0.22	Aviraemic, survived
2	F	57	Multiple myeloma	Sib allo	RIC	No	EBV, CMV	Acute	51	3,000,000	21	GI, lung	Brincidofovir	100mg twice weekly for 5 doses.	No	Methyl-prednisolone, Infliximab, MMF	No	0.07	Died with viraemia
3	M	34	ALL	Mismatched UD allo (1 antigen mismatch)	Fludarabine, cyclophosphamide, TBI	Yes, alemtuzumab	CMV, BK	Acute	21	240,000	67	GI, hepatic, urine	Brincidofovir	100mg twice weekly for 18 doses	No	Methyl-prednisolone, MMF, Tacrolimus	Yes	0.18	Aviraemic, survived
4	F	48	Secondary AML	Mismatched UD allo (1 antigen mismatch)	RIC	Yes, alemtuzumab	CMV, HHV6	Chronic	335	41,993	2	Lung, eye	Cidofovir	Dose unknown. On treatment for 2 days until death	Yes	Ciclosporin	Unknown	0.20	Died with viraemia
5	F	44	AML	MUD allo	RIC	Yes ATG	CMV, EBV	Chronic	135	352	7	Lung, GI, urinary	Cidofovir	1.5mg/kg 3 times weekly stopped due to nephrotoxicity	No	Prednisolone	Yes	0.70	Aviraemic survived
6	M	22	ALL	Sib allo	MAC	No	None	Chronic	1140	972	8	Lung, eye, GI	None	-	No	Ciclosporin	No	2.05	Aviraemic, survived
7	M	39	Follicular lymphoma	MUD allo	RIC	Yes, alemtuzumab	HSV-1, PIV-3	Chronic	237	165,415	32	Lung, GI, urinary	Cidofovir	1.5mg/kg 3 times weekly for 9 doses (with probenecid) until death	No	Ciclosporin, MMF, Methyl-prednisolone	Yes	0.23	Died with viraemia
8	F	30	Hodgkins lymphoma	MUD allo	RIC	Yes, alemtuzumab	CMV	Acute	20	3,133	14	Lung GI, tract	None	-	No	Ciclosporin	Yes	0.05	Aviraemic, survived
9	M	28	Aplastic anaemia	Sib allo	RIC	Yes ATG	EBV	None	67	1,593	7	GI, urinary	Cidofovir	2mg/kg 3 times weekly for 4 doses (with probenecid)	No	Ciclosporin	No	1.71	Aviraemic, survived
10	F	19	AML	Sib allo	MAC	Yes, alemtuzumab	HHV6	None	63	15,772	28	GI, Urinary	Cidofovir	1.5mg/kg alternate days for 7 doses. Stopped due to nephrotoxicity	No	Ciclosporin	Yes	0.18	Aviraemic, survived

**Abbreviations:** **ALC**, absolute lymphocyte count. **ALL**, acute lymphoblastic leukaemia. **AML**, acute myeloid leukaemia. **ATG** anti-thymocyte globulin. **CMV**, cytomegalovirus. **EBV**, Epstein-Barr virus. **GI**, gastrointestinal. **GVHD**, graft versus host disease. **HHV-6** Human herpes virus 6. **HSV-1**, herpes simplex virus type 1. **IS**, immunosuppression. **IVIG**, intravenous immunoglobulin. **kg**, kilogramme. **MAC**, myeloablative conditioning. **mg**, milligramme. **ml**, millilitre. **MMF**, mycophenolate mofetil. **MUD allo**, matched unrelated donor allograft. **PIV-3**, Parainfluenza virus type 3. **PCR**, polymerase chain reaction. **RIC**, reduced intensity conditioning. **RSV**, respiratory syncytial virus. **Sib allo**, sibling donor allograft. **TBI**, total body irradiation.



**Table 2.** Summary of published cases of adenoviral infection treated using brincidofovir

Cases	Study/case type	Co-morbidities	Clinical features	Conditioning	Initial therapy	Duration and dose	Outcome	Reference
12 F allogeneic SCT	Case report	Aplastic anaemia, GVHD	Hepatitis	Fludarabine, melphalan, alemtuzumab	Cidofovir	2mg/kg twice weekly increasing to 3mg/kg At least 8 weeks.	Resolution of viraemia. Patient survived	Paolino <i>et al</i> (2011) [25]
58 F allogenic SCT	Case report	T cell prolymphocytic leukaemia	encephalomyelitis	Fludarabine, melphalan, anti-thymocyte globulin	Cidofovir	NR	Died	Awosika <i>et al</i> (2013)[26]
20s F allogeneic SCT	Case report	Aplastic anaemia, PTLD	Disseminated infection	NR	Cidofovir	2mg/kg for 2 weeks ( 5 doses)	Died	Keyes <i>et al</i> (2016)[27]
5 F allogeneic SCT	Case report	Myelodysplastic syndrome	Viraemia alone	NR	Cidofovir	NR	Resolution of viraemia.	Voigt <i>et al</i> (2016)[28]
13 patients (8 paediatric) SCID (1) Small bowel transplant (1) Allogeneic SCT (11)	Case series	NR	GI Symptoms (7) GU Symptoms (4) Respiratory Symptoms (3) CNS (1) Bone Marrow involvement (1) Disseminated (6)	NR	Cidofovir	1-3mg/kg weekly for up to 6 months	1 survived	Florescu <i>et al</i> (2012) [20]
Paediatric SCT	Retrospective observational study	NR specifically for the patients treated	Viraemia (47) Disseminated (5)	NR specifically for patients treated	Cidofovir then brincidofovir (12) Brincidofovir only (4)	2mg/kg twice weekly	13/16 patients became aviraemic	Hiwarkar <i>et al</i> (2017) [29]
Adult CD34+ selected SCT	Prospective observational study	NR specifically for the patients treated	Viraemia alone (6) Adenoviral disease (6)	myeloablative	Cidofovir only (5) Brincidofovir +/- cidofovir in (7)	NR	4/6 with viraemia alone became aviraemic. 5/6 with disease died with viraemia	Lee <i>et al</i> (2016)[30]
Adult and paediatric allogeneic SCT	Randomised, placebo controlled trial	NR	Viraemia alone	Myeloablative or RIC	Brincidofovir	Up to 100mg twice weekly for median 19 days OR Up to 200mg once weekly for median 32 days OR placebo	8/12 viraemia undetectable (twice weekly group) 4/14 viraemia undetectable (once weekly group)	Grimley <i>et al</i> (2017) [31]

**Abbreviations:** CD, cluster of differentiation. CNS, central nervous system. GI, gastrointestinal. GU, genito-urinary. GVHD, graft versus host disease. kg, kilogramme. mg, milligramme. NR, not reported. PTLD, post transplant lymphoproliferative disease. RIC, reduced intensity conditioning. SCID, severe combined immunodeficiency. SCT, stem cell transplant.

Figure 1

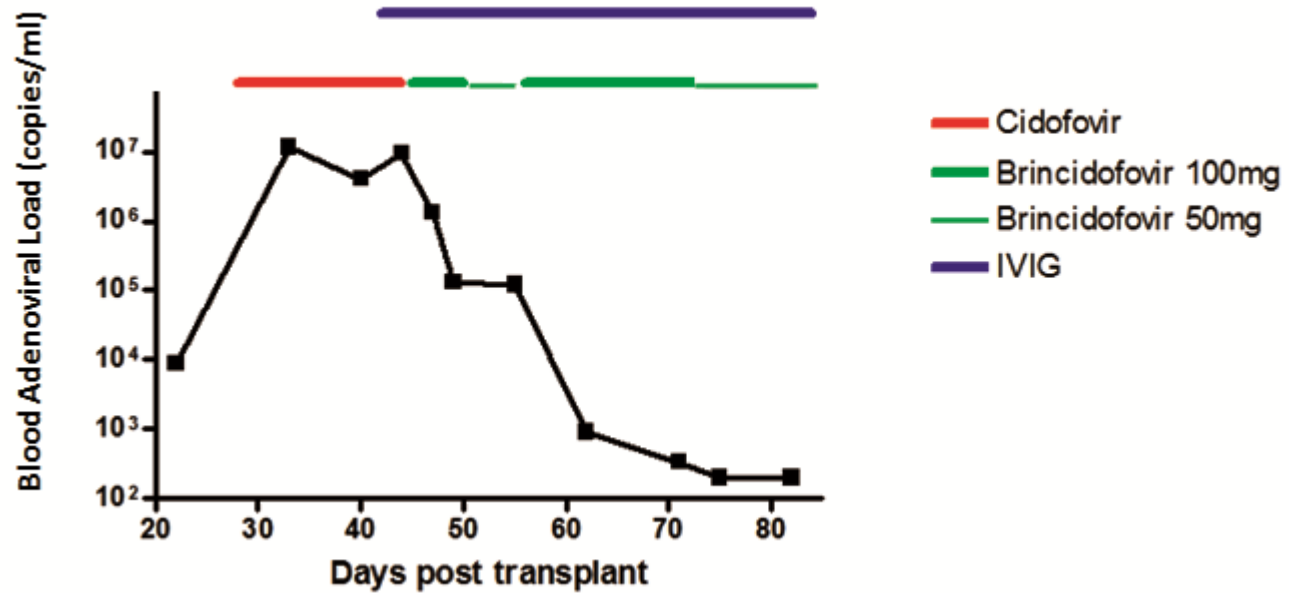


Figure 2

