

# Morning Glory Syndrome in Children

## Association With Endocrine and Central Nervous System Anomalies

H. Sprague Eustis, MD; Marc R. Sanders, MD; Teresa Zimmerman, MD

**Objective:** To identify morning glory syndrome, an uncommon optic disc anomaly. Generally, it is an isolated ocular abnormality; however, some cranial facial and neurologic associations have been reported.

**Patients:** We herein report two patients with morning glory syndrome and associated pituitary dwarfism. In one patient, the pituitary insufficiency was secondary to compression of the pituitary gland by a basal

encephalocele; in the second patient, causative factors were not identified.

**Conclusions:** Patients with morning glory syndrome should have a complete general physical examination and growth evaluation so that early recognition and treatment of the patient with pituitary dwarfism can occur.

(*Arch Ophthalmol.* 1994;112:204-207)

**E**ARLY DESCRIPTIONS of the uncommon optic disc anomaly now known as morning glory syndrome can be traced to reports by Reis<sup>1</sup> in 1908 and Handmann<sup>2</sup> in 1929. In 1970, Kindler<sup>3</sup> first coined the term *morning glory syndrome* because the ophthalmoscopic appearance of this anomaly closely resembles that of the morning glory flower. Morning glory syndrome is characterized by a funnel-shaped, excavated optic disc surrounded by chorioretinal pigmentary disturbance. Occasionally seen are collections of glial tissue overlying the center of the disc, retinal vascular abnormalities, high myopia, and nonrhegmatogenous retinal detachments.

Most cases of morning glory syndrome are unilateral; however, there have been some reports of bilateral cases, which may show a hereditary tendency.<sup>4</sup> Females are affected twice as frequently as males, and the right eye is more frequently involved in unilateral cases (60%).<sup>4</sup> Generally, morning glory syndrome is an isolated ocular abnormality; however, some systemic associations have been reported, including midline cranial facial defects such as hypertelorism, cleft lip and palate, basal encephalocele, agenesis of the

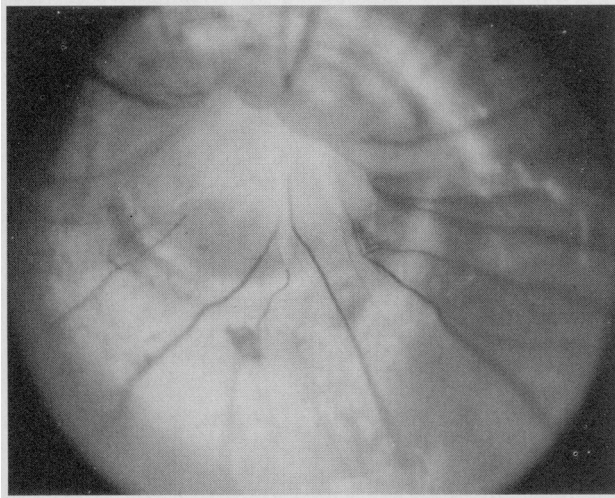
corpus callosum, and defects in the floor of the sella turcica.<sup>5-13</sup> Infrequently, renal anomalies and the CHARGE syndrome have also been reported as associated findings.<sup>14,15</sup> We report herein a series of two cases of morning glory syndrome associated with midline central nervous system anomalies and endocrine dysfunction.

### REPORT OF CASES

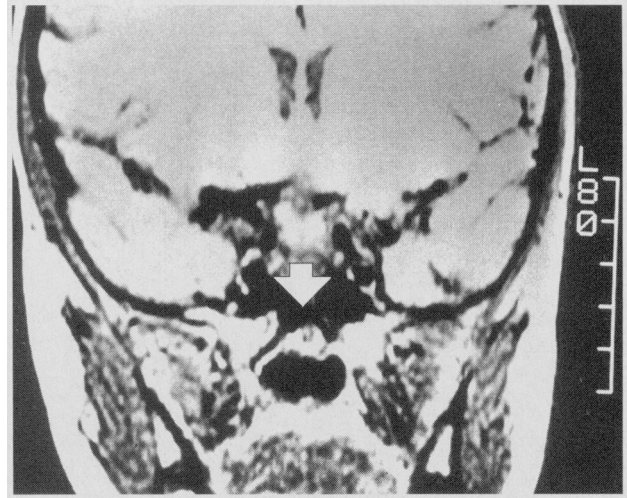#### CASE 1

A female infant was referred at age 4 months for a wandering right eye. She was born after a term pregnancy to a 36-year-old gravida 6, para 4, aborta 2 woman. The pregnancy was complicated by hyperemesis for which an unknown medication was used. Delivery and perinatal course were uncomplicated. At the 4-month evaluation, a variable esotropia was noted. Funduscopic examination revealed the characteristic appearance of morning glory syndrome. The patient was lost to follow-up until the age of 7 years when ocular examination revealed a visual acuity of hand motion in the right eye and 20/20 OS. A relative afferent pupillary defect was present in the right eye. Motility examination revealed a 10–prism diopter right hy-

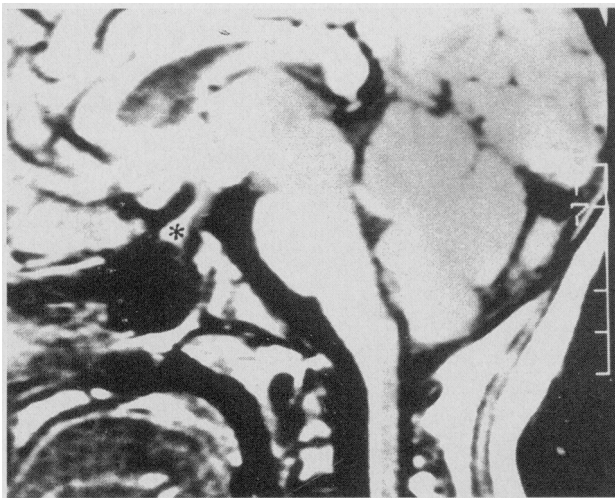From the Departments of Ophthalmology (Drs Eustis and Sanders) and Pediatrics (Drs Eustis and Zimmerman), Ochsner Clinic and Alton Ochsner Medical Foundation, New Orleans, La.



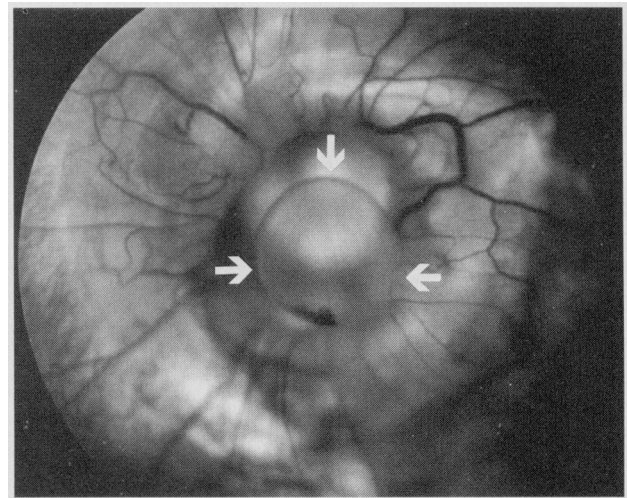
**Figure 1.** Right optic nerve of case 1 demonstrating the typical appearance of the morning glory-shaped disc anomaly.



**Figure 2.** Coronal section of the magnetic resonance imaging scan of case 1. The arrow points to the cleft in the sellar region.



**Figure 3.** Sagittal section of the magnetic resonance imaging scan of case 1. The asterisk marks the pituitary gland, which is compressed by a meningocele traversing the sellar cleft.



**Figure 4.** Left optic nerve of case 2, showing the morning glory-shaped disc anomaly. Note retinal cyst (arrows) emanating from the optic disc margin.

perotropia that increased in left gaze and was associated with a variable V-esotropia. Ductions revealed marked overaction of the right inferior oblique muscle. Latent nystagmus was present in the right eye. With confrontation fields, 10° to 20° of visual field remained inferiorly in the

### *See also pages 153 and 154*

right eye, and full visual fields were present in the left eye. On fundoscopic examination, the morning glory-shaped disc was again noted and was associated with an inferior retinal detachment (**Figure 1**). Findings from examination of the left eye were normal.

Because of her short stature, the patient was referred for growth evaluation. At age 8 years 3 months, her height was 108 cm (less than the fifth percentile) and her weight was 20.8 kg (seventh percentile). No asym-

metry and no unusual facial features were noted. The remaining results of her general physical examination were normal. Endocrine evaluation included a bone age between 3 and 4 years by Tanner and Greulich-Pyle standards. Thyroid function tests and growth hormone studies confirmed the diagnosis of growth hormone deficiency (**Table**). Computed tomography of the brain and sella was performed with and without contrast. A bony defect was found in the base of the skull. Magnetic resonance imaging (MRI) revealed a 3-mm cleft in the sellar region (**Figure 2**). A meningocele traversed this cleft and extended into the sellar region, compressing the pituitary gland (**Figure 3**). The pituitary was hypoplastic, and no obvious pituitary stalk was visualized. The hypothalamus was hypertrophied. A diagnosis of multiple pituitary hormone insufficiency was made, and recombinant human growth hormone and thyroid hormone replacement was then initiated.

## CASE 2

A 3-month-old male infant was referred for evaluation of visual inattention. He was the product of a term, uncomplicated, first gestation. History before our examination included repair of a cleft lip at age 2 months. His ophthalmologic examination revealed absence of fixation in the left eye and a relative afferent pupillary defect in the left eye. Visual acuity was central, steady, and maintained in the right eye. Ductions were full, and a 30-prism diopter exotropia was measured by the Krinsky method. Epiphora was noted in both eyes. The anterior segment showed a corneal diameter of 9.5 mm in the right eye and of 8.5 mm in the left eye. Cycloplegic refraction was +1.25 sphere in the right eye and -11.50 sphere in the left eye. The right fundus was normal. The left fundus showed typical morning glory syndrome (**Figure 4**).

**O**N GENERAL physical examination at 3 months of age, he was 57 cm long (below the 10th percentile), his stretched phallus length was 2.5 cm (2 SDs below the mean), and he had bilateral descended testes. The result of a chromosomal analysis was a normal 46 XY. The MRI scan of the head showed partial agenesis of the corpus callosum. The pituitary gland appeared normally formed on the MRI scan. At the 7-month follow-up examination, he was 65.5 cm long (between the fifth and 10th percentile), weighed 7.8 kg (25th percentile), and had a stretched phallus length of 2 cm (2.5 SDs below the mean). Testosterone therapy (25 mg given intramuscularly once a month for 3 months) was begun at this time. At age 3 years 5 months, his height was 86.4 cm (3 SDs below the mean); growth velocity, 4.7 cm/y (less than the fifth percentile); weight, 12.5 kg (less than the fifth percentile); and stretched phallus length, less than the 10th percentile. Bone age by Greulich-Pyle standards was 2 years 8 months at a chronologic age of 3 years 6 months. A growth hormone evaluation at this time revealed a decreased somatomedin C level and a blunted response to levodopa and clonidine hydrochloride stimulation tests (Table). Recombinant human growth hormone therapy was then initiated, and it demonstrated a 4-cm increment in height after 3 months of therapy.

### COMMENT

Although morning glory syndrome is usually an isolated ophthalmologic finding, midline neurologic and craniofacial defects, including hypertelorism, cleft lip and palate, basal encephaloceles, agenesis of the corpus callosum, and defects of the sella turcica, have been reported.<sup>5-13</sup> The association of morning glory syndrome with midline clefting abnormalities can be attributed to a common developmental defect in embryogenesis. A review of cranio-

### Endocrine Test Results

Test	Case 1	Case 2
Somatomedin C, ng/mL*	28†	5†
Thyroxine, µg/dL	5.8	10.3
T <sub>3</sub> ‡ resin uptake, %	29	35
Free thyroxine index	5.1	3.4
Thyroid-stimulating hormone, µIU/mL	0.9	1.2
Cortisol, µg/dL	...	25
Growth hormone stimulation tests (maximal response)		
Clonidine, ng/mL	No increase†	<1
Arginine	No increase†	...
Insulin	No increase†	...
Levodopa, ng/mL	...	2
Cortisone response after insulin	Increase	...

\*Units and normal range changed.

†Abnormal value.

‡T<sub>3</sub> indicates triiodothyronine.

facial embryogenesis in the work by Kissel et al<sup>16</sup> lends support to this notion. The most anterior portion of the cephalic neural plate develops into the prosencephalon and the prosencephalic neural crest. The anterior brain, diencephalon, and neuroectodermal structures of the eye develop from the prosencephalon. The medial and paramedial facial structures and the anterior base of the skull are derived from the prosencephalic neural crest. Any defect in the formation of the prosencephalic neural crest brings about median malformations of the face and the anterior portion of the base of the skull and anomalies of the anterior brain. The craniofacial anomalies are direct (total or partial absence of ectomesenchyme), whereas we propose the cerebral anomalies are an indirect effect (defect of induction). We propose the following to support this theory. The prosencephalic neural crest segment is sensitive to toxic insults during development for several reasons. First, it is small, yet it gives rise to a large cellular population in a short period. Second, unlike other parts of the neural crest, it cannot be controlled by adjacent crests because it is the most anterior. A defect in the proper formation of the neural crest has been invoked as the cause of basal encephaloceles by failure of closure of the anterior neuropore, which should occur by 4 weeks' gestation.<sup>5-16</sup> Agenesis of the corpus callosum is an indirect induction defect that may follow. Abnormalities of neural crest migration explain hypertelorism and medial and paramedial facial clefts. Any insult occurring between 4 and 8 weeks' gestation could theoretically affect closure of the superior end of the embryonic fissure of the eye, closure of the anterior neuropore, and migration midline structures derived from the neural crest. This hypothesis would seem to explain the morning glory syndrome and the constellation of associated findings with this disorder.

The two cases reported herein bring the total number of cases of morning glory syndrome associ-

ated with pituitary dwarfism to five.<sup>9-11</sup> The causative factors of pituitary dwarfism differ in our two cases. In the first case, mechanical compression of the pituitary gland by a basal meningocele resulted in the hypopituitarism and secondary hypertrophy of the hypothalamus. Similarly, in the previously reported cases of

***We recommend that patients with morning glory syndrome have a complete general physical examination and growth evaluation to identify pituitary hormone deficiencies***

morning glory syndrome and pituitary dwarfism, an associated basal encephalocele was present. Without further information, we can only suppose a similar mechanism in these cases. In our second case, the causative factors are less clear. The association of endocrine abnormalities and optic nerve hypoplasia has been well documented; however, the exact mechanism behind this association is unclear.<sup>17-19</sup> We hypothesize that there were abnormalities of hypothalamic control or abnormalities in the portal hypophysial system, either of which would result in reduced trophic stimulation of the pituitary gland, growth hormone deficiency, and presumed luteinizing hormone deficiency.

The importance of recognizing the association of morning glory syndrome with midline facial and nervous system defects has been stressed in previous case reports. We herein add pituitary abnormalities to the growing list of associated abnormalities. We recommend that patients with morning glory syndrome have a complete general physical examination and growth evaluation to identify pituitary hormone deficiencies. Early recognition of growth hormone deficiency is especially important because recombinant human growth hormone is now available for early treatment of these patients.

*Accepted for publication August 19, 1993.*

Reprint requests to Ochsner Clinic, 1516 Jefferson Hwy, New Orleans, LA 70121 (Dr Eustis).

REFERENCES

1. Reis W. Eine wenig bekannte typische Missbildung am Sehnerveneintritt: unbeschriebene Grubenbildung auf der Papilla n. optici. *Z Augenheilkd.* 1908;19:505.
2. Handmann M. Erbliche vermutlich angeborene zentrale gliose Entartung des Sehnerven mit besonderer Beteiligung der Zentralgefäesse. *Klin Monatsbl Augenheilkd.* 1929;83:145.
3. Kindler P. Morning glory syndrome: unusual congenital optic disk anomaly. *Am J Ophthalmol.* 1970;69:376-384.
4. Brown GC, Tasmand WS. *Congenital Anomalies of the Optic Disc.* New York, NY: Grune & Stratton; 1983.
5. Pollack JA, Newton TH, Hoyt WF. Transsphenoidal and transtethmoidal encephaloceles: a review of clinical and roentgen features in 8 cases. *Radiology.* 1968;90:442-453.
6. Goldhammer Y, Smith JL. Optic nerve anomalies in basal encephalocele. *Arch Ophthalmol.* 1975;93:115-118.
7. Koenig SB, Naidich TF, Lissner G. The morning glory syndrome associated with sphenoidal encephalocele. *Ophthalmology.* 1982;89:1368-1373.
8. Caprioli J, Lesser RL. Basal encephalocele and morning glory syndrome. *Br J Ophthalmol.* 1983;67:349-351.
9. Storms M, Dralands L, Leys A, Vanderschueren D, Bouillon R. Morning glory syndrome and basal encephalocele mimicking a pituitary adenoma. *Bull Soc Belge Ophthalmol.* 1987;2:97-103.
10. Takezawa N, Sato M, Yanagisawa T, Shimizu N. Pituitary dwarfism associated with morning glory syndrome and transsphenoidal encephalocele: a case report [in Japanese]. *No To Hattatsu.* 1987;19:492-496. English abstract.
11. Kobayashi S, Miyazaki M, Miyagi O, Yodonawa M, Shimizu S. A case of transsphenoidal meningoencephalocele [in Japanese]. *No Shinkei Geka.* 1990;18:1065-1070.
12. Hope-Ross M, Johnston SS. The morning glory syndrome associated with sphenoidal encephalocele. *Ophthalmic Paediatr Genet.* 1990;11:147-153.
13. Steinkuller PG. The morning glory disk anomaly: case report and literature review. *J Pediatr Ophthalmol Strabismus.* 1980;17:81-87.
14. Beyer WB, Quencer RM, Osher KH. Morning syndrome: a functional analysis including fluorescein angiography, ultrasonography, and computerized tomography. *Ophthalmology.* 1982;89:1362-1367.
15. Risse JF, Guillaume JB, Boissonnot M, Bonneau D. An unusual polymalformation syndrome: 'CHARGE association' with unilateral 'morning glory syndrome.' *Ophthalmologie.* 1989;3:196-198.
16. Kissel P, Andre JM, Jacquier A. *The Neurocristopathies.* New York, NY: Masson Publishing; 1981.
17. Skarf B, Hoyt CS. Optic nerve hypoplasia in children: association with anomalies of the endocrine and CNS. *Arch Ophthalmol.* 1984;102:62-67.
18. Lambert SR, Hoyt CS, Narahara MH. Optic nerve hypoplasia. *Surv Ophthalmol.* 1987;32:1-9.
19. Brodsky MC, Glasier CM. Optic nerve hypoplasia: clinical significance of associated central nervous system abnormalities on magnetic resonance imaging. *Arch Ophthalmol.* 1993;111:66-74. Erratum: *Arch Ophthalmol.* 1993;111:491.