

# Skeletal Immaturity, Rostral Sparing, and Disparate Hip Morphologies as Biomechanical Causes for Legg-Calvé-Perthes' Disease

MICHAEL A. BERTHAUME<sup>1,2,\*</sup>, DANIEL C. PERRY<sup>3</sup>, CATHERINE DOBSON<sup>1</sup>, ULRICH WITZEL<sup>4</sup>, NICHOLAS M. CLARKE<sup>5</sup>, AND MICHAEL FAGAN<sup>1</sup>

<sup>1</sup>Medical and Biological Research Group, School of Engineering, University of Hull, Hull, Yorkshire, HU6 7RX, United Kingdom

<sup>2</sup>Department of Anthropology, University of Massachusetts, Amherst, Amherst, Massachusetts, 01003, United States of America

<sup>3</sup>Division of Health Sciences, Warwick Medical School, The University of Warwick, Coventry, West Midlands, CV4 7AL, United Kingdom

<sup>4</sup>Research Group of Biomechanics, Department of Engineering, University of Bochum, Bochum, 44801, Germany

<sup>5</sup>Department of Child Health, Southampton General Hospital and University of Southampton, Southampton, SO16 6YD, United Kingdom

Short Title: Biomechanical Causes for Legg-Calvé-Perthes' Disease

\*Correspondence to Dr. Michael A. Berthaume, Medical and Biological Engineering Research Group, School of Engineering, University of Hull, Hull, HU6 7RX, United Kingdom

E-mail: [M.Berthaume@hull.ac.uk](mailto:M.Berthaume@hull.ac.uk)

This is the peer reviewed version of the following article: Berthaume, M. A., Perry, D. C., Dobson, C. A., Witzel, U., Clarke, N. M. and Fagan, M. J. (2016), Skeletal immaturity, rostral sparing, and disparate hip morphologies as biomechanical causes for Legg-Calvé-Perthes' disease. *Clin. Anat.*, 29: 759–772, which has been published in final form at doi:10.1002/ca.22690. This article may be used for non-commercial purposes in accordance With Wiley Terms and Conditions for self-archiving.

This article has been accepted for publication and undergone full peer review but has not been through the copyediting, typesetting, pagination and proofreading process which may lead to differences between this version and the Version of Record. Please cite this article as an 'Accepted Article', doi: 10.1002/ca.22690

**ABSTRACT**

Legg-Calvé-Perthes' (Perthes') disease is a developmental disease of the hip joint that may result in numerous short and long term problems. The aetiology of the disease remains largely unknown, but the mechanism is believed to be vascular and/or biomechanical in nature. There are several anatomical characteristics that tend to be prevalent in children with Perthes' disease, namely: skeletal immaturity, reduced height and rostral sparing. We present an overview of the literature, summarising the current understanding of the pathogenesis, particularly related to how the formation of the vasculature to the femoral epiphysis places children aged 5-8 at a higher risk for Perthes' disease, how skeletal immaturity and rostral sparing could increase the probability of developing Perthes' disease, and how animal models have aided our understanding of the disease. In doing so, we also explore why Perthes' disease is correlated to latitude, with populations at higher latitudes having higher incidence rates than populations closer to the Equator. Finally, we present five hypotheses detailing how Perthes' disease could have a biomechanical cause.

**KEY WORDS**

Legg-Calve-Perthes disease; aetiology; biomechanical causes; skeletal immaturity; rostral sparing; short stature; Allen's and Bergmann's rules; socioeconomic status, second-hand smoking, animal models

## INTRODUCTION

Legg-Calvé-Perthes' (Perthes') disease is a developmental disease of the hip joint that can result in both short and long term morbidity, including pain, limited hip movement and early onset osteoarthritis. It is believed that the disease is caused by a restriction of the epiphyseal blood supply, which leads to necrosis and weakening of the femoral head. Physiological loading of the hip can then lead to a subchondral fracture in the bony epiphysis, and collapse of the bony part of the epiphysis. Although the disease was first described over a hundred years ago (Calvé, 1910; Legg, 1910; Perthes, 1910) and the pathogenesis has been hypothesized for three decades (Salter and Thompson, 1984; Thompson and Salter, 1987), the aetiology of the disease remains unknown (Perry and Hall, 2011). Research into the aetiology of Perthes' disease has focused mainly on factors that are well-known to have negative influences on health; for example, birth factors (i.e. low birth-weight, late in the birth order and parents who are older at the time of the birth) (Molloy and Macmahon, 1967; Fisher, 1972; Wynne-Davies and Gormley, 1978; Hall et al., 1979; Wang et al., 1990; Margetts, 2001; Lappin et al., 2003; Sharma et al., 2005; Wiig et al., 2006), second-hand smoking (Molloy and Macmahon, 1967; García Mata et al., 2000; Gordon et al., 2004; Sharma et al., 2005; Bahmanyar et al., 2008) and low socioeconomic status (Barker et al., 1978; Wynne-Davies and Gormley, 1978; Hall et al., 1979, 1983, 1988; Wijesekera, 1984; Hall and Barker, 1989; Kealey et al., 2000; Gordon et al., 2004; Pillai et al., 2005; Sharma et al., 2005; Perry et al., 2011, 2012a, 2012b).

Inconsistencies in aetiological factors between cases of Perthes' disease make it difficult to predict those at risk of the disease. The high degree of variability in incidence rates around the world also makes it difficult to identify common factors (Perry et al., 2012d). However, some factors appear consistent across studies. These include: rostral sparing (dysmorphic growth patterns with sparing of the head and upper limbs (Burwell et al., 1978; Burwell, 1988)), being short in stature while being

heavy/normal weight for age (Goff, 1954; Ralston, 1955; Cameron and Izatt, 1960; Weiner and O'Dell, 1970; Fisher, 1972; Emr et al., 1973; Katz and Siffert, 1977; Burwell et al., 1978; Wynne-Davies and Gormley, 1978; Cannon et al., 1989; Wiig et al., 2006; Perry and Hall, 2011) (although these factors were not found to be statistically significant in some studies (Girdany and Osman, 1968; Laron et al., 1973; Kealey et al., 2004; Sharma et al., 2005)), and being skeletally immature (Goff, 1954; Caffey, 1968; Girdany and Osman, 1968; Weiner and O'Dell, 1970; Fisher, 1972; Laron et al., 1973; Emr et al., 1973; Harrison et al., 1976; Katz and Siffert, 1977; Thompson et al., 1978; Bohr, 1979; de Guembecker and Duriez, 1981; Edvardsen et al., 1981; Harrison and Burwell, 1981; Kristmundsdottir et al., 1984, 1986, 1987; Wijesekera, 1984; Thompson and Salter, 1987; Burwell, 1988; Loder et al., 1995; Vila-Verde and da Silva, 2001; Kitoth et al., 2003; Lee et al., 2007; Zarco et al., 2008). These conditions appear to predispose an individual to Perthes' disease, and/or promote a vascular insult to the medial circumflex artery, causing infarction to the developing epiphysis and Perthes' disease to ensue.

A review of the recent literature reveals a decline in studies investigating the aetiology of Perthes' disease. Instead, recent research tends to focus on treatment modalities (Kim, 2012). Treatment methods vary from observation to immobilisation, splintage, or surgery depending on the child's age, the level of damage experienced by the bony epiphysis, and the beliefs of the surgeon (Catterall, 1971; Stulberg et al., 1981; Herring et al., 1992; McQuade and Houghton, 2005; Canavese and Dimeglio, 2008; Osman et al., 2009). Past treatment methods focused on immobilisation and reduction of the loading of the hip in the hope that this would prevent further collapse of the femoral head (Danforth, 1934; Herndon and Heyman, 1952; Goff, 1954; Katz, 1967). However, these treatments were largely unsuccessful, perhaps because muscles crossing the hip can produce significant forces at the joint that far exceed the forces produced by body weight (Bergmann et al., 1993, 2001).

The primary goal of the current treatment methods is containment of the femoral head within the acetabulum. This maintains the weakened femoral head within the relative sphericity of the

acetabulum, thereby encouraging the femoral head to adopt the shape of the acetabulum during the reossification stage of the disease. Attempts are made to achieve this non-invasively with a range of motion exercises and braces, or surgically through femoral or pelvic osteotomies (Herring et al., 2004). When deciding between non-invasive and surgical treatment, Catterall classification and “at risk signs” play crucial roles: non-invasive treatment is more appropriate for children in Catterall groups I and II, and surgical treatment (namely, a femoral osteotomy) is more appropriate for children in Catterall groups III and IV, particularly when they are “at risk” for further femoral collapse (Catterall, 1971; Lloyd-Roberts et al., 1976). Outcomes tend to be correlated with sex and age at onset of the disease, with those 6 years old and younger doing better than older children, and boys doing better than girls (Herring et al., 2004; Canavese and Dimeglio, 2008; Osman et al., 2009). This could be because a smaller portion of the epiphysis is bony in younger children and boys. These treatments can be time consuming, place a significant financial and psychological burden on the family, and consume a significant proportion of the individual’s childhood (Goff, 1954).

The mechanism underpinning Perthes’ disease is believed to be vascular, and although the aetiology of the vascular insult remains unknown, it has been hypothesized to be biomechanical in nature (Trueta, 1957; Caffey, 1968; Harrison and Burwell, 1981; Kristmundsdottir et al., 1984; Salter and Thompson, 1984; Thompson and Salter, 1987; Wiig et al., 2007; Nelitz et al., 2009). Surprisingly, research concerning the biomechanics of the disease is sparse and tends to focus on the effects rather than the causes of the disease (Moseley, 1980; Brown et al., 1982; Rab et al., 1982; Kristmundsdottir et al., 1984; Ueo et al., 1987). The goal of this paper is to propose a number of biomechanically-based hypotheses that explain the development of Perthes’ disease.

## **PATHOGENESIS**

The pathogenesis of Perthes' disease is described in detail by Salter and Thompson (1984) and Thompson and Salter (1987). Initially, an ischemic episode occurs, avascular necrosis of the femoral epiphysis ensues, and epiphyseal growth is arrested (Fig. 1). This can occur up to a year before the collapse of the femoral head (Inoue et al., 1976). Eventually, the epiphysis is revascularized, necrotic bone is resorbed, and new bone is laid down. During the time of bone resorption, the epiphysis is particularly weak and prone to fracture because a) necrotic bone is weaker than healthy bone (Pringle et al., 2004; Koob et al., 2007; Hofstaetter et al., 2010), and b) the resorption of the weak, necrotic bone removes what little structural support the necrotic bone was providing (McQuade and Houghton, 2005; Kim et al., 2006). Observations in children with Perthes' disease (Inoue et al., 1976; Iwasaki et al., 1982) and animal models (Kemp, 1973) suggest this process may occur once or multiple times before Perthes' disease develops.

When the epiphysis is particularly weak, a pathological (most likely subchondral) fracture occurs and Perthes' disease becomes evident both clinically and radiographically. Salter and Thompson (1984) argue that up until the point of fracture, the child does not have Perthes' disease, and is simply at risk of developing Perthes' disease.

This therefore suggests two distinct steps in the disease mechanism; the first being to weaken the bone via a vascular insult, and the second being a trauma to the femoral head. Our hypotheses provide biomechanical explanations for how the blood supply could be cut off and how the pathological fracture could occur.

## BLOOD SUPPLY TO THE EPIPHYSIS

During the first three years of development, the femoral epiphysis has two main blood supplies arising from the medial and lateral circumflex arteries, which enter the epiphysis via the superior, posterior, lateral and the inferior, posterior, medial quadrants, respectively (Trueta, 1957; Ogden, 1974). These arteries supply blood to the epiphysis via vessels that branch off and directly enter the cartilaginous head, and via vessels that branch off, enter the metaphysis, and travel around the growth plate to enter the epiphysis (Ogden, 1974; Chung, 1976). As an individual ages, fewer vessels reach the epiphysis and there is marked individual and racial variation (Trueta, 1957). When the individual is about two to three years old, the lateral circumflex artery stops supplying blood to the epiphysis and only supplies blood to the metaphysis. In addition, the blood vessels that previously skirted around the periphery of metaphysis and supplied blood to the epiphysis via the metaphysis cease to exist (Crock, 1965; Lauritzen, 1974; Ogden, 1974). Thus, from the ages of four to seven years, the bony part of the femoral epiphysis only receives blood from the medial circumflex artery. By the time the child is seven years old, the foveolar artery (i.e. the acetabular branch of the obturator artery) begins to supply blood to the bony epiphysis (Tucker, 1949; Trueta, 1957).

As a result, the bony part of the femoral epiphysis is particularly susceptible to ischemic episodes between the ages of four and seven years old, especially if the medial circumflex artery is damaged or restricted. African children are believed to have a higher level of vascularization to the epiphysis during this age period, but this has never been systematically tested (Ogden, 1974). This could explain why Perthes' disease tends to occur in Caucasian children between the ages of five and eight more than any other race or age group. Angiograms of children with Perthes' disease have revealed that, in early stages of the disease, there is a devascularization of the epiphysis most likely caused by an abrupt interruption of the medial circumflex artery (Théron, 1980; de Camargo et al., 1984).

Furthermore, in children with Perthes' disease older than seven years old, there is an absence of a blood supply to the femoral head from the lateral circumflex and obturator arteries (Théron, 1980; de Camargo et al., 1984; Atsumi et al., 2000). This is followed by revascularization of the epiphysis, although the number of arteries supplying blood to the epiphysis of the afflicted side is reduced compared to the contralateral side (de Camargo et al., 1984; Shore et al., 2012).

It should be noted that the occlusion observed in the angiograms may have occurred as a result of the damage from the subchondral fracture and/or the femoral head collapse, and therefore may not have led to the initial infarction (Kitoh et al., 2003). Nevertheless, evidence supporting the hypothesis that restriction of the blood supply from the medial circumflex artery leads to the development of Perthes' disease is considerable (Iwasaki et al., 1982; Perry et al., 2012c). Furthermore, animal models have shown that vascular occlusion of the medial circumflex artery can cause Perthes'-like radiographic changes (Yoshida et al., 2000; Kim, 2010; Zhang et al., 2010).

## **SKELETAL IMMATURITY**

Skeletal maturity is commonly measured via hand-wrist radiographs of children, although it can be measured in other ways (Acheson, 1954, 1957; Stuart et al., 1962; Greulich et al., 1971; Tanner et al., 1976; Gaskin et al., 2011). The two methods usually used for measuring skeletal maturity in the wrist are the Greulich and Pyle, and Tanner Whitehouse (TW2 and TW3) methods (Greulich et al., 1971; Tanner et al., 1976). The Greulich and Pyle method compares hand-wrist radiographs of a patient to a series of published hand-wrist radiographs with known skeletal ages. Skeletal age is determined by deciding which published radiograph the patient's radiograph best resembles, and assigning the patient that skeletal age, making the method prone to significant interobserver variation (Bull et al., 1999). The Tanner Whitehouse method assigns a score to each of the ossification centres in the hand and wrist,



summing the scores and assigning an age based on the final score, making it less prone to interobserver variation (Bull et al., 1999).

Differences in the techniques can lead to two different skeletal ages for the same individual. There is a particularly high risk of this happening in children with Perthes' disease because of skeletal disharmony (Kristmundsdottir et al., 1984; Bull et al., 1999; Lee et al., 2007). Under the Greulich and Pyle method, "skeletal standstill" – a period of time, usually years, in which there is no progress in skeletal maturation – was observed in a number of boys followed by catch-up growth (Harrison et al., 1976). However, when these same children were skeletally aged using the Tanner Whitehouse method, no skeletal standstill was observed (Kristmundsdottir et al., 1984). Since it is unlikely that the children stopped maturing skeletally at such a young age, it can be concluded that the Greulich and Pyle method is not appropriate for children with Perthes' disease (Bull et al., 1999). In addition, the method used to skeletally age children with Perthes' disease must be taken into account when comparing studies dealing with skeletal age and Perthes' disease.

Hypotheses concerning the cause(s) of skeletal immaturity in children with Perthes' disease have included malnutrition (Burwell, 1988) to endocrinopathies (Rayner et al., 1986; Kealey et al., 2004). The best investigated nutritional deficiency is manganese deficiency, as it was proven to cause similar growth failure in chicks (Hall et al., 1989). Whilst an initial study of manganese deficiency was highly suggestive of a nutritional deficiency (Hall et al., 1989), a subsequent confirmatory study was unable to replicate these results (Perry et al., 2000), making the nutritional component uncertain. There is no strong association with endocrinopathies, with investigations for hypothyroidism and growth hormone deficiencies failing to yield consistent findings (Kenet et al., 2008; Vosmaer et al., 2010; Perry and Hall, 2011).

From a biomechanical perspective, we hypothesise that an immature skeleton is less efficient at supporting the loads of a child, because skeletal mechanical properties are known to increase with age (Currey and Butler, 1975). We hypothesise that the small bony epiphysis is less able to resist loading. This could lead to mechanical failure of the joint (Acheson, 1957), especially considering the material properties in a mature hip joint are distributed in a way to resist effectively normal loading conditions (Hong et al., 2000; Lubovsky et al., 2011; Wright et al., 2012). In the case of Perthes' disease, if the hip joint were skeletally immature, it would be inefficient in resisting the loads applied to it, and would be susceptible to occlusion of the blood supply and trauma (e.g. a subchondral fracture) (Loder and Skopelja, 2011).

In children with Perthes' disease, it is important to consider how the skeletal age of the hip relates to chronological and skeletal age in general. One such study has compared the pelvis to the wrist, using a modified method of Acheson's method, and found that the pelvis was skeletally immature, but not as skeletally immature as the wrist (Acheson, 1957; Loder et al., 1995). The differences were suggested to be due to the rostral sparing observed in Perthes' disease (see later). Differential maturation, mirroring the rostral sparing pattern of growth, may be an important contribution to the disease mechanism.

## **SOCIOECONOMIC STATUS, SECOND-HAND SMOKING, AND DECREASED ARTERIAL HEALTH**

The association between socioeconomic status (SES) deprivation and Perthes' disease is strong (Gordon et al., 2004; Sharma et al., 2005; Perry et al., 2011, 2012a,b; Perry, 2013 a,b; ), while the relationship between second-hand smoking and Perthes' disease is more contested (García Mata et al.,

2000; Gordon et al., 2004; Bahmanyar et al., 2008). In early studies investigating the relationship between SES and Perthes' disease, a positive correlation was discovered between people who lived in urban regions, lower SES, and Perthes' disease. It was hypothesized that living in an urban area caused the increase in incidence rates of Perthes' disease: this hypothesis was eventually proven false (Joseph et al., 1988; Hall and Barker, 1989; Kealey et al., 2000), as it was discovered the correlation between urbanization and Perthes' disease only existed because low SES and urbanization covaried (Barker et al., 1978; Perry et al., 2012b). The current hypothesis is that people of lower SES may share a deprivation-related 'exposure', which is the aetiological determinant in Perthes' disease (Hall et al., 1983; Kealey et al., 2000).

Given the strong association between SES and smoking (Winkleby et al., 1992; Adler et al., 1994), attention has been directed to identify if tobacco smoke exposure may be the aetiological determinant (García Mata et al., 2000). However, the strong correlation between SES and smoking is such that it is difficult to disentangle the two adequately.

Second-hand smoke is known to have many adverse health effects in children, including a decrease in arterial health (Kallio et al., 2007), which has been documented both in children who currently suffer from and adults who formerly suffered from Perthes' disease (Hailer et al., 2010; Perry et al., 2012c). If these arterial problems are severe enough to cause mild ischemias, this could theoretically cause skeletal immaturity (Catterall et al., 1982; Dillman and Hernandez, 2009), which could lead to the development of Perthes' disease.

## SHORT STATURE, NORMAL WEIGHT

Anatomical problems prevalent in children with Perthes' disease include rostral sparing and short stature while maintaining a normal to slightly heavy weight (Fisher, 1972; Burwell et al., 1978; Thompson et al., 1978; Hall et al., 1988; Eckerwall et al., 1996; Güngör, 2014). Rostral sparing is a condition where the axial skeleton follows a normal growth pattern while the appendicular skeleton follows an impaired growth pattern, with more inferior (caudal) segments having a larger level of impairment than more superior (rostral) ones (Burwell et al., 1978; Hall et al., 1988; Rao et al., 1995; Perry and Hall, 2011). This would result in the ratio of bodyweight above the hip joint to bodyweight below the hip joint to be abnormally high in children with rostral sparing.

The higher bodyweight supported by the hip joint, and skeletally immature hips raises the possibility that the hip will be overloaded. This overloading could cause occlusion of the blood supply and development of Perthes' disease.

## REGIONAL VARIATION IN INCIDENCE LEVELS

The hypothesis concerning differences in body proportions and overloading of the hip joint may also explain differences in incidence rates of Perthes' disease around the world. In a recent systematic review of incidence, Perry et al. (2012d) determined that race was one of the most important factors in determining variations in incidence levels, with people of East Asian descent having lower incidence rates (Coyle, 1975; Joseph et al., 1988; Rowe et al., 2005; Kim et al., 2006; Joseph and Willoughby, 2010) than people of Caucasian descent (Gray et al., 1972; Moberg and Rehnberg, 1992; Margetts, 2001; Pillai et al., 2005; Sharma et al., 2005; Wiig et al., 2006; Krul et al., 2010; Terjesen et al., 2010). Although people of African descent are hypothesized to have the lowest incidences, they were excluded from the study due to insufficient data (Ebong, 1977; Purry, 1982). Further evidence that a racial component

causes differences in incidence rates comes from two studies that compared incidence levels of two different races living in the same environment, where people of Caucasian descent had higher incidence rates than people of African or Asian descent (Purry, 1982; Faraj and Nevelos, 2000).

Once race is accounted for, latitude was the strongest predictor for incidence rates, with an increase in incidence of 1.44 times for each ten degrees movement in latitude from the Equator (Perry et al., 2012d). It is difficult to address the differences in incidences between races without further information regarding cross-cultural (a) variation in skeletal maturation rates, (b) ontogenetic changes in anthropometric measurements, and (c) variation in growth curves, as these factors may not be constant. For example, it appears skeletal maturation rates are slower in Indians, who also have a later age of onset for the disease (Joseph et al., 1988). The correlation between incidence and latitude, however, can be explained using a principle from comparative biology.

In the mid to late 1800's, Carl Bergmann (Bergmann, 1848) and Joel Allen (Allen, 1877) proposed two distinct rules concerning body proportions of endothermic animals. These rules were later combined, and are frequently referred to as Allen's and Bergmann's rules. Briefly, these rules predict that selection will act on endothermic animals that are closer to the Equator in a way that will maximize an animal's surface area to volume ratio, helping the animal expend heat. Conversely, the rules predict that selection will act to reduce the surface area to volume ratio when the animal is further away from the Equator, helping the animal conserve heat.

Under Allen's and Bergmann's rules, selection would be expected to act on humans in a way that would cause humans closer to the Equator to have longer limbs and shorter bodies, and weigh less compared to humans further away from the Equator. Not too surprisingly, there is support for this in the fossil record (Ruff, 1994; Churchill, 2006).

This would mean that, compared to people with ancestors who lived closer to the Equator, people with ancestors who lived further from the Equator would appear to have rostral sparing. This would in turn cause the latter group to have a higher hip loading and therefore be more likely to experience a higher incidence of Perthes' disease. Therefore, the correlation between latitude and increased incidence of Perthes' disease could be explained by Allen's and Bergmann's rules. This hypothesis remains to be tested.

## PERTHES' DISEASE IN NON-HUMAN ANIMALS

Because the exact cause(s) of Perthes' disease remain(s) unknown, we cannot say whether or not non-human animals suffer from Perthes' disease (Mickelson et al., 1981). Conditions similar to Perthes' disease have been reported in a rhesus macaque (*Macaca mulatta*) (Smedley et al., 2004), a red panda (*Ailurus fulgens fulgens*) (Delclaux et al., 2002), a western lowland gorilla (*Gorilla gorilla gorilla*) (Douglass, 1981), broiler chickens (*Gallus gallus domesticus*) (Duff, 1984), dogs (*Canis lupis familiaris*) (Tutt, 1935; Ljunggren, 1967) and rats (*Rattus norvegicus*) (Hirano et al., 1988). One key interesting difference between "Perthes' disease" in non-human animals and humans is that it appears to be highly hereditary in non-humans (Hirano et al., 1988; Vasseur et al., 1989), while there is no evidence for heritability in humans (Fisher, 1972; Gray et al., 1972; Wynne-Davies and Gormley, 1978; Hall, 1986; Lappin et al., 2003; W.-C. Kim et al., 2006).

Whilst inheritance may be important, there is a body of evidence implying that Perthes' disease has a biomechanical cause. Spontaneously hypertensive rats (SHRs) are a strain of Wistar Kyoto rats (WKYs) that are prone to having skeletally immature femoral epiphyses (Hirano et al., 1988), and to developing a Perthes'-like condition, while ordinary WKYs are not skeletally immature and do not develop Perthes' features. However, if SHRs are treated with hyperbaric oxygenation, effectively

increasing the ossification rate and causing the femoral head to develop at a normal rate, the femoral head does not become overloaded and the SHRs do not develop the Perthes'-like features (Kataoka et al., 1992). Also, if the SHRs are placed on a restricted diet (leading to a reduction in body weight), there is a significant drop in the frequency of Perthes' characteristics (Tomita et al., 1999; Kawahara et al., 2002), presumably because they overload their hips less. If the ordinary WKYs are forced to stand on their hind legs when feeding, thereby overloading their hip joints, they develop features of Perthes' at a frequency similar to the SHRs (Suehiro et al., 2000, 2005). Thus, it appears that, although there is a genetic factor that increases levels of susceptibility of Perthes' disease in non-human animals, biomechanical overloading of the hip joint appears to be the trigger which causes Perthes' disease.

## PATHWAYS TO PERTHES' DISEASE

Here, we propose five, untested, hypotheses that describe how Perthes' disease could be caused by a biomechanical overloading of the hip joint, three of which concern skeletal immaturity. The hypotheses focus on how the blood supply could become occluded biomechanically. In all cases, the null hypothesis is that Perthes' disease has no biomechanical cause.

*H1: Inadequate blood flow - The impaired blood supply undernourishes growth and ossification centres throughout the body, with the more proximal portions receiving more nutrients than the more distal. Because it is nutrient deficient, the bony epiphysis of the femur is small and inefficient at resisting the loads being applied to it, leading to overloading and necrosis of the bony epiphysis. The necrotic epiphysis weakens, is further overloaded, and fractures (see Fig. 2).*

Children with Perthes' disease have vascular problems. In particular, they have smaller arteries, slower blood velocity and slower blood flow (Perry et al., 2012c). It is therefore possible that insufficient nutrients are being delivered to the growth centres, affecting the distal segments more than the proximal ones. This could also explain the rostral sparing seen in children with Perthes' disease, and would be even more likely to occur when the child is between the ages of four and seven, with only one blood supply to the bony epiphysis (Tucker, 1949; Trueta, 1957). This could lead to a small bony epiphysis that is inefficient at resisting loads, and could eventually lead to necrosis, causing the epiphysis to weaken biomechanically. Finally, normal loading of the hip joint could lead to the formation of a subchondral fracture, and collapse of the bony epiphysis.

*H2: Intraosseous vasculature occlusion - The immature epiphysis cannot properly resist the loads being applied to it, and the cartilage in the epiphysis is excessively compressed. This causes occlusion of the blood supply, leading to necrosis of the bony epiphysis, causing it to weaken, overload, and fracture (see Fig. 3).*

Cartilage is more compliant than bone and less efficient at resisting loads. It is possible that the hip joint, being skeletally immature and composed of a larger amount of cartilage than it should for a child of a given size and age, cannot effectively resist the loads. This could cause the blood vessels within the cartilage of the developing femoral head to deform and occlude, leading to necrosis. The necrotic bone can then be overloaded, and fracture can occur.

*H3: Epiphyseal overloading - The immature epiphysis cannot resist the loads being applied to it, causing a subchondral fracture to occur, leading to collapse of the bony epiphysis and occlusion of the blood supply (see Fig. 4).*



This is the only hypothesis that puts occlusion of the blood supply after the subchondral fracture. As there is evidence of multiple ischemic episodes occurring in some patients with Perthes' disease, this hypothesis could not be used to explain all cases. However, it is possible for the disease to have more than one cause, one of which takes multiple ischemic episodes into account, and one of which does not (Inoue et al., 1976).

*H4: Extra-articular vasculature occlusion - Occlusion of the blood supply occurs in the medial circumflex artery outside of the femoral head, leading to necrosis of the bony epiphysis, causing it to weaken, overload, and fracture (see Fig. 5).*

Ogden (1974) hypothesized a number of ways that the medial circumflex artery could be compressed in a child: between the acetabular labrum and intertrochanteric region, the iliopsoas tendon and adductor longus, or the iliopsoas tendon and the pubic ramus. It is also possible that there could be a morphological change in the hip joint which causes the blood supply to be occluded.

Lateral displacement of the femoral head is frequently seen in children with Perthes' disease, although it is not known whether this causes or is caused by the disease (Joseph, 1989). It is possible that the skeletally immature hip joint is not efficient at resisting the loads applied to it, causing the cartilage to become overworked. Overworked cartilage is known to retain water and cause damage to the collagen network (Donohue et al., 1983). If this happens on the medial portion of the femoral head or on the adjacent portion of the acetabulum, this could cause swelling of the articular cartilage, pushing the femoral head laterally and forcing it to interact with the lip of the acetabulum. This could lead to occlusion of the blood supply (Ueo et al., 1987). Temporary swelling of the ligamentum teres could also lead to the lateralization of the femoral head, and if the femoral head does not return to its original location after the swelling has subsided, a similar series of events could occur (Kamegaya et al., 1989).

For this hypothesis, it is worth noting that, during development, a number of peripheral anastomoses can occur between the medial circumflex artery and other local arteries to supply blood to the femoral head (Gautier et al., 2000). While these anastomoses are not ubiquitous among adults, some, such as the inferior gluteal artery anastomosis, can be found in 80% of adults. If these anastomoses form sufficiently early in life, they could potentially continue to supply blood to the femoral head through a proximal connection with the medial circumflex artery, even after it has been pinched off distally (Gautier et al., 2000).

*H5: Extraosseous vascular occlusion - The femur and/or acetabulum are morphologically unique in such a way that causes high stresses and/or strains to form around the areas at which the arteries are entering the femoral head. This leads to occlusion of the blood supply and necrosis of the bony epiphysis, causing it to weaken, overload, and fracture (see Fig. 6).*

A number of morphological changes have been noted in the acetabulum of patients with Perthes' disease (Reynolds et al., 1999; Madan et al., 2003; Grzegorzewski et al., 2006). However, because of the lack of ossification, it is difficult to view and take measurements of the acetabular rim from radiographs, forcing the measurements to be simplistic, e.g. distance between the cranial and caudal points of the rim (Kamegaya et al., 1989; Madan et al., 2003). More complex measurements, such as acetabular retroversion, have been taken from adults who had Perthes' disease when they were children (Eijer et al., 2006; Ezoë et al., 2006; Berg et al., 2010). This calls into question whether any morphological change in the acetabulum caused or was caused by Perthes' disease (Eijer, 2007; Sankar and Flynn, 2008; Larson et al., 2011; Kawahara et al., 2012). In addition, as there are no definitive symptoms preceding the development of Perthes' disease, it is unknown whether or not morphological changes observed in children with the disease, such as femoral anteversion, caused the disease or occurred as a result of it (Moulton and Upadhyay, 1982; Upadhyay et al., 1986, 1987; Joseph, 1989).

Other studies have speculated on morphological changes in the femur that could cause Perthes' disease. However, there is such a wide range of "normal" morphologies that it could be difficult to identify a set of morphological characteristics that could cause Perthes' disease. For example, femoral neck angle (also known as the angle of inclination, femoral inclination, collodiaphyseal angle, and neck shaft angle), is reduced to about 110 degrees in femoral osteotomies designed to promote containment of the femoral head in the acetabulum (Joseph and Price, 2011). Yet this angle is known to vary greatly in adults and is negatively correlated with activity level (Anderson and Trinkaus, 1998; Toogood et al., 2009; Osorio et al., 2012) and age (Beals, 1969; Tardieu, 2010). Furthermore, the femoral neck angle also covaries with other aspects of femoral morphology, such as bicondylar angle, biacetabular distance, length of the femur, and length of the femoral neck (Isaac et al., 1997; Tardieu and Damsin, 1997). Understanding how all aspects of femoral morphology co-vary with one another is important when testing H5, as the differences seen in children with Perthes' disease may not fall outside the normal range of children of the same age and sex.

Finally, many studies that have investigated morphological variations in the affected femur do so by comparing it to the contralateral femoral epiphysis, and operate under the assumption that the contralateral hip represents a normal geometry. However, numerous studies of the contralateral hip have shown that it is frequently abnormal (Harrison and Blakemore, 1980; Harrison and Burwell, 1981; Arie et al., 1986; Kandzierski et al., 2003; Kitoh et al., 2003). Therefore, a geographically and racially appropriate control group should be chosen for comparison.

Testing these hypotheses is challenging, but can be achieved using tools to quantify and compare morphology (e.g. geometric morphometrics), and advanced engineering techniques, such as finite element analysis (FEA) which are commonly used in comparative anatomical studies (Moseley, 1980; Brown et al., 1982; Rab et al., 1982; Choo et al., 1989; O'Higgins, 2000; Richmond et al., 2005; Vaverka et al., 2006; Rayfield, 2007; Park et al., 2009; Salmaso and Brombin, 2013; Salmingo et al., 2014;

Smith et al., 2015). FEA will be particularly useful in quantifying the biomechanical effects of such variations in morphology, and the consequences of skeletal immaturity and variations in material properties.

## CONCLUSION

To treat and ultimately prevent Perthes' disease, we must properly understand its aetiology, the trigger of which is likely to be biomechanical in nature. However, this trigger only affects a small portion of the population, whose hip joints are particularly susceptible to overloading.

The biomechanics of Perthes' disease is poorly understood, and in the case of early stages of the disease, understudied. We propose several biomechanical hypotheses that describe how a biomechanical trigger, interacting with the vascular supply to the femoral head, may cause Perthes' disease, and how being skeletally immature, having rostral sparing, and a problematic vascular system could make a child more susceptible to this trigger. Furthermore, we speculate on how biomechanical failure may interact with the known risk factors for Perthes' disease (e.g. low SES and second-hand smoking) to make a child even more susceptible.

Through the use of the latest morphological assessment techniques to assess and compare geometries and advanced engineering modelling techniques to estimate deformations, strains, stresses, and reaction forces within the hip joint, it will be possible to begin to address these hypotheses and investigate the role of biomechanical failure in the pathogenesis of Perthes' disease.

## REFERENCES

- Acheson RM. 1954. A method of assessing skeletal maturity from radiographs; a report from the Oxford child health survey. *J Anat* 88:498–508.
- Acheson RM. 1957. The Oxford method of assessing skeletal maturity. *Clin Orthop* 10:19–39.
- Adler NE, Boyce T, Chesney MA, Cohen S, Folkman S, Kahn RL, Syme SL. 1994. Socioeconomic status and health: The challenge of the gradient. *Am Psychol* 49:15–24.
- Allen JA. 1877. The influence of physical conditions in the genesis of species. *Radical Rev* 1:108–140.
- Anderson JY, Trinkaus E. 1998. Patterns of sexual, bilateral and interpopulational variation in human femoral neck-shaft angles. *J Anat* 192:279–285.
- Arie E, Johnson F, Harrison MH, Hughes JR, Small P. 1986. Femoral head shape in Perthes' disease. Is the contralateral hip abnormal? *Clin Orthop Relat Res* 209:77–88.
- Atsumi T, Yamano K, Muraki M, Yoshihara S, Kajihara T. 2000. The blood supply of the lateral epiphyseal arteries in Perthes' disease. *J Bone Joint Surg Br* 82:392–398.
- Bahmanyar S, Montgomery SM, Weiss RJ, Ekblom A. 2008. Maternal smoking during pregnancy, other prenatal and perinatal factors, and the risk of Legg-Calvé-Perthes' disease. *Pediatrics* 122:e459–e464.
- Barker D, Dixon E, Taylor J. 1978. Perthes' disease of the hip in three regions of England. *J Bone Joint Surg Br* 60:478–480.
- Beals RK. 1969. Developmental changes in the femur and acetabulum in spastic paraplegia and diplegia. *Dev Med Child Neurol* 11:303–313.
- Berg RP, Galantay R, Eijer H. 2010. Retroversion of the contralateral adult acetabulum after previous Perthes' disease. *Acta Orthop Belg* 76:42–47.
- Bergmann C. 1848. Über die verhältnisse der wärmeökonomie der thiere zu ihrer gröÙe. *Gottinger studien*. 3:595–708.
- Bergmann G, Deuretzbacher G, Heller M, Graichen F, Rohlmann A, Strauss J, Duda GN. 2001. Hip contact forces and gait patterns from routine activities. *J Biomech* 34:859–871.
- Bergmann G, Graichen F, Rohlmann A. 1993. Hip joint loading during walking and running, measured in two patients. *J Biomech* 26:969–990.
- Bohr HH. 1979. International skeletal maturation in Legg-Calvé-Perthes' disease. *Int Orthop* 2:277–281.
- Brown TD, Mutschler TA, Ferguson AB. 1982. A non-linear finite element analysis of some early collapse processes in femoral head osteonecrosis. *J Biomech* 15:705–715.
- Bull RK, Edwards PD, Kemp PM, Fry S, Hughes IA. 1999. Bone age assessment: a large scale comparison of the Greulich and Pyle, and Tanner and Whitehouse (TW2) methods. *Arch Dis Child* 81:172–173.
- Burwell RG. 1988. Perthes' disease: growth and aetiology. *Arch Dis Child* 63:1408–1412.

Burwell RG, Dangerfield PH, Hall DJ, Vernon CL, Harrison MH. 1978. Perthes' disease. An anthropometric study revealing impaired and disproportionate growth. *J Bone Joint Surg Br* 60:461–477.

Caffey J. 1968. The early roentgenographic changes in essential coxa plana; their significance in pathogenesis. *Am J Roentgenol* 103 :620–634.

Calvé J. 1910. Sur une forme particuliere de pseudo-coxalgie greffee sur des deformations caracteristiques de l'extremite superieure du femur. *Rev Chirurgie*. 30 :54–84.

Cameron JM, Izatt MM. 1960. Legg-Calvé-Perthes' disease. *Scot Med J* 5:148–154.

Canavese F, Dimeglio A. 2008. Perthes' disease: prognosis in children under six years of age. *J Bone Joint Surg Br* 90:940–945.

Cannon S, Pozo J, Catterall A. 1989. Elevated growth velocity in children with Perthes' disease. *J Pediatr Orthoped* 9:285–292.

Catterall A. 1971. The natural history of Perthes' disease. *J Bone Joint Surg Br* 53:37–53.

Catterall A, Pringle J, Byers P, Fulford G, Kemp H, Dolman C, Bell H, McKibbin B, Ralis Z, Jensen O, Lauritzen J, Ponseti I, Ogden J. 1982. A review of the morphology of Perthes' disease. *J Bone Joint Surg Br* 64:269–275.

Choo BS, Hogg ADC, Burwell RG, Moulton A, Worthington BS. 1989. A study of stress factors in Perthes' disease at the hip using the finite element method. *Struct Eng* 67:92–94.

Chung SM. 1976. The arterial supply of the developing proximal end of the human femur. *J Bone Joint Surg Am* 58:961–970.

Churchill SE. 2006. Bioenergetic perspectives on Neanderthal thermoregulatory and activity budgets. In: Harvati, K., Harrison, T. (Eds.), *Neanderthals Revisited: New Approaches and Perspectives, Vertebrate Paleobiology and Paleoanthropology*. Dordrecht: Springer. p 113–134.

Coyle W. 1975. Perthes' disease in Hong Kong. *J West Pac Orthop Assoc* 12:1–14.

Crock HV. 1965. A revision of the anatomy of the arteries supplying the upper end of the human femur. *J Anat* 99:77–88.

Currey JD, Butler G. 1975. The mechanical properties of bone tissue in children. *J Bone Joint Surg Am* 57:810–814.

Danforth MS. 1934. The treatment of Legg-Calvé-Perthes' disease without weight bearing. *J Bone Joint Surg Am* 16:516–534.

de Camargo FP, de Godoy RM, Tovo R. 1984. Angiography in Perthes' disease. *Clin Orthop Relat Res* 191:216–220.

de Guembecker W, Duriez J. 1981. Modification of skeletal maturation in Perthes' disease. *Rev Chir Orthop Reparatrice Appar Mot* 67:473–478.

Delclaux M, Talavera C, López M, Sánchez JM, García MI. 2002. Avascular necrosis of the femoral heads in a red panda (*Ailurus fulgens fulgens*): possible Legg-Calvé-Perthes' disease. *J Zoo Wildlife Med* 33:283–285.

Dillman JR, Hernandez RJ. 2009. MRI of Legg-Calvé-Perthes' disease. *Am J Roentgenol* 193:1394–1407.

Donohue JM, Buss D, Oegema TR, Thompson RC. 1983. The effects of indirect blunt trauma on adult canine articular cartilage. *J Bone Joint Surg Am* 65:948–957.

Douglass EM. 1981. Legg-Calvé-Perthes' disease in a lowland gorilla. *Vet Med Sm Anim Clin* 76:101–104.

Duff SR. 1984. Capital femoral epiphyseal infarction in skeletally immature broilers. *Res Vet Sci* 37:303–309.

Ebong WW. 1977. Legg-Calvé-Perthes' disease in Nigerians. *Int Surg* 62:217–218.

Eckerwall G, Wingstrand H, Hägglund G, Karlberg J. 1996. Growth in 110 children with Legg-Calvé-Perthes' disease: a longitudinal infancy childhood puberty growth model study. *J Pediatr Orthop B* 5:181–184.

Edvardsen P, Slørdahl J, Svenningsen S. 1981. Operative versus conservative treatment of Calvé-Legg-Perthes' disease. *Acta Orthop Scand* 52:553–559.

Eijer H. 2007. Towards a better understanding of the aetiology of Legg-Calvé-Perthes' disease: acetabular retroversion may cause abnormal loading of dorsal femoral head-neck junction with restricted blood supply to the femoral epiphysis. *Med Hypotheses* 68:995–997.

Eijer H, Berg RP, Haverkamp D, Pécasse GABM. 2006. Hip deformity in symptomatic adult Perthes' disease. *Acta Orthop Belg* 72:683–692.

Emr J, Svobodová L, Svoboda J, Feltl M. 1973. Body growth, skeletal age and size of the femoral epiphysis in children with Legg-Calvé-Perthes' disease on the territory of the East Bohemian Region. *Sb Ved Pr Lek Fak Karlovy Univerzity Hradci Kralove Suppl* 16:297–307.

Ezoe M, Naito M, Inoue T. 2006. The prevalence of acetabular retroversion among various disorders of the hip. *J Bone Joint Surg Am* 88:372–379.

Faraj AA, Nevelos AB. 2000. Ethnic factors in Perthes' disease: a retrospective study among white and Asian population living in the same environment. *Acta Orthop Belg* 66:255–258.

Fisher RL. 1972. An Epidemiological Study of Legg-Perthes' Disease. *J Bone Joint Surg Am* 54:769–778.

García Mata S, Ardanaz Aicua E, Hidalgo Ovejero A, Martínez Grande M. 2000. Legg-Calvé-Perthes' disease and passive smoking. *J Pediatr Orthoped* 20:326–330.

Gaskin CM, Kahn SL, Bertozzi JC, Bunch PM. 2011. Skeletal development of the hand and wrist: A radiographic atlas and digital bone age companion. Oxford: Oxford University Press. p 1-144.

Gautier E, Ganz K, Krugel N, Gill T, Ganz R. 2000. Anatomy of the medial femoral circumflex artery and its surgical implications. *J Bone Joint Surg Br* 82:679–683.

- Girdany BR, Osman MZ. 1968. Longitudinal growth and skeletal maturation in Perthes' disease. *Radiol Clin N Am* 6:245–251.
- Goff C. 1954. *Legg-Calvé-Perthes syndrome and related osteochondroses of youth*. 1st ed. Springfield, Illinois: Charles C Thomas. p 1-332.
- Gordon JE, Schoenecker PL, Osland JD, Dobbs MB, Szymanski DA, Luhmann SJ. 2004. Smoking and socio-economic status in the etiology and severity of Legg-Calvé-Perthes' disease. *J Pediatr Orthop B* 13:367–370.
- Gray IM, Lowry RB, Renwick DH. 1972. Incidence and genetics of Legg-Perthes' disease (osteochondritis deformans) in British Columbia: evidence of polygenic determination. *J Med Genet* 9:197–202.
- Greulich W, Pyle S, Waterhouse A. 1971. *A radiographic standard of reference for the growing hand and wrist*. Chicago: Case Western Reserve University. p 1-122.
- Grzegorzewski A, Synder M, Kozłowski P, Szymczak W, Bowen RJ. 2006. The role of the acetabulum in Perthes' disease. *J Pediatr Orthoped* 26:316–321.
- Güngör NK. 2014. Overweight and obesity in children and adolescents. *J Clin Res Pediatr Endocrinol* 6:129–143.
- Hailer YD, Montgomery SM, Ekblom A, Nilsson OS, Bahmanyar S. 2010. Legg-Calvé-Perthes' disease and risks for cardiovascular diseases and blood diseases. *Pediatrics* 125:e1308–15.
- Hall A, Barker D. 1989. Perthes' disease in Yorkshire. *J Bone Joint Surg Br* 71:229–233.
- Hall A, Barker D, Dangerfield P, Osmond C, Taylor J. 1988. Small feet and Perthes' disease. A survey in Liverpool. *J Bone Joint Surg Br* 70:611–613.
- Hall AJ, Barker DJ, Dangerfield PH, Taylor JF. 1983. Perthes' disease of the hip in Liverpool. *Brit Med J* 287:1757–1759.
- Hall AJ, Margetts BM, Barker DJP, Walsh HPJ, Redfern TR, Taylor JF, Dangerfield P, Delves HT, Shuttler IL. 1989. Low blood manganese levels in Liverpool children with Perthes' disease. *Paediatr Perinat Ep* 3:131–136.
- Hall D, Harrison M, Burwell R. 1979. Congenital abnormalities and Perthes' disease. Clinical evidence that children with Perthes' disease may have a major congenital defect. *J Bone Joint Surg Br* 61:18–25.
- Hall DJ. 1986. Genetic aspects of Perthes' disease. A critical review. *Clin Orthop Relat Res* 209:100–114.
- Harrison M, Blakemore E. 1980. A study of the "normal" hip in children with unilateral Perthes' disease. *J Bone Joint Surg Br* 62:31–36.
- Harrison MH, Burwell RG. 1981. Perthes' disease: a concept of pathogenesis. *Clin Orthop Relat Res* 156:115–127.
- Harrison MHM, Turner MH, Jacobs P. 1976. Skeletal immaturity in Perthes' disease. *J Bone Joint Surg Br* 58:37–40.



Herndon CH, Heyman CH. 1952. Legg-Perthes' disease; an evaluation of treatment by traction and ischial weight-bearing brace. *J Bone Joint Surg Am* 34:25–46.

Herring JA, Kim HT, Browne R. 2004. Legg-Calvé-Perthes disease part II: prospective multicenter study of the effect of treatment on outcome. *J Bone Joint Surg Br* 86:2121–2134.

Herring JA, Neustadt JB, Williams JJ, Early JS, Browne RH. 1992. The lateral pillar classification of Legg-Calvé-Perthes' disease. *J Pediatr Orthoped* 12:143–150.

Hirano T, Iwasaki K, Yamane Y. 1988. Osteonecrosis of the femoral head of growing, spontaneously hypertensive rats. *Acta Orthop Scand* 59:530–535.

Hofstaetter JG, Roschger P, Klaushofer K, Kim HKW. 2010. Increased matrix mineralization in the immature femoral head following ischemic osteonecrosis. *Bone*. 46:379–385.

Hong J, Hipp JA, Mulkern RV, Jaramillo D, Snyder BD. 2000. Magnetic resonance imaging measurements of bone density and cross-sectional geometry. *Calcified Tissue Int* 66:74–78.

Inoue A, Freeman MA, Vernon-Roberts B, Mizuno S. 1976. The pathogenesis of Perthes' disease. *J Bone Joint Surg Br* 58:453–461.

Isaac B, Vettivel S, Prasad R, Jeyaseelan L, Chandi G. 1997. Prediction of the femoral neck-shaft angle from the length of the femoral neck. *Clin Anat* 10:318–323.

Iwasaki K, Suzuki R, Okazaki T, Ikeda S, Inoue Y, Shimauchi R. 1982. The haemodynamics of perthes' disease. *Int Orthop* 6:141–148.

Joseph B. 1989. Morphological changes in the acetabulum in Perthes' disease. *J Bone Joint Surg Br* 71:756–763.

Joseph B, Chacko V, Rao B, Hall A. 1988. The epidemiology of Perthes' disease in south India. *Int J Epidemiol* 17 603–607.

Joseph B, Price CT. 2011. Principles of containment treatment aimed at preventing femoral head deformation in Perthes' disease. *Orthop Clin* 42:317–327.

Joseph B, Willoughby R. 2010. Perthes' disease, a review of contributions from the Asia-Pacific Region. *Malays Orthop J* 4:1–8.

Kallio K, Jokinen E, Raitakari OT, Hämäläinen M, Siltala M, Volanen I, Kaitosaari T, Viikari J, Rönnemaa T, Simell O. 2007. Tobacco smoke exposure is associated with attenuated endothelial function in 11-year-old healthy children. *Circulation* 115:3205–3212.

Kamegaya M, Moriya H, Tsuchiya K, Akita T, Ogata S, Someya M. 1989. Arthrography of early Perthes' disease. Swelling of the ligamentum teres as a cause of subluxation. *J Bone Joint Surg Br* 71:413–417.

Kandzierski G, Karski T, Kozlowski K. 2003. Capital femoral epiphysis and growth plate of the asymptomatic hip joint in unilateral Perthes' disease. *J Pediatr Orthop B* 12:380–386.

- Kataoka Y, Hasegawa Y, Iwata H, Matsuda T, Genda E, Miura T, Takahashi H. 1992. Effect of hyperbaric oxygenation on femoral head osteonecrosis in spontaneously hypertensive rats. *Acta Orthop Scand* 63:527–530.
- Katz JF. 1967. Conservative treatment of Legg-Calvé-Perthes' disease. *J Bone Joint Surg Am* 49:1043–1051.
- Katz JF, Siffert RS. 1977. Skeletal maturity in Legg-Calvé-Perthes' disease. *Int Orthop* 230:227–230.
- Kawahara S, Nakashima Y, Oketani H, Wada A, Fujii M, Yamamoto T, Mawatari T, Motomura G, Sato T, Akiyama M, Fujii T, Takamura K, Iwamoto Y. 2012. High prevalence of acetabular retroversion in both affected and unaffected hips after Legg-Calvé-Perthes disease. *J Orthop Sci* 17:226–232.
- Kawahara T, Shimokawa I, Tomita M, Hirano T, Shindo H. 2002. Effects of caloric restriction on development of the proximal growth plate and metaphysis of the caput femoris in spontaneously hypertensive rats: Microscopic and computer-assisted image analyses. *Microsc Res Techniq* 59:306–312.
- Kealey WDC, Lappin KJ, Leslie H, Sheridan B, Cosgrove AP. 2004. Endocrine profile and physical stature of children with Perthes' disease. *J Pediatr Orthoped* 24:161–166.
- Kealey WDC, Moore AJ, Cook S, Cosgrove AP. 2000. Deprivation, urbanisation and Perthes' disease in Northern Ireland. *J Bone Joint Surg Br* 82:167–171.
- Kemp HB. 1973. Perthes' disease: an experimental and clinical study. *Ann Roy Coll Surg* 52:18–35.
- Kenet G, Ezra E, Wientroub S, Steinberg DM, Rosenberg N, Waldman D, Hayek S. 2008. Perthes' disease and the search for genetic associations: collagen mutations, Gaucher's disease and thrombophilia. *J Bone Joint Surg Br* 90:1507–1511.
- Kim HKW. 2010. Legg-Calvé-Perthes' disease. *J Am Acad Orthop Surgeons* 18:676–686.
- Kim HKW. 2012. Pathophysiology and new strategies for the treatment of Legg-Calvé-Perthes' disease. *J Bone Joint Surg Am* 94:659–669.
- Kim HKW, Morgan-Bagley S, Kostenuik P. 2006. RANKL inhibition: a novel strategy to decrease femoral head deformity after ischemic osteonecrosis. *J Orthop Res* 21:1946–1954.
- Kim W-C, Hiroshima K, Imaeda T. 2006. Multicenter study for Legg-Calvé-Perthes' disease in Japan. *J Orthop Sci* 11:333–341.
- Kitoh H, Kitakoji T, Katoh M, Takamine Y. 2003. Delayed ossification of the proximal capital femoral epiphysis in Legg-Calvé-Perthes' disease. *J Bone Joint Surg Br* 85:121–124.
- Koob TJ, Pringle D, Gedbaw E, Meredith J, Berrios R, Kim HKW. 2007. Biomechanical properties of bone and cartilage in growing femoral head following ischemic osteonecrosis. *J Orthop Res* 25:750–757.
- Kristmundsdottir F, Burwell R, Harrison MHM, Marshall WA. 1984. Bone age retardation at the hand and wrist in children with Perthes' disease. In: Brooms, J., Hallspie, R., Sand, A., Susanne, C., Hebbelinch, M. (Eds.). *Human growth and development*. New York: Plenum Press. p 365–374.

- Kristmundsdottir F, Burwell RG, Hall DJ, Marshall WA. 1986. A longitudinal study of carpal bone development in Perthes' disease: its significance for both radiologic standstill and bilateral disease. *Clin Orthop Relat Res* 209:115–123.
- Kristmundsdottir F, Burwell RG, Harrison MHM. 1987. Delayed skeletal maturation. *Acta Orthop Scand* 58:277–279.
- Krul M, van der Wouden JC, Schellevis FG, van Suijlekom-Smit LWA, Koes BW. 2010. Acute non-traumatic hip pathology in children: incidence and presentation in family practice. *Fam Pract* 27:166–70.
- Lappin K, Kealey D, Cosgrove A, Graham K. 2003. Does low birthweight predispose to Perthes' disease? Perthes' disease in twins. *J Pediatr Orthop B* 12:307–310.
- Laron Z, Axer A, Drezner Z. 1973. Growth and development of children with Legg-Calvé-Perthes syndrome in Israel. *Israel J Med Sci* 9:612–616.
- Larson, AN, Stans A, Sierra RJ. 2011. Ischial spine sign reveals acetabular retroversion in Legg-Calvé-Perthes' disease. *Clin Orthop Relat Res* 469:2012–2018.
- Lauritzen J. 1974. The arterial supply to the femoral head in children. *Acta Orthop Scand* 45:724–736.
- Lee S-T, Vaidya SV, Song H-R, Lee S-H, Suh S-W, Telang SS. 2007. Bone age delay patterns in Legg-Calvé-Perthes' disease: an analysis using the Tanner and Whitehouse 3 method. *J Pediatr Orthoped* 27:198–203.
- Legg AT. 1910. An obscure affection of the hip-joint. *Boston Med Surg J* 162:202–204.
- Ljunggren G. 1967. Legg-Perthes' disease in the dog. *Acta Orthop Scand Suppl* 95:1–79.
- Lloyd-Roberts G, Catterall A, Salamon P. 1976. A controlled study of the indications for and the results of femoral osteotomy in Perthes' disease. *J Bone Joint Surg Br* 58:31–36.
- Loder RT, Farley FA, Herring JA, Schork MA, Shyr Y. 1995. Bone age determination in children with Legg-Calvé-Perthes' disease: a comparison of two methods. *J Pediatr Orthoped* 15:90–94.
- Loder RT, Skopelja EN. 2011. The epidemiology and demographics of Legg-Calvé-Perthes' disease. *ISRN Orthoped* 2011:1–14.
- Lubovsky O, Wright D, Hardisty M, Kiss A, Kreder HJ, Whyne C. 2011. Importance of the dome and posterior wall as evidenced by bone density mapping in the acetabulum. *Clin Biomech* 26:262–266.
- Madan S, Fernandes J, Taylor JF. 2003. Radiological remodelling of the acetabulum in Perthes' disease. *Acta Orthop Belg* 69:412–420.
- Margetts BM. 2001. The incidence and distribution of Legg-Calvé-Perthes' disease in Liverpool, 1982-95. *Arch Dis Child* 84:351–354.
- McQuade M, Houghton K. 2005. Use of bisphosphonates in a case of Perthes' disease. *Orthop Nurs* 24:393–398.
- Mickelson MR, McCurnin DM, Awbrey BJ, Maynard JA, Martin RK. 1981. Legg-Calvé-Perthes' disease in dogs: a comparison to human Legg-Calvé-Perthes' disease. *Clin Orthop Relat Res* 157:287–300.

- Moberg A, Rehnberg L. 1992. Incidence of Perthes' disease in Uppsala, Sweden. *Acta Orthop Scand* 63:157–158.
- Molloy MK, Macmahon B. 1967. Birth weight and Legg-Perthes' disease. *J Bone Joint Surg Am* 49:498–506.
- Moseley CF. 1980. The biomechanics of the pediatric hip. *Orthop Clin N Am* 11:3–16.
- Moulton A, Upadhyay S. 1982. A direct method of measuring femoral anteversion using ultrasound. *J Bone Joint Surg Br* 64:469–472.
- Nelitz M, Lippacher S, Krauspe R, Reichel H. 2009. Perthes' disease: current principles of diagnosis and treatment. *Deutsches Ärzteblatt international*. 106:517–523.
- O'Higgins P. 2000. The study of morphological variation in the hominid fossil record: biology, landmarks and geometry. *J Anat* 197:103–120.
- Ogden JA. 1974. Changing patterns of proximal femoral vascularity. *J Bone Joint Surg Am* 56:941–950.
- Osman MK, Martin DJ, Sherlock DA. 2009. Outcome of late-onset Perthes' disease using four different treatment modalities. *J Child Orthop* 3:235–242.
- Osorio H, Schorwer K, Coronado C, Delgado J, Aravena P. 2012. Proximal femoral epiphysis anatomy in Chilean population: orthopedic and forensic aspects. *Int J Morph* 30:258–262.
- Park WM, Kim YH, Kim K, Oh TY. 2009. Non-destructive biomechanical analysis to evaluate surgical planning for hip joint diseases. *Int J Precis Eng Manuf* 10:127–131.
- Perry CA, Taylor JF, Nunn A, Dangerfield PH, Delves H. 2000. Perthes' disease and blood manganese levels. *Arch Dis Child* 82:428–429.
- Perry DC. 2013a. Unravelling the enigma of Perthes' disease. *Ann Roy Coll Surg* 95:311–316.
- Perry DC. 2013b. The epidemiology of Perthes' disease. *Bone Joint J Orthop Br* 95:124–128.
- Perry DC, Bruce CE, Pope D, Dangerfield PH, Platt MJ, Hall AJ. 2011. Perthes' disease: deprivation and decline. *Arch Dis Child* 96:1124–1128.
- Perry DC, Bruce CE, Pope D, Dangerfield PH, Platt MJ, Hall AJ. 2012a. Legg-Calvé-Perthes' disease in the UK: geographic and temporal trends in incidence reflecting differences in degree of deprivation in childhood. *Arthritis and Rheum* 64:1673–1679.
- Perry DC, Bruce CE, Pope D, Dangerfield PH, Platt MJ, Hall AJ. 2012b. Perthes' disease of the hip: socioeconomic inequalities and the urban environment. *Arch Dis Child* 97:1053–1057.
- Perry DC, Green DJ, Bruce CE, Pope D, Dangerfield PH, Platt MJ, Hall AJ, Jones H. 2012c. Abnormalities of vascular structure and function in children with Perthes' disease. *Pediatrics* 130:e126–131.
- Perry DC, Hall AJ. 2011. The epidemiology and etiology of Perthes' disease. *Orthop Clin N Am* 42:279–283.

- Perry DC, Machin DMG, Pope D, Bruce CE, Dangerfield PH, Platt MJ, Hall AJ. 2012d. Racial and geographic factors in the incidence of Legg-Calvé-Perthes' disease: a systematic review. *Am J Epidemiol.* 175:159–166.
- Perthes G. 1910. Uber arthritis deformans juvenilis. *Deutsche Zeitschrift fur Chirurgie.* 107:111–159.
- Pillai A, Atiya S, Costigan PS. 2005. The incidence of Perthes' disease in Southwest Scotland. *J Bone Joint Surg Br* 87:1531–1535.
- Pringle D, Koob TJ, Kim HKW. 2004. Indentation properties of growing femoral head following ischemic necrosis. *J Orthop Res* 22:122–130.
- Purry N. 1982. The incidence of Perthes' disease in three population groups in the Eastern Cape region of South Africa. *J Bone Joint Surg Br* 64:286–288.
- Rab GT, DeNatale JS, Herrmann LR. 1982. Three-dimensional finite element analysis of Legg-Calvé-Perthes' disease. *J Pediatr Orthoped* 2:39–44.
- Ralston E. 1955. Legg-Perthes' disease and physical development. *J Bone Joint Surg Am* 37:647–648.
- Rao BS, Joseph B, Chacko V, Hall AJ. 1995. Altered skeletal growth in Perthes' disease: an anthropometric study of children from rural India. *J Pediatr Orthop Br* 4:91–94.
- Rayfield EJ. 2007. Finite element analysis and understanding the biomechanics and evolution of living and fossil organisms. *Ann Rev Earth Pl Sci* 35:541–576.
- Rayner PHW, Schwalbe SL, Hall DJ. 1986. An assessment of endocrine function in boys with Perthes' disease. *Clin Orthop Relat Res* 209:124–128.
- Reynolds D, Lucas J, Klaue K. 1999. Retroversion of the acetabulum: A cause of hip pain. *J Bone Joint Surg Br* 81:281–288.
- Richmond BG, Wright BW, Grosse I, Dechow PC, Ross CF, Spencer MA, Strait DS. 2005. Finite element analysis in functional morphology. *Anat Rec.* 283:259–74.
- Rowe S-M, Jung S-T, Lee K-B, Bae B-H, Cheon S-Y, Kang K-D. 2005. The incidence of Perthes' disease in Korea: a focus on differences among races. *J Bone Joint Surg Br* 87:1666–1668.
- Ruff CB. 1994. Morphological adaptation to climate in modern and fossil hominids. *Am J Phys Anthrop* 37:65–107.
- Salmaso L, Brombin C. 2013. *Permutation Tests in Shape Analysis, SpringerBriefs in Statistics.* New York: Springer. p 1-95.
- Salmingo RA, Skytte TL, Traberg MS, Mikkelsen LP, Henneberg K, Wong C. 2014. Altered biomechanics of a Perthes' hip investigated by contact modeling. Abstract from 7th World Congress of Biomechanics, Boston, MA, United States.
- Salter RB, Thompson GH. 1984. Legg-Calvé-Perthes' disease. The prognostic significance of the subchondral fracture and a two-group classification of the femoral head involvement. *J Bone Joint Surg Am* 66:479–489.

- Sankar WN, Flynn JM. 2008. Retroversion of the acetabulum: a cause of hip pain. *J Pediatr Orthoped* 28:440–443.
- Sharma S, Sibinski M, Sherlock DA. 2005. A profile of Perthes' disease in Greater Glasgow: is there an association with deprivation? *J Bone Joint Surg Br* 87:1536–1540.
- Shore BJ, Millis MB, Kim YJ. 2012. Vascular safe zones for surgical dislocation in children with healed Legg-Calvé-Perthes' disease. *J Bone Joint Surg Am* 94:721–727.
- Smedley JV, Lomax LG, Williams JF, Barras PW, Hasselschwert DL. 2004. Legg-Calvé-Perthes' disease in a rhesus macaque (*Macaca mulatta*). *Comp Med* 54:585–588.
- Smith AL, Benazzi S, Ledogar JA, Tamvada K, Smith LCP, Weber GW, Spencer MA, Lucas PW, Michael S, Shekeban A, Al-Fadhlah K, Almusallam AS, Dechow PC, Grosse IR, Ross CF, Madden RH, Richmond BG, Wright BW, Wang Q, Byron C, Slice DE, Wood SA, Dzialo C, Berthaume MA, van Casteren A, Strait DS. 2015. The feeding biomechanics and dietary ecology of *Paranthropus boisei*. *Anat Rec* 298:145–167.
- Stuart HC, Pyle SI, Cornoni J, Reed RB. 1962. Onsets, completions, and spans of ossification in the 29 bone-growth centers of the hand and wrist. *Pediatrics* 29:237–249.
- Stulberg SD, Cooperman DR, Wallensten R. 1981. The natural history of Legg-Calvé-Perthes' disease. *J Bone Joint Surg Am* 63:1095–1108.
- Suehiro M, Hirano T, Mihara K, Shindo H. 2000. Etiologic factors in femoral head osteonecrosis in growing rats. *J Orthop Sci* 5:52–56.
- Suehiro M, Hirano T, Shindo H. 2005. Osteonecrosis induced by standing in growing Wistar Kyoto rats. *J Orthop Sci* 10 501–507.
- Tanner J, Whitehouse R, Cameron N, Marshall W, Healy M, Goldstein H. 1976. Assessment of skeletal maturity and prediction of adult height, 2nd ed. London: Academic Press Inc. p 106.
- Tardieu C. 2010. Development of the human hind limb and its importance for the evolution of bipedalism. *Evol Anthropol* 19:174–186.
- Tardieu C, Damsin P. 1997. Evolution of the angle of obliquity of the femoral diaphysis during growth-correlations. *Clin Anat* 19:91–97.
- Terjesen T, Wiig O, Svenningsen S. 2010. The natural history of Perthes' disease. *Acta Orthop* 81:708–714.
- Théron J. 1980. Angiography in Legg-Calvé-Perthes' disease. *Radiology* 135:81–92.
- Thompson A, Leong J, Fung H. 1978. Legg-Calvé-Perthes in southern Chinese children. *J W Pac Orthop* 15:63–69.
- Thompson GH, Salter RB. 1987. Legg-Calvé-Perthes' disease. Current concepts and controversies. *Orthop Clin N Am* 18:617–635.



- Tomita M, Shimokawa I, Maeda H, Higami Y, Kawahara T, Ikeda T, Hirano T. 1999. Dietary restriction reduces the prevalence of osteonecrosis of the caput femoris in spontaneously hypertensive rats. *Calcified Tissue Int* 64:259–262.
- Toogood PA, Skalak A, Cooperman DR. 2009. Proximal femoral anatomy in the normal human population. *Clin Orthop Relat Res* 467:876–885.
- Trueta J. 1957. The normal vascular anatomy of the human femoral head during growth. *J Bone Joint Surg Br* 39:358–394.
- Tucker FR. 1949. Arterial supply to the femoral head and its clinical importance. *J Bone Joint Surg Br* 31:82–93.
- Tutt JFD. 1935. Tuberculosis of the hip joint in a cairn terrier. *Vet Rec* 47:428.
- Ueo T, Tsutsumi S, Yamamuro T, Okumura H 1987. Biomechanical analysis of perthes' disease using the finite element method: the role of swelling of articular cartilage. *Arch Orthop Trauma Surg* 106:202–208.
- Upadhyay SS, Burwell RG, Moulton A. 1986. Femoral anteversion in Perthes' disease with observations on irritable hips. Application of a new method using ultrasound. *Clin Orthop Relat Res* 209:70–76.
- Upadhyay SS, O'Neil T, Burwell RG, Moulton A. 1987. A new method using medical ultrasound for measuring femoral anteversion (torsion): technique and reliability. An intra-observer and inter-observer study on dried bones from human adults. *J Anat* 155:226–232.
- Vasseur PB, Foley P, Stevenson S, Heitter D. 1989. Mode of inheritance of Perthes' disease in Manchester terriers. *Clin Orthop Relat Res* 244:281–292.
- Vaverka M, Navrat T, Vrbka M, Florian Z, Fuis V. 2006. Stress and strain analysis of the hip joint using FEM. *Tech Health Care*. 14:271–279.
- Vila-Verde VM, da Silva KC. 2001. Bone age delay in Perthes' disease and transient synovitis of the hip. *Clin Orthop Relat Res* 385:118–123.
- Vosmaer A, Pereira RR, Koenderman JS, Rosendaal FR, Cannegieter SC. 2010. Coagulation abnormalities in Legg-Calvé-Perthes disease. *J Bone Joint Surg Am* 92:121–128.
- Wang NH, Lee FT, Chin LS, Lo WH. 1990. Legg-Calvé-Perthes' disease: clinical analysis of 57 cases. *J Formosan Med Assoc* 89:764–771.
- Weiner DS, O'Dell HW. 1970. Legg-Calvé-Perthes' disease. Observations on skeletal maturation. *Clin Orthop Relat Res* 68:44–49.
- Wiig O, Terjesen T, Svenningsen S. 2007. Inter-observer reliability of the Stulberg classification in the assessment of Perthes' disease. *J Child Orthop* 1:101–105.
- Wiig O, Terjesen T, Svenningsen S, Lie SA. 2006. The epidemiology and aetiology of Perthes' disease in Norway. A nationwide study of 425 patients. *J Bone Joint Surg Br* 88:1217–1223.
- Wijsekera C. 1984. Perthes' disease in Kurunegala. *Ceylon Med J* 29:65–83.

Winkleby MA, Jatulis DE, Frank E, Fortmann SP. 1992. Socioeconomic status and health: how education, income, and occupation contribute to risk factors for cardiovascular disease. *Am J Public Health* 82:816–820.

Wright DA, Meguid M, Lubovsky O, Whyne CM. 2012. Subchondral bone density distribution in the human femoral head. *Skeletal Radiol* 41:677–683.

Wynne-Davies R, Gormley J. 1978. The aetiology of Perthes' disease: genetic, epidemiological and growth factors in 310 Edinburgh and Glasgow patients. *J Bone Joint Surg Br* 60:6–14.

Yoshida G, Hirano T, Shindo H. 2000. Deformation and vascular occlusion of the growing rat femoral head induced by mechanical stress. *J Orthop Sci* 5:495–502.

Zarco N, Moran J, Hernández M. 2008. Retraso en la madurez esquelética en pacientes mexicanos con Legg-Calvé-Perthes - medigraphic.com. *Acta Ortop Mex* 22:157–161.

Zhang P, Liang Y, Kim H, Yokota H. 2010. Evaluation of a pig femoral head osteonecrosis model. *J Orthop Res* 5:15–21.

Accepted Article



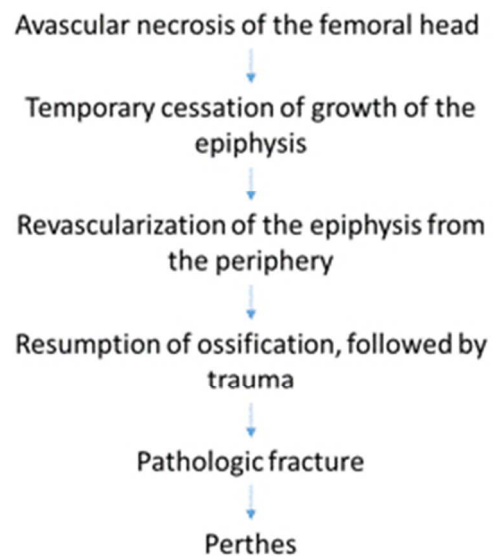


Figure 1: Pathogenesis that leads to Perthes'. Adopted from Fig. 2 in Salter and Thompson (1984) 67x76mm (96 x 96 DPI)

Accepted

## Hypothesis 1

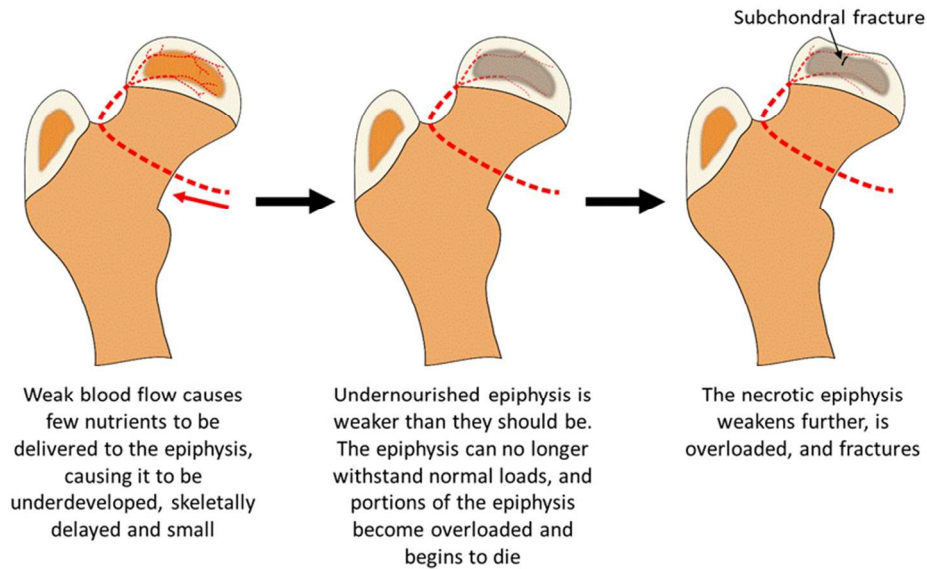


Figure 1: Inadequate blood flow hypothesis, explaining how an individual could develop Perthes' disease. Note: This is femur is of a child, 5-8 years old, who is only receiving blood to the epiphysis from the medial circumflex artery. Therefore, arteries other than the medial cirmcumflex artery are not depicted for clarity.

250x164mm (96 x 96 DPI)

Accept

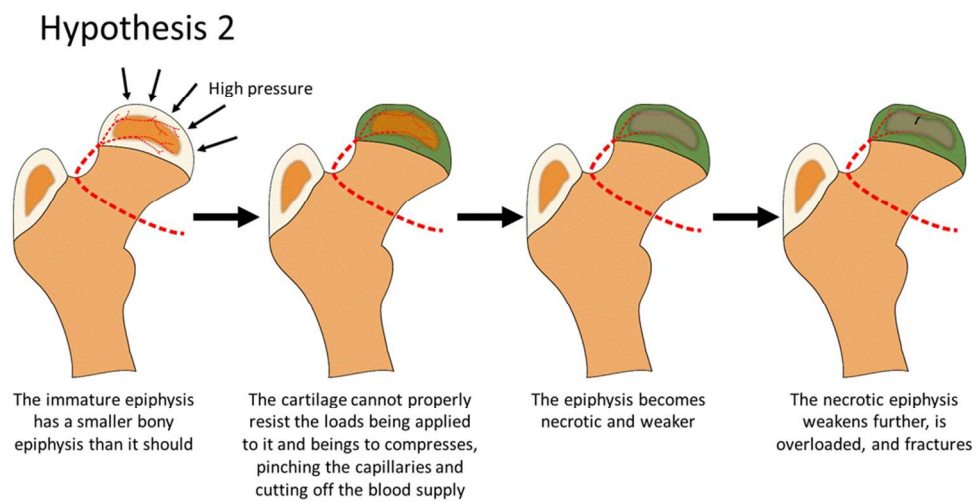


Figure 3: Intraosseous vasculature occlusion hypothesis. The cartilage is depicted as green in the second, third and fourth frames to emphasize it is being compressed.  
300x155mm (96 x 96 DPI)

Accepted

### Hypothesis 3

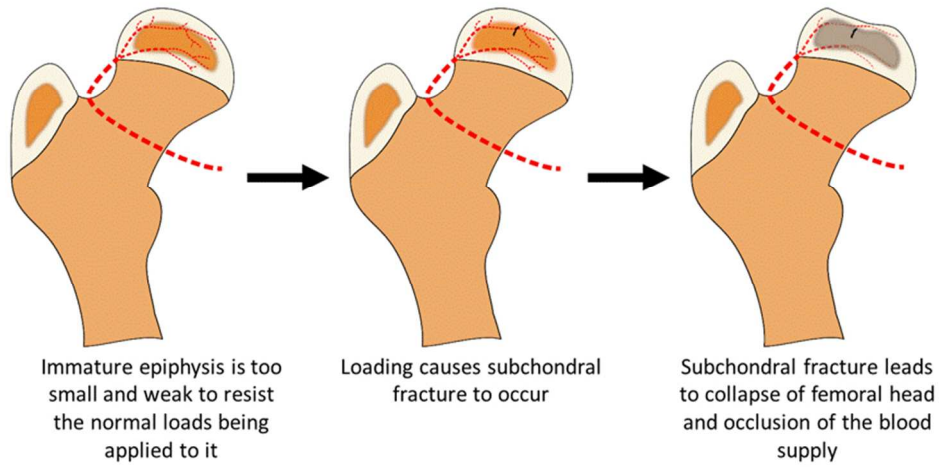


Figure 4: Epiphyseal overloading hypothesis.  
243x141mm (96 x 96 DPI)

Accepted

## Hypothesis 4

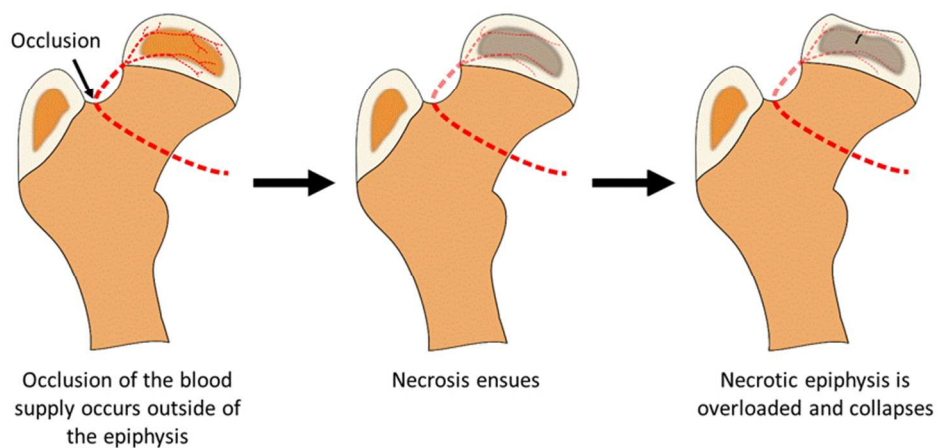
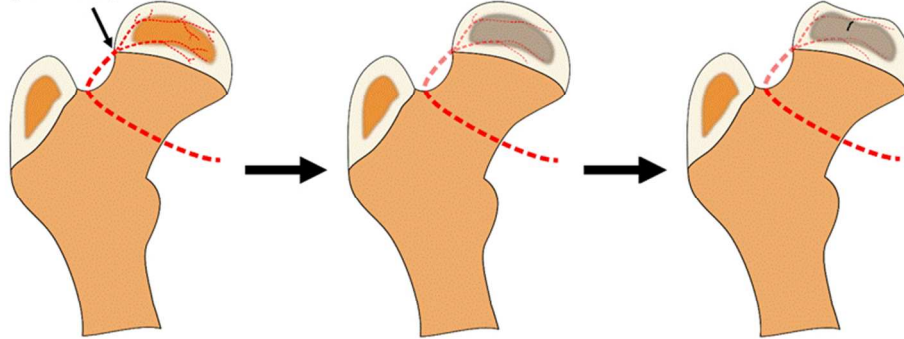


Figure 5: Extra-articular vasculature occlusion hypothesis. Blood supply is occluded outside of the epiphysis. 244x137mm (96 x 96 DPI)

Accepted

## Hypothesis 5

High stresses/strains



The femur and/or acetabulum are shaped in a way that causes high stresses/strains around where the medial circumflex artery enters the epiphysis

High stresses/strains cause occlusion of the blood supply and necrosis

Epiphysis is overloaded and fractures

Figure 6: Extrasosseous vasculature occlusion hypothesis. A morphological change in the femur causes occlusion of the blood supply outside of the epiphysis due to elevated stresses or strains on the epiphysis. 244x151mm (96 x 96 DPI)

Accepte