

# 6. First Evidence for Interpersonal Violence in Ukraine's Trypillian Farming Culture: Individual 3 from Verteba Cave, Bilche Zolote

*Malcolm Lillie, Inna Potekhina, Alexey G. Nikitin and Mykhailo P. Sokhatsky*

---

*This paper presents the initial stages of an interdisciplinary study of human skeletal remains interred at Verteba Cave, western Ukraine. This site has been described previously as a “ritual site of the Trypillian culture complex” by Nikitin et al. (2010), and the material considered here is one of seven crania recovered during excavations at Verteba between 2008 and 2010. Palaeopathological analysis of the individual considered here indicates that this is a young adult female with evidence for peri-mortem injury, cranial surgery and processing for interment. This evidence, together with the burial context itself, provides the first insights into early stage Trypillia culture inter-personal interactions and burial ritual in this region of Ukraine.*

**Keywords:** Violent interactions; Cranial surgery; Body processing

## 1. Introduction

This paper presents the results of recent fieldwork at Verteba Cave in Ukraine (Figure 6.1). This location is a unique site (as outlined below) containing human remains that date to the Eneolithic, and later, periods (Nikitin et al., 2010). The site is located near the town of Bilche Zolote in southwestern Ukraine (Lat: 48.47/Long: 25.53), ca. 460 kilometres (290 miles) southwest of Kiev (Figure 6.1). The cave is an 8,555 metre long gypsum cave located in the Podillya region. Human remains have been excavated at this location since 1876, with more recent work undertaken by a team from the Borschiv Regional Museum, under the directorship of Mykhailo Sokhatsky and colleagues from Grand Valley State University. Absolute dating of disarticulated skeletal material (fourteen elements including a mandible, a number of ribs, vertebrae and a radius) from this cave are primarily dated to the Koshylovetska Trypillian (formally spelled “Trypolie” or “Tripolye”) culture group (dated to phase CII, at ca. 3450–3100 BC) (Nikitin et al., 2010: 11).

Whilst there are intrusive Linearbandkeramik (LBK) farming groups in the territory of Ukraine prior to the establishment of the Trypillian culture, this group represents the subsequent internal development of farming in Ukraine (Videiko, 1994; Zbenovich, 1996; Rassamakin 1999; Manzura 2005). Excavations in Romania have also identified the Cucuteni culture, which is named after the ‘type-site’ for this culture in this country (Zbenovich, 1996: 200). The Cucuteni-Trypillia culture developed through intensive contacts with, and expansion of, Neolithic Balkan-Carpathian agricultural groups (e.g. Körös, Boian, LBK, Hamangia and Petrești) as they expanded northwards into Moldova and Ukraine (Korvin-Piotrovskiy, 2008: 24).

Nikitin et al. (2010) have previously noted that early stage burials/human remains are virtually non-existent until the CII phase of the Trypillia farming culture in the territory of Ukraine; i.e. after ca. 3400calBC (Dergatschov and Manzura, 1991). Indeed, Kruts (2008) reports that only individual finds have been made for the early and

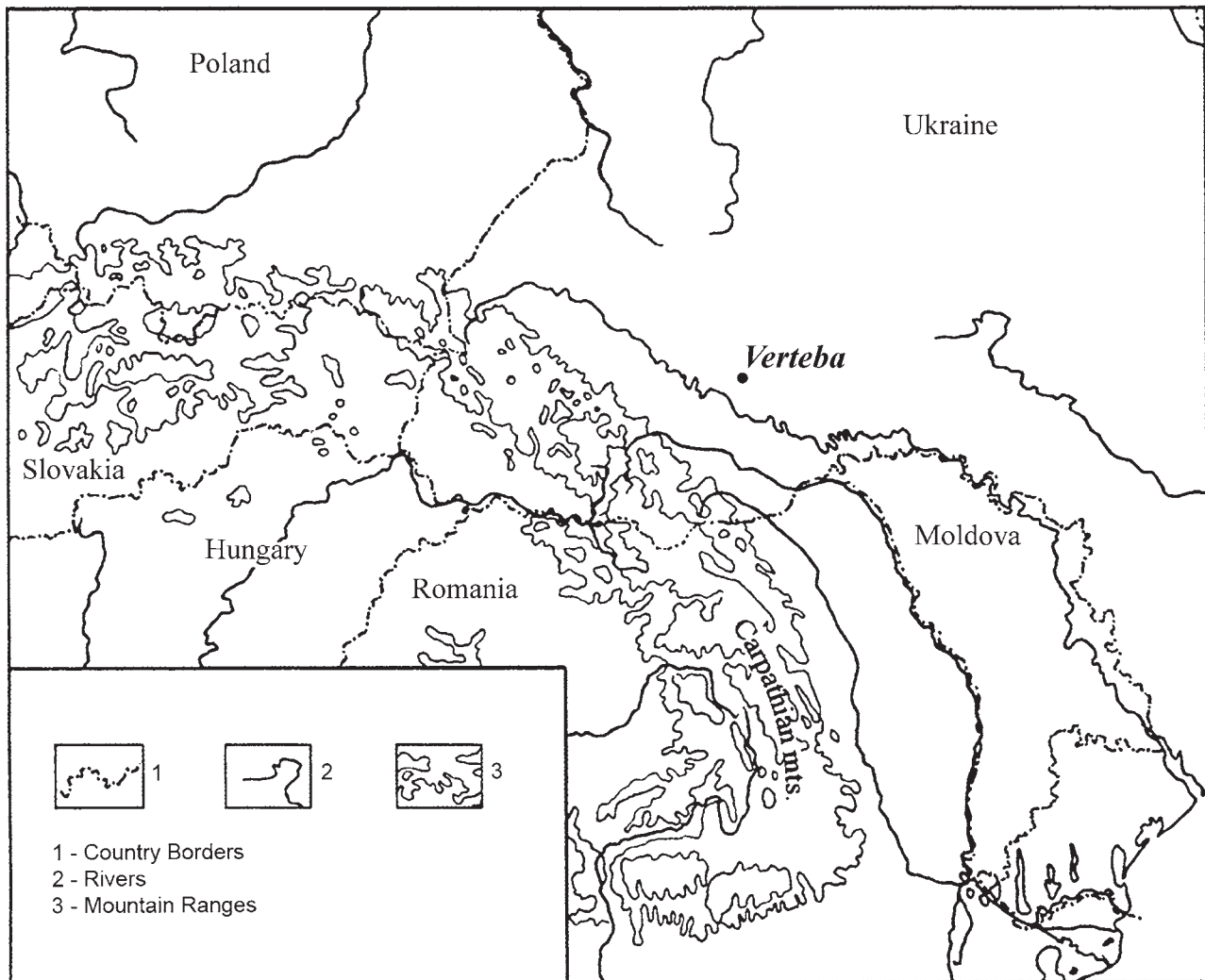


Figure 6.1. Map of the Podillya region with adjacent areas of Ukraine and neighbouring countries showing the approximate location of Verteba Cave (after Nikitin *et al.*, 2008).

middle stage of Trypillia, at sites such as Luka Ustynska, Soloncheny II, Vremye, Nezvysko and Lipkany, and that the majority of these finds are poorly preserved. As such, the dates that have been obtained on disarticulated skeletal elements from cultural horizons at Verteba are of some significance, being earlier in some cases than finds of human skeletal material discovered for the Trypillia culture in Ukraine to date (Nikitin *et al.*, 2010: 9).

The cultural horizons themselves include significant numbers of pottery vessels (including conical dishes, deep bowls, bulging and bi-conical urns, and binocular-shaped vessels), anthropomorphic and zoomorphic figurines, faunal and human remains and charcoal (Nikitin *et al.*, 2010: 13). The matrix of the three cultural horizons in the cave includes loams with gravel, which were probably used to level the cave floor, carbonate clays mixed with charcoal and burnt gypsum, and some burnt wood and lime. Excavations since 1996 have shown that in excess of 1m of sediment has built up in the cave, with *ca.* 64<sup>2</sup>m having been excavated to date, and the existence of sterile

horizons between the occupation debris suggests that there are breaks in the use of the cave (ibid., 2010: 15). To date seven locations within the cave have been excavated, but it should be noted that the areas excavated are near the cave entrance, *ca.* 65m in from the entrance and *ca.* 95m in from the entrance, and that not all areas have continuous deposits in evidence.

## 2. Material and Methods

Analysis of the cranial remains at Verteba followed standard protocols for ageing and sexing as outlined in the literature (e.g. Ferembach *et al.*, 1980; Bass, 1987; Helmuth, 1988; Smith, 1984, 1991; Buikstra and Ubelaker, 1994). We recognise the limitations in ageing and sexing using cranial material, but as no reliable associations with postcranial material were identified during the excavations, or the current study, cranial morphology and dental wear were relied upon in this stage of the analysis.




Figure 6.2. Crania Nest at Verteba Cave: four human crania to the left of the picture with aurochs horn resting on a large stone in the right-centre of image (image courtesy of M. Sokhatsky). Note: Individual 4 was shown to have the mandible in association, and this individual was also distinctive in that the humerus of a young child aged 6mths–1.5 years at death, was placed inside the crania prior to inclusion in the ‘nest’.

All crania were located in close proximity to each other within the cave, with four of the crania located in a ‘nest’ (Figure 6.2) that was located in a niche, or recess, in the cave wall. The niche, which is located at the same level as the cave floor, was further demarcated from the general cave deposits by the construction of a low wall.

The remaining three crania were all located within ca. 1.4m of the ‘nest’ area, and given that access to this cave was unrestricted until recently, it is entirely possible that these crania could have formed part of the original deposit within the ‘nest’. Individual 3 (discussed below) was recovered from the southeastern area of the earlier, 2007, excavations ca. 1.4m from the crania nest. The crania were all analysed by two of us (IP and MCL), and samples were recovered for AMS dating and stable isotope analysis of carbon and nitrogen at the Oxford facility, UK, with samples for strontium isotope analysis recovered for study by Professor Doug Price (Wisconsin). All of the crania have been measured, and recording of the nature of calculus deposition, caries expression (i.e. necrotic pits investigated macroscopically with a dental probe to assess severity of expression) and pathology has been undertaken. The results from the analysis of individual 3 are discussed below.

### 3. Results

Individual 3 (1.2SE) is a female? aged 18–22 (and probably towards the lower end of this range (Ferembach *et al.*, 1980; Bass, 1987). With the exception of damage in the right nasal area (including damage to the upper part of the maxilla, and right lacrimal, and the damage discussed below (and shown in Figure 6.5), the cranium is complete. In the maxillary dentition, the left first premolar, and first to third molars, and the right first premolar and first to third molars are all retained *in situ*, whilst the remainder of the dentition exhibits post-mortem loss (all sockets unremodelled). Both first premolars and first molars show pinpoint dentine exposure, whilst the second and third molars are unworn, with only minor polishing on the second and third molars. The teeth have concretions of material adhering to them, making assessment of calculus deposition difficult to determine with any degree of certainty; this concreted material is probably derived from solution of the gypsum into the cave earth at this location as this precipitate is also visible on the crania from this cave. There is no indication of caries development on any of the preserved teeth of this individual.

The strontium and stable isotope data for diet requires processing, but a preliminary assessment of the data






Figure 6.3. Impact damage on posterior of crania – Individual 3. The black arrows mark the sharp fracture line that is ca. 26mm in length, whilst the aperture is ca. 6mm wide at this point. The area of ‘lost’ vault is marked by the white top arrow which is ca. 15mm from the centre at the bottom left to the centre top right, this area appears to represent peripheral fracturing of the vault away from the main point of impact. The white right arrow marks the edge of the fracture on the right side of the aperture where the vault has been forced inwards by the pressure of the impact. Note calcite formation on vault and areas of damage (image © M. Lillie).

indicates that this individual is local to the region, as the strontium signature is the same as those obtained from pig molars and the other individuals from this cave. The dietary signal is consistent with farming, i.e. terrestrial  $C_3$  diets, in which the associated fauna were not significant in dietary terms, i.e. the majority of the diet of these individuals was cereal-based. The data clearly indicates that this individual was part of a community that was engaged in agro-pastoral farming practices, as would be consistent with the Trypillian culture in this region. However, we should note that at present we are not in a position to assess any freshwater resource contribution to the diet. The AMS dating of this individual indicates an age of 3709–3537calBC (OxA-26202;  $4863 \pm 33$ BP). This age is indicative of stage BII/CI of the Trypillia culture at 3900–3450calBC, making this one of the earliest dates yet obtained for Trypillia culture human remains from the territory of Ukraine.

Individual 3 has evidence for penetrating impact damage on the back of the vault at lambda. In Figure 6.3 it is

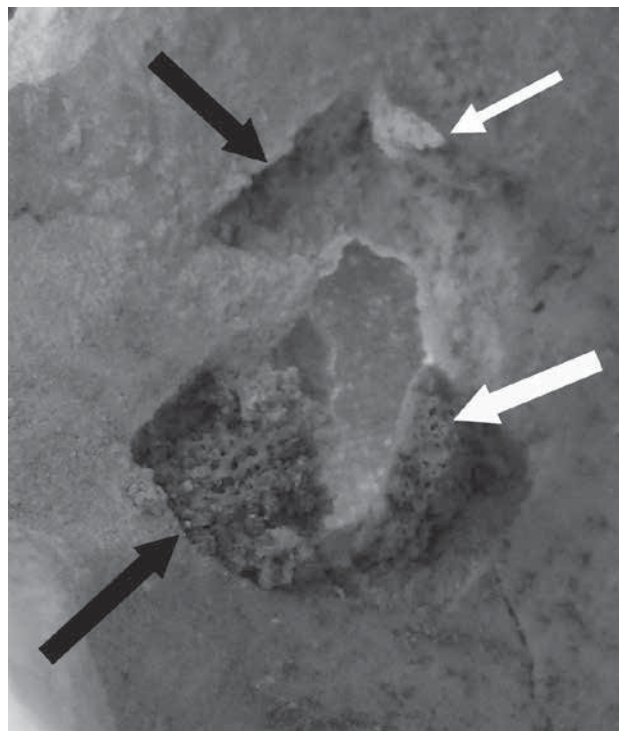


Figure 6.4. Internal view of impact damage on vault of Individual 3. White arrow shows fragments of bone that have been pushed inwards and remain *in situ*. Black arrows show areas where the inner surface of the vault has fragmented away due to impact pressure, and the top of the aperture has a small area of bone forced inwards (top white arrow), and peeling from the inner table of the vault (lower white arrow), indicating a fresh bone fracture (image © M. Lillie).

apparent that the ectocranial surface (outer table) has been forced inwards by the impact, with blunt force compression in evidence and fragmentation of the vault (comminuted fracture); the ectocranial bone can clearly be seen still attached (*in situ*) on the left side of aperture.

In detail, the left side of the impact damage in Figure 6.3 is 26mm in length. At its widest point the entire insult is 32mm from left to right and ca. 38mm from top to bottom. It is difficult to interpret this damage without further study, but the position and structure of the damage would be consistent with a blow delivered from in front, and above of, a person who was kneeling forwards.

Figure 6.4 shows the internal detail of the trauma, with bone pushed inwards from the outer table of the vault in evidence alongside fracturing and ‘peeling’ of the endocranial surface, and loss of bone. The diploë is exposed, or lost, throughout the majority of the circumference of the aperture in the internal region, and the endocranial plate has fragmented away, leaving sharp, well defined edges around the aperture. The internal damage is more pronounced than the external damage (internally the maximum length is ca. 41.6mm and maximum width is ca. 33.2mm). There is no evidence for reactive bone in this area.

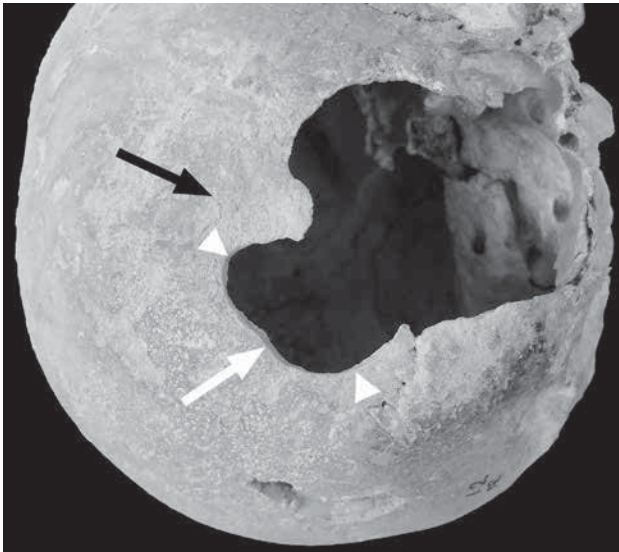


Figure 6.5. Individual 3 Probable trepanation – right side of crania showing sharp edges of aperture that indicate removal of bone (white arrow) and wear/erosion that has occurred in situ (black arrow). Distance between white triangles is 47mm (image © M. Lillie).

At this point it should be noted that there are no signs of bone reaction on this, or any of the other damage discussed in relation to individual 3, and similarly, all of the areas considered in this study were characterised as having exactly the same colour as the rest of the cranium. Furthermore, the calcite concretions in evidence over the surfaces of the vault also occur on all of the edges of the apertures, and other damage in evidence on this cranium.

The cranium of this individual also has evidence for the removal of bone (possible trepanation) from the right side of the vault (Figure 6.5); the fact that this bone removal was peri-mortem in nature is indicated by the very sharp edges to the aperture, visible ‘saw’ marks (although rodent gnawing cannot be discounted until further analysis is undertaken) along the surface of the cut, which are perpendicular to the cranial table throughout the area of the aperture that is preserved, and the fact that the cut edge is the same colour as the remainder of the vault. The only caveat to this observation is that the calcite deposition around and on the edge of the cut obscures any evidence for remodelling of the bone in this area.

The aperture appears to have comprised either two holes (in a figure of eight), or one figure of 8 shaped hole, and is irregular in shape. The edges of the cut are sharp and do not have any evidence for remodelling, perhaps reinforcing the suggested peri-mortem processing of the skull (with the above caveat in place). The absence of the temporal negates the recording of cut marks on this side of the vault (see below).

Cut marks are located on the left side of the vault, superior and posterior to the mastoid process, indicating cutting of the attachments of the neck muscles and tendons



Figure 6.6. Cut marks on the left side of the cranium of individual No. 3 (I.2SE) from Vertebe. Note fresh and sharp appearance of cuts located superior and posterior to the mastoid process indicating the cutting of the attachment of the neck muscles and tendons (in the area of attachment for Sternocleidomastoideus [SCM], Splenius capitis, and Longissimus capitis). The collapse and cracking of the bone (arrowed) indicates that processing occurred peri-mortem whilst the bone was still fresh. The laminar bone in the area of the white arrow has fragmented and fallen away from the vault whilst the bone in the area of the black arrow has remained in situ despite being compressed and fragmenting up from the vault (image © M. Lillie).

in order to detach the head from the body (Figure 6.6). The location of these cuts indicates the severing of the attachment of the neck muscles and tendons (in the area of attachment for Sternocleidomastoideus [SCM], Splenius capitis, and Longissimus capitis). Cut 1 is 27.84mm in length, and there is clear evidence for pressure damage towards the lower part of the incision, suggesting a left to right cutting action. Cut 2 indicates the use of less pressure and is 17.9mm in length, again with increased depth to the lower end of the incision.

As can be seen in Figure 6.6, the bone has clearly fragmented away from the vault (in the area of the white arrow) whilst in the area of the black arrow the pressure of the cut has caused the laminate to buckle upwards. The edges of these cuts are extremely clean and sharp, again suggesting peri-mortem activity. There appear to be suggestions of other cut marks on a number of the crania analysed at Vertebe, but these initial observations will need to be confirmed in the laboratory.

#### 4. Discussion

As the majority of the known burials of the Trypillian culture (over 20 sites to date) are associated with the



Kasperivska group (also known as Gorodsko-Kasperovsky or Gordyneshtsky type), which is dated to phase CII of Trypillia at ca. 3125–2775 BC (Nikitin *et al.*, 2010: 11), the dating of individual 3 to 3709–3537calBC, i.e. stage BII of Trypillia, is of particular significance. Similarly, the range of peri-mortem pathologies in evidence on individual 3 indicate that a combination of inter-personal violence, possible cranial surgery and the processing of this individual (removal of the skull) for inclusion in the burial context has been undertaken (e.g. Šlaus, 1994: 165; Orschiedt *et al.*, 2003; Pfeiffer and van der Merwe, 2004; Facchini *et al.*, 2008). The suggested removal of the crania for inclusion in the burial context would most likely have occurred soon after death, as it is clear from this study that the cut marks were made on fresh bone. The absence of the mandibles would appear anomalous given the removal of the skull as part of the interment ritual, and whilst no explanation is currently forthcoming from the current analysis this clearly warrants further investigation as the study of these deposits progresses.

The impact damage on the back of the crania of Individual 3 is pronounced, and clearly the result of an attack perhaps aimed at causing grievous bodily harm. It is difficult to see how this injury could have occurred accidentally, although of course this scenario cannot be ruled out. The fact that this insult is peri-mortem in nature is reflected in the excellent preservation of the fractured vault pieces *in situ* and the total absence of evidence for remodelling of the vault. In addition to the pain and blood loss that the penetrating injury would entail, the neurological consequences, assuming that death was not immediate, would be considerable, and would have included brain damage as the ecto- and endocranial plates were forced inwards (cf. Orschiedt *et al.*, 2003: 380).

At present we have yet to determine whether the impact damage to the crania of Individual 3 was caused by a stone or metal implement. However, it should be noted at this point that whilst the Trypillian culture is an Eneolithic farming culture, these populations had access to copper metallurgy, so the weapon used to inflict the injury could be either stone or metal (probably an axe in either case). Equally, the knives used in the processing of this individual (Figure 6.6) could have been of either type, and future study of the crania will include microscopic examination and XRF analysis of the cut surfaces to see if traces of copper can be detected, as and when funding allows.

In addition, to the above observations it is worth noting that this population had contacts, trade and exchange relations with contemporary central European groups such as the Tisza-Polgár and Baden culture groups, possibly due to the copper mining activities in the Verteba area (Nikitin *et al.*, 2010: 16; Sokhatskij *et al.*, 2000).

Finally, it is also apparent that the cutmarks on Individual 3 are distinct and lack evidence for re-modelling, indicating immediate post-mortem processing of the remains as part of the burial rituals undertaken by the BII phase Trypillia culture groups in the vicinity of Verteba Cave (Tung, 2008).

After discussions with colleagues during the BABAO conference in Bournemouth the lead author is inclined to consider the sequence of events as potentially comprising the initial violence to the person, causing the penetrating impact damage on the back of the vault. This would undoubtedly have been sufficient to warrant an attempt at intrusive surgery aimed at releasing the pressure that would have resulted from the injury, although initial removal of the impacted bone would have been a logical surgical approach. As such the possible evidence for cranial surgery on the right side of the vault may therefore be related to bone removal for ritual or trophy taking purposes, or both?

Subsequently, as with the other six cranial interred in this area of the cave, individual 3 was processed for inclusion in the burial context via removal of the cranium, as attested by the cut marks visible in Figure 6.6. The lack of evidence for healing of any of these three pathologies suggests that they were both peri-mortem and immediately post-mortem in nature.

## 5. Conclusions

The evidence for peri-mortem injury and surgery, post-mortem processing and the mortuary rituals undertaken on the human remains recorded at Verteba are unique for the Trypillia culture, both in terms of the dating, context, and range of activities in evidence. We are currently in the process of assessing the crania in relation to their anthropological type (craniometrics) and correspondence to the Trypillian culture composition (cf. Kruts, 2008), as the assignment of these crania to the Trypillian culture is currently based on the dating and context of the finds. Given the local strontium signatures and the burial context, this assumption is considered to be realistic at present. The full analysis of the anthropology and palaeopathology of these individuals, along with a consideration of their isotopic characteristics and burial context, is ongoing. However, it is already evident that this site is of considerable significance to our understanding of the early stages of the Trypillia culture farming population in Ukraine and to the elucidation of society in terms of inter-personal violence, possible cranial surgery or the removal of 'discs' as trophies, the processing of human remains in death, and the articulation of burial rites of these early farming groups.

## Acknowledgements

We would like to thank the NERC-AHRC National Radiocarbon Facility (NRCF), Oxford for providing funding for the AMS dating (Project – No. NF/2011/2/18). We would also like to thank Sasha Potekhina for driving us from Kiev to Verteba (ML, IP), no small feat given the distance and condition of the roads in places! Colleagues at Bilche Zolote are also thanked for their help with the fieldwork. Alexey Nikitin and Gwyn Madden, and students from Grand Valley State University, have undertaken

excavations at Verteba since 2008, and the material discussed in this paper comes from a visit undertaken by two of us (IP, ML) in 2011. Funding for the fieldwork was provided by the Wetland Archaeology and Environments Research Centre at the University of Hull. ML would like to thank Chris Knüsel for earlier comments on the pathologies discussed and Chris Meiklejohn (Winnipeg) and Deborah Merrett (SFU) for additional thoughts on this material. As always any errors or omissions rest with the lead author.

Finally, we would like to dedicate this paper to the memory of a number of individuals, who were friends, colleagues and mentors, including; Professor Dimitri Telegin, Professor Marek Zvelebil, Professor Vladimir Timofeev, Professor Pavel Dolukhanov, Dr Ken Jacobs and Dr Roger Jacobi.

## References

- Bass, W.M. 1987. *Human Osteology: A Laboratory and Field Manual*. Archaeology Society, Columbia, MO.
- Buikstra, J.E., Ubelaker, D.H. 1994. *Standards for Data Collection from Human Remains*. Arkansas Archeological Survey Research Series No.44, Fayetteville.
- Dergatschov, V.A., Manzura, I.V. 1991. *Pogrebal'nye komplekсы pozdnego Trypolya (Burial Complexes of the Late Trypillia)*. Shytnytsa, Kishinev.
- Facchini, F., Rastelli, E., Belcastro, M.G. 2008. *Peri mortem* cranial injuries from a Medieval grave in Saint Peter's Cathedral, Bologna, Italy. *International Journal of Osteoarchaeology* 18, 421–430.
- Ferembach, D., Schwidetzky, I., Stloukal, M. 1980. Recommendations for age and sex diagnosis of skeletons. *Journal of Human Evolution* 9, 517–549.
- Helmuth, H. 1988. *A Laboratory Manual in Physical Anthropology*. Canadian Scholar's Press, Toronto.
- Korvin-Piotrovskiy, O.H. 2008. Trypillian culture in Ukraine, in: Ciuk, K. (Ed.), *Mysteries of Ancient Ukraine: the Remarkable Tripilian Culture 5400–2700 BC*. Royal Ontario Museum, Canada, pp. 22–31.
- Kruts, S.I. 2008. Anthropological composition of the Trypillian population, in: Ciuk, K. (Ed.), *Mysteries of Ancient Ukraine: the Remarkable Tripilian Culture 5400–2700 BC*. Royal Ontario Museum, Canada, pp. 55–57.
- Manzura, I. 2005. Steps to the steppe: Or, how the North Pontic region was colonised. *Oxford Journal of Archaeology* 24, 313–338.
- Nikitin, A.G., Sokhatsky, P., Kovaliukh, M.M., Videiko, M.Y. 2010. Comprehensive site chronology and ancient mitochondrial DNA analysis from Verteba Cave – a Trypillian culture site of Eneolithic Ukraine. *Interdisciplinaria Archaeologica: Natural Sciences in Archaeology* 1, 9–18.
- Orschiedt, J., Häußer, A., Haidle, M.N., Alt, K.W., Buitrago-Téllez, C.H. 2003. Survival of a multiple skull trauma: The case of an Early Neolithic individual from the LBK enclosure at Herxheim (Southwest Germany). *International Journal of Osteoarchaeology* 13, 375–383.
- Pfeiffer, S., van der Merwe, N.J. 2004. Cranial injuries to Later Stone Age children from the Modder River Mouth, Western Cape Province, South Africa. *South African Archaeological Bulletin* 59, 59–65.
- Rassamakin, Y. 1999. The Eneolithic of the Black Sea steppe: Dynamics of cultural and economic development 4500–2300 BC, in: Levine, M., Rassamakin, Y., Kislenko, A., Tatarintseva, N. (Eds.), *Late Prehistoric Exploitation of the Eurasian Steppe*. McDonald Institute Monographs, Cambridge, pp. 59–182.
- Šlaus, M. 1994. Osteological evidence for peri-mortem trauma and occupational stress in two Medieval skeletons from Croatia. *Collegium Anthropologicum* 18, 165–75.
- Smith, B.H. 1984. Patterns of molar wear in hunter-gatherers and agriculturalists. *American Journal of Physical Anthropology* 63, 39–56.
- Smith, B.H. 1991. Standards of human tooth formation and dental age assessment, in: Kelley, M.A., Larsen, C.S. (Eds.), *Advances in Dental Anthropology*. Wiley Liss, New York, pp. 143–68.
- Sokhatskij, M., Klochko, V., Manichev, V., Kvasnista, V., Kozak, S. and L. Demchenko. 2000. Issues concerning Tripolye metallurgy and the virgin copper of Volhynia. *Baltic-Pontic Studies* 9, 168–186.
- Tung, T.A. 2008. Dismembering bodies for display: A bioarchaeological study of trophy heads from the Wari site of Conchopata, Peru. *American Journal of Physical Anthropology* 136, 294–308.
- Videiko, M.Y. 1994. Tripolye – “Pastoral” contacts, facts and character of the interactions: 4800–3200 BC. *Baltic-Pontic Studies* 2, 5–28.
- Zbenovich, V.G. 1996. The Tripolye culture: Centenary of research. *Journal of World Prehistory* 10, 199–241.

---

# 7. Beheading at the Dawn of the Modern Age: The Execution of Noblemen during Austro-Ottoman Battles for Belgrade in the late 17th century

*Nataša Miladinović-Radmilović and Vesna Bikić*

---

*The early modern history of Belgrade, Serbia, was marked by battles between the Ottoman and Habsburg empires, but also by extensive reshaping of the fortress and the town. The changes that Belgrade underwent are attested by rescue excavations on the Rajičeva Street site outside the fortress walls. Trench 12 was particularly interesting to archaeologists and anthropologists. A single location yielded five bodiless skulls. All belonged to males, aged between 20 and 45 years of age. All showed decapitation marks, apparently caused by a sword cut at the level of cervical vertebrae (C2, C3 and C4), except one, inflicted at the lower third of the occipital bone and severing part of the right mastoid process. There was no evidence that the heads had been publicly displayed, except in one case, where both the skull base and C1 had suffered additional violent injuries when impaled. The skulls had probably been carefully disposed of after the execution, as evidenced by the presence of mandibles and anatomic connection of cervical vertebrae which had not yet succumbed to postmortem decomposition. From all available data, the interrelationship of 'burials' and structural remains, and coin finds, the beheading may be placed between 1688 and 1717.*

**Keywords:** Perimortem injuries; Sharp blade cut marks; Decapitation

## 1. Introduction

Beheading was widely considered the severest penalty imposed only for the most serious crimes, such as an act of treason against a state or a sovereign. Unfailingly ending in death, it is a method of execution, not of torture. In some societies, such as England, beheading with a sword or an axe was considered an honourable death and was reserved for the nobility, whereas commoners and the poor were more often sentenced to death by hanging (Daniell, 1997). At the dawn of the modern age this form of capital punishment was in use in the Ottoman Empire as well (Wiltschke-Schrotta and Stadler, 2005: 58–59). Sporadic information has come down to us from European diplomatic travellers visiting the Balkans in the 16th and 17th centuries. Some of them claimed to have seen severed heads of spies put on public display as a deterrent to others (Levental, 1989: 61). The most gruesome of such accounts is certainly that of the execution of Nicolas Doxat de

Morez, the Austrian army colonel and military engineer who served as head of the Construction Department in Austrian-held Belgrade in 1723–36 (Leben des Herren Baron Doxat von Morez, 1757: viii–xii; Popović, 2006: 219–242). For the abortive defence and surrender of the fortress of Niš to the Ottomans, he was sentenced to death by beheading and executed in Belgrade, not far from the fortress: 'The headsman, who showed up in the meantime, struck an unfortunate blow, which cut too deep into his shoulder, and he tumbled off the chair without letting out a slightest scream. On the ground, it was only the fourth blow that cut off his head' (Leben des Herren Baron Doxat von Morez, 1757: 65–67).

Although material evidence for such executions is seldom found, there are examples from virtually all periods of the past (Harman *et al.*, 1981; Wells, 1982; Anderson, 2001; Walker, 2001: 588–590; Wiltschke-Schrotta and Stadler, 2005). To the best of our knowledge, one such



skull was archaeologically recovered from the area just outside the southeast fortress wall, but it has not received due attention because of an unclear find context (a levelling layer).<sup>1</sup> Yet, the find-spot seems to suggest that the head was put on display, possibly at the top of the fortress wall. The five skulls presented here are the only archaeological discovery from this period in the Balkans to date attesting to the death penalty by beheading. In addition to blade cut marks on the bones, which permit reconstruction of the beheading technique, its significance resides in a clear and well-defined context.

### 1.1 Context of the Discovery

The location of Rajićeva Street site is significant in itself (Figure 7.1a), because it is an area outside the line of fortifications which had a somewhat different development from the fortress through the stages of Belgrade's urban transformation from the time of Roman dominance (2nd–4th c.) until the 19th century. In view of the stratigraphy of the site, we focused on the last Austro-Ottoman horizon. It began with the Ottoman conquest of Belgrade in 1521 and lasted practically until the final Ottoman withdrawal in 1867. Especially dynamic was the period between the 1690s and the late 18th century, marked by Austro-Ottoman wars and extensive reshaping of the fortress and the town. The extent and nature of these changes is clear from the surviving siege and rebuilding plans (Škalamera, 1973a, 1973b, 1973c, 1975a, 1975b, 1975c, 1975d, 1975e, 1975f), and largely attested by archaeological excavations. In that sense, the archaeological context of the discovery is substantiated by those archival sources.

The rescue excavations conducted in 2004 uncovered the skulls (G 20–24, i.e. Nos. 1–5) and nine skeletons in the Austro-Ottoman layer, which, in that part of the site, overlies a late Roman street that led from the Roman castrum to the civilian settlement. The skulls were grouped together and, as it appeared at the moment of discovery, three were laid on the left cheek and two on the right, with two of the five partially overlying each other (Figure 7.1b). In their immediate vicinity were nine skeletons, six male and three female, of different ages. Apparently, the bodies had simply been laid on the ground (no burial pits were identified) and variously orientated, though mostly northeast to southeast and west to east; in addition, four male skeletons (G 13–16) were strangely intertwined. This cluster of osteological remains was dated by the coins found in the layer, the youngest of which was a Ragusan coin of 1684.

The five skulls and nine skeletons were disturbed and partly damaged by the foundation wall of a later building, which, judging from the surviving plans of the fortress and town of Belgrade, could have been either of the following two barracks: Austrian Builders' (*Maurer*) Barrack, built in 1727 to accommodate the engineer units engaged in construction work on the fortress and around the town (Škalamera, 1975c: 23–25), or Ottoman Sipahi Cavalry Barrack, built on the site of the former, which had been

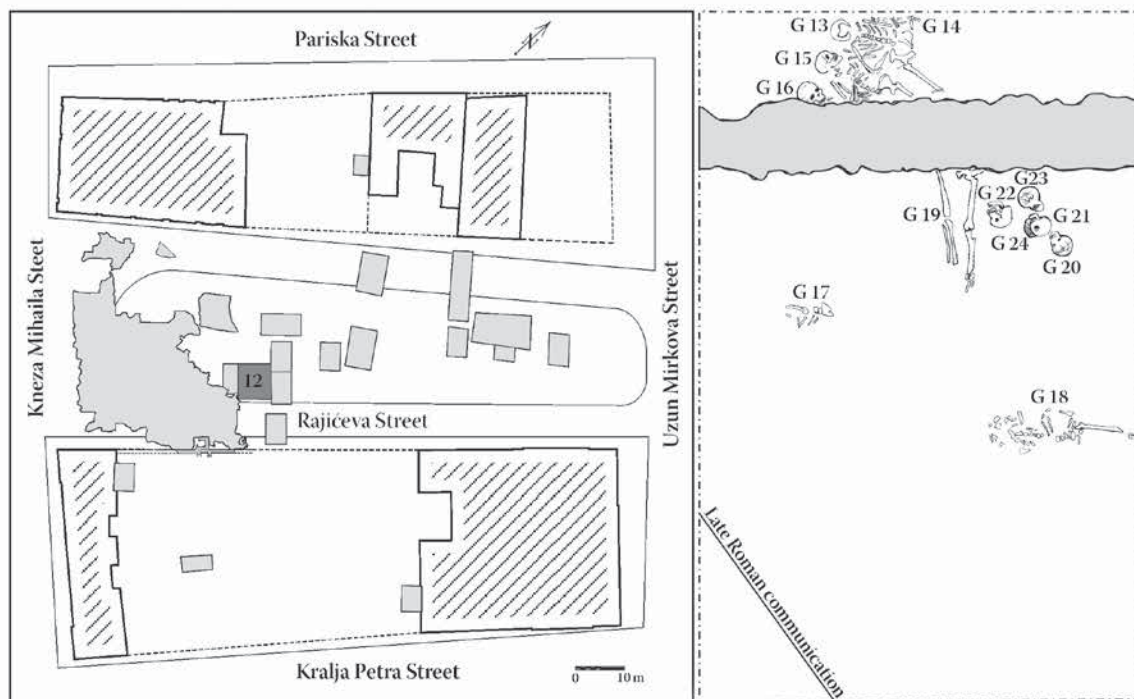
razed to the ground after the Ottoman takeover of Belgrade in the autumn of 1739 (Škalamera, 1975d). Judging by the construction method and size of the building, we are inclined to identify it as the Ottoman Sipahi Barrack.

The approximate date and circumstances of the 'burial', however, can be assumed from the analysis of historical plans with high certainty. Of relevance to establishing the terminus post quem are the plans from the period of Austro-Ottoman wars (1688–1690) and the ensuing Ottoman reshaping of the town (1690–1717). The oldest plan (1688) shows on this site a musalla – an enclosed open air area for prayer – and, around it, a large cemetery (*Orta mezarlik*) for Muslim soldiers killed in the battle for Belgrade in 1521 (Škalamera, 1975a: 18–21). Excavations in the east zone of the site unearthed a part of this cemetery with individual and communal burials, and fragments of three Islamic grave markers. However, the cluster of skulls within the former musalla enclosure indicates that they could not have been buried there until after the prayer space was abandoned or demolished, which may be related to the Austrian capture of Belgrade in 1688 (Škalamera, 1975b: 22). On the other hand, the terminus ante quem would be the Austrian reshaping of Belgrade that began in 1717. From all available data, the interrelationship of osteological and structural remains, and coin finds, the date of the beheading may be limited to a period between 1688 and 1717.<sup>2</sup>

### 2. Materials and Methods

This paper will be confined to the anthropological analysis of the five skulls (Nos. 1–5, Table 7.1). In determining the sex of the beheaded individuals, we focused on morphological features of the cranium (*glabella*, *planum nuchale*, *processus mastoideus*, *processus zygomaticus*, *arcus superciliaris*, *protuberantia occipitalis externa*, *os zygomaticum*, *tubera frontale et parietale*, *os frontale* slope angle, *margo supraorbitalis* and shape of *orbitae*) and mandible (general appearance: *corpus mandibulae*, *ramus mandibulae* and *angulus mandibulae*; *mentum*, *angulus mandibule* and *margo inferior*), using the method established by a group of European anthropologists (Ferembach *et al.*, 1980: 523–524) and Buikstra and Ubelaker (1994: 19–21). Age estimation tools used were the changes on the occlusal surfaces of all teeth according to Lovejoy's scoring of age-related occlusal wear (Lovejoy, 1985).<sup>3</sup>

All necessary measurements for calculating cranial and mandibular indices were made (Bass, 1995).<sup>4</sup> Cranial and mandibular metrical elements and indices are presented in Table 7.2 for each skull. On teeth, mesiodistal and buccolingual diameters were measured and they are presented in Table 7.3 as recommended by Hillson (1990: 240–242, 1996: 80–82). Dental analyses (Tables 7.4–7.6), palaeopathological analyses and observation of non-metric variations (Table 7.7) were also conducted.



a



b

Figure 7.1. a) Location of Rajičeva street site, with find-spot of skulls (drawing: N. Lazarević). b) Skulls during excavation (photo: S. Pop-Lazić).



Table 7.1. Inventory of preserved bones.

PRESERVED BONES OF CRANIAL SKELETON	G 20	G 21	G 22	G 23	G 24
Frontal bone	75–100%	75–100%	75–100%	75–100%	50%
Right parietal bone	75–100%	75–100%	75–100%	75–100%	75–100%
Left parietal bone	75–100%	75–100%	75–100%	75–100%	75–100%
Right temporal bone	75–100%	almost 100%	75–100%	75–100%	75–100%
Left temporal bone	75–100%	100%	75–100%	100%	50–75%
Occipital bone	75–100%	100%	75–100%	75–100%	75–100%
Right mastoid process	100%	100%	75–100%	100%	100%
Left mastoid process	100%	100%	100%	100%	100%
Right zygomatic bone	100%	100%	-	100%	-
Left zygomatic bone	100%	100%	75–100%	100%	50%
Hyoid bone	50–75%	-	-	-	-
Skull bone fragments	-	-	6	15	27
Fragments of skull base bones	31	36	42	19	51
Maxilla	75%	75–100%	50%	75%	75–100%
Mandible	75–100%	75–100%	75–100%	75–100%	75–100%
POSTCRANIAL SKELETON					
C1	3 fragments	100%	fragment	fragment	100%
C2	dens missing	50–75%	-	100%	75–100%
C3	almost 100%	-	-	100%	-
C4	-	-	-	75%	-

### 3. Results

#### *Skull No. 1 (G 20)*

Skull No. 1 belonged to a male aged 30–45 (Tables 7.1–7.7).

Sharp force traumata consistent with decapitation are observable on C3 (Figures 7.2a and 7.2c) and the right gonion (Figures 7.2b and 7.2c). The cut on C3 only nicked the *processus articularis inferior* on the right side, while affecting on the left side *processus articularis inferior*, *arcus vertebrae* (*processus spinosus* is completely missing) and *corpus vertebrae* (at an angle of 30° to the vertical of the spinal cord).

Another observable palaeopathological change is an osteoma of 0.6 cm diameter in the middle of the frontal bone above the glabellar region.

#### *Skull No. 2 (G 21)*

Skull No. 2 belonged to a male aged 20–24 (Tables 7.1–7.7).

The left parietal bone shows two incidences of sharp force trauma: one that almost bisected the bone (downward blow at an angle of 80°, Figure 7.3b), the other parallel to the lambdoid suture (angle of 45°) (Figure 7.3a).

Sharp force trauma consistent with decapitation is observable on the left gonion (downward blow at an angle of 65°, Figure 7.3c) and C2 (Figure 7.3d). The body of C2 is bisected at an angle of 43° to the vertical of the spinal cord (Figure 7.3e).

Other palaeopathological changes are an injury with associated infection in the *spina nasalis* area, and an anomaly in the development of the atlas (*foramen arteriae vertebralis* instead of *sulcus*).

#### *Skull No. 3 (G 22)*

Skull No. 3 belonged to a male aged 25–35 (Tables 7.1–7.7).

Sharp force trauma is observable on the frontal bone (downward blow at an angle of 8°) and both parietals (downward blow at an angle of 25°) (Figures 7.4a and 7.4b). They were apparently inflicted by a person standing at the victim's right side, in two consecutive actions of the same hand. As both injuries could have been fatal, the beheading presumably took place shortly afterwards.

Sharp force traumas consistent with decapitation occur on the occipital bone, base of the skull and right mastoid process (Figures 7.4c–f).

Other palaeopathological changes are three antemortem blunt force injuries: of the frontal and left parietal bone (both 0.5 cm in diameter), and of the occipital bone (1 × 3 cm).

#### *Skull No. 4 (G 23)*

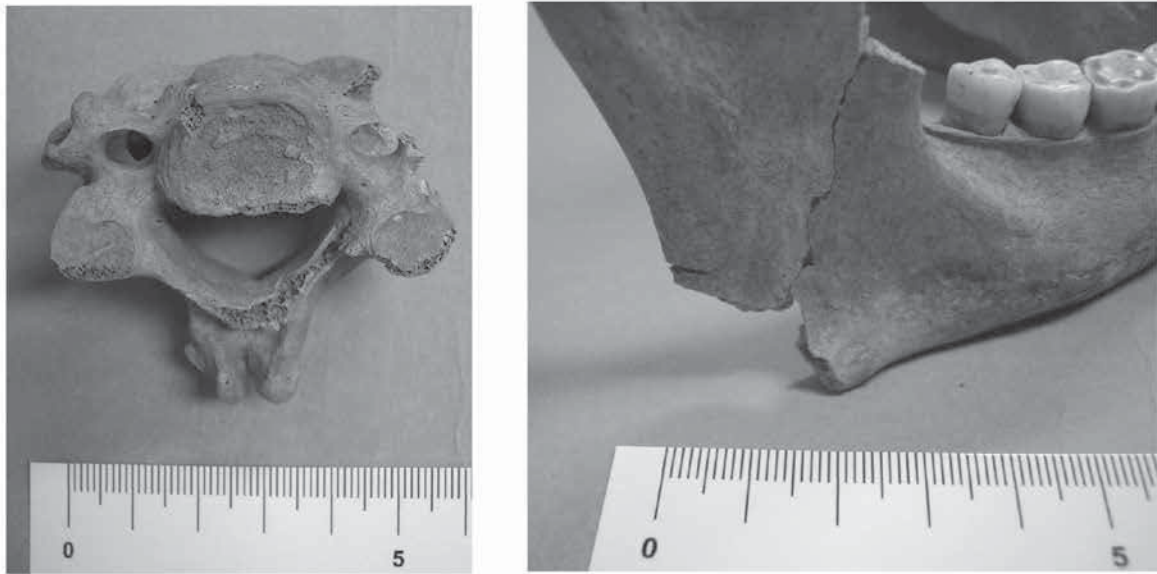
Skull No. 4 belonged to a male aged 20–30 (Tables 7.1–7.7).

There is sharp force trauma on the frontal bone (blow delivered from left to right by a right-handed person standing in front of the victim) and in the middle of the zygomatic arch (upward blow, leaving a nearly horizontal mark) (Figures 7.5a and 7.5b). Although severe, these injuries, inflicted in two consecutive actions of the same hand, should not have been fatal. Presumably, the decapitation was carried out shortly afterwards.

Sharp force trauma consistent with decapitation occurs on the fourth cervical vertebra (Figures 7.5c and 7.5d).

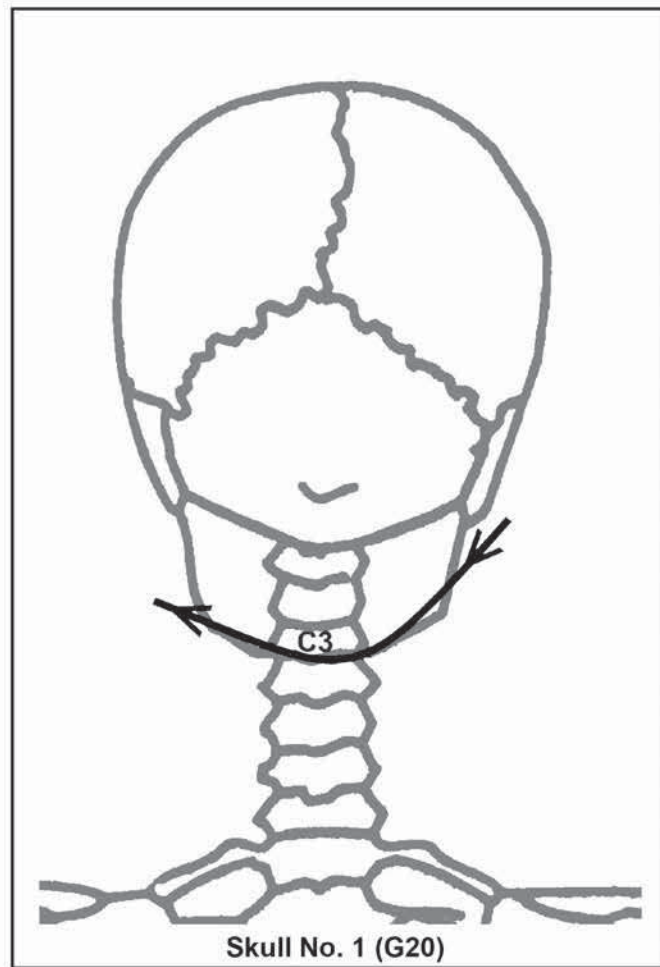
Another observable palaeopathological change is an antemortem blunt force injury (0.7 cm in diameter) of the frontal bone 2 cm from the bregma (Figure 7.5a).





a

b



c

Figure 7.2. a) Sharp force trauma consistent with decapitation on third cervical vertebra. b) Sharp force trauma consistent with decapitation on right gonion. c) Reconstruction of decapitation technique.

Table 7.2 Cranial measurements and indices

CRANIAL SKELETON (cm)	G 20		G 21		G 22		G 23		G 24	
Primal cranial measurements										
Maximum cranial length (g-op)	18.20		17.90		18.20		17.50		-	
Maximum cranial breadth (eu-eu)	14.50		13.80		13.50		14.60		13.00	
Basion/bregma height (b-ba)	-		14.80		13.40		-		-	
<i>Cranial Index</i>	79.67		77.09		74.17		83.42		-	
<i>Cranial Length-Height Index</i>	-		82.68		76.37		-		-	
<i>Cranial Breadth-Height Index</i>	-		107.24		87.15		-		-	
<i>Mean Basion-Height Index</i>	-		93.37		84.81		-		-	
<i>Cranial module</i>	-		15.50		15.20		-		-	
Porion-bregma height	11.65		11.70		12.35		11.95		9.40	
Basion-porion height	-		-		-		-		-	
<i>Mean Porion-Height Index</i>	71.25		73.81		77.91		74.45		-	
<i>Index of Flatness of the Cranial Base</i>										
Minimum frontal breadth (ft-ft)	9.30		9.50		-		9.20		-	
<i>Fronto-Parietal Index</i>	64.14		68.84		-		63.01		-	
Basion-prosthion length	-		-		-		-		-	
Basion-nasion length	-		-		-		-		-	
<i>Prognathic Index</i>	-		-		-		-		-	
Facial skeleton										
Total facial height (n-gn)	11.20		12.50		12.25		-		-	
Upper facial height (n-alveolar)	6.80		7.80		7.55		-		-	
Facial width or bizyg. breadth (zy-zy)	12.80		13.00		-		-		-	
<i>Total Facial Index</i>	87.50		96.15		-		-		-	
<i>Upper Facial Index</i>	53.12		60.00		-		-		-	
Nose										
Nasal height (n-ns)	5.40		-		5.15		-		-	
Nasal breadth (al-al)	2.30		2.55		2.30		2.40		2.30	
<i>Nasal Index</i>	42.59		-		44.66		-		-	
Orbits										
Orbital height	R	L	R	L	R	L	R	L	R	L
	3.55	3.55	3.30	3.00	-	3.40	-	-	-	-
Orbital breadth (mf-ec)	-		3.90		-		4.25		-	
<i>Orbital Index</i>	-		91.02		-		80.00		-	
Maxilla										
Maxilloalveolar length (pr-alv)	-		-		-		-		-	
Maxilloalveolar breadth (ecm-ecm)	-		-		-		-		-	
<i>Maxilloalveolar Index</i>	-		-		-		-		-	
Palate										
Palatal length	6.40		6.30		6.05		6.40		6.00	
Palatal breadth	-		-		-		-		-	
<i>Palatal Index</i>	-		-		-		-		-	
Mandible										
Mandible length	10.40		11.20		11.60		10.40		10.60	
Bicondylar breadth (cdl-cdl)	-		12.15		12.05		-		12.00	
Bigonial breadth (go-go)	10.70		10.90		11.00		11.45		-	
Height of ascending ramus	7.80		7.50		7.10		7.10		-	
Minimum breadth of ascending ramus	3.20		3.25		3.05		3.20		3.15	
Height of mandibular symphysis (gn-idi)	2.80		3.20		3.05		3.15		3.05	
Thickness of mandibular body	0.85		1.10		1.10		1.25		0.85	
Height of mandibular body	2.90		3.40		3.10		3.05		2.75	
<i>Mandibular Index</i>	-		92.18		96.26		-		88.33	
<i>Mandibular Body Robusticity Index</i>	29.31		32.35		35.48		40.98		30.90	
<i>Mandibular Ramus Index</i>	41.02		43.33		42.95		45.07		-	
<i>Frontomandibular Index</i>	86.91		87.15		-		80.35		-	

### Skull No. 5 (G 24)

Skull No. 5 belonged to a male aged 20–30 (Tables 7.1–7.7).

Sharp force trauma consistent with decapitation occurs on the right gonion (Figures 7.6c and 7.6d) and C2 (Figures 7.6a, 7.6b and 7.6c).

### 4. Discussion

Even though our analysis was limited by the fact that the postcranial skeletons were missing,<sup>5</sup> it was possible to verify the archaeologists' assumption about execution by beheading, and to reconstruct the individual acts of decapitation. What happened to their bodies remains

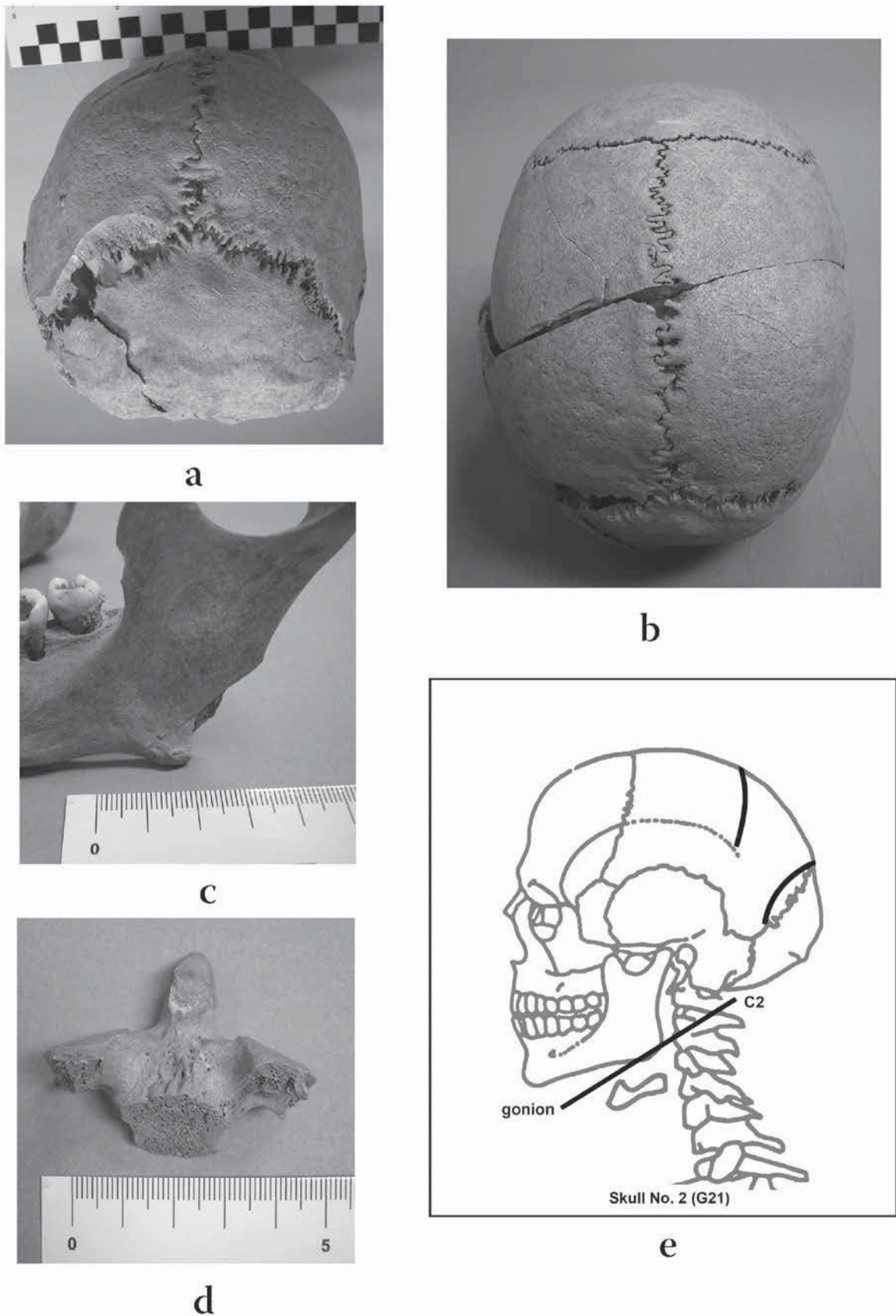


Figure 7.3. a, b) Perimortem sharp blade injuries to left parietal bone. c) Sharp force trauma consistent with decapitation on left gonion. d) Sharp force trauma consistent with decapitation on second cervical vertebra. e) Reconstruction of decapitation technique.



Table 7.3 Odontometric data

Odontometric data (diameter in cm)										
Maxilla	G 20		G 21		G 22		G 23		G 24	
Tooth	diameter		diameter		diameter		diameter		diameter	
	M/L	VB/L	M/L	VB/L	M/L	VB/L	M/L	VB/L	M/L	VB/L
11	postm. loss		0.90	0.80	0.80	0.75	postm. loss		0.90	0.80
12	0.60	0.60	0.70	0.70	0.65	0.60	postm. loss		postm. loss	
13	0.75	0.80	0.80	0.95	0.75	0.85	0.70	0.85	0.75	0.90
14	0.65	0.85	0.65	0.95	0.65	0.90	0.60	0.90	0.75	1.05
15	0.60	0.80	0.70	0.85	0.65	0.90	0.60	0.90	0.60	1.00
16	0.90	1.00	1.00	1.20	0.95	1.10	1.00	1.05	1.00	1.10
17	0.85	0.95	0.95	1.20	0.85	1.10	0.85	1.10	0.90	1.15
18	0.80	0.90	0.90	1.00	0.90	0.90	0.90	1.10	0.95	1.15
21	postm. loss		0.95	0.80	0.80	0.75	postm. loss		0.90	0.80
22	postm. loss		0.70	0.65	postm. loss		postm. loss		0.75	0.70
23	postm. loss		0.80	0.90	0.75	0.85	postm. loss		0.75	0.85
24	0.65	0.85	0.70	0.95	0.65	0.90	0.60	0.85	0.70	1.00
25	0.60	0.80	0.70	0.90	0.60	0.90	0.60	0.90	0.65	1.00
26	0.95	0.95	1.05	1.15	0.95	1.20	0.95	1.10	1.00	1.20
27	0.80	0.95	0.85	1.15	0.80	1.10	0.85	1.05	0.90	1.10
28	0.70	0.95	0.80	1.10	0.85	1.05	postm. loss		0.90	1.15

Odontometric data (diameter in cm)										
Mandibula	G 20		G 21		G 22		G 23		G 24	
Tooth	diameter		diameter		diameter		diameter		diameter	
	M/L	VB/L	M/L	VB/L	M/L	VB/L	M/L	VB/L	M/L	VB/L
31	0.50	0.60	0.55	0.65	0.50	0.55	0.50	0.60	0.55	0.70
32	0.55	0.70	0.60	0.75	0.55	0.65	0.55	0.65	0.65	0.60
33	0.60	0.80	0.65	0.75	0.65	0.80	0.60	0.80	0.70	0.80
34	0.65	0.65	0.70	0.75	postm. loss		0.65	0.70	0.70	0.80
35	0.65	0.75	0.75	0.85	0.70	0.80	0.65	0.70	0.70	0.85
36	0.95	0.90	1.10	1.05	1.00	1.00	1.05	1.00	1.05	1.05
37	0.95	0.95	1.10	caries	0.95	0.95	1.05	1.00	0.95	1.00
38	0.95	0.90	1.10	1.10	0.95	0.90	1.00	1.00	1.00	1.05
41	root		0.60	0.70	0.50	0.55	0.50	0.55	0.55	0.65
42	0.55	0.65	0.60	0.75	0.55	0.65	0.60	0.65	0.60	0.65
43	0.60	0.75	0.75	0.85	0.65	0.80	0.65	0.75	0.70	0.80
44	0.60	0.65	0.65	0.75	0.65	0.75	0.70	0.70	0.70	0.80
45	0.60	0.75	0.75	0.90	0.65	0.80	0.65	0.75	0.65	0.90
46	0.90	0.90	caries		1.00	1.00	root		1.00	1.05
47	0.85	0.90	antem. loss		0.95	0.95	1.00	1.00	1.05	1.00
48	0.90	0.85	caries		1.00	0.95	1.00	0.95	1.00	1.00

unknown; they were probably buried or disposed of elsewhere. Some other important questions also remain unanswered: were the victims restrained, and were the fatal injuries of victims G 21 and G 22 inflicted only to the cranial skeleton, in what order were they executed, etc.?

The sharp force injuries to the skulls are very similar to cut marks left by swords (Lewis, 2008). In our view, however, such entrance and exit angles can only be produced by a bladed weapon similar to the sword but slightly curved and thinner and therefore more manoeuvrable (Figures 7.2c, 7.3e, 7.4f, 7.5d and 7.6d); in other words, the sabre. Incidentally, the sabre was a widely used weapon in the Balkans from the 16th through the 20th century (Šercer, 1979; Milosavljević, 1993).

Victim G 20 was probably kneeling, his back to the executioner and facing the 'public'. If so, the executioner must have been right-handed (Figure 7.2c). The sabre went downward, nicked the right gonion at an angle of

55° and in its upward arc sliced the lower left part of C3 at an angle of 30°.

Victim G 21 had suffered two lethal injuries to the left parietal bone from a sharp-edged weapon, probably a sabre, by a person standing above him or at his left side. The victim was either killed or knocked unconscious, and thus his head had to be laid down on a block, on its right side, and was severed with a single blow (Figure 7.3e).

Victim G 22 had also sustained two fatal injuries, one to the frontal, the other to both parietal bones, and was either killed instantly or lost consciousness. Hence, as in the previous case, his head was propped up on a support, sideways on the left cheek, and severed probably using the usual technique. What is intriguing in this particular case are perimortem sharp blade injuries on the occipital bone inflicted immediately after the beheading (first blow at an angle of 45°, second at 10°, and third, affecting almost the entire base of the skull, at an angle less than 10°). The



a



b



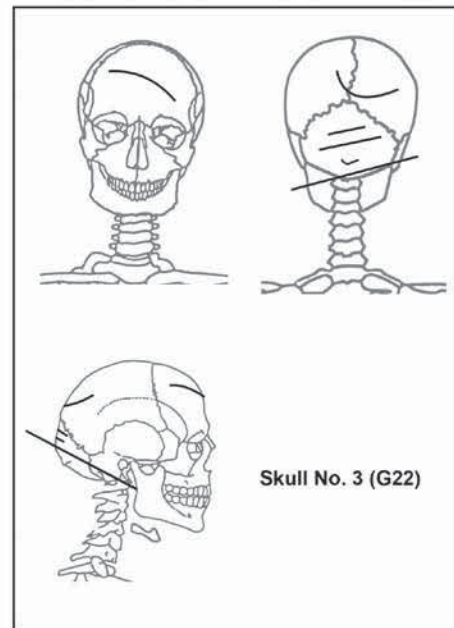
c



d



e



f

Figure 7.4. a) Perimortem sharp blade injury to frontal bone. b) Perimortem sharp blade injury to both parietals. c, d, e) Few perimortem sharp blade injuries consistent with decapitation to occipital bone. f) Reconstruction of decapitation technique.

Table 7.4 Caries

Caries (diameter in cm)					
Maxilla					
Tooth	G 20	G 21	G 22	G 23	G 24
11	-	-	-	-	-
12	-	-	-	-	-
13	-	-	-	-	-
14	-	-	-	-	-
15	-	-	-	-	-
16	-	spot (L)	-	-	-
17	-	-	-	-	-
18	-	3 spots (O)	-	-	-
21	-	-	-	-	-
22	-	-	-	-	-
23	-	-	-	-	-
24	-	-	-	-	-
25	-	spot (O)	-	-	-
26	-	spot (L)	-	-	-
27	0.25 (D) <sup>1</sup>	-	-	-	-
28	5 spots (O) and 0.30 (M)	spot (O)	spot (B)	-	-
Caries (diameter in cm)					
Mandibula					
Tooth	G 20	G 21	G 22	G 23	G 24
31	-	-	-	-	-
32	-	-	-	-	-
33	-	-	-	-	-
34	-	-	-	-	-
35	-	-	-	-	-
36	-	2 spots (O)	-	-	-
37	-	0.80 (gross; O/B)	-	-	-
38	-	0.30 (O)	-	-	-
41	-	-	-	-	-
42	-	-	-	-	-
43	-	-	-	-	-
44	-	-	-	-	-
45	-	-	-	-	-
46	0.30 (D)	gross gross	-	-	-
47	0.30 (M)	-	-	-	-
48	-	gross-gross	-	-	-

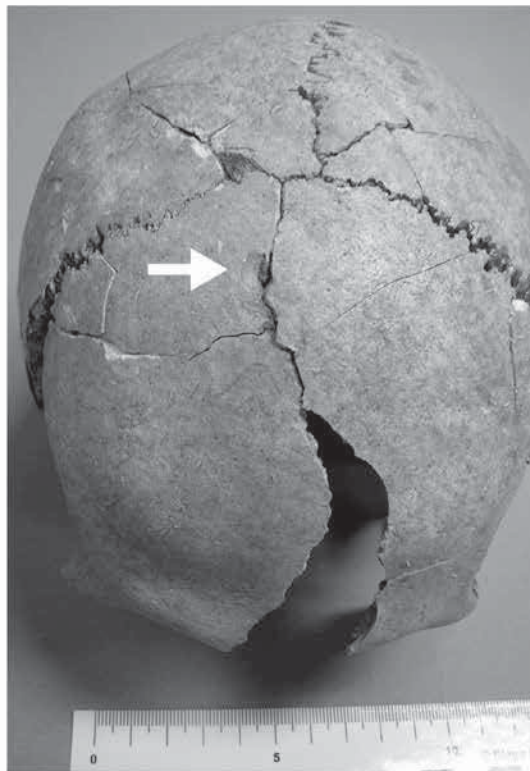
<sup>1</sup> All caries lesions are on the crowns (O – occipital; M – mesial; D – distal; L – lingual; B – buccal), except, of course, gross caries (O/B – occluso-buccal) and gross-gross caries. ‘Gross caries’ is the term used to describe a lesion that has grown to the point that it includes several possible sites of initiation, and, therefore, its original site cannot be determined. ‘Gross gross’ carious cavity, involving the loss of so much of the tooth that it is not possible to determine whether the lesion was initiated in the crown or root, and there is a clear opening into an exposed pulp chamber or root canal (Hillson 2001).

Table 7.5 Dental diseases

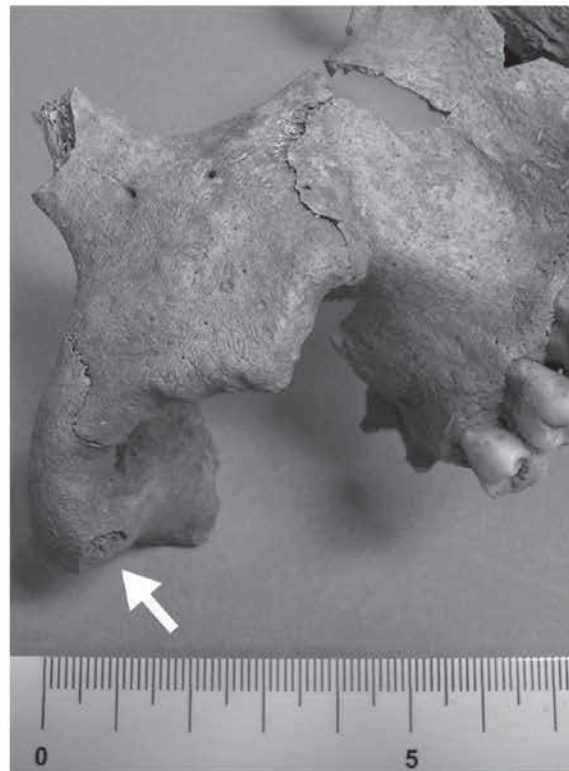
Dental diseases present	G 20	G 21	G 22	G 23	G 24
Maxilla					
Hypoplasia <sup>1</sup>	medium	considerable	medium	slight→medium	medium
Periodont. disease	medium	medium→consider.	medium→consider.	medium→consider.	slight
Calculus	slight	medium→consider.	medium→consider.	slight→medium	-
Periapical abscesses	-	-	-	-	-
Mandibula					
Hypoplasia	medium	considerable	medium	slight→medium	medium
Periodont. disease	medium	medium→consider.	medium→consider.	medium→consider.	slight
Calculus	medium	medium→consider.	slight	slight→medium	medium
Chronical periapical abscesses	-	37 (B: 0.4 cm) and 46 (B: 0.6 cm)	-	46 (B: 0.5 cm)	-

<sup>1</sup> Scoring for hypoplasia, periodontal disease and calculus is taken from Brothwell (1981: 155 and 156).

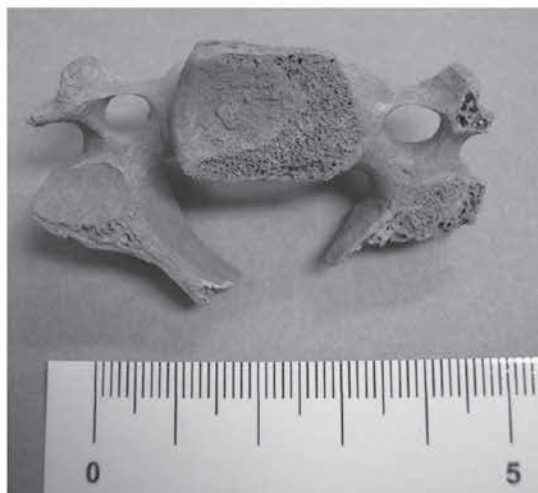



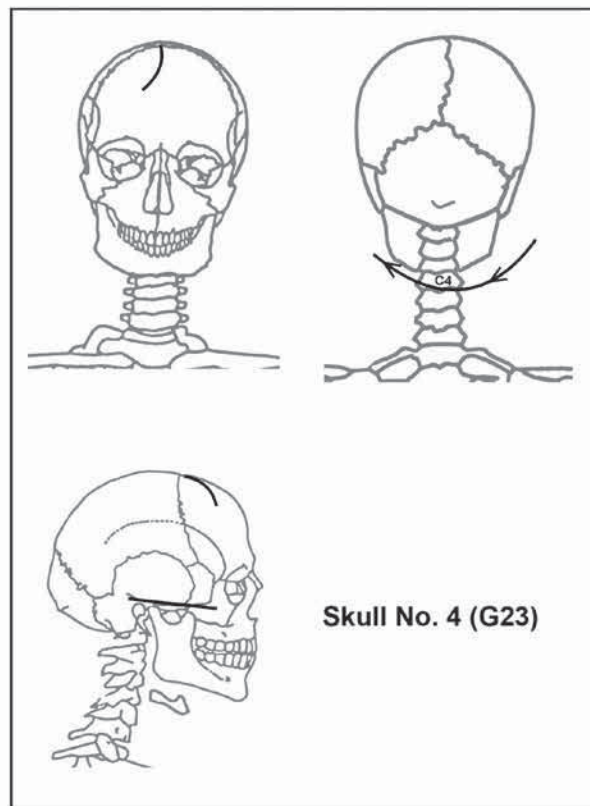
a



b



c



d

Figure 7.5. a) Blunt force injury to frontal bone. b) Perimortem sharp blade injury to zygomatic arch. c) Sharp force trauma consistent with decapitation on fourth cervical vertebra. d) Reconstruction of decapitation technique.

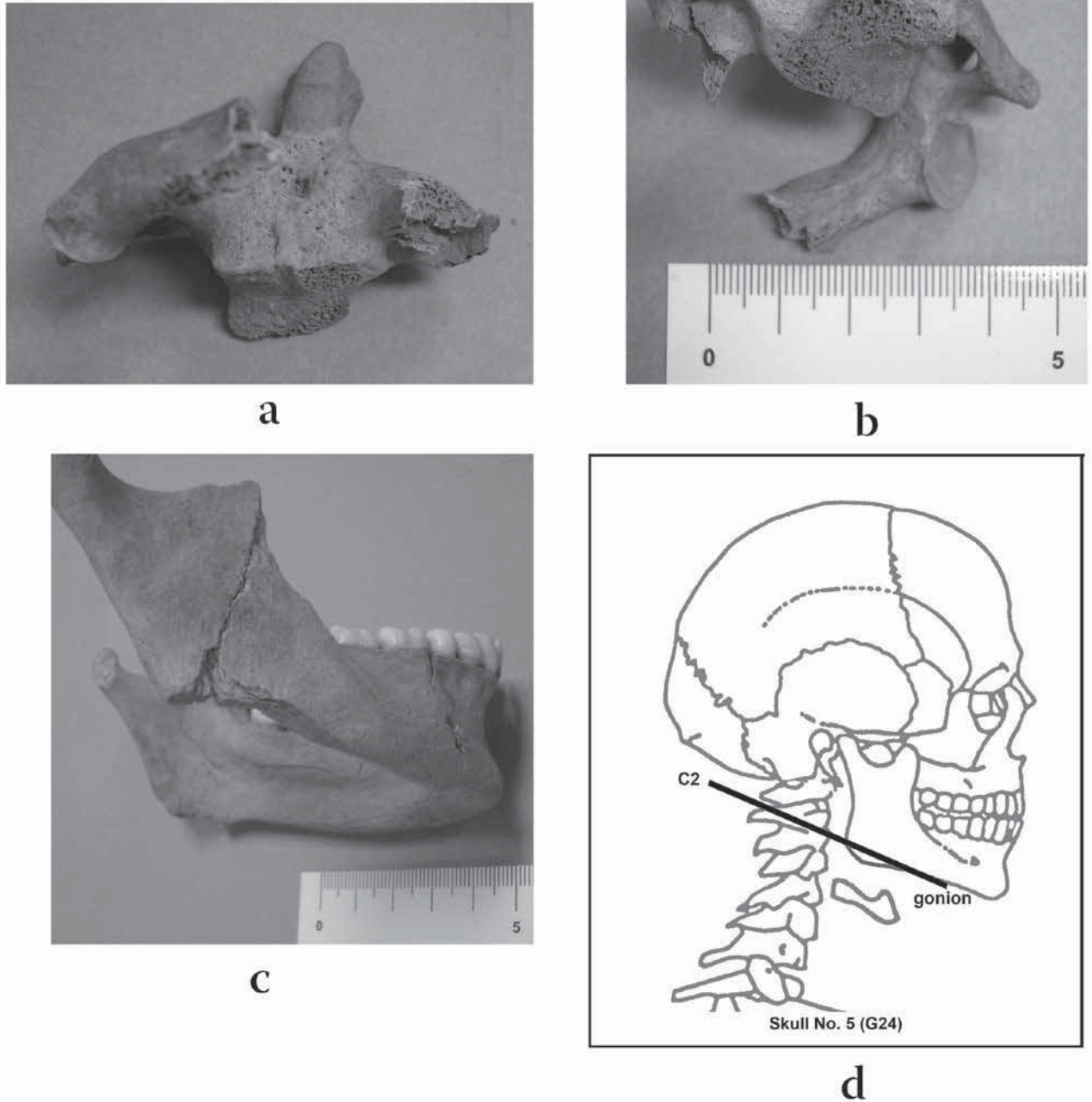


Figure 7.6. a, b) Sharp force trauma consistent with decapitation on second cervical vertebra. c) Sharp force trauma consistent with decapitation on right gonion. d) Reconstruction of decapitation technique.

Table 7.6 Anomalies of teeth and occlusion

Anomalies of teeth and occlusion present	G 20	G 21	G 22	G 23	G 24
Anomalies of teeth					
Maxilla					
Rotation of teeth	14, 15, 24 and 26	-	-	-	-
Mandible					
Rotation of teeth	-	-	41	-	-
Occlusion	edge-to-edge	protrusion	edge-to-edge	edge-to-edge	protrusion

Table 7.7 Non-metric variations

Non-metric variations <sup>1</sup> present	G 20	G 21	G 22	G 23	G 24
<i>Sulci frontales</i>	one on the right side	one on the right side	-	-	-
<i>Foramen infraorbitale accessorium</i>	-	three on the left side	two on the left side	-	-
<i>Ossa suturae lambdoideae</i>	-	-	one on the right and two on the left side	two on each side (d= 0.5 × 0.8 cm)	-
<i>Linea nuchae suprema</i>	prominent	-	-	prominent	-
<i>Foramen zygomaticofaciale</i>	two on each side	-	two on the left side	two on the right side	two on the left side
Trace expression of the squamo-mastoid suture	on both sides	-	-	-	-

<sup>1</sup> Observation of non-metric variations is according to Hauser and De Stefano (1989).

purpose of these blows might have been to make it ‘easier’ to set the head upon a stake for public display. This is the only skull that shows evidence of further violent penetration of the base of the skull when impaled (Figures 7.4c and 7.4e). The head may not have been displayed for very long, considering that the mandible and the fragment of the atlas (probably somehow left stuck in the base of the skull) remained attached to the head with the surrounding soft tissues.

Victim G 23 was beheaded in the ‘regular’ way. The injuries inflicted with a sharp blade prior to beheading were not fatal. The person was probably on his knees, with the executioner standing behind him. The sabre, swung in a semi-arc from right to left, affected only the lower left side of the body (at an angle of 10°) and inferior articular process of the fourth cervical vertebra. The force of the blow sliced off the *arcus vertebrae* and *processus spinalis* (Figure 7.5d).

Victim G 24 was probably kneeling, facing the ‘public’, while the executioner, undoubtedly right-handed, was standing behind him (Figure 7.6d). The sabre was swung downward, first cutting the right gonion at an angle of 10°, and then the lower right part of C2 at an angle of 20°. Considering the markedly high decapitation location, the head may have also been propped up sideways on its left cheek.

## 5. Conclusion

The nature of the find, above all the severed heads, and the find-spot lead us to think of a punishment imposed for wartime crimes, such as mutiny, espionage or treason. Such an assumption is suggested by the numerous perimortem injuries probably sustained in a head-to-head battle that had preceded the beheading, and by the public display of one of the heads. The large number and severity of injuries in one case (No. 3) suggests that this individual may have been the prime culprit, possibly the leader of a mutiny, as additionally corroborated by the fact that this is the only head that was

publicly displayed. It seems reasonable to assume that the execution of the five persons took place during the Austro-Ottoman wars of the late 17th century, most likely during the Ottoman recapture of Belgrade in 1690.

The heads were probably disposed of shortly after the execution, as evidenced by the presence of mandibles and anatomic connection of cervical vertebrae as yet unaffected by postmortem decomposition. Moreover, they were neatly arranged, which suggests a measure of respect for the executed. The form of punishment suggests distinguished civilians or high-ranking militaries. That they indeed were notable and well off is indicated by their healthy and well-kept teeth (no lifetime tooth loss). Dental analyses have shown very low levels of tooth wear (even considering their relatively young adult age) and caries. The only exception is skull No. 2 with a few carious teeth and one tooth lost antemortem (probably also due to caries). All this indicates well-fed individuals and a diet rich in proteins of animal origin (Larsen, 1999: 76–77).

The skeletons discovered in the immediate vicinity, however, call for a different interpretation. The absence of burial pits, and the orientation and partial intertwinement of the bodies suggest that they were simply dumped in the ground, possibly out of a cart; which was not an uncommon treatment of the urban poor, as evidenced by recent archaeological excavations in Sremska Mitrovica (Miladinović-Radmilović, 2011a: 138–177, 2011b). Hence, the ‘burial’ of noblemen, or rather the disposal of their remains (bodiless heads), with the urban poor would not have merely been an act of denigration commensurate with the crime they had been punished for, but the effacement of the fact that they had ever existed; a sad wartime occurrence in all times and places in human history.

## Acknowledgements

This paper is a result of the project *Urbanization processes and development of medieval society* (No. 177021) funded by the Ministry of Education, Science and Technological



Development of the Republic of Serbia. We express our gratitude to Mr Miro Radmilović for the reconstruction drawings of the beheadings made according to our observations, to our colleague Neda Dimovski (Municipal Museum, Subotica) for her expert assistance, to the student Dragica Bizjak for assistance in preparing the osteological material for analysis and useful suggestions, and to Marina Adamović Kulenović for translating the text.

## Notes

1. Information contained in the excavation records of the Institute of Archaeology, Belgrade/Belgrade Fortress Research Project.
2. We were not in a position to carry out AMS dating because these skulls are unique archaeological samples and therefore the preparation of bone sections was not allowed.
3. It is known that this method is not population specific and this must be taken into consideration during the age estimation of different populations particularly in archaeological investigations. Since the preparation of bone sections was not allowed, we could not use the method of root dentine translucency for age estimation. On the other hand, pulp/tooth area ratio as an indicator of age is quite a new method for age estimation, which requires a radiographic image of an examined tooth, computer-aided drafting software and trained personnel. Unfortunately, this method was too expensive and we were not able to perform such age assessments.
4. Regrettably, as can be seen in Figure 7.1b, only the bones of a single skull (No. 1) are not deformed by soil pressure.
5. Apart from a few cervical vertebrae.

## References

- Anderson, T. 2001. Two decapitations from Roman Towcester. *International Journal of Osteoarchaeology* 11, 400–405.
- Bass, W.M. 1995. *Human Osteology: A Laboratory and Field Manual*. Missouri Archaeological Society, Columbia, MO.
- Brothwell, D.R. 1981. *Digging Up Bones: The Excavation, Treatment and Study of Human Skeletal Remains*, 3rd edition. British Museum (Natural History), London and Oxford University Press, Oxford.
- Buikstra, J.E., Ubelaker, D.H. 1994. *Standards for Data Collection from Human Skeletal Remains*. Arkansas Archeological Survey Research Series No. 44, Fayetteville.
- Daniell, Ch. 1997. *Death and Burial in Medieval England 1066–1550*. Routledge, London and New York.
- Ferembach, D., Schwidetzky, I., Stloukal, M. 1980. Recommendations for age and sex diagnosis of skeletons. *Journal of Human Evolution* 7, 517–549.
- Harman, M., Molleson, T.I., Price, J.L. 1981. Burials, bodies and beheading in Romano-British and Anglo-Saxon cemeteries. *Bulletin of the British Museum of Natural History – Geology* 35(3), 145–188.
- Hauser, G., De Stefano, G.F. 1989. *Epigenetic Variants of the Human Skull*. E. Schweizerbart'sche Verlagsbuchhandlung, Stuttgart.
- Hillson, S. 1990. *Teeth*. Cambridge University Press, Cambridge.
- Hillson, S. 1996. *Dental Anthropology*. Cambridge University Press, Cambridge.
- Hillson, S. 2001. Recording dental caries in archaeological human remains. *International Journal of Osteoarchaeology* 11, 249–289.
- Larsen, C.S. 1999. *Bioarchaeology: Interpreting Behavior from the Human Skeleton*. Cambridge University Press, Cambridge.
- Leben des Herren Baron Doxat von Morez 1757 – Leben des Kaiserlichen Generals und berühmten Ingenieurs Herren Baron Doxat von Morez, Welcher Anno 1738. den 20sten Martii zu Belgrad enthauptet worden, nebst besondern Umständen des damaligen Türken-Krieges, 1757/ Život carskog generala i slavnog inženjera gospodina barona Doksata de Moreza pogubljenog 20. marta 1739. u Beogradu, uz opis pojedinih dešavanja u tadašnjem ratu protiv Turaka, 1757. Biblioteka grada Beograda, Belgrade 2006.
- Levental, Z. 1989. *Britanski putnici u našim krajevima od sredine XV do početka XIX veka*. Dečje novine, Gornji Milanovac.
- Lewis, J.E. 2008. Identifying sword marks on bone: criteria for distinguishing between cut marks made by different classes of bladed weapons. *Journal of Archaeological Science* 35, 2001–2008.
- Lovejoy, C.O. 1985. Dental wear in the Libben Population: Its functional patterns and role in the determination of adult skeletal age at death. *American Journal of Physical Anthropology* 68, 47–56.
- Miladinović-Radmilović, N. 2011a. *Sirmium – Necropolis*. Arheološki institute, Belgrade and Blago Sirmijuma, Sremska Mitrovica.
- Miladinović-Radmilović, N. 2011b. Exostoses of the external auditory canal. *Starinar* LX/2010, 137–146.
- Milosavljević, B. 1993. *Mačevi u zbirniku Vojnog muzeja XIV–XX veka*. Vojni muzej, Beograd.
- Popović, M. 2006. *Beogradska tvrđava*, 2nd revised edition. Javno preduzeće Beogradska tvrđava, Belgrade.
- Šercer, M. 1979. *Sablje*. Povijesni muzej Hrvatske, Zagreb.
- Škalamera, Ž. 1973a. Planovi Beograda iz 1688. godine. *Urbanizam Beograda* 20, 15–18.
- Škalamera, Ž. 1973b. Planovi barokne rekonstrukcije Beograda iz 1717–1740. godine. *Urbanizam Beograda* 23, 13–18.
- Škalamera, Ž. 1973c. Planovi Beograda iz 1789. godine. *Urbanizam Beograda* 24, 19–24.
- Škalamera, Ž. 1975a. Područje Knez Mihailove ulice u osmanlijskom šehru Beogradu od 1521. do 1688. godine, in: *Knez Mihailova ulica, zaštita nasleđa, uređenje prostora*. Belgrade, Galerija Srpske akademije nauka i umetnosti 26, pp. 18–21.
- Škalamera, Ž. 1975b. Područje Knez Mihailove ulice od 1688. do 1717. godine, in: *Knez Mihailova ulica, zaštita nasleđa, uređenje prostora*. Galerija Srpske akademije nauka i umetnosti 26, Belgrade, p. 22.
- Škalamera, Ž. 1975c. Područje Knez Mihailove ulice u doba barokne rekonstrukcije Beograda 1718–1740. godine, in: *Knez Mihailova ulica, zaštita nasleđa, uređenje prostora*. Galerija Srpske akademije nauka i umetnosti 26, Belgrade, pp. 23–27.
- Škalamera, Ž. 1975d. Područje Knez Mihailove ulice u drugoj polovini XVIII veka i početkom XIX veka, in: *Knez Mihailova ulica, zaštita nasleđa, uređenje prostora*. Galerija Srpske akademije nauka i umetnosti 26, Belgrade, pp. 28–31.
- Škalamera, Ž. 1975e. Područje Knez Mihailove ulice za vreme Prvog srpskog ustanka, in: *Knez Mihailova ulica, zaštita nasleđa, uređenje prostora*. Galerija Srpske akademije nauka i umetnosti 26, Belgrade, p. 32.
- Škalamera, Ž. 1975f. Područje Knez Mihailove ulice u prvoj fazi razvoja prestonice Kneževine Srbije od 1815. do 1867.

- godine, in: *Knez Mihailova ulica, zaštita nasleđa, uređenje prostora*. Galerija Srpske akademije nauka i umetnosti 26, Beograd, pp. 33–39.
- Wiltschke-Schrotta, K. and Stadler, P. 2005. Beheading in Avar times (630–800 A.D.). *Acta Medica Lituanica* 12(1), 58–64.
- Walker, P. L. 2001. A bioarchaeological perspective on the history of violence. *Annual Review of Anthropology* 30, 573–596.
- Wells, C. 1982. The human remains, in: McWhirr, A., Viner, I., Wells, C. *Romano-British Cemeteries at Cirencester*. Cirencester Excavation Committee, Cirencester, pp. 135–202.