Denton A. Cooley's
50th Anniversary
in Medicine

Coronary Angioscopy

Christopher J. White, MD
Stephen R. Ramee, MD
Tyrone J. Collins, MD
Joseph P. Murgo, MD

Endothelial disruption and thrombosis are key factors contributing to the development of unstable angina and acute myocardial infarction.[1-3] However, angiography, "the gold standard," has been shown to be a relatively insensitive method for detecting these intraluminal changes. Initial reports have suggested that angioscopy could provide valuable information about plaque morphology in patients with coronary artery disease. These developments, together with improvements in fiberoptic technology and catheter design, have laid the groundwork for the advancement of percutaneous coronary angioscopy in the catheterization laboratory.[4-16] The promise of the angioscope is that direct visual examination of the surface morphology of a coronary artery will provide more accurate information than angiography. Theoretically, this enhanced ability to detect subtle details of plaque morphology will yield improved clinical outcomes for selected patients undergoing interventional procedures.

Performance of Angioscopy

Angioscopic Equipment

The angioscopic imaging system is made up of components including illumination fibers, imaging fibers, a video camera and monitor, and a videotape recorder. The illumination source provides a high-intensity "cold" light to avoid thermal damage to the vessel being imaged. The imaging bundle consists of at least 2,000 optical fibers for adequate resolution. The video recorder provides an archival storage medium for reviewing the images.

The angioscope (Imagecath®, Baxter Edwards; Irvine, California, USA) is a catheter within a catheter (Fig. 1). The inner catheter contains 3,000 imaging fibers and is guided within the coronary artery over a conventional 0.014-inch angioplasty guidewire. Although the imaging bundle comprises several thousand fibers, its diameter is approximately 0.018 inch (similar to that of an angioplasty guidewire), so the human eye cannot see the completed image without magnification. Angioscopy systems employ a high resolution color video camera to display the magnified mosaic on a color monitor. The image that is carried through the fiberoptic catheter is magnified and then exposed to the surface of an imaging sensor within the video camera. Angioscopic systems use a charge coupled device (CCD) that samples the image for red, green, and blue light and converts that information into an electronic signal that is recorded onto magnetic tape. Charge coupled devices are exceptionally sensitive and small in size, both advantages for an angioscopic imaging sensor. Despite miniaturization, the CCD contains a large number of sensors, thereby reducing the loss associated with the magnified projection of the mosaic image onto the monitor.

The outer catheter measures 4.5 Fr in diameter and has a lumen for inflating and deflating an occlusion balloon at its distal tip. The occlusion balloon is composed of a very compliant material that achieves a variable final diameter, up to a maximum diameter of 5.0 mm, depending on the volume of liquid introduced. In the space between the inner catheter and outer catheter, there is room for a solution to be infused to clear the field of view during inflation of the occlusion balloon. The inner catheter, or imaging bundle, may be advanced or withdrawn independently of the outer catheter a distance of 6 cm, so that multiple segments of the vascular lumen can be examined. Both the inner and outer catheters are guided by the same angioplasty guidewire in a "monorail" fashion, which facilitates rapid exchange.

This series in recognition of Dr. Cooley's 50th anniversary in medicine is continued from the December 1994 issue.

Key words: *Angioscopy; catheterization*

From: *The Section of Cardiology, Department of Internal Medicine, Ochsner Medical Institutions, New Orleans, Louisiana 70121*

Section editors:
Grady L. Hallman, MD
Robert D. Leachman, MD
John L. Ochsner, MD

Address for reprints:
Christopher J. White, MD, Director, Interventional Cardiology, Health Care International, Beardmore Street, Clydebank, Scotland G81 4DY

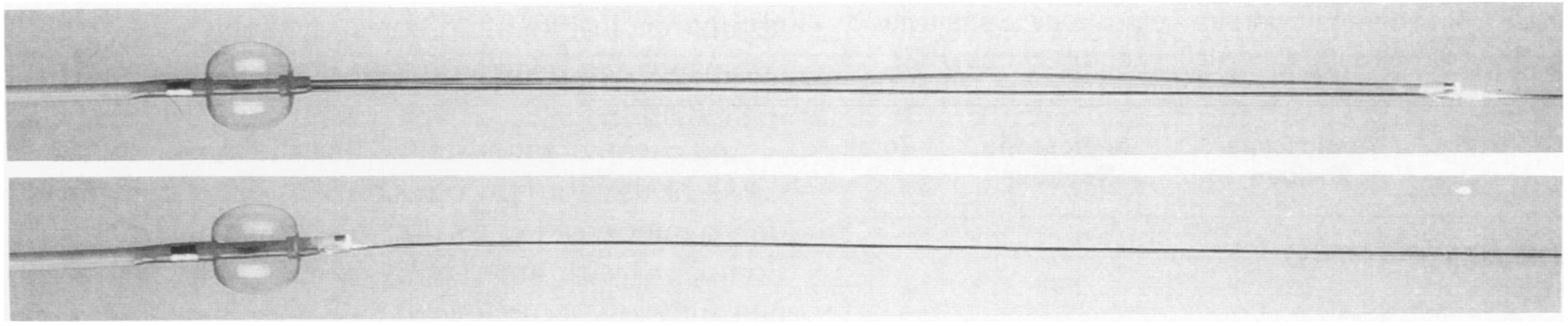

Fig. 1 *Baxter Imagecath® Angioscope. Top: The occlusion balloon is inflated and the image element is extended over a guidewire. Bottom: The image element has been retracted into the outer catheter.*

Angioscopic Procedure

Vascular access is obtained in the femoral or brachial artery with an 8-Fr sheath, a conventional angioplasty guiding catheter is advanced to the coronary ostium of interest, and 10,000 units of heparin are administered. A 0.014-inch angioplasty guidewire is placed into the distal portion of the coronary artery. Because the angioscope uses a monorail design that enables rapid exchange, it may be advanced over a guidewire into the coronary artery of interest just proximal to the segment imaged. The flush lumen of the angioscope is connected to a power injector for infusion of warmed, lactated Ringer's solution at a rate of 0.5 to 1.0 cc per second. The occlusion balloon is hand-inflated with a 1-cc syringe filled with a 1:1 mixture of saline and radiographic contrast material. Special care is taken not to overinflate the balloon. The imaging bundle is then advanced over the guidewire to view the intraluminal surface of the vessel. Each imaging sequence lasts approximately 30 to 45 seconds, after which the balloon is deflated and the flush discontinued. These steps can be repeated several times, until the region of interest has been adequately investigated.

When angioscopy is performed in conjunction with angioplasty, imaging may be performed before or after treatment, or both. The target lesion is generally not crossed when imaging is performed before angioplasty, due to the small size of the vascular lumen. Complete imaging of the vessel can be performed after dilation to examine the distal segments of the vessel not accessible before angioplasty. The entire sequence, from introducing the angioscope to obtaining images, can usually be accomplished in less than 5 minutes.

Angioscopic Images of Lesion Morphology

Acute Coronary Ischemia

Dramatic differences in plaque morphology have been observed between patients presenting with clinical symptoms of stable or unstable angina, when undisturbed lesions have been imaged with angioscopy before coronary angioplasty.[13] Intracoronary angioscopy of undisturbed lesions (performed before coronary angioplasty) demonstrated a significantly higher occurrence of complex plaque, including plaque ruptures or dissections and associated intracoronary thrombi, in patients with unstable angina than in those with stable angina (Fig. 2).

These results confirmed the intraoperative angioscopy study by Sherman and coworkers[8] in which they documented both a surprisingly high incidence of intracoronary thrombi in patients with unstable angina and the insensitivity of angiography in detecting these thrombi. These in vivo findings are consistent with postmortem studies suggesting that the pathophysiology responsible for the occurrence of unstable angina is plaque rupture and thrombus formation.[1-3]

In our own study, we also confirmed that angiography was less sensitive than angioscopy in detecting intracoronary thrombi (Table I). To determine whether the presence of intracoronary thrombus correlated with procedural complications of angioplasty, we performed percutaneous coronary angi-

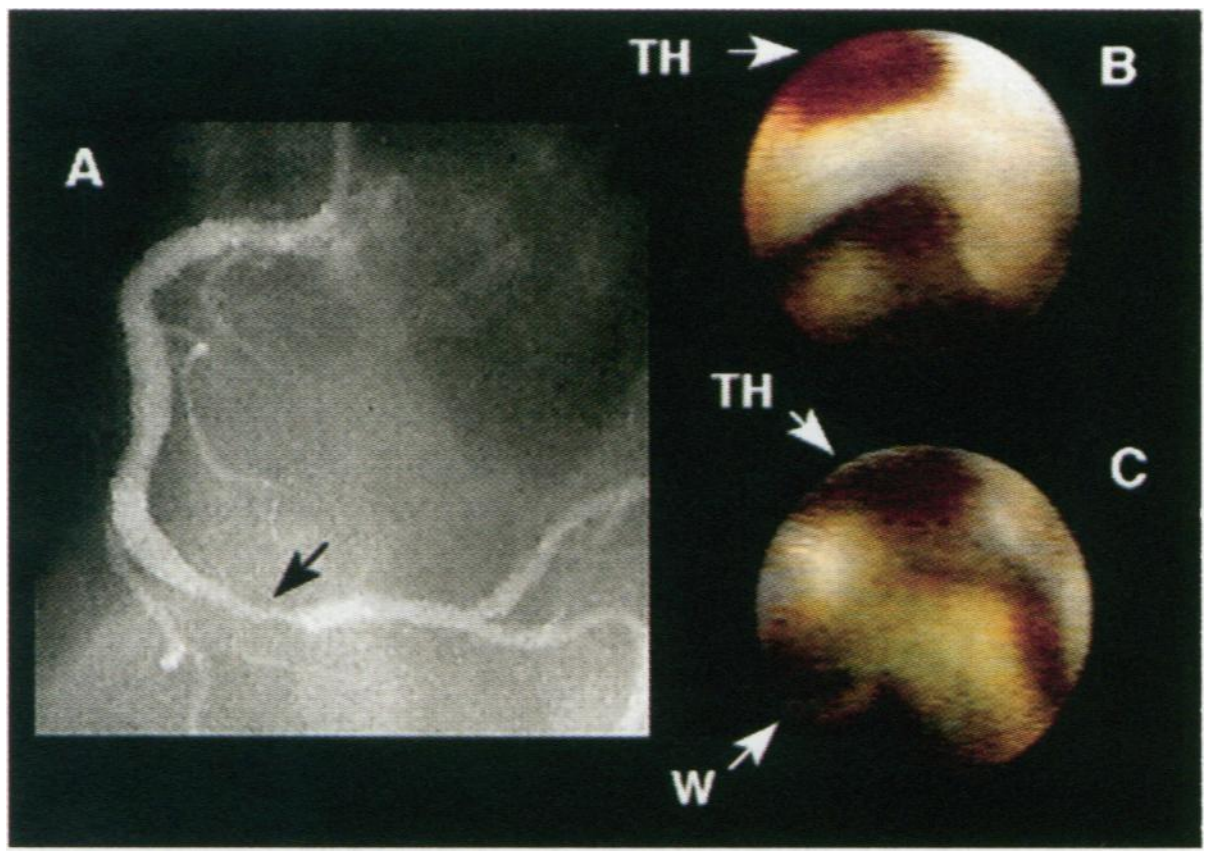

Fig. 2 ***A)*** *Angiogram of right coronary lesion (arrow) in a patient with unstable angina.* ***B)*** *Before percutaneous angioplasty, angioscopy shows mural thrombus (TH).* ***C)*** *After percutaneous angioplasty, angioscopy shows the guidewire (W) in the lumen, and persistent mural thrombus (TH) within an intimal dissection.*

TABLE I. Angiographic versus Angioscopic Sensitivity and Specificity for Intracoronary Thrombus (n = 122)

	Angioscope Positive	Angioscope Negative	Total
Angiogram Positive	20 (TP)	4 (FP)	24
Angiogram Negative	54 (FN)	44 (TN)	98
Total	74	48	122

Angiographic Sensitivity = 27%	Positive Predictive Value = 83%
Angiographic Specificity = 92%	Negative Predictive Value = 45%

FN = false negative; FP = false positive; TN = true negative; TP = true positive

oscopy in 122 patients before or after angioplasty, or both.[17] Patients were treated with routine angioplasty techniques; no thrombolytic agent was administered. Stable angina was present in 27 patients, and unstable angina was present in 95 patients. Angioscopy demonstrated that patients with unstable angina had a much higher incidence of intracoronary thrombus (70/95 patients; 74%) than did patients with stable angina (4/27; 15%) ($p < 0.001$).

In-hospital adverse outcomes, defined either as the occurrence of major sequelae (death, myocardial infarction, or emergency bypass) or as the recurrence of ischemic events (angina, abrupt occlusion, or repeat angioplasty), were associated with the presence of angioscopically identified intracoronary thrombus. A major sequela occurred in 10 of 95 (11%) patients with unstable angina, compared with none of the 27 stable angina patients ($p=0.07$); and recurrent ischemic events occurred in 22 of 95 (23%) unstable angina patients, compared with 2 of 27 (7%) stable angina patients ($p = 0.05$). The presence of intracoronary thrombus appeared to be associated with adverse outcomes after coronary angioplasty.

Abrupt Occlusion after Angioplasty

Abrupt occlusion of a coronary artery is the major cause of morbidity and mortality associated with percutaneous transluminal coronary angioplasty.[18-23] Therapy intended to reopen occluded vessels is either empirical or guided by angiographic imaging of lesion morphology that has inherent limitations in specifically identifying the cause of the occlusion. In order to directly visualize the intravascular morphology of abruptly occluded vessels, we performed percutaneous coronary angioscopy in 17 patients with abrupt occlusion after coronary angioplasty and compared the results of angioscopy with those of angiography.[24]

Angioscopy demonstrated that the most common cause of the abrupt occlusion was dissection, with only a minority of cases due to coronary thrombosis. Compared with angioscopy, angiography was significantly less accurate in identifying a specific cause of the occlusion, correctly identifying only 4 of 14 (29%) occlusive dissections and 1 of 3 (33%) intraluminal thrombi. Dissection, characterized by bulky tissue fragments obstructing the lumen of the vessel, was the primary cause of the occlusion in 14 of 17 (82%) vessels. In 3 of 17 (18%) vessels, occlusive intraluminal thrombi were seen. All 3 patients with occlusive intraluminal thrombi had unstable angina, including 2 patients with postmyocardial infarction angina and 1 patient with a crescendo pattern of angina.

We also used the angioscopic images to guide salvage therapy. The 3 patients with occlusive thrombi were treated with a selective infusion of 250,000 units of intracoronary urokinase (Abbokinase, Abbott Laboratories; Abbott Park, Illinois, USA) over 30 minutes (Fig. 3). Urokinase was used alone in 1 patient and as an adjunct to repeat balloon dilation in 2 patients. Two patients had their angioplasty procedures successfully salvaged without infarction. The 3rd patient's vessel was successfully recanalized; however, patency could not be sustained, and he was sent for emergency bypass surgery with a perfusion balloon in place to maintain flow.

Among the procedures performed in the 14 patients with occlusive dissections, long balloon inflations were unable to reopen 2 occluded vessels, and the patients were sent for emergency coronary bypass surgery. In the remaining 12 patients with occlusive dissections, 8 patients were successfully treated with repeat balloon dilation, 3 were successfully treated with repeat balloon dilation and directional coronary atherectomy, and 1 was treated with stent implantation.

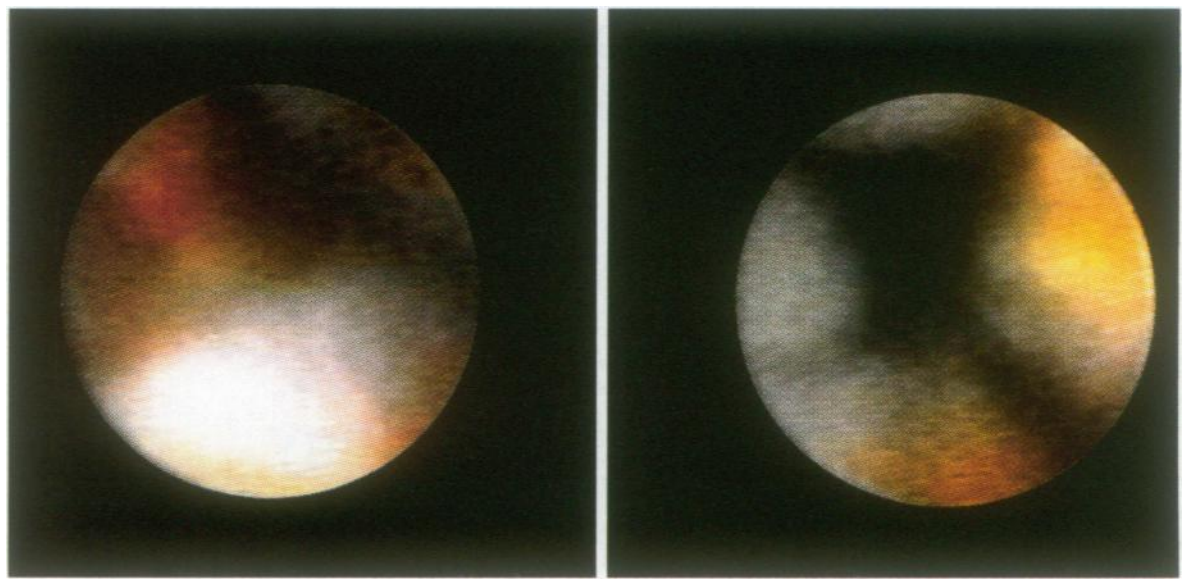

Fig. 3 *Left: Intraluminal red thrombus is present at 11 o'clock. Right: After urokinase infusion, the red thrombus has resolved.*

Saphenous Vein Grafts

The results of percutaneous angioscopy and angiography for detecting critical elements of surface lesion morphology were compared in 21 patients undergoing balloon angioplasty of saphenous vein coronary bypass grafts.[25] Angioscopy and angiography were performed before and after angioplasty of "culprit lesions" in bypass grafts. All but 1 of the patients had unstable angina. The mean age of the saphenous vein coronary bypass grafts was 10.1 ± 2.4 years (range, 5 to 15 years). There was no correlation between age of the bypass graft and the presence of friable plaque. On the basis of our results (Table II), we concluded that angioscopy is superior to angiography for detecting complex lesion morphology in bypass grafts.

Future Applications of Angioscopy

The correlation of atherosclerotic lesion morphology with clinical outcomes has been the cornerstone of our understanding of atherosclerosis and has guided our treatment of patients with this disease. The landmark study by DeWood and colleagues[26] made clear the role of intracoronary thrombosis in the pathogenesis of myocardial infarction and dramatically altered the standard of therapy from supportive care to interventional therapy with thrombolytic agents. Angiographic studies of coronary morphology in patients with stable and unstable angina have enabled us to identify patients with high-risk lesions.[27-29] However, these studies have been limited by the documented insensitivity of angiography in assessing residual stenosis after angioplasty and in detecting subtle changes in coronary artery surface morphology, such as plaque fractures, dissections, and intracoronary thrombi.[30-44]

When compared with angiography, angioscopy offers a superior sensitivity and specificity for identifying subtle changes in atherosclerotic plaque morphology. Like angiography, this is a percutaneous technique that can be used to more closely examine suspect regions or lesions. Angioscopy enables the in vivo examination of the abnormality present on the surface of the coronary artery. Our early studies suggest that angioscopy has the potential to improve understanding of coronary artery lesion morphology in patients with acute ischemic syndromes, restenosis after angioplasty, and saphenous vein graft disease.

TABLE II. Comparison of Angioscopy and Angiography in Saphenous Vein Grafts (n = 21)

	Thrombus	Dissection	Friable Plaque
Angioscopy	15 (71%)	14 (66%)	11 (52%)
Angiography	4 (19%)	2 (10%)	5 (24%)
p-value	<0.001	<0.01	<0.05

Percutaneous coronary angioscopy may play a role in guiding interventional coronary therapy. Angioscopy, when compared with angiography, is better able to detect small amounts of intracoronary thrombus that may have a negative impact on the outcome of angioplasty in patients with acute ischemic syndromes. Current studies are under way to determine if the angioscopic detection of intracoronary thrombus in patients undergoing balloon angioplasty can identify those at higher risk of complications from the procedure. Perhaps the administration of adjunctive thrombolytic therapy, either before or after balloon dilation, will eventually be guided by angioscopic findings.

Summary

Coronary angioscopy will not replace angiography as the gold standard for imaging atherosclerotic coronary arteries. However, there may well be a clinical niche for a technology that gives accurate information regarding a specific lesion, if that information can be used to improve the acute or chronic outcome of an interventional procedure. Our experience demonstrates that angioscopy indeed provides this information. Using angioscopy, we now have access to information regarding arterial wall disease that heretofore has been available only at necropsy. In addition, whereas angiography has provided only a 2-dimensional, gray-scale image of the coronary vessels, angioscopy offers a full-color, 3-dimensional perspective of the intracoronary surface morphology. These important lesion-specific details, not reliably available from angiography alone, may ultimately be used to improve patient outcome and to assess risk.

References

1. Davies MJ, Thomas T. The pathological basis and microanatomy of occlusive thrombus formation in human coronary arteries. Philos Trans R Soc Lond (Series B) 1981;294: 225-9.
2. Falk E. Unstable angina with fatal outcome: dynamic coronary thrombosis leading to infarction and/or sudden death. Autopsy evidence of recurrent mural thrombosis with peripheral embolization culminating in total vascular occlusion. Circulation 1985;71:699-708.
3. Falk E. Plaque rupture with severe pre-existing stenosis precipitating coronary thrombosis: characteristics of coronary atherosclerotic plaques underlying fatal occlusive thrombi. Br Heart J 1983;50:127-34.
4. Litvack F, Grundfest WS, Lee ME, Carroll RM, Foran R, Chaux A, et al. Angioscopic visualization of blood vessel interior in

animals and humans. Clin Cardiol 1985;8:65-70.

5. Grundfest WS, Litvack F, Sherman T, Carroll R, Lee M, Chaux A, et al. Delineation of peripheral and coronary detail by intraoperative angioscopy. Ann Surg 1985;202:394-400.
6. Sanborn TA, Rygaard JA, Westbrook BM, Lazar HL, McCormick JR, Roberts AJ. Intraoperative angioscopy of saphenous vein and coronary arteries. J Thorac Cardiovasc Surg 1986;91:339-43.
7. Lee G, Garcia JM, Corso PJ, Chan MC, Rink JL, Pichard A, et al. Correlation of coronary angioscopic to angiographic findings in coronary artery disease. Am J Cardiol 1986;58:238-41.
8. Sherman CT, Litvack F, Grundfest W, Lee M, Hickey A, Chaux A, et al. Coronary angioscopy in patients with unstable angina pectoris. N Engl J Med 1986;315:913-9.
9. Spears JR, Spokojny AM, Marais HJ. Coronary angioscopy during cardiac catheterization. J Am Coll Cardiol 1985;6:93-7.
10. Uchida Y, Tomaru T, Nakamura F, Furuse A, Fujimori Y, Hasegawa K. Percutaneous coronary angioscopy in patients with ischemic heart disease. Am Heart J 1987;114:1216-22.
11. Uchida Y, Hasegawa K, Kawamura K, Shibuya I. Angioscopic observation of the coronary luminal changes induced by percutaneous transluminal coronary angioplasty. Am Heart J 1989;117:769-76.
12. Uchida Y. Percutaneous coronary angioscopy by means of a fiberscope with a steerable guidewire. Am Heart J 1989;117:1153-5.
13. Ramee SR, White CJ, Collins TJ, Mesa JE, Murgo JP. Percutaneous angioscopy during coronary angioplasty using a steerable microangioscope. J Am Coll Cardiol 1991;17:100-5.
14. White CJ, Ramee SR. Percutaneous coronary angioscopy: methods, findings, and therapeutic implications. Echocardiography 1990;7:485-94.
15. Mizuno K, Arai T, Satomura K, Shibuya T, Arakawa K, Okamoto Y, et al. New percutaneous transluminal coronary angioscope. J Am Coll Cardiol 1989;13:363-8.
16. White CJ, Ramee SR, Mesa JE, Collins TJ. Percutaneous coronary angioscopy in patients with restenosis after coronary angioplasty. J Am Coll Cardiol 1991;17(Suppl B):46B-49B.
17. White CJ, Ramee SR, Collins TJ, et al. Angioscopically detected coronary thrombus correlates with adverse PTCA outcome [abstract]. Circulation 1993;88(Suppl IV):IV-3206.
18. De Feyter PJ, van den Brand M, Jaarman GJ, van Domburg R, Serruys PW, Suryapranata H. Acute coronary occlusion during and after percutaneous transluminal coronary angioplasty: frequency, prediction, clinical course, management, and follow-up. Circulation 1991;83:927-36.
19. Simpfendorfer C, Belardi J, Bellamy G, Galan K, Franco I, Hollman J. Frequency, management and follow-up of patients with acute coronary occlusions after percutaneous transluminal coronary angioplasty. Am J Cardiol 1987;59:267-9.
20. Ellis SG, Roubin GS, King SB III, Douglas JS Jr, Weintraub WS, Thomas RG, et al. Angiographic and clinical predictors of acute closure after native vessel coronary angioplasty. Circulation 1988;77:372-9.
21. Detre KM, Holmes DR Jr, Holubkov R, Cowley MJ, Bourassa MG, Faxon DP, et al. Incidence and consequences of periprocedural occlusion: the 1985–1986 National Heart, Lung, and Blood Institute Percutaneous Transluminal Coronary Angioplasty Registry. Circulation 1990;82:739-50.
22. Sugrue DD, Holmes DR Jr, Smith HC, Reeder GS, Lane GE, Vlietstra RE, et al. Coronary artery thrombus as a risk factor for acute vessel occlusion during percutaneous transluminal coronary angioplasty: improving results. Br Heart J 1986;56:62-6.
23. Mabin TA, Holmes DR Jr, Smith HC, Vlietstra RE, Bove AA, Reeder GS, et al. Intracoronary thrombus: role in coronary occlusion complicating percutaneous transluminal coronary angioplasty. J Am Coll Cardiol 1985;5:198-202.
24. White CJ, Ramee SR, Collins RJ, Jain A, Mesa JE, Ventura HO. Percutaneous coronary angioscopy: applications in interventional cardiology. J Intervent Cardiol 1993;6:61-7.
25. White CJ, Ramee SR, Collins TJ, Mesa JE, Jain A. Percutaneous angioscopy of saphenous vein coronary bypass grafts. J Am Coll Cardiol 1993;21:1181-5.
26. DeWood MA, Spores J, Notske R, Mouser LT, Burroughs R, Golden MS, et al. Prevalence of total coronary occlusion during the early hours of transmural myocardial infarction. N Engl J Med 1980;303:897-902.
27. Ambrose JA, Winters SL, Stern A, Eng A, Teichholz LE, Gorlin R, et al. Angiographic morphology and the pathogenesis of unstable angina pectoris. J Am Coll Cardiol 1985;5:609-16.
28. Rehr R, DiSciascio G, Vetrovec G, Cowley M. Angiographic morphology of coronary artery stenoses in prolonged rest angina: evidence of intracoronary thrombosis. J Am Coll Cardiol 1989;14:1429-37.
29. Levin DC, Fallon JT. Significance of the angiographic morphology of localized coronary stenoses: histopathologic correlations. Circulation 1982;66:316-20.
30. Vlodaver Z, Frech R, Van Tassel RA, Edwards JE. Correlation of the antemortem coronary arteriogram and the postmortem specimen. Circulation 1973;47:162-9.
31. Grondin CM, Dyrda I, Pasternac A, Campeau L, Bourassa MG, Lespérance J. Discrepancies between cineangiographic and postmortem findings in patients with coronary artery disease and recent myocardial revascularization. Circulation 1974;49:703-8.
32. Pepine CJ, Feldman RL, Nichols WW, Conti CR. Coronary arteriography: potentially serious sources of error in interpretation. Cardiovasc Med 1977;2:747-56.
33. Arnett EN, Isner JM, Redwood DR, Kent KM, Baker WP, Ackerstein H, et al. Coronary artery narrowing in coronary heart disease: comparison of cineangiographic and necropsy findings. Ann Intern Med 1979;91:350-6.
34. Isner JM, Kishel J, Kent KM, Ronan JA Jr, Ross AM, Roberts WC. Accuracy of angiographic determination of left main coronary arterial narrowing: angiographic–histologic correlative analysis in 28 patients. Circulation 1981;63:1056-64.
35. Spears JR, Sandor T, Baim DS, Paulin S. The minimum error in estimating coronary luminal cross-sectional area from cineangiographic diameter measurements. Cathet Cardiovasc Diagn 1983;9:119-28.
36. White CW, Wright CB, Doty DB, Hiratza LF, Eastham CL, Harrison DG, et al. Does visual interpretation of the coronary arteriogram predict the physiologic importance of a coronary stenosis? N Engl J Med 1984;310:819-24.
37. Isner JM, Donaldson RF. Coronary angiographic and morphologic correlation. Cardiol Clin 1984;2:571-92.
38. Gould KL. Quantification of coronary artery stenosis in vivo. Circ Res 1985;57:341-53.
39. Zijlstra F, van Ommeren J, Reiber JHC, Serruys PW. Does the quantitative assessment of coronary artery dimensions predict the physiologic significance of a coronary stenosis? Circulation 1987;75:1154-61.
40. Marcus ML, Skorton DJ, Johnson MR, Collins SM, Harrison DG, Kerber RE. Visual estimates of percent diameter coronary stenosis: "A battered gold standard" [editorial]. J Am Coll Cardiol 1988;11:882-5.
41. Katritsis D, Webb-Peploe M. Limitations of coronary angiography: an underestimated problem? Clin Cardiol 1991;14:20-4.

42. Block PC, Myler RK, Stertzer S, Fallon JT. Morphology after transluminal angioplasty in human beings. N Engl J Med 1981;305:382-5.
43. Düber C, Jungbluth A, Rumpelt H-J, Erbel R, Meyer J, Thoenes W. Morphology of the coronary arteries after combined thrombolysis and percutaneous transluminal coronary angioplasty for acute myocardial infarction. Am J Cardiol 1986;58:698-703.
44. Essed CE, van den Brand M, Becker AE. Transluminal coronary angioplasty and early restenosis: fibrocellular occlusion after wall laceration. Br Heart J 1983;49:393-6.