

Reversible Cardiomyopathy in Paediatric Addison's Disease - A Cautionary Tale

L.S. Conwell¹, L.M. Gray², R.G. Delbridge³, M.J. Thomsett¹ and J.A. Batch¹

¹Department of Endocrinology and Diabetes and ³Paediatric Intensive Care Unit,
Royal Children's Hospital, Brisbane and ²Rockhampton, Queensland, Australia

ABSTRACT

A 13 year-old girl with clinical features of Addison's disease developed acute cardiac failure after initiation of treatment and after initial clinical improvement. Large doses of i.v. hydrocortisone and oral fludrocortisone, in addition to inotropic and ventilatory support, were required to achieve cardiovascular stability. The cardiomyopathy improved over one week and her condition then remained stable on oral glucocorticoid and mineralocorticoid replacement therapy. Reversible cardiomyopathy is a rare and potentially life-threatening complication of Addison's disease. The second reported paediatric patient is presented, the only one reported to require ventilatory support.

KEY WORDS

adrenal failure, Addison's disease, myocardium, cardiomyopathy

INTRODUCTION

Acquired autoimmune adrenal failure may occur alone or as a manifestation of either autoimmune polyendocrinopathy type 1 or type 2 syndromes. It is the commonest cause of primary adrenal failure in developed countries, accounting for 75-90% of cases¹.

Reprint address:
Dr. L.S. Conwell
Department of Endocrinology and Diabetes
Royal Children's Hospital
Herston Road, Herston
Brisbane, Queensland
Australia, 4029
e-mail: louise_conwell@health.qld.gov.au

This report describes reversible cardiomyopathy in a child with Addison's disease. There is only one previous report of such a case. An 11 year-old boy developed cardiac failure 24 hours after treatment with intravenous fluids and hydrocortisone². In comparison, the patient in this report required increased inotropic support and mechanical ventilatory support.

PATIENT REPORT

A 13 year-old girl presented with 3 weeks of weight loss, lethargy, weakness, abdominal cramping, vomiting and salt-craving. Increasing skin pigmentation had been apparent for several months. Her past medical and family history was unremarkable.

Physical examination revealed a cachectic, weak and hyperpigmented girl. Her temperature was 35.2°C, respiratory rate 20/min, heart rate 105/min, blood pressure 65/30 mmHg and peripheral perfusion poor.

Initial investigations demonstrated sodium 121 mmol/l (normal 137-147), potassium 7.0 mmol/l (3.5-5.0), creatinine 0.14 mmol/l (0.04-0.10), chloride 93 mmol/l (96-109), bicarbonate 14 mmol/l (25-33), venous pH 7.3 (7.3-7.4), glucose 4.2 mmol/l (3.0-7.7), corrected calcium 3.45 mmol/l (2.25-2.65), magnesium 0.4 mmol/l (0.7-1.1) and lactate 1.1 mmol/l (0.6-2.0).

A provisional diagnosis of acute adrenal insufficiency was made. Early morning cortisol measured on a sample collected 7 days before presentation was 27 nmol/l (1.0 µg/dl) (normal 200-700 nmol/l [7-25 µg/dl]). ACTH could not be measured prior to treatment. Adrenal auto-antibodies were subsequently positive (1:160) confirming the diagnosis of autoimmune Addison's disease.

Intravenous fluids, intravenous hydrocortisone (100 mg q 6 h) and oral fludrocortisone (100 µg bid) were commenced. Despite marked initial improvement, respiratory distress and hypotension developed 36 hours after admission. Basal respiratory crackles were present without peripheral oedema. Despite initial hypovolaemia, the patient was only in 1.2 l positive fluid balance. The chest X-ray was consistent with extensive pulmonary oedema (Fig. 1).

After initiation of intravenous broad-spectrum antibiotics, intravenous magnesium bolus, diuretic therapy and inotropic support (dopamine 5 µg/kg/min), the patient was transferred to a tertiary paediatric intensive care unit.

Increasing inotropic support was required (dopamine 7.5 µg/kg/min and dobutamine 10 µg/kg/min). Echocardiography revealed a non-dilated left ventricle, mild mitral regurgitation and global reduction in left ventricular fractional shortening to 24% (normal 26-40%). Cardiac troponin I was mildly elevated at 2.2 ng/l (<0.4 ng/l). Ventilation

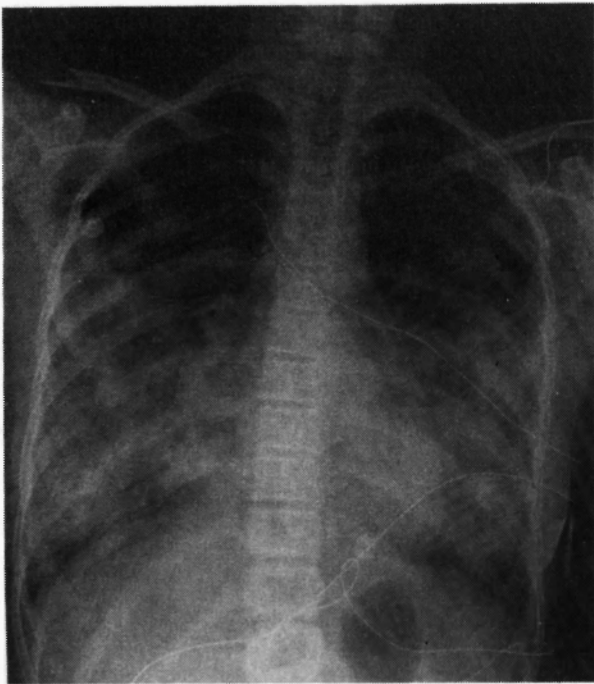


Fig. 1: Chest X-ray. Bilateral mid and lower zone alveolar shadowing consistent with extensive pulmonary oedema.

was supported with mask continuous positive airway pressure (CPAP) for 2 days. Intubation and ventilation were then required due to intolerance of mask CPAP and the ongoing requirement for respiratory support. The patient did not develop acidosis during this period. Intravenous hydrocortisone and oral fludrocortisone doses were increased to achieve cardiovascular stability (maximal doses of 100 mg q 3 h and 300 µg tid, respectively). Extubation was achieved on day 8, with cessation of inotropic support on day 9.

Nasopharyngeal aspirates were negative for respiratory viruses. Blood cultures were negative. Initial thyroid function tests at presentation showed an elevated TSH level of 8 mU/l (normal 0.4-5 mU/l) with normal fT₄. The TSH had normalised on repeat testing and thyroid autoantibodies were negative.

Left ventricular fractional shortening had increased to 32% by day 12. Trivial mitral regurgitation persisted. ECG on day 21 showed T-wave inversion in leads I, AVL and V6. Hypomagnesaemia persisted, requiring oral supplementation for 3 weeks. The patient's condition then remained stable on oral glucocorticoid and mineralocorticoid replacement therapy, and was weaned to expected physiological doses by day 17. Echocardiography 5 months later demonstrated stable myocardial contractility with low-normal left ventricular fractional shortening and improved mitral valve function.

DISCUSSION

Potential factors contributing to myocardial dysfunction in this patient with Addison's disease include chronic glucocorticoid deficiency, mineralocorticoid deficiency, ischaemia and hypomagnesaemia.

Other examples of reversible cardiomyopathy in the context of glucocorticoid deficiency have been described, including a neonate with congenital adrenal hyperplasia and a 36 year-old man with Addison's disease^{3,4}. A 6 year-old boy, subsequently diagnosed with adrenoleukodystrophy, died due to primary myocardial pump failure⁵. In contrast to these patients, the reported patient's cardiac func-

tion deteriorated after the commencement of treatment and after initial clinical improvement.

Hypovolaemia and/or electrolyte imbalance are not essential in the pathogenesis of circulatory collapse observed in adrenal insufficiency. Corticosteroids play a key role in the regulation of circulatory function⁶. Glucocorticoids are important for intrinsic myocardial contractility and regulation of the sympathetic nervous system. Adrenalectomised animals demonstrate diminished myocardial function with impaired adenosine triphosphatase activity⁷, calcium transport⁸, and compartmentalisation of phosphorylase in heart muscle⁹. Glucocorticoid deficiency downregulates adrenergic receptors, and decreases epinephrine synthesis, tissue sensitivity to catecholamines and epinephrine activation of glycogenolysis in the myocardium⁹. Sympathectomy and α - and β -blockade protect stressed adrenalectomised animals from circulatory failure. It has been proposed that catecholamines may have a detrimental effect on the heart in the absence of a corresponding increase in glucocorticoid, due to an increase in intracellular lactate and impaired contractility¹⁰. Aldosterone exerts a positive inotropic action; therefore mineralocorticoid deficiency may also contribute to myocardial dysfunction¹¹.

Cardiac troponin I is a very sensitive and specific marker for myocardial cell necrosis, with levels remaining elevated for 7-10 days after an episode of myocardial necrosis¹². Although there were no acute ischaemic ECG features, inverted T waves were apparent at Day 21. In this case, ischaemic injury may have been a secondary effect rather than the primary causative insult. Glucocorticoid deficiency may lower the threshold for ischaemic injury.

In addition to impaired cardiac output, hypotension in Addison's disease is due to hypovolaemia secondary to renal salt loss and vomiting; and increased production of the vasodilator bradykinin and decreased vascular reactivity, both due to glucocorticoid deficiency¹¹. Lower levels of α_1 -adrenergic receptors and angiotensin-1 receptors have been described. Although plasma angiotensin II levels are high and contribute to the maintenance of peripheral resistance, the effectiveness of angiotensin II is blunted¹¹.

Although congestive cardiac failure associated with fludrocortisone treatment has been described in patients with Addison's disease¹³, the patient reported here had only received two 100 μ g doses of oral fludrocortisone.

Acute viral myocarditis is a common cause of reversible myocardial dysfunction in children and adolescents¹⁴. Viruses such as cytomegalovirus have been implicated in the pathogenesis of adrenal insufficiency in immunocompromised states, e.g. AIDS¹⁵. However the patient was immunocompetent and did not have a history of fever or respiratory symptoms in the 10-14 days prior to presentation. Symptoms and signs of primary adrenal insufficiency had been present for months preceding the myocardial compromise, suggesting that a viral agent was not simultaneously contributing to acute myocarditis and adrenalitis.

Hypomagnesaemia may contribute to cardiac dysfunction. Low magnesium levels are common in seriously ill patients, including those with acute myocardial infarction or heart failure¹⁶. Magnesium modulates mechanical and electrical functions of cardiac and vascular cells¹⁶, and animals fed on a low magnesium diet have developed cardiomyopathy¹⁷. Hypercalcaemia, as evident in this reported patient, has been previously associated with Addison's disease, with resolution after correction of cortisol deficiency¹⁸. Although glucocorticoid receptors are present in bone cells^{19,20}, the mechanism is poorly understood. A PTH effect is discounted due to hypercalcaemia in an Addisonian patient with co-existent idiopathic hypoparathyroidism²¹. Documented persistence despite intravenous rehydration suggests haemoconcentration is not a major mechanism. Elevated urinary calcium excretion has been documented indicating increased calcium input into the extracellular fluid. Bone biopsies in three patients with hypercalcaemia and Addison's disease demonstrated depressed osteoblastic and osteoclastic activities at the trabecular surfaces¹⁸. However, calcium levels are mostly regulated by active transport of calcium out of interstitial bone fluid into the blood by the osteocyte 'lining cells'¹⁸.

Cardiac contractile function is diminished by acidosis. Mechanisms include altered intracellular calcium mobilisation and decreased myofibrillar

calcium sensitivity²². However the pH of the reported patient was 7.3 at presentation and was in the range 7.35-7.45 during the period of deteriorating cardiac function in the intensive care unit.

Mitochondrial disorders can be a cause of both cardiomyopathy and autoimmune adrenal disease²³. Our patient did not demonstrate associated clinical features, such as ptosis, ophthalmoparesis, peripheral myopathy or pigmentary retinopathy.

This report describes the onset of congestive cardiac failure more than 24 hours after institution of treatment and after initial improvement. Chronic myocardial glucocorticoid deficiency was likely the predominant pathogenetic mechanism causing the deterioration in cardiac function. Hydration therapy partially corrected the hypovolaemic state, with water and sodium retention due to commencement of glucocorticoid and mineralocorticoid therapy. However recovery of cardiac functioning was slower. Hence there was likely diminished functional reserve of the myocardium to cope with the increased intravascular volume due to partial correction of hypovolaemia. There may be a role for increased initial glucocorticoid replacement or slower rehydration. Due to the mechanisms stated previously, inotropic agents may be poorly effective until large doses of glucocorticoid have been administered.

This report highlights the importance of evaluating myocardial function in patients with long-standing glucocorticoid deficiency and being alert to the potential complication of cardiomyopathy as treatment is commenced. High doses of glucocorticoids may be required in this context. Cardiomyopathy should also be remembered as a possible presentation of glucocorticoid deficiency.

ACKNOWLEDGEMENTS

Dr. Louise Conwell's Clinical Research Scholarship was supported by the Royal Children's Hospital Foundation, Brisbane.

REFERENCES

- Peterson P, Uibo R, Krohn KJ. Adrenal autoimmunity: results and developments. *Trends Endocrinol Metab* 2000; 11: 285-290.
- Derish M, Eckert K, Chin C. Reversible cardiomyopathy in a child with Addison's disease. *Intens Care Med* 1996; 22: 460-463.
- Boston BA, DeGroff C, Hanna CE, Reller M. Reversible cardiomyopathy in an infant with unrecognized congenital adrenal hyperplasia. *J Pediatr* 1994; 124: 936-938.
- Afzal A, Khaja F. Reversible cardiomyopathy associated with Addison's disease. *Can J Cardiol* 2000; 16: 377-379.
- Walker C, Butt W. A case of cardiovascular collapse due to adrenal insufficiency. *Aust Paediatr J* 1988; 24: 197-198.
- Bouachour G, Tirot P, Varache N, Gouello JP, Harry P, Alquier P. Hemodynamic changes in acute adrenal insufficiency. *Intens Care Med* 1994; 20: 138-141.
- Rovetto MJ, Murphy RA, Lefer AM. Cardiac impairment in adrenal insufficiency: reduced ATPase activity of myocardial contractile proteins. *Circ Res* 1970; 26: 419-428.
- Narayanan N. Effects of adrenalectomy and in vivo administration of dexamethasone on ATP-dependent calcium accumulation by sarcoplasmic reticulum from rat heart. *J Mol Cell Cardiol* 1983; 15: 7-15.
- Narayanan N, Khandelwal RL. Microsomal phosphorylase in rat heart: depletion following adrenalectomy and restoration by in vivo administration of dexamethasone. *Endocrinology* 1985; 117: 1544-1549.
- Cleghorn RA. Cardiovascular failure in experimental adrenal insufficiency: a historical revival. *Perspect Biol Med* 1983; 27: 135-155.
- Kacsoh B. Adrenal gland. In: *Endocrine Physiology*. New York: McGraw-Hill, 2000; 360-447.
- Antman EM, Tanasijevic MJ, Thompson B, Schactman M, McCabe CH, Cannon CP, et al. Cardiac-specific troponin I levels to predict the risk of mortality in patients with acute coronary syndromes. *N Engl J Med* 1996; 335: 1342-1349.
- Willis FR, Byrne GC, Jones TW. Fludrocortisone induced heart failure in Addison's disease. *J Paediatr Child Health* 1994; 30: 280-281.
- Towbin JA. Myocarditis and pericarditis in adolescents. *Adolesc Med* 2001; 12: 47-67.
- Pulakhandam U, Dincsoy HP. Cytomegaloviral adrenalitis and adrenal insufficiency in AIDS. *Am J Clin Pathol* 1990; 93: 651-656.
- Agus MS, Agus ZS. Cardiovascular actions of magnesium. *Crit Care Clin* 2001; 17: 175-186.
- Bloom S. Magnesium deficiency cardiomyopathy. *Am J Cardiovasc Pathol* 1988; 2: 7-17.

18. Montoli A, Colussi G, Minetti L. Hypercalcaemia in Addison's disease: calciotropic hormone profile and bone histology. *J Intern Med* 1992; 232: 535-540.
19. Raisz LG, Kream BE. Regulation of bone formation (second of two parts). *N Engl J Med* 1983; 309: 83-89.
20. Raisz LG, Kream BE. Regulation of bone formation. *N Engl J Med* 1983; 309: 29-35.
21. Walker DA, Davies M. Addison's disease presenting as a hypercalcemic crisis in a patient with idiopathic hypoparathyroidism. *Clin Endocrinol (Oxf)* 1981; 14: 419-423.
22. Endoh M. Acidic pH-induced contractile dysfunction via downstream mechanism: identification of pH-sensitive domain in troponin I. *J Mol Cell Cardiol* 2001; 33: 1297-1300.
23. Boles RG, Roe T, Senadheera D, Mahnovski V, Wong LJ. Mitochondrial DNA deletion with Kearns Sayre syndrome in a child with Addison disease. *Eur J Pediatr* 1998; 157: 643-647.

