

REVIEW

Australian Dental Journal 2002;47:(1):2-11

Specific orofacial problems experienced by musicians

DKL Yeo,* TP Pham,† J Baker,‡ SAT Porter§

Abstract

Background: Patients who play musical instruments (especially wind and stringed instruments) and vocalists are prone to particular types of orofacial problems. Some problems are caused by playing and some are the result of dental treatment. This paper proposes to give an insight into these problems and practical guidance to general practice dentists.

Method: Information in this paper is gathered from studies published in dental, music and occupational health journals, and from discussions with career musicians and music teachers.

Results: Orthodontic problems, soft tissue trauma, focal dystonia, denture retention, herpes labialis, dry mouth and temporomandibular joint (TMJ) disorders were identified as orofacial problems of career musicians. Options available for prevention and palliative treatment as well as instrument selection are suggested to overcome these problems.

Conclusions: Career musicians express reluctance to attend dentists who are not sensitive to their specific needs. General practitioner dentists who understand how the instruments impact on the orofacial structures and are aware of potential problems faced by musicians are able to offer preventive advice and supportive treatment to these patients, especially those in the early stages of their career.

Key words: Musicians, musical instruments, orofacial problems, soft tissue lesions, malocclusion.

(Accepted for publication June 2000.)

INTRODUCTION

With the popularity of musical instruments, dentists are treating an increasing number of musicians of all ages and abilities, some of whom will experience orofacial problems as a result of their chosen career or pastime. The treatment of orofacial problems may, in turn, have adverse consequences for the players of woodwind instruments, some stringed instruments (violin and viola) and vocalists. A mutual understanding

between the dentist and the musician is necessary to provide accurate diagnosis and appropriate dental therapy of these specific orofacial problems.

In diagnosing orofacial problems that may be related to musical instruments, patients should be questioned about the frequency and duration of their musical sessions. It is beneficial for patients to demonstrate to the dentist how their musical instruments are played.¹ By observing and understanding how the instrument impacts on the orofacial structures, the dentist can gain a greater understanding of the patient's radiographs and study models. Arriving at an appropriate treatment plan that addresses the musician's special needs may involve referral to dental specialists.

Table 1 summarizes the playing positions of the five groups of wind instruments (single-reed instruments; double-reed instruments; instruments with a small mouth aperture; brass instruments; and the bagpipes) and the two string instruments (violin and viola). Each musical instrument is played differently with unique influences on the orofacial structures.

Wind instruments

Playing a wind instrument is a complex neuromuscular task that requires increased ventilation and increased orofacial muscle activity.^{2,3} To play a wind instrument, an embouchure must be formed whereby the lips, tongue and teeth are applied to the mouthpiece to act as both a seal and a funnel for the air. The relationship between embouchure, the palate, and the muscles of respiration, controls sound production particularly in tone, quality, dynamics and articulation. The different mouthpiece on each wind instrument requires a unique muscular pattern to form the embouchure. Some individuals have dental and facial features which readily facilitate the formation of an embouchure. Others have orofacial features which necessitate compensatory movements of the mandible and muscles of the head and neck that may create later problems. To ignore the physical requirements of forming a correct embouchure in the selection of an instrument may limit a musician's ability to play to his or her full potential.² Table 2 lists the orofacial features that can compromise the embouchure in wind instrument players.

*General Practitioner, Music Teacher (Piano, Clarinet), Freelance Composer.

†General Practitioner.

‡Music Teacher (Flute, Clarinet, Saxophone, Trumpet, Trombone, Piano).

§Lecturer, Community Dentistry, The University of Queensland.

Table 1. The playing positions of wind and string instruments

Wind instruments

- Single-reed instruments (e.g., clarinet, saxophone, bass clarinet)
The instrument is played intra-orally with a wedge-shaped mouthpiece that has a single bamboo reed attached to its underside. The maxillary incisors rest on the sloping upper surface of the mouthpiece, while the lower lip is placed between the lower surface of the mouthpiece and the mandibular incisal edges.
- Double-reed instruments (e.g., oboe, bassoon, cor anglais, double bassoon)
The instrument is played intra-orally with a mouthpiece made from two bamboo reeds bound together with a cord. The mouthpiece is placed between the upper and lower lips, which covers the underlying incisal edges.
- Instruments with a small mouth aperture (e.g., flute, piccolo)
The instrument is played extra-orally by rolling the lower lip along the lip plate of the mouthpiece while the upper lip is pushed downward to form a small 'O' shape opening for directing the air towards the opposite rim of the blow hole. Some of the air is caught against the lip of the hole and begins vibrating as it enters the instrument.
- Brass instruments (e.g., trumpet, French horn, trombone, tuba, euphonium, tenor horn)
The instrument is played extra-orally by pursing the lips against the metal cup-shaped mouthpiece.
- Bagpipes (e.g., Scottish Highland bagpipe)
The bagpipe is played by blowing through a blowpipe into a hide bag held under the arm. Air is squeezed by the player's arm and distributed through large drone pipes, providing background harmony, and a smaller chanter pipe, on which the melody is played. Inside the pipes are reeds which vibrate as the air is forced out.

String instruments - Violin and viola

- The instrument is braced between the left shoulder and inferior border of the mandible, with the teeth often clenched to stabilize the mandible and prevent its deflection to the right. The playing position can vary from one in which it is held directly in front of the person to one in which the instrument is straight to the left.

Orofacial problems common across instrument groups

Musicians report a variety of orofacial problems, which interfere with their playing or cause general discomfort, some are common to all players, others are specific to a particular instrument. Those common across instrument types include orthodontic problems, soft tissue trauma, focal dystonia, denture retention, herpes labialis, dry mouth, and the consequences of routine dental treatment. Table 3 summarizes the orofacial problems experienced by musicians and the corresponding therapeutic options.

Orthodontic implications

Certain factors may combine during the playing of musical instruments to alter the equilibrium between dental and skeletal structures and produce malocclusion. These include the type of mouthpiece, the number of hours the instrument is played, the

position of the teeth, and the forces introduced by the tongue and facial muscles during playing.^{2,4,5}

Forces produced by the playing of wind instruments are larger than forces produced by average muscle contractions and approach the pressure levels of maximum lip effort. They may reach levels of sufficient magnitude, duration and direction to produce a malocclusion or help to correct one.^{2,6} The optimal force for orthodontic tooth movement (tipping, rotation, extrusion) is 35-60 grams exerted usually over six hours,⁷ whereas the mean force exerted by three different wind instrument groups is substantially greater (flute 211 grams, reed 270 grams, brass 500 grams).⁶ These forces are potentially harmful to teeth and the occlusion if exerted for sufficient time.^{2,4,5}

Controversy exists about the orthodontic effects on adult musicians from playing a wind instrument. Whilst one study of professional musicians (ages 18-61)⁸ reported greater than normal overjets in single-reed instrumentalists and retroclined mandibular incisors in both single reed and brass musicians, another study reported only minor movements.⁹ Reasons offered for the latter result are that the different forces on the teeth are balanced or that the total duration of the force is too short to move teeth.⁹ In addition, many professional musicians play several wind instruments and the resulting influences on the dentition may be in different directions.¹⁰ Fortunately for many amateur musicians, daily practice lasts for 90 minutes or less and is usually not long enough to bring about significant dental or skeletal changes. In contrast, serious wind musicians practice more than three hours daily which may be harmful and will require greater dental supervision.^{3,7,8}

Studies conducted on children younger than 15 years who play wind instruments report an increased overjet for reed players and a retroinclination of mandibular incisors in brass players as mentioned earlier.^{5,11} Children

Table 2. Orofacial features that compromise the embouchure in wind musicians

- Lip
Poor lip control²
Short lips^{19,26}
Lip irritation/sores/ulcers^{2,26}
Lip and facial muscle fatigue²
Asymmetry of face and lips¹³
- Tongue
Tongue thrusting habits³
- Teeth
Crowded, overlapping and sharp teeth^{2,4,13,19}
Rotated, elongated or misplaced teeth^{4,13,19,26}
Severe maxillary or mandibular anterior teeth protrusion⁴
Severe posterior crossbite^{4,13}
Deep overbite¹³
Anterior open bites¹³
Diastemata between anterior teeth^{2,4,13,26}
Unreplaced congenitally missing or extracted teeth^{2,4,13}
Loose and painful incisors²⁶
- Jaw
Temporomandibular joint pain²
Severe skeletal class II and III discrepancy¹³

Table 3. Orofacial problems experienced by musicians and therapeutic options

Orofacial problem	Instrument	Therapeutic options
<p>Orthodontic problems:</p> <ul style="list-style-type: none"> • Proinclination of maxillary incisors^{5,8,11} • Retroinclination of maxillary incisors^{5,6,11} • Retroinclination of mandibular incisors^{5,8,11} • Deep anterior overbite^{8,13} 	<ul style="list-style-type: none"> Clarinet Saxophone Brass Clarinet Saxophone Clarinet Saxophone Violin Viola Violin Viola 	<p>Leave alone unless compromise embouchure. Close supervision if practice more three hours per day especially in children.</p> <p>Refer to orthodontist if required.</p>
<p>Posterior crossbite¹³</p>	<ul style="list-style-type: none"> Violin Viola 	
<p>Focal dystonia^{15,16,17}</p> <ul style="list-style-type: none"> • Decreased control or stiffness of tongue/lip • Decreased control and inco-ordination of lip/cheek • Spasm of lip/cheek and loss of lip seal • Spasm, cramp, decreased control of lip/cheek 	<ul style="list-style-type: none"> Bassoon Trumpet French horn Trombone 	<p>Early diagnosis; psychotherapeutic, physical and behavioural techniques.</p>
<p>General oral and dental problems:</p> <ul style="list-style-type: none"> • Dental prostheses: reduced retention and stability⁴ • Fracture of incisal restorations²³ • Incisal wear of maxillary anterior teeth¹¹ • Devitalization of maxillary incisors¹² 	<ul style="list-style-type: none"> Woodwind Brass Woodwinds Brass Clarinet Saxophone Clarinet Saxophone 	<p>Mechanical denture aids, embouchure dentures; implants. Acrylic lip shield; maximum retention. Rubber patch or elastoplast on upper surface of mouthpiece. Prevention by acrylic lip shield, palatal splint or shortening of incisors to balance load.</p>
<ul style="list-style-type: none"> • Dry Mouth²¹ 	<ul style="list-style-type: none"> Wind instruments Strings Voice 	<p>Rehydration and oral hygiene advice; stress management techniques.</p>
<ul style="list-style-type: none"> • Irritation and scarring of labial mucosa^{1,2,4} 	<ul style="list-style-type: none"> Woodwind Brass 	<p>Round sharp edges, polish restorations, acrylic or metal lip shield.</p>
<ul style="list-style-type: none"> • Increased salivation⁴ 	<ul style="list-style-type: none"> Woodwinds Brass 	<p>Oral hygiene advice; remove calculus; antibiotics for bacterial sialadenitis in oboe players.</p>
<ul style="list-style-type: none"> • TMJ disorders^{2,4,8,11,12,30,33} 	<ul style="list-style-type: none"> Clarinet Saxophone Trombone Tuba Violin Viola Voice 	<p>Occlusal splints; physical therapy; reduce playing time; modify shoulder rest for string players.</p>
<ul style="list-style-type: none"> • Dermatitis; Eczematous lesions^{2,14,31} 	<ul style="list-style-type: none"> Clarinet Saxophone Flute Piccolo Brass Violin Viola 	<p>Refer to dermatologist for allergen testing; control skin dampness; reduce playing time; reduce pressure; alter posture, custom made chin pad or rest, gold-plated mouthpiece; grow beard.</p>
<ul style="list-style-type: none"> • Herpes Labialis²⁰ 	<ul style="list-style-type: none"> Woodwind Brass Voice 	<p>Stress management; astringent for drying and crusting of lesion; acyclovir cream; oral acyclovir prophylaxis.</p>
<ul style="list-style-type: none"> • Distortion of vowel and consonant production¹³ 	<ul style="list-style-type: none"> Voice 	<p>Check malocclusion, spacing, angulation and thickness of teeth.</p>

usually make their choice of preferred instrument before the development of the roots of permanent teeth and related bones is complete.^{2,12} This coincides with the time when occlusal change due to playing the instrument is most likely.² Serious wind instrument playing is best delayed until after this period or the selection of an instrument is made to maximize favourable orthodontic movement.^{5,11} An alternative is for the child to play different instruments during this period.¹⁰

Using wind instruments that are suited to a patient's dental occlusion can assist orthodontic treatment, particularly for children 11 to 13 years of age.^{5,13} If chosen correctly, instruments may assist in tooth movement during treatment or in maintaining stability of movement after treatment. Alternatively, they can delay or even destroy what orthodontists are trying to accomplish.⁵ The duration of retainer use depends upon the choice of instrument. As a guide, brass instruments can help to reduce overjet and decrease overbite. Single-reed instruments tend to increase overjet and overbite, and double-reed instruments tend to reduce overjet and increase overbite. Instruments with a small aperture can help to reduce overjet, increase overbite and may benefit a person with a short or weak upper lip or a protruding lower lip.⁵

Soft tissue trauma

In the course of playing a wind instrument, trauma to the lips and cheek can be felt after a lengthy practice

session. This usually leads to pain and ulceration which can interfere with the formation of the embouchure and the quality of performance. This is especially so during fixed orthodontic treatment. The use of wax, removal of protruding, sharp, or rough surfaces, and the polishing of brackets and teeth is recommended.¹³ An acrylic lip shield can help reduce irritation and protect the anterior teeth from excessive backward pressure.² Patients will sometimes resort to their own 'shields' such as soft material, rubber, tape or folded tissue paper to cushion the impact of the teeth on the soft tissue although the additional bulk is rejected by some musicians. Commercial lip guards are also available.^{2,14}

Focal dystonia

Focal dystonia, also known as occupational cramp, is a relatively uncommon condition. Whilst first observed in pianists' hands, focal dystonia has been reported in violinists and musicians who play both woodwind and brass instruments. The focal dystonia in muscles of the lips, face, jaw and tongue results in a loss of control of the muscles of the embouchure. The condition is painful but not as painful as overuse syndrome. Early diagnosis is beneficial and the condition should be considered in a differential diagnosis where the pain cannot be explained by any other pathology. Referral to a neurologist may be necessary. Treatment may include physical, psychotherapeutic or behavioural techniques. While these are often helpful, singly or in combination,

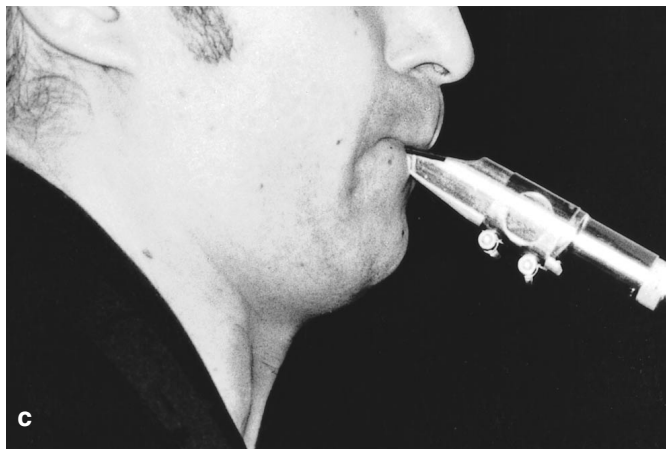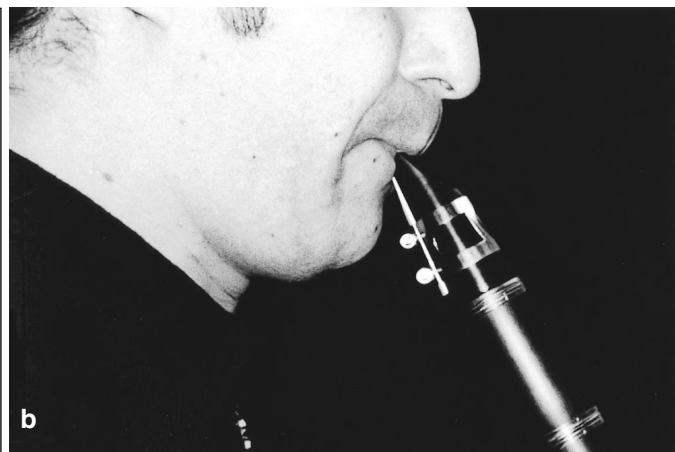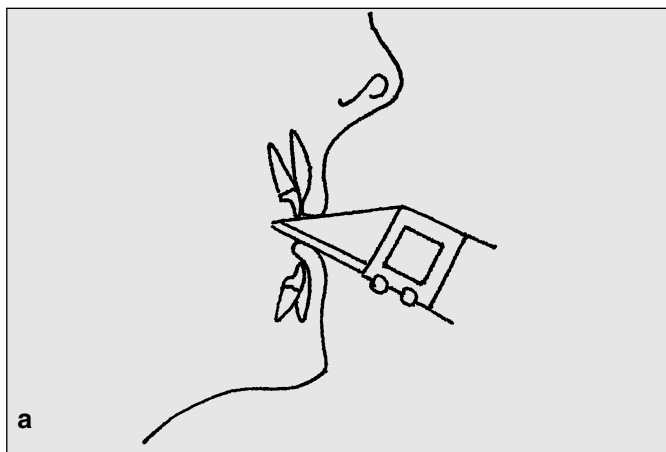


Fig 1. The playing position of the single-reed instrument. (a) A diagrammatic illustration of the embouchure for the single-reed instrument (modified from Howard and Lovrovich²). (b) The clarinet embouchure, lateral view. (c) The saxophone embouchure, lateral view.

focal dystonia is very resistant to therapy (or even long periods of rest) and may curtail a musical career.^{15,16,17}

Dental prostheses

Splints, lip shields, partial and full dentures all intrude on the embouchure and require co-operation and re-adjustment by the patient if a satisfactory result is to be achieved. The problems which are encountered by wearing prosthetic appliances during playing are two-fold – painful soft tissue lesions and a risk to the embouchure. Reducing bulk, smoothing the labial aspects of dentures, splints or shields, and having blunt

or rounded incisal edges on teeth will reduce labial soreness. Appliances are subjected to considerable intra-oral air pressure and muscle forces that may reduce their retention and stability. Several methods have been advocated to overcome these problems. Osseointegrated titanium implants are reported as having a 95 per cent long-term success rate.² A personalized embouchure can be manufactured using soft compressible acrylic over a denture to increase stability and reduce soft tissue discomfort.² A third means of increasing denture stability is to construct a special ‘embouchure denture’ for use whilst playing.

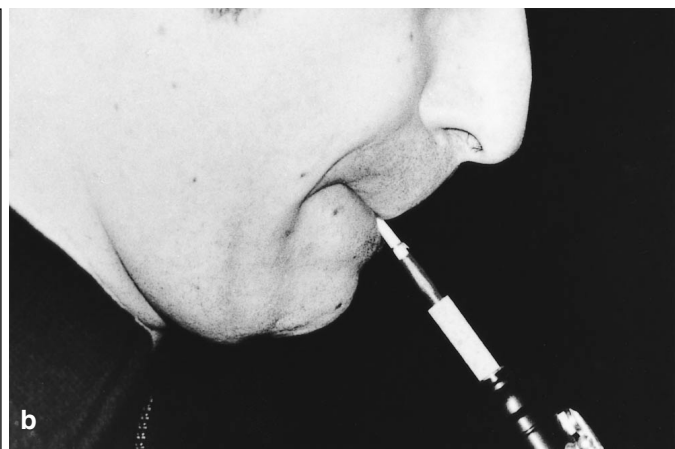
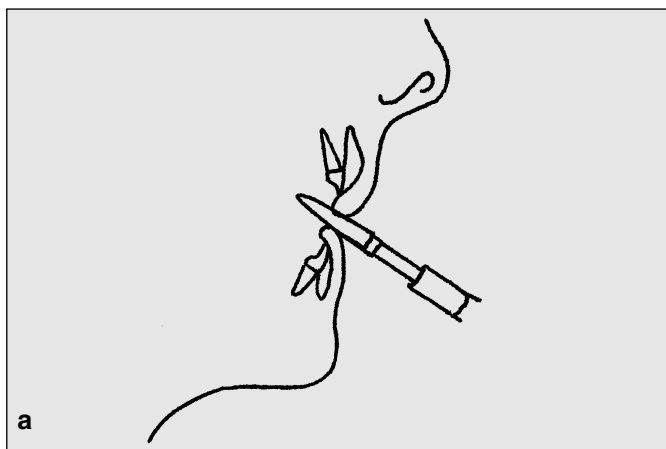


Fig 2. The playing position of the double-reed instrument. (a) A diagrammatic illustration of the embouchure for the double-reed instrument (modified from Howard and Lovrovich²). (b) The oboe embouchure, lateral view.

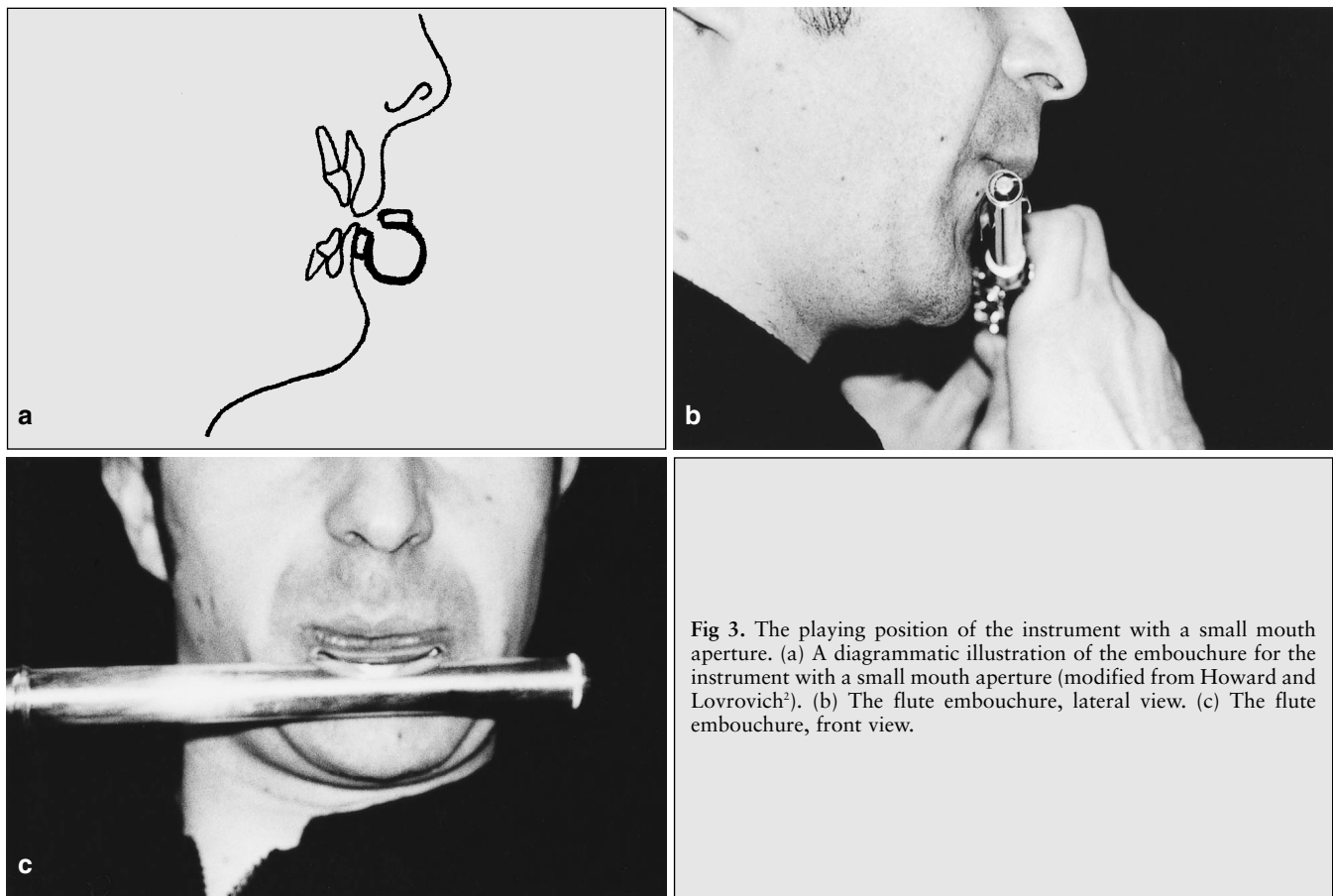


Fig 3. The playing position of the instrument with a small mouth aperture. (a) A diagrammatic illustration of the embouchure for the instrument with a small mouth aperture (modified from Howard and Lovrovich²). (b) The flute embouchure, lateral view. (c) The flute embouchure, front view.

This denture is constructed with interlocking inclined planes and with a bite-opening customized to the position of the instrument.^{2,4,18} If extractions become necessary it is important to replace the missing tooth (especially anterior teeth) as soon as possible to preserve the embouchure.^{2,4,18} In constructing crowns attention should be paid to reproducing a similar bulk to the original, reducing spaces, and rounding or blunting edges.¹⁹

Herpes labialis

Labial herpetic lesions are precipitated by mechanical trauma of the lips during playing, and outbreaks are more common during times of stress such as around the time of a performance. Twice as many wind musicians (34 per cent) as non-musicians experience herpetic outbreaks. Whilst there is no difference in the incidence between wind musicians, woodwind players tend to have outbreaks on the lower lip and brass instrument players on the upper lip. The use of 5% Acyclovir cream is recommended. However, wind musicians who suffer frequent outbreaks require prophylactic oral acyclovir.^{14,20}

Dry mouth

During the playing of a wind instrument more saliva is produced than usual and it tends to collect in the floor of the mouth where it remains until swallowed.⁴ However, nervousness especially associated with

performances, is common and may produce a dry mouth which interferes with playing.^{2,21} The duration of performance and practice, increased anxiety and constant intake of air combine to increase the need for fluids. Whilst in the experience of the authors, plain water is the preferred drink used by musicians for rehydration during practice, the dentist should explain the potential for erosion from acidic beverages and the consequences to the musician. The subsequent worn, rough or sharp incisal edges can traumatize or irritate the labial mucosa and compromise the formation of the embouchure.^{2,4} Furthermore, tooth sensitivity caused by erosion can be exacerbated by the frequent rapid deep intake of air required during playing.¹⁹

Routine dental treatment

Dentists who are treating wind instrument players should warn them of the potential for self-inflicted injury following local anaesthesia and take care in smoothing restorations and reducing sharp edges on teeth. The patient should be warned of any unavoidable changes, however slight, to tooth morphology following treatment so that readjustment time for tongue and lips can be anticipated and reduced.^{2,4,12} As mobile teeth are severely detrimental to playing, oral hygiene practices should be stressed to these musicians.

Due to the intra-oral pressure generated, the wind musician is advised not to resume playing for two weeks following a simple extraction and for a month or

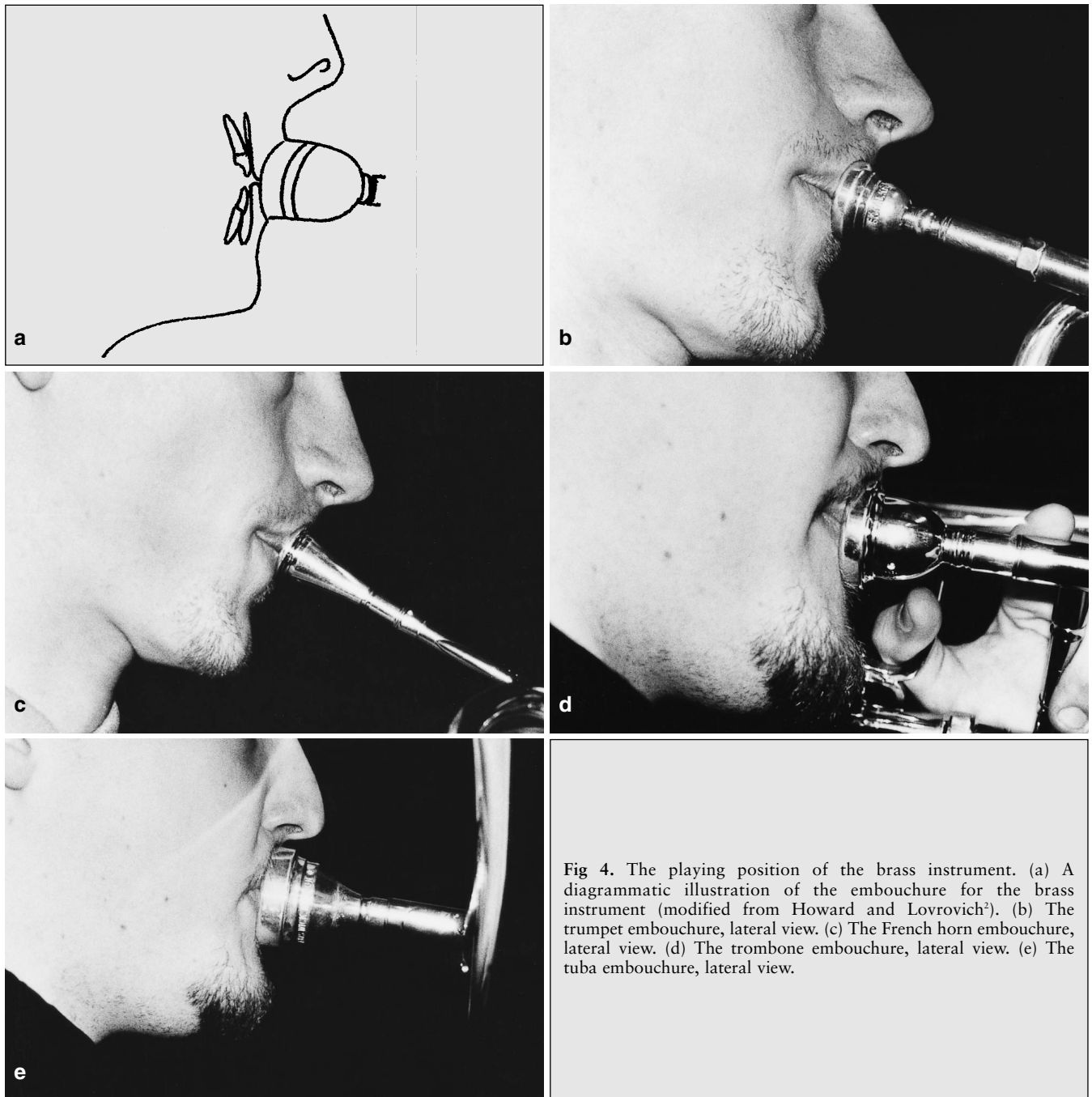


Fig 4. The playing position of the brass instrument. (a) A diagrammatic illustration of the embouchure for the brass instrument (modified from Howard and Lovrovich²). (b) The trumpet embouchure, lateral view. (c) The French horn embouchure, lateral view. (d) The trombone embouchure, lateral view. (e) The tuba embouchure, lateral view.

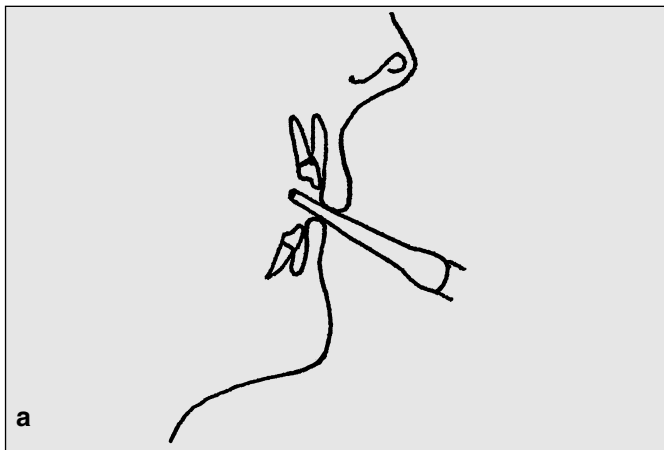
more following surgical removal of impacted third molars. Adequate time should be allocated for healing to occur, particularly for extractions in the maxillary arch where the high intra-oral pressure may cause a rupture into the maxillary sinus which can seriously incapacitate the musician. The recovery period following extractions depends on the number of teeth extracted, their location and the extent of the surgical procedure. Study models prior to extractions are advisable if replacement teeth are planned. Where possible, endodontic treatment should be undertaken rather than extractions especially in maxillary posterior teeth. Where removal of wisdom teeth is planned in adolescents who play wind instruments, it should occur prior to root formation to minimize the extent of trauma.^{2,12,22}

Orofacial considerations specific to instrument groups

Single-reed instruments

The single-reed instrument is played intra-orally with a wedge-shaped mouthpiece (Fig 1). The major part of its weight rests on the lower lip supported by the mandibular anterior teeth. There is also a lingual pressure on the maxillary anterior teeth.^{1,2,4}

The pain caused by any irregularity or sharpness of the lower anterior teeth from crowded, chipped or worn teeth cutting into the lip may hinder playing. Some degree of hyperkeratinization may reduce the pain. However, it can be alleviated by rounding and polishing the sharp edges or by small acid-etched composite restorations. A lip shield may solve chronic



a

Fig 5. (a) A diagrammatic illustration of the embouchure for the bagpipe. (b) The playing position of a Scottish Highland bagpipe.



lip irritation and increase playing time as well as protecting incisal restorations.^{2,3,4,14}

The maxillary anterior teeth may suffer incisal wear from frictional contact with the hard inclined plane of the mouthpiece and incisal corner restorations or crowns in these teeth are vulnerable. A rubber patch or elastoplast placed on the upper surface of the mouthpiece may reduce sliding and wearing of the upper anterior teeth. An acrylic lip shield may be constructed over the upper incisors and canines to relieve pressure on restorations and to spread the load over the remaining sound incisors and canines.²³

For clarinet and saxophone players with a deep over-bite, the maxillary central (and sometimes lateral) incisors suffer pulpal changes and can be devitalized by the excessive apically directed pressure caused by resting heavily on the mouthpiece.^{2,12} Endodontically-treated incisors can also experience periapical irritation and should be adequately protected from pressure by an acrylic lip shield, palatal splinting or careful shortening of the incisors to distribute the pressure across several teeth.^{12,23}

An eczematous dermatitis called 'clarinetist's cheilitis' can occur in the area where the wooden reed contacts the skin. It occurs on the median portion of the vermilion border of the lower lip and extends onto the chin. This reaction is attributed to pressure, friction,

and moisture (saliva or perspiration) under the lower lip.^{2,14} Single-reed instrumentalists salivate more than other musicians with an associated increase in calculus formation but the view once held that they experience more periodontal problems than others⁴ is not supported by later research.^{24,25} It is found that neither increased alveolar bone loss nor increased periodontal disease is evident in wind instrumentalists in the presence of good oral hygiene.²⁴

Double-reed instruments

The oboe has a contoured mouthpiece and is played intra-orally (Fig 2). The incisal surfaces of the teeth are covered by the lips and the mouthpiece is between the lips.^{1,2,4} The upper lip has to be stretched downwards under the incisors and backwards into the mouth. Double-reed instrumentalists are most susceptible to pain, ulceration or hyperkeratosis if teeth or restorations are crowded, sharp or rough and a person with a short upper lip will find this instrument difficult to play.^{1,2,26} In maintaining a controlled airflow through the narrow aperture between the reeds, these musicians produce a higher sustained intra-oral pressure than other wind players. Saliva, forced back into the parotid duct, may result in a bacterial infection with blockage of the duct and painful swelling, treatable with antibiotics but difficult to prevent.²



Fig 6. The proper violin position: the violin is held straight to the left, parallel to the floor by the shoulder and chin.

Instruments with a small mouth aperture

For flute and piccolo players the instrument rests against the lower lip and the upper lip is stretched down to form a small aperture (Fig 3). A precise and delicate stream of air, controlled by the muscles of the embouchure particularly the risorius and the modiolus, is directed into the mouthpiece.^{4,19,26} A short upper lip, buccally displaced maxillary canines or excessively irregular mandibular anterior teeth will compromise the embouchure and create difficulty in playing the flute or piccolo.^{4,19}

'Flautist's chin' is an eczematous lesion similar in appearance and aetiology to that of clarinet players. Perioral dermatitis may also occur in women of child-bearing age. As flutes often contain metal, sensitivities to nickel, chromium or other alloys may occur. Men may grow a beard as protection.^{2,14}

Brass instruments

The various brass instruments are played with the lips inside the metal cup-like mouthpiece and the incisors aligned vertically (Fig 4).^{1,2} Because of the importance of lip vibration in playing brass instruments, the embouchure is even more important to this player than other wood-wind players.²⁷ Pressure of the metal mouthpiece can cause pain or discomfort if the lips are pressed against rotated or rough teeth, the corners of teeth with adjacent spaces, or with protruded teeth.^{1,4,26} The vibration against the mouthpiece can cause friction and painful dry red lips.¹ The use of lip shields may alleviate pain but create fatigue. Metal shields are more satisfactory than acrylic ones.²⁷

Bruxism and temporomandibular joint (TMJ) problems are more prevalent in brass instrument players, the latter due to the protrusion of the mandible during embouchure formation. Treatment may include appliances worn at night, stress management and anti-inflammatory drugs.^{1,2,28} A higher incidence of crepitus and clicking was found in trombonists and tuba players compared to non-musicians.⁸

In addition to dry lips mentioned earlier, brass players can develop calluses on their upper lips. Their



Fig 7. A variation of the violin position: the violin is held in front of the person.

playing can be effected by fibrous bands within the orbicularis oris muscle, and contact dermatitis from allergies to nickel, chrome or metal alloys used in the mouth piece or to the polishing solutions used. Treatment for these problems may include surgery, gold plating of the mouthpiece and alternative solutions for cleaning the instrument.¹⁴

Bagpipes

In playing a Scottish Highland bagpipe, the piper fills a bag with air from a blowpipe (Fig 5) and uses arm pressure to distribute the air through drones and a chanter. Constant air pressure is maintained by deep breaths and some pipers use the tip of their tongue to seal the blowpipe whilst drawing breath to fill the bag.²⁹ Few orofacial problems have been reported in pipers. Personal comments made to the authors indicate a tendency to suffer from dry mouth.

Orofacial problems for string instrument players

The playing positions of the violin and viola are similar and can vary during a performance (Fig 6, 7). The violin is smaller than the viola (Fig 8). The instrument is held parallel to the floor between the shoulder and the jaw but with the position and pressure of the jaw and shoulder constantly changing.^{1,13} The teeth are often clenched and in crossbite.¹ An observation made to the authors was that the pressure exerted in supporting the viola during playing has resulted in fracturing of molar cusps in some individuals.

Violinists and violists report neck pain more frequently than the population norm (40 per cent compared with 14 per cent)² and pain in the masseter and temporalis muscles.¹ They are also prone to TMJ disorders, particularly pain in the region of the right TMJ, due to the pressure on the mandible of holding the instrument and the clenching of the masticatory muscles. In some cases, small repeated injuries can cause pathological remodelling of the right TMJ.^{1,2} A case has been reported of premature degenerative TMJ disease with condylar irregularities and a severely



Fig 8. The size difference between the violin (left) and viola (right) is demonstrated. Note that the viola is larger than the violin.

reduced right TMJ space in a young violinist due to the constant pressure of holding the violin against the left inferior border of the mandible.³⁰ Treatment options for TMJ disorders and neck pain include modification of the shoulder rest, use of occlusal splints, physiotherapy and stress management.¹ Resting the instrument on the clavicle, chewing sugarfree gum during practice, and sitting rather than standing have been suggested to the authors as measures which have given some relief to players.

'Fiddler's neck' is commonly found in violin (59 per cent) and viola (67 per cent) players where the instrument rests on the left side of the neck. This can range from a chronic dermatitis to serious infection and severe pain.³¹ Contributing factors include pressure, friction, perspiration and poor hygiene, and may also include allergy to some wood. It is important to rule out more serious diseases, such as cervical lymphadenopathy associated with malignancy, and diseases of the salivary gland. To reduce the incidence of the 'fiddler's neck', a custom-made chin rest is recommended for the violin or viola player. Other treatment options include altering posture, padding of the chin rest, shorter practice times, growing a beard (although follicle irritation may occur) and placing a cloth between the instrument and the neck.^{1,14,31}

Orofacial problems for vocalists

Sound for the voice is produced in a similar way to wind instruments – a combination of air and vibration. Air under pressure passes from the lungs to vibrate the vocal folds. The sound produced is modified by the pharynx, oral cavity and nasal cavity.³² The frequency, loudness and timbre of the sound can be hindered by changes to, or disease in the oral cavity such as ulceration or tenderness of the tongue and soft tissue of the mouth; infection which may spread to other tissues; malocclusion such as spacing or interference with the tongue or lips; missing teeth; and any alteration to the shape or bulk of teeth.¹³ To avoid possible distortions in vowel and consonant production, dentists should try to maintain the existing angulation and thickness of the teeth.

Vocalists may subject their jaws to a range of unnatural positions in the hope of achieving a desired result during singing and may suffer TMJ problems as a result.³³ Vocalists are also prone to recurrent herpes simplex during periods of stress.¹⁴ A moist oral environment is necessary for singing, but during performance or practice a dry throat and mouth may develop. The authors noted that singers generally tend to rehydrate with water because the acid in fruit juice has a burning effect on their throat and the sugar in soft drinks causes excessive production of phlegm. Both are avoided.

SUMMARY

For those musicians who play wind instruments and for violinists, violists and vocalists, orofacial problems may be detrimental to their careers. These problems may result from playing an instrument or from dental treatment. They are summarized, with possible options for treatment, in Table 3. The prevalence of orofacial problems increases with stress and stress management techniques may be sufficient to contain many problems.³⁴

As an occupational group, professional musicians are conscious of the need for oral health. They are more conscientious about dental attendance and oral hygiene habits than a similar population of non-musicians and have a lower number of missing teeth. However, few musicians report receiving oral health instruction specific to their playing needs.^{25,35} One brass player, felt so strongly about the importance of her lips and mouth that she was reluctant to attend a dentist who did not understand and share her concerns.² Music teachers, who can anticipate and observe early signs of trouble, should be offered the opportunity to increase their knowledge of common orofacial conditions for the benefit of their pupils. Some music teachers have come to realize the importance of a dental evaluation before an individual selects an instrument to study seriously and dentists may receive such referrals.

Dentists need to be aware of the impact of musical instruments on the oral cavity and the impact of their treatment on musicians. There would appear to be a need for dentists to extend their oral health instruction

and preventive advice to provide information that is relevant to musicians, their parents and their music teachers.

ACKNOWLEDGEMENTS

The authors express appreciation to the Australian Music Academy (Queensland) for help with the illustrations, and particularly to the musicians photographed for their ready co-operation.

REFERENCES

1. Zimmers PL, Gobetti JP. Head and neck lesions commonly found in musicians. *J Am Dent Assoc* 1994;125:1487-1496.
2. Howard JA, Lovrovich AT. Wind instruments: their interplay with orofacial structures. *Med Probl Perform Art* 1989;4:59-72.
3. Prenskey HD, Shapiro GI, Silverman SI. Dental diagnosis and treatment for musicians. *Spec Care Dentist* 1986;6:198-202.
4. Herman E. Dental considerations in the playing of musical instruments. *J Am Dent Assoc* 1974;89:611-619.
5. Herman E. Influence of musical instruments on tooth positions. *Am J Orthod* 1981;80:145-155.
6. Engelman JA. Measurement of perioral pressures during playing of musical wind instruments. *Am J Orthod* 1965;51:856-864.
7. Proffit WR. The biological basis of orthodontic therapy. In: Rudolph P, eds. *Contemporary orthodontics*. 3rd edn. St. Louis: Mosby, 2000:296-325.
8. Gualtier PA. May Johnny or Janie play the clarinet? The Eastman study: a report on the orthodontic evaluations of college-level and professional musicians who play brass and woodwind instruments. *Am J Orthod* 1979;76:260-276.
9. Rindisbacher T, Hirschi U, Ingervall B, Geering A. Little influence on tooth position from playing a wind instrument. *Angle Orthod* 1990;60:223-228.
10. Fuhrmann S, Schupbach A, Thuer U, Ingervall B. Natural lip function in wind instrument players. *Eur J Orthod* 1987;9:216-223.
11. Brattström V, Odenrick L, Kvam E. Dentofacial morphology in children playing musical wind instruments: a longitudinal study. *Eur J Orthod* 1989;11:179-185.
12. Porter MM. The embouchure and some of its endodontic problems. *J Br Endod Soc* 1975;8:27-28.
13. Herman E. Orthodontic aspects of musical instrument selection. *Am J Orthod* 1974;65:519-530.
14. Harvell J, Maibach HI. Skin disease among musicians. *Med Probl Perform Art* 1992;7:114.
15. Lederman RJ. Occupational cramp in instrumental musicians. *Med Probl Perform Art* 1988;3:45-51.
16. Lockwood AH. Medical problems of musicians. *N Engl J Med* 1989;320:221-227.
17. Brandfonbrener AG. Musicians with focal dystonia. A report of 58 cases seen during a ten-year period at a performing arts medicine clinic. *Med Probl Perform Art* 1995;10:121-127.
18. Porter MM. Dental problems in wind instrument playing. 6. Single reed instruments – The embouchure denture. *Br Dent J* 1968;124:34-36.
19. Porter MM. Dental problems in wind instrument playing. 7. Double reed instruments. *Br Dent J* 1968;124:78-81.
20. Barkvoll P, Attramadal A. Recurrent herpes labialis in a military brass band. *Scand J Dent Res* 1987;95:256-258.
21. Shoup D. Survey of performance-related problems among high school and junior high school musicians. *Med Probl Perform Art* 1995;10:100-105.
22. Mortenson GC, Kolar LW. Understanding the procedures and risks involved in the extraction of third molars. *Med Probl Perform Art* 1988;3:119-122.
23. Porter MM. Dental problems in wind instrument playing. 3. Single reed instruments - Restorative dentistry. *Br Dent J* 1967;123:489-493.
24. Bergström J, Eliasson S. Alveolar bone height in professional musicians. *Acta Odontol Scand* 1986;44:141-147.
25. Bergström J, Eliasson S. Dental care habits, oral hygiene, and gingival health in Swedish professional musicians. *Acta Odontol Scand* 1985;43:191-197.
26. Porter MM. Dental problems in wind instruments. 1. Dental aspects of embouchure. *Br Dent J* 1967; 123: 393-396.
27. Porter MM. Dental problems in wind instrument playing. 9. Brass instruments (continued). *Br Dent J* 1968;125:183-187.
28. Bejjani FJ. Musculoskeletal and neuromuscular conditions of instrumental musicians. *Arch Phys Med Rehabil* 1996;77:406-413.
29. Potter PJ. Musculoskeletal symptoms associated with the great highland bagpipe. *Med Probl Perform Art* 1993;8:81-83.
30. Reider CE. Possible premature degenerative temporomandibular joint disease in violinists. *J Prosthet Dent* 1976; 35: 662-664.
31. Blum J, Ritter G. Violinists and violists with masses under the left side angle of the jaw known as 'fiddler's neck'. *Med Probl Perform Art* 1990;5:155-160.
32. Hollien H, Brown O, Weiss R. Another view of vocal mechanics. *J Singing* 1999;56:11-22.
33. Taddey JJ. Musicians and temporomandibular disorders: prevalence and occupational etiologic considerations. *J Craniomandibib Pract* 1992;10:241-244.
34. Middlestadt SE, Fishbein M. Health and occupational correlates of perceived occupational stress in symphony orchestra musicians. *J Occupational Med* 1988;30:687-692.
35. Bergström J, Eliasson S. Dental health in professional musicians. *Swed Dent J* 1985;9:225-231.

Address for correspondence/reprints:

Dr Suzette Porter
School of Dentistry
The University of Queensland
200 Turbot Street, Brisbane, Queensland 4000
Email: suzette.porter@mailbox.uq.edu.au