

Transverse cerebellar diameter on cranial ultrasound scan in preterm neonates in an Australian population

M SWAMINATHAN, MW DAVIES, PG DAVIS and FR BETHERAS

Division of Neonatal Services, The Royal Women's Hospital, Melbourne, Victoria, Australia

Objective: Fetal measurement of transverse cerebellar diameter (TCD) has been shown to correlate well with gestational age (GA), even in the presence of growth retardation. The aim of this study was to define the normal range of TCD in preterm neonates in an Australian population between 23 and 32 weeks GA.

Methodology: Infants admitted to the Royal Women's Hospital, Melbourne, having routine cranial ultrasound scans (< 1500 g and/or of gestational age \leq 32 weeks at birth) had their TCD measured on a cranial scan performed during the first 3 days of life. The posterior fossa was examined through the asterion using a General Electric LOGIQ 500 scanner (GE Medical Systems, Waukesha, USA) and TCD measurement was taken in the coronal plane.

Results: 106 infants < 1500 g and/or of GA \leq 32 weeks at birth had their TCD measured between 1 January 1997 and 30 November 1997. Transverse cerebellar diameter and associated 95% confidence intervals are described for infants between 23 and 32 weeks GA. The linear regression equation relating TCD and GA was: TCD (mm) = $-12.9 + 1.61 \times$ GA (weeks). $R^2 = 0.80$, $P < 0.001$.

Conclusion: This is the only study of TCD measurement using cranial ultrasound in a group of preterm newborns, and forms the basis for nomograms of TCD which can be used as a tool to assist in the assessment of GA, even in growth-retarded preterm newborns, and in the diagnosis of cerebellar hypoplasia.

Key words: cerebellum; infant; preterm; transverse cerebellar diameter; ultrasonography.

Normal values for transverse cerebellar diameter (TCD) in fetuses¹ and term newborns^{2,3} have been determined for populations in Japan, United States and Israel. There are no similar data for Australian term neonates and no data in preterm newborns worldwide. The early pregnancy scan is currently the most reliable tool for assessing the gestational age (GA) of the fetus. In cases where an early pregnancy scan has not been performed or in the presence of multiple pregnancies, determining GA using standard antenatal measurements may be inaccurate. The TCD serves as a valid indicator of GA in the fetus and is a standard against which aberrations in other fetal parameters may be compared, especially when the gestational age cannot be determined by the routine methods of an early pregnancy scan or the date of the last menstrual period.^{1,4} It may also be helpful in determining gestational age in newborn infants. Standard measurements of transverse cerebellar diameter can also be used in the diagnosis of cerebellar hypoplasia when the GA is known.¹

The aim of this study was to define the normal range for TCD in preterm newborns to the margins of viability and to determine the relationship between gestational age and transverse cerebellar diameter.

METHODS

Setting

Intensive and Special Care Nurseries, Royal Women's Hospital, Melbourne, Australia.

Subjects

In our unit, routine cranial ultrasound scans are performed on all infants < 1500 g birthweight and/or < 33 weeks GA, on days 1, 3, 7 and 28. From 1 January 1997 to 30 November 1997 there were 302 such babies admitted to our unit. One hundred and six infants had TCD measured at a known GA, ranging from 23 to 32 weeks. Infants whose GA was not known and those with cranio-spinal malformations were excluded. Transverse cerebellar diameter measurements were taken from cranial scans performed on the first 3 days of life. The GA assessment was based upon an early pregnancy scan (< 18 weeks GA) in 83 (78%) or by certain dates (date of last menstrual period) in 23 (22%) if no antenatal scan was performed.

Technique

The posterior fossa was examined using a General Electric LOGIQ 500 scanner (GE Medical Systems, Waukesha, USA), with a 7.5 MHz (megaHertz) probe, using the asterion as the acoustic window. The measurement of TCD was taken in the coronal plane. The widest diameter of the cerebellum was measured (see Fig. 1). The measurements were taken by one of three investigators (MS, MD, FB) and all measurements were validated by the senior neonatal ultrasonologist (FB).

Correspondence: Dr MW Davies, Senior Neonatal Fellow, Division of Neonatal Services, The Royal Women's Hospital, 132 Grattan Street, Carlton, Victoria, 3053, Australia. Fax: 03 93472731; email: mwdavies@ozemail.com.au

M Swaminathan, MB, BS, MD, DCH, Neonatal Fellow. MW Davies, MB, BS, FRACP, DCH, Senior Neonatal Fellow. PG Davis, MD, FRACP, Neonatal Consultant. FR Betheras, MB, BS, FRCOG, FRACOG, DDU, Neonatal Ultrasonologist.

Accepted for publication 24 December 1998.

Statistics

Data were entered and analysed using linear regression in an SPSS database (SPSS Inc., Chicago, USA). The fitted line plot and 95% confidence intervals for TCD versus GA were determined.

RESULTS

The data for the TCD for individual GA groups are summarized in Table 1. The regression equation relating TCD as the dependent variable to GA as the independent variable was: $TCD (mm) = -12.9 + 1.61 \times GA (weeks)$. $R^2 = 0.80$, $P < 0.001$. The figure shows individual measurements, with interpolation lines indicating mean TCD and 95% confidence intervals around individual data points (see Fig. 2).

DISCUSSION

The cerebellum is relatively resistant to disturbances in fetal growth and cranial deformation. In the embryo, the cerebellum appears at the end of the fifth week as a swelling over-riding the fourth ventricle. By 6 weeks, the flocculo-nodular lobes develop,

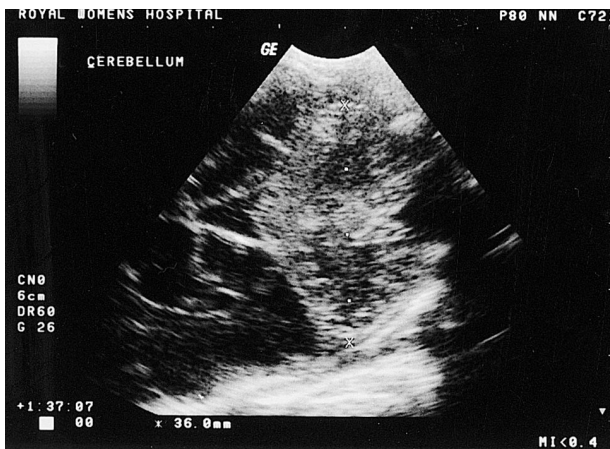


Fig. 1 Measurement of transverse cerebellar diameter on cranial ultrasound scan.

Table 1 Transverse cerebellar diameter by gestational age

Gestational age (weeks)	No. infants	Mean	Standard deviation
23	4	24.2	0.87
24	2	26.1	1.56
25	14	27.4	1.22
26	4	29.4	2.14
27	13	29.9	0.72
28	11	32.4	1.55
29	15	33.6	2.45
30	15	36.4	2.55
31	12	36.6	2.85
32	16	38.5	2.60

followed by bilateral growth of the hemispheres which eventually meet in the midline. The folia of the vermis begin to develop by 13 weeks and the lamellae are evident by 15 weeks paralleling the growth of the cerebellar hemispheres.⁵ The cerebellum lies in the posterior fossa and is surrounded laterally by the dense petrous ridges of the temporal bones and inferiorly by the occipital bone. The petrous ridges are aligned perpendicular to the plane of maximum extrinsic compression experienced *in utero* by the foetal head. Thus the cerebellum and posterior fossa are more resistant to deformation by extrinsic pressure than the parietal bones and the corresponding bi-parietal diameter.⁶

Using ultrasound, several authors have observed that the biparietal diameter may be affected by variations in the shape of the skull.^{7,8} McLeary *et al.*⁹ have found on ultrasonography of the foetal skull that the posterior fossa is not affected by the pressure effects, and that cerebellar diameter is a more accurate reflection of gestational age than biparietal diameter particularly in the presence of abnormal skull shapes like brachycephaly and dolichocephaly.

Goldstein *et al.*¹⁰ found in a fetal ultrasonographic study of 335 fetuses of varying GA that sonographic visualization of the cerebellar growth reveals a linear relationship during the second trimester. Thus the measurement of TCD in millimetres is approximately equal to the GA in weeks during this period. The rate of growth decreases towards term. Fetal growth data from Goldstein *et al.*¹⁰ are compared with our data in Fig. 3.

Cabbad *et al.* found that 22 out of 23 asymmetrically growth impaired fetuses had a TCD lower than expected but within the normal range,¹¹ suggesting that this measurement could be used to help estimate GA in these cases.

A prospective ultrasonographic study of 19 intrauterine growth retarded fetuses showed that the growth of the TCD is unaffected by intrauterine growth retardation. Thus the sonographic measurement may serve as an independent and reliable correlate of GA against which potential deviations of growth may be compared.¹²

Another study of ultrasound measurements of TCD in twin and triplet pregnancies demonstrated that, unlike other biometric values, only the TCD measurement remains relatively unaffected by discordant growth in twin and triplet gestations.¹³

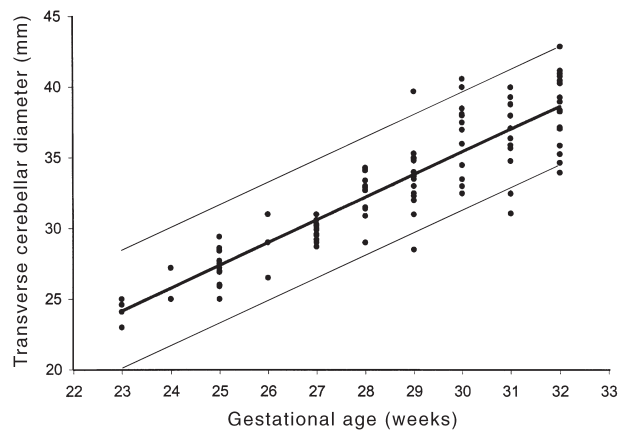


Fig. 2 Correlation between transverse cerebellar diameter in millimetres and gestational age in weeks in a group of preterm newborns between 23 and 32 weeks gestation. Transverse cerebellar diameter (mm) = $-12.9 + 1.61 \times$ gestational age (weeks). $R^2 = 0.80$, $P < 0.001$.

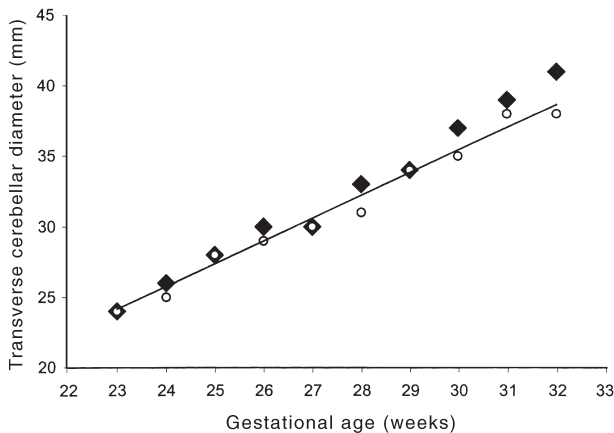


Fig. 3 Comparison of neonatal transverse cerebellar diameter data with fetal transverse cerebellar diameter data. (—), fitted line plot from our data as in Fig. 2. (◆), mean fetal transverse cerebellar diameter from Hill *et al.*¹⁴ (○), median fetal transverse cerebellar diameter from Goldstein *et al.*¹³

Furthermore, no significant difference was observed in the fetal TCD growth among singleton, twin and triplet sibling fetuses. These data confirmed the relative preservation of normal cerebellar growth in intra-uterine growth retardation (IUGR) fetuses and the similar rate of growth observed in singleton and multiple pregnancies. The TCD therefore represents an independent biometric measurement that can be used in both singleton and multi-fetal gestations to assess normal and deviant fetal growth.

In a group of 116 diabetic and non-diabetic singleton gestations with an estimated fetal weight at or above the 90th percentile, Hill *et al.* found that the TCD did not overestimate GA in the non-diabetic group, and overestimated age in the diabetic group by only 0.5 postmenstrual weeks, making it a useful tool for predicting age in this population.¹⁴ Fetal growth data from Hill *et al.*¹⁴ are compared with our data in Fig. 3.

A comparison of an ultrasonographic method of assessing GA to the currently available most reliable clinical method of assessment of GA using the new Ballard's score (NBS)¹⁵ revealed the following contrasts. The new Ballard's score was assessed for 578 newly born infants, of which 150 infants were less than 32 weeks gestation. In this study the mean difference (± 2 SD) in GA estimated by NBS – compared with certain dates – was 0.32 ± 1.58 for extremely premature infants < 26 weeks and 0.34 ± 1.68 for infants between 26 and 31 weeks gestation. In our study, 106 infants from 23 to 32 completed weeks of gestation were studied for the degree of correlation of TCD with GA. Figure 2 reveals the TCD predicts GA $\pm \approx 2.5$ weeks. The correlation coefficient (R) between TCD and GA in our study was 0.89 as compared to the correlation coefficient of 0.97 between the NBS and gestation based on last menstrual period.¹⁵ The confidence intervals in our study are wider because of the small number of infants in each GA group. However, a good correlation with increasing GA is seen. The mean plot of TCD values from our data compared with the fetal studies of Hill *et al.*¹⁴ and Goldstein *et al.*¹³ (Fig. 3) confirm that there is a good correlation in our mean values with those of fetal studies. The NBS requires a degree of handling for the physical and neurological maturity assessment that an extremely preterm infant may not tolerate or may not be possible due to

attached catheters, etc. Measuring the TCD at the time of a routine cranial ultrasound provides a quicker method to assess GA in extremely premature newborns.

There is variation in the techniques used to measure the size of the cerebellum on ultrasound in the literature. Bornholz measured the area of the cerebellar vermis in neonates and *in utero*.¹⁶ In normal neonates, there was good correlation with central vermian area and GA. Edward *et al.* studied 80 healthy term neonates by ultrasonographic assessment of cerebellar dimensions.² They concluded that the area and circumference of the vermis correlated well with GA. Multiple regression models made with a single vermis measurement along with either the cerebellar area or its circumference further improved GA prediction. Anderson *et al.*¹⁷ determined correlation between cerebellar vermis area and vermis diameter and GA in 41 newborns weighing less than 2000 g birthweight. No study in fetuses or neonates has examined the intra- or inter-observer reliability of ultrasound measurement of TCD.

Extrapolation of conclusions drawn from a large number of fetal studies done on TCD and GA correlation, suggests that this correlation can be applied even in the neonatal period in preterm newborns. Comparison of our data with fetal measurements (Fig. 3) reveals very similar values. There are only two studies in the published literature on ultrasound measurements of cerebellar dimensions and GA correlation in newborns and both were in term infants. Numbers were small and both used different dimensions of cerebellar ultrasonographic measurement to determine GA.

Ours is the first study to measure TCD of a group of preterm newborns using cranial ultrasound. These data form the basis for nomograms of transcerebellar diameter which can then be used as a tool to assist in the assessment of GA and the diagnosis of cerebellar hypoplasia.

REFERENCES

- Hata K, Hata T, Senoh D *et al.* Ultrasonographic measurement of the foetal transverse cerebellum in utero. *Gynecol. Obstet. Invest.* 1989; **28**: 111–2.
- Edward C, Raju TNK, Aldana O. Cerebellar dimensions in assessment of gestational age in neonates. *Radiology* 1991; **181** (2): 581–5.
- Rotmensch S, Goldstein I, Liberati M, Shalev J, Ben-Rafael Z, Copel JA. Foetal transverse cerebellar diameter in Down Syndrome. *Obstet. Gynecol.* 1997; **89**: 534–7.
- Reece EA, Goldstein I, Pihu G, Hobbins JC. Foetal cerebellar growth unaffected by intrauterine growth retardation: A new parameter for prenatal diagnosis. *Am. J. Obstet. Gynecol.* 1987; **157**: 622–38.
- Larroche JC. Part II. The development of the central nervous system during intrauterine life. In Falkner F, ed. *Human Development*. WA Saunders, Philadelphia, 1966; 257–276.
- Losser JD, Lemire RJ, Alvord EC Jr. The development of the folia in the human cerebellar vermis. *Anat. Rec.* 1972; **173**: 109–13.
- Kasby CB, Poll V. The breech head and its ultrasound significance. *Br. J. Obstet. Gynecol.* 1982; **89**: 106–10.
- Hadlock FP, Deter RL, Carpenter RJ, Park SK. Estimating foetal age: Effect of head shape on BPD. *AJR* 1981; **137**: 83–5.
- McLeary RD, Kuhns LR, Barr M. Ultrasonography of the foetal cerebellum. *Radiology* 1984; **151**: 439–42.
- Goldstein I, Reece EA, Pihu G, Bovicelli L, Hobbins JC. Cerebellar measurements with ultrasonography in the evaluation of foetal growth and development. *Am. J. Obstet. Gynecol.* 1987; **156**: 1065–9.
- Cabbad M, Kofinas A, Simon N, King K, Lyttle E. Fetal weight-cerebellar diameter discordance as an indicator of asymmetrical fetal growth impairment. *J. Reprod. Med.* 1992; **37**: 794–8.

- 12 Shimizu T, Gaudette S, Nimrod C. Transverse cerebellar diameter in twin gestations. *Am. J. Obstet. Gynecol.* 1992; **167**: 1004–8.
- 13 Goldstein I, Reece EA. Cerebellar growth in normal and growth restricted fetuses of multiple gestations. *Am. J. Obstet. Gynecol.* 1995; **173**: 1343–8.
- 14 Hill LM, Guzick D, Fries J, Hixson J, Rivello D. The transverse cerebellar diameter in estimating gestational age in large for gestational age fetus. *Obstet. Gynecol.* 1990; **75**: 981–5.
- 15 Ballard JL, Khoury JC, Wedig K *et al.* New Ballard Score, expanded to include extremely premature infants. *J. Paediatrics* 1991; **119**: 417–23.
- 16 Bornholz JC. Newborn cerebellar size. *Pediatrics* 1982; **70**: 284–7.
- 17 Anderson N, Wells E, Hay R, Darlow B. Cerebellar vermis measurement at cranial sonography for assessing gestational age in the newborn weighing less than 2000 grams. *Early Hum. Dev.* 1996; **44**: 59–70.